

## Bispectral Index Decreased to "0" in Propofol Anesthesia after a Cross-clamping of Descending Thoracic Aorta

Manabu Kakinohana, M.D., Ph.D.,\* Yuji Miyata, M.D.,† Tetsuya Kawabata, M.D.,† Seisyo Kawashima, M.D.,†  
Joho Tokumine, MD, Ph.D.,‡ Kazuhiro Sugahara, M.D., Ph.D.§

THE Bispectral Index (BIS) monitor (BIS® monitor; Aspect Medical System, Inc., Newton, MA) integrates electroencephalographic data *via* a proprietary algorithm based on empirical data into a nominal 100 to 0 scale, in which 100 represents the awake state and 0 represents the isoelectric electroencephalogram.<sup>1</sup> The BIS® monitor is highly capable of correctly predicting both the loss and recovery of consciousness and has been reported to be more reliable in assessing the level of sedation and hypnosis during surgery than other available processed electroencephalogram algorithms.<sup>2-4</sup> It also has been used clinically to guide anesthetic drug administration<sup>5</sup> and to quantify the pharmacokinetic and pharmacodynamic action of anesthetic drugs in the laboratory setting.<sup>6</sup>

We report a case of a rapid decrease in the BIS score during total intravenous anesthesia using propofol after cross-clamping the descending thoracic aorta for elective thoracic aortic aneurysm repair and suggest that the BIS® monitor provides useful information on altered propofol pharmacokinetics after aortic cross-clamping.

### Case Report

A 46-yr-old man was admitted for elective thoracic aortic aneurysm repair. His history was unremarkable except for hypertension. After routine monitoring of vital signs was supplemented with BIS® monitoring, anesthesia was induced with fentanyl and propofol and maintained with infusions of propofol and ketamine and intermittent injections of fentanyl *via* an upper limb vein. The infusion rate of propofol was varied to maintain the BIS between 40 and 60. A Swan-Ganz catheter was inserted into the right internal jugular vein for monitoring continuous cardiac output. The patient had consented to participate in a clinical investigation of the suppressive effects of propofol anesthesia on transcranial electrical motor evoked potentials during thoracic and thoracoabdominal aortic surgery. Blood samples for this purpose were drawn from the arterial line at defined time intervals. A stable level of anesthesia was maintained, with a BIS score of approximately 60. After isolation of both the right femoral artery and vein, the arterial cannula was inserted and then attached to the pump oxygenator. A long venous cannula (Long Cannula RK-28M, Toyobo, Osaka, Japan) was introduced into the right femoral vein, and the tip of this catheter was

advanced between the inferior vena cava and right atrium. The tip was confirmed to be correctly positioned by transesophageal echocardiography. A standard roller pump and oxygenator to circulate oxygenated blood from the long venous cannula to the femoral artery were available for partial cardiopulmonary bypass of distal perfusion. During surgery, the patient was hemodynamically stable. A cross-clamp of the descending thoracic aorta at the level of Th 7 was performed, followed by the start of partial cardiopulmonary bypass of distal perfusion at a perfusion rate of 3–3.2 l/min under normothermic conditions. Guided by transesophageal echocardiographic images that revealed the left ventricular cavity size and function, perfusionists could regulate the rate of distal perfusion and level in the venous reservoir for adequate preload in the upper body. Approximately 15 min after cross-clamping, the patient's BIS level decreased rapidly from its steady-state value of 60 to a value of 0 (infusion rate of propofol,  $6 \text{ mg} \cdot \text{kg}^{-1} \cdot \text{h}^{-1}$ ). Mean arterial pressure was 72 mmHg, and continuous cardiac output monitoring indicated 1.2–1.4 l/min proximal to the aortic cross-clamp. Pulsation of bilateral carotid arteries was clearly palpable, suggesting adequate blood supply to the brain. Although depth of anesthesia was assessed as very deep, infusion of propofol was discontinued until the BIS started to increase. Fifteen minutes after infusion of propofol was stopped, the BIS began to increase by degrees. At a BIS score of 30, infusion of propofol was begun at  $6 \text{ mg} \cdot \text{kg}^{-1} \cdot \text{h}^{-1}$ . Subsequently, the BIS score began to decrease again and was less than 10 at approximately 25 min after restart of propofol infusion. This phenomenon could be reproduced by "stopping and restarting" of propofol infusion (Fig. 1). An aortic graft was inserted, with a cross-clamp time of 105 min. Approximately 15 min after declamping, the patient's BIS level increased slowly from a value of 20 to more than 30. Surgical procedures were completed uneventfully, and this patient was admitted to the intensive care unit, with an anesthetic time of 7 h 45 min. The patient had recovered completely from anesthesia 6 h after admission to the intensive care unit and manifested no neurologic deficits. All blood samples drawn simultaneously from the radial artery and the left femoral artery, including those before cross-clamping of the aorta, at 3 time points during aortic cross-clamping, and 15 min after declamping, were retained for high-performance liquid chromatography (MC Medical, Inc., Osaka, Japan) analysis. High-performance liquid chromatography analysis revealed that the propofol concentrations of samples from the radial artery (proximal to the aortic clamp) during cross-clamping of the aorta were significantly elevated compared with pre-cross-clamping values. Also, propofol concentrations in samples from the radial artery were approximately 4–5 times higher than those from the femoral artery (Fig. 1).

### Discussion

The depth of anesthesia using propofol was assessed with the BIS® monitor, which appears to be a very promising tool for evaluating the adequacy of anesthesia.<sup>7</sup> Therefore, the BIS® monitor can provide information on an adequate rate of propofol infusion in individual patients. In our case, before the aortic cross-clamp, the BIS® monitor indicated that  $6 \text{ mg} \cdot \text{kg}^{-1} \cdot \text{h}^{-1}$  of propofol was an adequate rate of infusion. However,

\* Associate Professor, † Instructor, ‡ Assistant Professor, § Professor.

Received from the Department of Anesthesiology, Faculty of Medicine, University of the Ryukyus, Okinawa, Japan. Submitted for publication December 26, 2002. Accepted for publication May 1, 2003. Support was provided solely from institutional and/or departmental sources.

Address reprint requests to Dr. Kakinohana: Department of Anesthesiology, Faculty of Medicine, University of the Ryukyus, 207 Uehara, Nishihara, Okinawa, 903-0125, Japan. Address electronic mail to: mnb-shk@ryukyu.ne.jp. Individual article reprints may be purchased through the Journal Web site, [www.anesthesiology.org](http://www.anesthesiology.org).

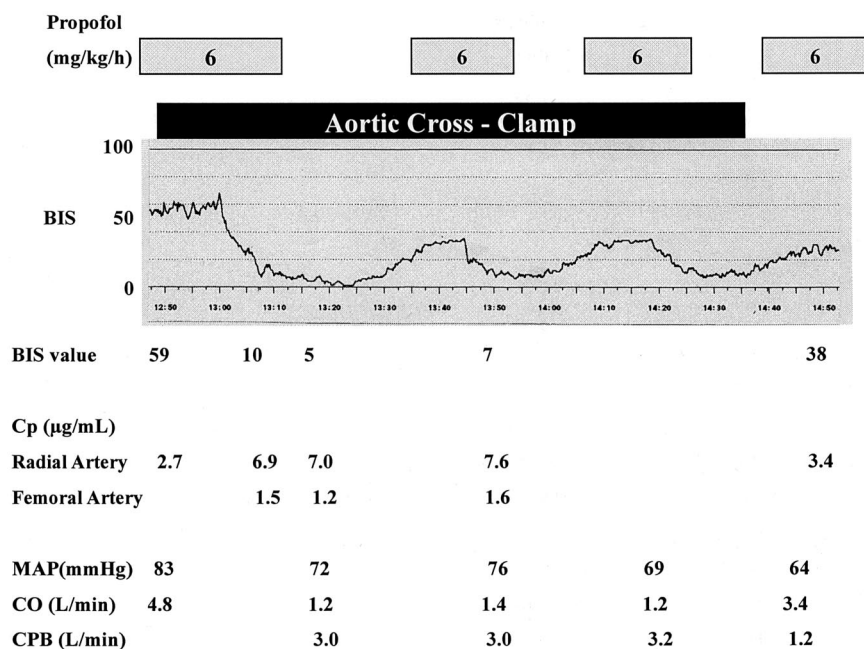


Fig. 1. Changes in Bispectral Index (BIS), infusion rate of propofol, mean arterial pressure, cardiac output, and flow rate of a partial cardiopulmonary bypass of distal perfusion before, during, and after aortic cross-clamp. CO = cardiac output measured by Swan-Ganz catheter; Cp = plasma concentrations of propofol measured by high-performance liquid chromatography; CPB = partial cardiopulmonary bypass for distal perfusion; MAP = mean arterial pressure in the right radial artery.

despite steady infusions of propofol, a rapid decrease in BIS occurred approximately 15 min after the aortic cross-clamp. Hypoperfusion in the brain was an unlikely cause of this decrease, according to physical findings that included palpable pulses of bilateral carotid arteries and hemodynamic variables that included radial arterial blood pressure and cardiac output. Indeed, this patient had normal emergence from anesthesia and normal neurologic function within 24 h of the postoperative period. In this case, BIS values had altered, corresponding to the “stopping-restarting” of propofol infusion, and the plasma propofol concentration was much higher during the aortic cross-clamping than before. It was therefore likely that the increase in plasma propofol concentration ( $> 7 \mu\text{g/mL}$ ) would induce an isoelectrical encephalogram resulting in a BIS of 0 during the aortic cross-clamp.

There are two explanations for such a decreased BIS value. First, cross-clamping of the thoracic aorta would change circulatory conditions, such as reducing circulating volume and decreasing cardiac output in the area proximal to the aortic cross-clamp, because blood flow from the heart should be only for perfusion of the head, neck, and upper limbs. It was reported that blood flow through the descending thoracic aorta was approximately 65–70% of the cardiac output in humans,<sup>8</sup> meaning that only 30–35% of cardiac output may be essential for perfusion of the area proximal to the cross-clamp of the descending thoracic aorta. Therefore, it would be reasonable for approximately one third of the total blood volume to be circulated in the area proximal to the aortic cross-clamp. In this case, transesophageal echocardiographic images confirmed that the tip of the long venous cannula was positioned at the junction between the inferior vena cava and right atrium. This long venous cannula has 10 oval side-holes ( $10 \times 5 \text{ mm}$ ) in the 20 cm that

compose the tip. We believe that much of the venous blood in the inferior vena cava would be withdrawn from the side-holes of this cannula during the cardiopulmonary bypass. During the stage of cardiopulmonary bypass for distal perfusion, we used transesophageal echocardiography to monitor the left ventricular cavity size and function to allow adequacy of preload and optimal fluid resuscitation for maintenance of both upper and lower body perfusion. Although it is likely that blood from the inferior vena cava should enter the right atrium and mix with blood from the superior vena cava, we think that only a small amount of such blood entered the right atrium, with the result that an almost “split circulation” was produced by the thoracic aortic cross-clamp. This change would greatly reduce the distribution volume of propofol infused *via* the upper limb and result in much higher plasma propofol concentrations in the body proximal to the aortic cross-clamp when the infusion rate was set on the basis of body weight.

Second, the reduction of hepatic clearance of propofol should be considered. A clinical study<sup>9</sup> of patients having orthotopic liver transplantation showed that the area under the time–blood propofol concentration curve was significantly greater than in patients having extrahepatic abdominal surgery. Furthermore, Mashimo *et al.*<sup>10</sup> demonstrated that total plasma clearance of propofol in the anhepatic phase was significantly lower than that in the postanhepatic phase during liver transplantation in the pig. Because blood flow into the liver from the area proximal to the aortic cross-clamp theoretically vanishes, propofol clearance is ultimately decreased in that area, which would, in part, result in an increase in the blood concentration of propofol.

In our patient, ketamine, as well as propofol, was infused at  $0.5 \text{ mg} \cdot \text{kg}^{-1} \cdot \text{h}^{-1}$  during the aortic cross-clamp. Although we did not measure blood concentra-

tions of ketamine in this patient, it is, of course, likely that with the infusion of ketamine, its blood concentration increased and deepened the level of anesthesia.<sup>11</sup> However, ketamine does not influence either BIS or electroencephalogram variables during propofol infusion.<sup>11,12</sup> Together with the series of observations in our patient, this dramatic change of BIS values should be associated predominantly with changes in propofol pharmacokinetics.

In our institution, monitoring of motor evoked potentials was used to monitor the functional integrity of the descending motor pathways during thoracic or thoracoabdominal aneurysm surgery under total intravenous anesthesia *via* an upper limb vein. It has been our experience in surgery of the descending thoracic aorta that motor evoked potentials, in the setting of steady-state propofol infusion, disappeared during the aortic cross-clamp and reappeared after propofol infusion was stopped. From this case and those experiences, it can be considered that in the cross-clamp of the thoracic aorta, a rapid change in BIS value may reflect an increase in propofol concentration in "the brain," caused by a reduction of distribution volume for propofol and an ultimate reduction of its clearance. This change may induce undetectable motor evoked potentials without any spinal cord injury during thoracic aortic surgery and result in a "false-positive."

In conclusion, we would like to emphasize that an unexpected, rapid decrease in the BIS score during cross-clamp of the thoracic aorta might reflect an unexpected increase in propofol concentration in the proximal area of the aortic cross-clamp. It was speculated that this increase in propofol concentration might be caused

by alterations of the pharmacokinetics of propofol by the aortic cross-clamp. The BIS® monitor is a useful tool for providing information on the adequate infusion rate of propofol during descending thoracic aortic surgery.

## References

1. Olofson E, Dahan A: The dynamic relationship between end-tidal sevoflurane and isoflurane concentrations and Bispectral Index and spectral edge frequency of the electroencephalogram. *ANESTHESIOLOGY* 1999; 90:1345-53
2. Flaisch R, Windsor A, Sigl J, Sebel PS: Recovery of consciousness after thiopental or propofol: Bispectral Index and isolated forearm technique. *ANESTHESIOLOGY* 1997; 86:613-9
3. Liu J, Singh H, White PF: Electroencephalogram bispectral analysis predicts the depth of midazolam-induced sedation. *ANESTHESIOLOGY* 1996; 84:64-9
4. Liu J, Singh H, White PF: Electroencephalogram bispectral index correlates with intraoperative recall and depth of propofol induced sedation. *Anesth Analg* 1997; 84:185-9
5. Song D, Joshi JP, White PF: Titration of volatile anesthetics using Bispectral Index facilitates recovery after ambulatory anesthesia. *ANESTHESIOLOGY* 1997; 87:842-84
6. Billard V, Gambus PL, Chamoun N, Stanski DR, Shafer SL: A comparison of spectral edge, delta power and bispectral index as EEG measures of alfentanil, propofol, and midazolam drug effect. *Clin Pharmacol Ther* 1997; 91:1947-9
7. Doi M, Gajraj RJ, Mantzaridis H, Kenny GN: Relationship between calculated blood concentration of propofol and electrophysiological variables during emergence from anaesthesia: Comparison of bispectral index, spectral edge frequency, median frequency and auditory evoked potential index. *Br J Anaesth* 1997; 78:180-4
8. Cariou A, Monchi M, Joly LM, Bellenfant F, Claessens YE, Thebert D, Brunet F, Dhainaut JF: Noninvasive cardiac output monitoring by aortic blood flow termination: Evaluation of the Sometec Dynemo-3000 system. *Crit Care Med* 1998; 26:2066-72
9. Veroli P, O'Kelly B, Bertrand F, Trouvin JH, Farinotti R, Ecoffey C: Extrahepatic metabolism of propofol in man during the anhepatic phase of orthotopic liver transplantation. *Br J Anaesth* 1992; 68:183-6
10. Mashimo T, Tsuda Y, Ikeda M, Shibuya H, Inagaki Y, Seto T, Yoshiya I: Pharmacokinetics of propofol during liver transplantation in small pigs. *Masui* 1996; 45:293-7
11. Sakai T, Singh H, Mi WD, Kudo T, Matsuki A: The effect of ketamine on clinical endpoints of hypnosis and EEG variables during propofol infusion. *Acta Anaesthesiol Scand* 1999; 43:212-16
12. Hirota K, Kubota T, Ishihara H, Matsuki A: The effects of nitrous oxide and ketamine on the bispectral index and 95% spectral edge frequency during propofol-fentanyl anaesthesia. *Eur J Anaesthesiol* 1999; 16:779-83

Anesthesiology 2003; 99:1225-7

© 2003 American Society of Anesthesiologists, Inc. Lippincott Williams & Wilkins, Inc.

## Recording Electrocardiograms Can Be Dangerous

Jürgen Peters, Prof. Dr. med

PARTICIPATION of anesthesiologists in murder trials is probably rare. I became involved in a case of an anesthesiologist prosecuted for murder by application of

succinylcholine. The case investigated whether electrocardiogram strip chart recordings, showing ventricular fibrillation and presented by the charged physician as being recorded from his wife during cardiopulmonary resuscitation (CPR), were authentic or faked with a simulator.

This article is featured in "This Month in Anesthesiology." Please see this issue of *ANESTHESIOLOGY*, page 5A.

Professor of Anesthesiology and Intensive Care Therapy, and Chairman.

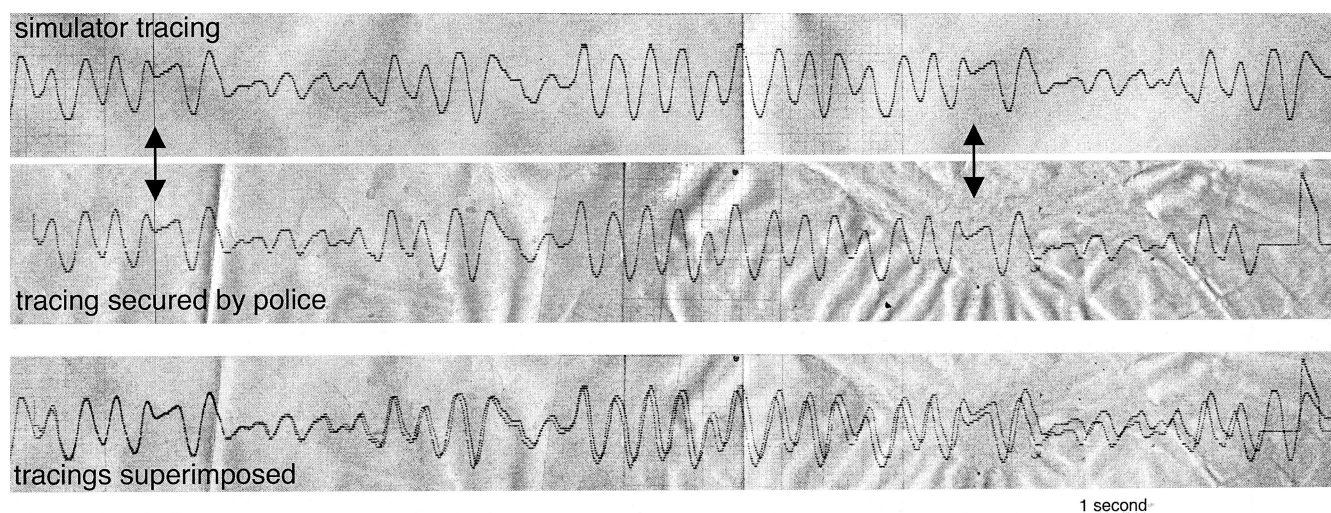
Received from Klinik für Anästhesiologie und Intensivmedizin, Universitätsklinikum Essen, Essen, Germany. Submitted for publication April 18, 2003. Accepted for publication May 21, 2003. Support was provided solely from institutional and/or departmental sources.

Address reprint requests to Dr. Peters: Klinik für Anästhesiologie und Intensivmedizin, Universitätsklinikum Essen, Hufelandstr. 55, D-45122 Essen, Germany. Address electronic mail to: juergen.peters@uni-essen.de. Individual article reprints may be purchased through the Journal Web site, [www.anesthesiology.org](http://www.anesthesiology.org).

## Case Report

A 35-yr-old woman was found dead by a mobile physician and paramedic rescue team at the bottom of a stairway next to a vacuum cleaner. Prolonged CPR was unsuccessful. Eight minutes earlier, the team had been dispatched to the scene, a couple's home, *via* telephone alert by the woman's husband, a trained anesthesiologist. He reportedly had found his wife unconscious and looking pale, with a slow and weak pulse that eventually faded. Before the alert, he himself





**Fig. 1.** Ventricular fibrillation tracing recorded from a simulator, the tracing presented to the rescue team, and both tracings superimposed using imaging software. Epochs from the simulator are repeated after 4 s (arrows).

had administered CPR, including tracheal intubation and bag ventilation using his emergency equipment. Furthermore, he presented several electrocardiogram strips with date and time annotations showing consecutive sinus bradycardia (exactly 30 beats per min), asystole, and ventricular fibrillation (fig. 1), recorded before the team's arrival using his portable electrocardiogram monitor and printer, and he suggested that his wife's blood pressure problems possibly evoked her accident.

After the woman was pronounced dead, police officers were called and performed a workup and seized materials, including the electrocardiographic recordings. Of note, one policeman noted that the dead woman's husband might have tried to conceal one of the electrocardiogram strips.

On forensic autopsy, some pulmonary edema, a scalp laceration, and findings consistent with intubation and CPR were seen, but no pathology indicating inflicted external force or explaining the woman's death. Accordingly, after taking specimens, the woman's corpse was released for cremation. On later review, however, the possibility of murder rather than an accident was considered because of a suspected discrepancy between the initial sinus bradycardia and the stated but unsuccessful resuscitation measures, a succinylcholine vial considered missing from the anesthesiologist's emergency case, and testimony regarding the couple's seriously disturbed relationship. The anesthesiologist was charged with murder by using succinylcholine.

However, no succinylcholine or its degradation products were found in specimens by using mass spectrometry. Subsequently, the court sought my testimony on whether electrocardiographic recordings could have been generated using an electrocardiogram simulator (Heartsim 2000; Laerdal, Stavanger, Norway) available to the accused at his hospital.

In response, I recorded simulator rhythms on a similar electrocardiogram recorder with all lead permutations in the recorder's diagnostic and monitor modes and compared them with electrocardiographic strips seized from the scene. Furthermore, I asked the simulator's manufacturer to provide simulated recordings and to indicate how they had been originally obtained. Of note, the tracing showing ventricular fibrillation secured on the scene bore a striking resemblance with one recording from the simulator. In fact, both tracings showing ventricular fibrillation were essentially superimposable when using imaging software (fig. 1). Furthermore, the fibrillation pattern appeared to be repetitive after 4 s. Accordingly, I testified that at least part of the electrocardiographic recordings secured on the scene, previously presumed to have been recorded from the accused's wife during CPR, was identical with the unique ventricular fibrillation pattern stored in and displayed by this particular simulator. Ruling out random coincidence, this implied that electrocardiogram tracings

seized on the scene had not been recorded from the woman found dead.

Subsequently, the anesthesiologist admitted to having killed his wife, without elaborating on the circumstances for legal reasons, and was sentenced to prolonged imprisonment.

## Discussion

This case is interesting from a medical, educational, and legal perspective. Certainly, intravenous or intramuscular succinylcholine can evoke prolonged respiratory muscle paralysis<sup>1,2</sup> and asphyxia within minutes. However, because it is rapidly cleaved in blood and tissues and breakdown continues after death, succinylcholine can hardly be detected in specimens by routine forensic mass spectrometry.<sup>3,4</sup> Accordingly, succinylcholine was not detected in the remains of five victims of a confessed serial killer using intramuscular suxamethonium, but was detected in a syringe buried nearby.<sup>5</sup> With no proof of succinylcholine administration, the prosecutor's line of evidence rested on the investigation of whether electrocardiographic recordings, previously stated by the accused to have been recorded personally from his wife during CPR, were faked, thus implying a criminal act.

Ventricular fibrillation is recognized by erratic activity around the electrocardiogram's baseline with no regular pattern, but possible periodicity has not been studied in humans. However, fibrillated animal hearts show little evidence of relevant periodicity.<sup>6,7</sup> Thus, any repetitive pattern during an epoch of apparent fibrillation suggests artifact rather than authentic cardiac activity.

Electrocardiogram simulators have stored in their memory epochs of rhythms once recorded from "real" patients. It is less appreciated, however, that these epochs are displayed as endless loops and, hence, display periodicity not present in original recordings. With respect to ventricular fibrillation, this simulator displays an identical fibrillation pattern every 4 s (fig. 1). Accord-

ingly, the same periodicity in the secured tracing suggested an origin from a simulator rather than authentic fibrillation. Furthermore, fibrillation tracings were virtually superimposable. In fact, I considered the chance that an epoch of fibrillation had shown both the same periodicity and the same pattern morphology as a specific simulator's fibrillation tracing as zero, suggesting that the electrocardiogram (including date and time annotations) was faked. Of importance, filters used in the electrocardiogram recorder's diagnostic and monitor modes substantially changed the fibrillation pattern, and without painstaking comparisons, using all leads and filters, the identity of the tracings easily could have gone unnoticed.

In summary, this scurrilous case shows that not all apparently medical evidence can be taken to be real and

that criminal action may involve the use of faked electrocardiograms using medical simulators.

## References

1. Durant NN, Katz RL: Suxamethonium. *Br J Anaesth* 1982; 54:195-206
2. Vanlinthout LE, van Egmond J, de Boo T, Lerou JG, Wevers RA, Booij LH: Factors affecting magnitude and time course of neuromuscular block produced by suxamethonium. *Br J Anaesth* 1992; 69:29-35
3. Forney RB Jr, Carroll FT, Nordgren IK, Pettersson BM, Holmstedt B: Extraction, identification and quantitation of succinylcholine in embalmed tissue. *J Anal Toxicol* 1982; 6:115-9
4. Balkon J, Donnelly B, Rejent TA: Determination of succinylcholine in tissues by TLC, GC/NPD, and GC/MS. *J Anal Toxicol* 1983; 7:237-40
5. Maeda H, Fujita MQ, Zhu BL, Ishidam K, Oritani S, Tsuchihashi H, Nishikawa M, Izumi M, Matsumoto F: A case of serial homicide by injection of succinylcholine. *Med Sci Law* 2000; 40:169-74
6. Small M, Yu D, Harrison RG, Robertson C, Clegg G, Holzer M, Sterz F: Deterministic nonlinearity in ventricular fibrillation. *Chaos* 2000; 10:268-77
7. Yu D, Small M, Harrison RG, Robertson C, Clegg G, Holzer M, Sterz F: Measuring temporal complexity of ventricular fibrillation. *Phys Lett A* 2000; 265:68-75

Anesthesiology 2003; 99:1227-9

© 2003 American Society of Anesthesiologists, Inc. Lippincott Williams & Wilkins, Inc.

# Successful Resuscitation from Prolonged Ventricular Fibrillation Using a Portable Percutaneous Cardiopulmonary Support System

Hiroshi Sunami, M.D.,\* Yoshihisa Fujita, M.D.,† Tomoko Okada, M.D.,\* Satoshi Wada, M.D.,\* Motoko Kimura, M.D.,‡ Atsuo Sari, M.D.,§ Kazuhiro Yoshida, M.D.¶

TWO cases of ventricular fibrillation (VF) under general anesthesia during noncardiac surgery are presented. Although both patients were refractory to conventional cardiopulmonary resuscitation (CPR), they were rescued using a percutaneous cardiopulmonary support (PCPS) system without any complications. We emphasize the importance of emergency extracorporeal circulation

A 75-yr-old man was scheduled for gastrectomy under general anesthesia with a diagnosis of early gastric cancer. He had had dilated cardiomyopathy for 5 yr. His medications included an angiotensin-converting enzyme inhibitor, digitalis, and a  $\beta$ -blocker. His physical status was New York Heart Association class II. Preoperative echocardiography revealed mild mitral regurgitation and diffuse left ventricular hypokinesis with an ejection fraction of 34%. Coronary angiography performed 1 month earlier showed mild luminal irregularities in the right and left coronary arteries but no significant stenotic changes.

Anesthesia was induced with midazolam, fentanyl, and vecuronium, and the trachea was intubated. Anesthesia was maintained with sevoflurane-oxygen and nitrous oxide. Radial artery and pulmonary artery catheters were inserted, and their pressures were 120/80 mmHg

with PCPS as a life-saving measure in prolonged CPR during intraoperative cardiac arrest.

## Case Reports

### Case 1

and 25/12 mmHg, respectively. Ten milliliters 1% lidocaine was administered through an epidural catheter inserted from Th8 to Th9, followed by continuous infusion at a rate of 4 ml/h of a mixture of 40 ml 1% lidocaine and 500  $\mu$ g fentanyl.

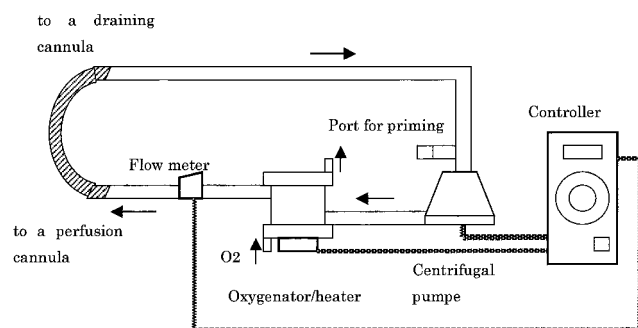
The surgery proceeded uneventfully with stable hemodynamics and arterial oxygen saturation. When the epigastric artery was ligated 1 h after the surgery was begun, however, VF occurred after ventricular extrasystoles. Closed-chest compression was immediately started by the surgeons, sevoflurane was switched off, and the lungs were manually ventilated with oxygen. For resuscitation, 1.0 mg ephedrine, 3.0 mg epinephrine in total, 80 mg lidocaine, and 20 ml sodium bicarbonate were administered. The findings of arterial blood gas/pH and electrolyte analysis during CPR revealed pH 7.41, 29 mmEq/l  $\text{pCO}_2$ , 477 mmHg  $\text{pO}_2$ , 131 mEq/l Na, and 4.3 mEq/l K, with a hematocrit of 38%. A peak arterial pressure of 80 mmHg was maintained by closed-chest compression during CPR. The patient could not be defibrillated with direct current shocks despite six attempts (200 J  $\times$  3, 300 J, 400 J  $\times$  2). The decision to use PCPS was made 25 min after the onset of VF. A 16.5-French, 15-cm perfusion cannula (CX-EB16ASH; TERUMO, Tokyo, Japan) was inserted through the left femoral artery, and a 21-French, 50-cm draining cannula (CX-EB21VSH, TERUMO) was inserted in the right atrium through the right internal jugular vein. Placement of perfusion and draining cannulae was performed using a modified Seldinger technique as follows. After skin preparation and draping, we advanced an 18-gauge needle into the vessels, replaced it with a guidewire, and incised the skin. The percutaneous tract was

\* Senior Resident, § Professor, † Associate Professor, § Lecturer, Department of Anesthesiology and Intensive Care Medicine, ¶ Department of Gastroenterological Surgery, Kawasaki Medical School.

From the Departments of Anesthesiology and Intensive Care Medicine and Gastroenterological Surgery, Kawasaki Medical School, Okayama, Japan. Submitted for publication February 12, 2003. Accepted for publication May 28, 2003. Support was provided solely from institutional and/or departmental sources.

Address reprint requests to Dr. Fujita: Department of Anesthesiology and Intensive Care Medicine, Kawasaki Medical School, 577 Matsushima, Kurashiki-city, Okayama, 701-0192 Japan. Address electronic mail to: fujitay@med.kawasaki-m.ac.jp. Individual article reprints may be purchased through the Journal Web site, [www.anesthesiology.org](http://www.anesthesiology.org).





### Case 2

A 68-yr-old man was scheduled for internal drainage of a pancreatic pseudocyst by Roux-en-Y cystojejunostomies. He had a 4-yr history of diabetes mellitus, which was treated with insulin. Although he had had chest pain 8 yr earlier, his coronary artery was angiographically normal. He had had no limitation in his physical activity. Preoperative echocardiography revealed good wall motion of the left ventricle with an ejection fraction of 76% and moderate mitral regurgitation. His preoperative blood tests were normal except for a high blood sugar level.

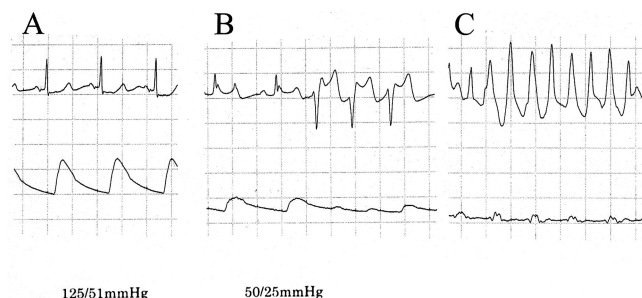
Anesthesia was induced and maintained in the same way as in case 1. Epidural analgesia was performed. Routine monitoring included electrocardiography, pulse oxymetry, capnometry, and direct arterial pressure *via* the left radial artery (fig. 2A). The patient was hemodynamically stable except for short runs of ventricular extrasystole observed when the surgery was started. This was treated with intravenous 125 mg mexiletine hydrochloride.

When the pancreatectomy was almost completed with 200 ml blood loss 3 h after the start of the surgery, VF developed shortly after hypotension (fig. 2B and C). Resuscitative measures were promptly started, and the lungs were ventilated with pure oxygen. Direct current shocks (200 J, 300 J, 360 J  $\times$  3) along with administration of drugs, including 50 mg lidocaine, 5.5 mg epinephrine in total, and 40 U vasopressin, were ineffective for restoring spontaneous heart rhythm. VF persisted despite CPR. We decided to use PCPS 20 min after the onset of VF. Emergency extracorporeal circulation was established percutaneously through cannulae inserted into the femoral vein and artery 10 min after that. We stopped chest compression and administration of drugs for resuscitation on initiation of extracorporeal circulation. Although a high mean arterial pressure was achieved initially because of the residual vasoconstrictive effect, it could be maintained at a flow rate of 3 l/min with a mean arterial pressure of 80 mmHg 20 min later. Direct current shock immediately after extracorporeal circulation failed, but the patient was defibrillated on PCPS 20 min later and spontaneous circulation was restored. The flow rate was reduced to 2.0 l/min, and sevoflurane inhalation was restarted. Twenty milligrams heparin was administered for anticoagulation at 1 h after extracorporeal circulation. The automated clotting time was maintained around 200 s after that. The surgery was completed 4 h later. Coronary angiography performed on the same day as PCPS revealed mild stenosis in the left anterior descending coronary artery. This was interpreted as insignificant by cardiologists. The patient was successfully decannulated the next day in the intensive care unit and transferred to the ward the following day. He was able to return home 2 weeks later without any neurologic complications.

**Fig. 1.** Schematic diagram of the portable cardiopulmonary support system. It consists of a controller with a battery, a flow meter probe, a cone-type centrifugal pump, a heating pad, and heparin-bonded preconnected circuitry with a hollow fiber membrane oxygenator. The system has an autopriming function to facilitate air bubble elimination from the circuitry. Priming with 470 ml normal saline solution and clearance of air from the whole circuitry can be completed in less than 5 min. The hatched area is kept sterile until connection to perfusion and draining cannulae. Thick arrows indicate blood flow direction, and thin arrows indicate oxygen flow direction.

then serially dilated with 8-French and 12-French dilators. The perfusion and draining cannulae incorporated with a dilator were advanced over the guidewire. The right jugular vein was chosen for venous access, because an attempt to puncture both femoral veins was not successful, whereas arterial access could be easily obtained by locating pulsation of the femoral artery.

Extracorporeal circulation was started at a flow rate of 2 to 3 l/min with our portable PCPS system (Capiiox SP-101, TERUMO), and closed-chest compression was discontinued (fig. 1). The mean aortic pressure was 130 mmHg. It took about 10 min from the decision to initiate extracorporeal circulation. The patient resumed spontaneous rhythm (120 beats/min) and an arterial pressure of 140/100 mmHg with the first direct current shock 3 min after the start of extracorporeal circulation. PCPS was continued at a flow rate of 2 l/min with an arterial pressure of 100/60 mmHg. Anticoagulation with heparin was started 1 h later to keep the automated clotting time around 200 s. After hemostasis and closure of the abdomen, the patient was transferred to the intensive care unit with the PCPS system. Although he had to undergo relaparotomy for hemostasis the same night, he could be separated from the PCPS system the next day. He remained in the intensive care unit for 2 days under hemodynamic monitoring. Playback of the monitor recording during operation revealed ST segment elevation in electrocardiogram lead II before VF developed. The patient underwent gastrectomy 4 weeks later uneventfully with PCPS standby.



**Fig. 2.** (A) Playback of the electrocardiogram II lead and arterial pressure tracing at a paper speed of 25 mm/s from case 2 after induction of anesthesia (arterial pressure = 125/51 mmHg). (B) Arterial pressure decreased suddenly to 50/25 mmHg. ST segment elevation and short run are noted. (C) Thirty seconds later, ventricular fibrillation developed.

### Discussion

We experienced two successful CPRs using PCPS in patients with refractory VF during noncardiac surgery. In our patients, conventional CPR was continued for about 35 min and 30 min in cases 1 and 2, respectively. The time required to initiate cardiopulmonary support after a decision to do so was made was 10 min. We believe that the two patients would not have fully recovered without the use of PCPS.

In 1989, Long *et al.*<sup>1</sup> reported a case of successful resuscitation of bupivacaine-induced cardiac arrest using a conventional cardiopulmonary bypass machine. They needed a midsternotomy for total extracorporeal circulation, blood transfusion to increase hematocrit, and volume infusion to increase mean arterial pressure. The

complexity and technical difficulty of the procedure prevented its widespread use as a resuscitative measure. With the advent of the PCPS system composed of a centrifugal pump and heparin-bonded preconnected circuitry with a hollow fiber membrane, extracorporeal circulation became more practical.

Extracorporeal circulation with PCPS is a well-established clinical technique in high-risk cardiac catheterization and postcardiotomy cardiogenic shock.<sup>2</sup> Recently, anecdotal case reports have suggested increased recognition of emergency PCPS as a life-saving measure for pulmonary thrombosis,<sup>3</sup> cardiac failure with pulmonary hypertension,<sup>4</sup> in-hospital CPR,<sup>5</sup> and drug intoxication.<sup>6</sup> Nevertheless, statistics regarding the use of emergency PCPS have revealed that the results are not necessarily favorable, especially when the neurologic outcome is considered as the end point.<sup>7</sup> Implementation of PCPS more than 30 min after unwitnessed cardiac arrest or CPR yields a patient survival rate of less than 10%.<sup>7-9</sup> The decision to use PCPS should be made as soon as possible in prolonged CPR for complete recovery.

To the best of our knowledge, no cases of emergent PCPS resuscitation in patients with noncardiac surgery have been previously reported. Because cardiac arrests during general anesthesia are all witnessed, victims in the operating room seem to benefit most from PCPS. A reported good survival rate for cardiac arrest victims in a catheterization laboratory, where situations are similar to those observed in the operating room with the use of PCPS, confirms this speculation.<sup>10</sup>

Technical advances such as preassembled circuitry, a small prime volume of 470 ml, a centrifugal pump, ease of air clearance from circuitry because of the absence of the heat exchanger and autoprimer functions of the system, and a percutaneous technique with thin-walled cannulae made the rapid initiation of extracorporeal circulation feasible (fig. 1). Because the heating pad incorporated into the PCPS is not so effective as a heat exchanger for the control of body temperature, patients become slightly hypothermic at 33–35°C during the course of extracorporeal circulation with our PCPS. Because hypothermia has neuroprotective effects, however, the unavoidable hypothermia might have contributed to the complete recovery of our patients to some extent.

Although PCPS seems to be life saving in many cases of prolonged CPR in the operating room, it is not indicated for patients with active bleeding or severe aortic regurgitation. The potential complications of PCPS include perforation or injury of vessels during placement of the large cannulae and ischemia in the lower extremities because of compromised blood flow in the femoral artery by the perfusion cannulae.<sup>11</sup>

It should be emphasized that for immediate and safe institution of extracorporeal circulation, teamwork on

the part of the specialists in the operating room (e.g., anesthesiologists, cardiologists, perfusionists, surgeons) is imperative along with a rapidly available PCPS system.

The increase in coronary perfusion pressure with PCPS may play a pivotal role in the return of spontaneous circulation, because adequate coronary perfusion pressure is well known to be the best predictor of successful defibrillation.<sup>12</sup> In our cases, mean aortic pressures to 130 mmHg (case 1) or 80 mmHg (case 2) were achieved with the institution of PCPS. Right atrial pressure presumably decreased because of venous drainage to PCPS, leading to a substantial increase in the coronary perfusion pressure. The successful defibrillation in our cases may thus be explained by the increased coronary perfusion pressure induced by PCPS.

In summary, we have described two patients with intraoperative cardiac arrest who were successfully resuscitated using a PCPS system. The patients could not have survived without it. Because intraoperative cardiac arrest victims are considered good candidates for full recovery, PCPS should be considered in any difficult cases of CPR in the operating room.

The authors thank Kazuo Tanemoto, M.D. and Sohei Hamanaka, M.D., Department of Cardiothoracic and Vascular Surgery, Ken'ichi Kasai, Perfusionist, and our colleagues in the Departments of Anesthesiology and Intensive Care Medicine and Cardiology, Kawasaki Medical School, Kurashiki, Japan, for their cooperation during resuscitation.

## References

1. Long WB, Rosenblum S, Grady IP: Successful resuscitation of bupivacaine-induced cardiac arrest using cardiopulmonary bypass. *Anesth Analg* 1989; 69: 403–6
2. Booth KL, Roth SJ, Perry SB, del Nido PJ, Wessel DL, Laussen PC: Cardiac catheterization of patients supported by extracorporeal membrane oxygenation. *J Am Coll Cardiol* 2002; 40:1681–6
3. Szocik J, Rudich S, Csete M: ECMO resuscitation after massive pulmonary embolism during liver transplantation. *ANESTHESIOLOGY* 2002; 97:763–4
4. Satoh H, Masuda Y, Izuta S, Yaku H, Obara H: Pregnant patient with primary pulmonary hypertension: General anesthesia and extracorporeal membrane oxygenation support for termination of pregnancy. *ANESTHESIOLOGY* 2002; 97:1638–40
5. Chen YS, Chao A, Yu HY, Ko WJ, Wu IH, Chen RJ, Huang SC, Lin FY, Wang SS: Analysis and results of prolonged resuscitation in cardiac arrest patients rescued by extracorporeal membrane oxygenation. *J Am Coll Cardiol* 2003; 41:197–203
6. Holzer M, Sterz F, Schoerhuber W, Behringer W, Domanovits H, Weinmar D, Weinstabl C, Stimpfl T: Successful resuscitation of a verapamil-intoxicated patient with percutaneous cardiopulmonary bypass. *Crit Care Med* 1999; 27: 2818–23
7. Hill JG, Bruhn PS, Cohen SE, Gallagher MW, Manart F, Moore CA, Seifert PE, Askari P, Banchieri C: Emergent applications of cardiopulmonary support: A multiinstitutional experience. *Ann Thorac Surg* 1992; 54:699–704
8. Korusz M, Zwischenberger JB: Percutaneous cardiopulmonary bypass for cardiac emergencies. *Perfusion* 2002; 17:269–77
9. Wittenmyer BL, Pomerantz BJ, Duff SB, Watson WD, Blackford JM: Single hospital experience with emergency cardiopulmonary bypass using the portable CPS (Bard) system. *J Extracorp Technol* 1997; 29:73–7
10. Mooney MR, Arom KV, Joyce LD, Mooney JF, Goldenberg IF, Von Rueden TJ, Emery RW: Emergency cardiopulmonary bypass support in patients with cardiac arrest. *J Thorac Cardiovasc Surg* 1991; 101:450–4
11. Ullrich R, Kneifel W, Fuchs M, Hodl W, Zimpfer M, Germann P: Portable cardiopulmonary support (ECPs) in the emergency room. *Anaesthesia* 1998; 53(suppl 2):6–8
12. Paradis NA, Martin GB, Rivers EP, Goetting MG, Appleton TJ, Feingold M, Nowak RM: Coronary perfusion pressure and the return of spontaneous circulation in human cardiopulmonary resuscitation. *JAMA* 1990; 263:1106–13

## Neuropathy following Axillary Brachial Plexus Block: Is It the Tourniquet?

Christopher J. Jankowski, M.D.,\* Mark T. Keegan, M.B., M.R.C.P.I.,\* Charles F. Bolton, M.D.,†  
Barry A. Harrison, M.B.B.S., F.A.N.Z.C.A., F.R.A.C.P.‡

AXILLARY brachial plexus block is an accepted and effective means of providing anesthesia for outpatient upper extremity procedures.<sup>1</sup> The incidence of nerve injury after axillary blockade is between 0.2% and 19%, however.<sup>2</sup> The mechanism of injury is unknown, but case series imply an association with identification of the cords of the brachial plexus by needle-seeking paresthesiae.<sup>3,4</sup> We describe a case of postoperative neuropathy affecting the upper limb, which was initially attributed to axillary blockade but, in fact, was caused by ischemic monomelic neuropathy (IMN) secondary to the use of a pneumatic tourniquet.

### Case Report

A 63-yr-old woman, American Society of Anesthesiology (ASA) physical class II, presented for open reduction and internal fixation of comminuted and displaced spiral fractures of her left third and fourth metacarpals. Relevant medical history included essential hypertension, which was controlled on hydrochlorothiazide. Bilateral carpal tunnel syndrome had been diagnosed clinically and confirmed by nerve conduction studies 17 yr before presentation. Her symptoms had resolved without surgery. The physical examination was, apart from the fractures, unremarkable. Her blood pressure was 130/60 mmHg, and her heart rate was 74 beats/min in sinus rhythm.

After intravenous administration of 1 mg midazolam and 50 µg fentanyl, an axillary brachial plexus block was performed *via* the elicitation of paresthesia technique using a 25-gauge, 2-in needle. Ulnar nerve paresthesia was obtained on the first pass, and 35 ml 1.25% mepivacaine and 1:200,000 epinephrine mixture was deposited. On the second pass, radial paresthesia was obtained and 15 ml was deposited. An additional 10 ml local anesthetic was deposited anterior to the axillary artery. A total of 60 ml 1.25% mepivacaine with 1:200,000 epinephrine was deposited into the brachial plexus sheath. There was no pain during injection of the local anesthetic. The intercostobrachial and musculocutaneous nerves were blocked *via* subcutaneous injection of 3 ml and 7 ml 2% lidocaine at the axilla and antecubital fossa, respectively.

The patient's left arm was abducted at no more than 90° to the torso and positioned level on an arm table. A tourniquet (Zimmer ATS 2000;

Zimmer, Dover, OH) was applied to the midpoint of the left upper arm and inflated to 300 mmHg. The block was satisfactory for the procedure in that neither supplemental nerve block, excessive sedation, nor general anesthesia was required. The patient underwent open reduction and internal fixation of the fractures. After 59 min, the tourniquet was deflated and a loose bulky dressing was applied. With the block still intact, the patient was dismissed to the outpatient area and, subsequently, home.

On the following day, surgical evaluation noted that there was "persistence of total ulnar paresthesias... now almost 24 h after the block." These symptoms persisted after the dressing was loosened. Three weeks later, the patient had "ulnar aching and dysesthesias up the forearm, and occasional shocks and discomfort on abduction of the arm." Surgical opinion was that the neurologic deficit was not caused by operative trauma but by injury resulting from the axillary block.

Three weeks after surgery, a neurologic consultation was obtained; examination revealed decreased hypothenar and interossei strength, decreased ulnar digit flexion, and decreased light touch and pinprick sensation on the left. At the time of the consultation, nerve conduction and electromyographic studies were obtained (Tables 1 and 2). Nerves were stimulated at the elbow and wrist, and responses were recorded in the hand. The amplitudes of the left ulnar and radial sensory and median motor responses were reduced. Motor and sensory distal latencies, conduction velocities, and F-wave latency were normal. Needle electrode examination of the muscles on the left demonstrated fibrillation potentials in all muscles sampled below the elbow and in the biceps above the elbow, consistent with a polyneuropathy. Voluntary motor unit potentials were normal throughout. The results indicated partial axonal degeneration of the ulnar, median, radial, and musculocutaneous nerves below the level of the tourniquet in the midupper arm. (There was also evidence of a mild bilateral median neuropathy at the wrists, consistent with her previous nerve conduction studies.) By 6 months, her symptoms had completely resolved.

### Discussion

The tourniquet is used in peripheral limb surgery to produce a bloodless surgical field. Post-tourniquet nerve palsy or "tourniquet paralysis" is well documented, and the incidence of tourniquet paralysis has been reported as 1 in 8,000 operations.<sup>5</sup> Recommendations for appropriate use of the tourniquet include the maintenance of a pressure no more than 150 mmHg greater than the systolic blood pressure and deflation of the tourniquet every 90-120 min.<sup>6</sup> Even the modern-day tourniquet used according to these recommendations may result in tourniquet paralysis, however.<sup>7</sup> A recent prospective observational study of upper and lower limb blockade using a nerve stimulator and the multiple injection technique demonstrated that higher tourniquet inflation pressure (> 400 mmHg) was associated with an increased risk of transient nerve injury.<sup>8</sup> Prolonged tourniquet time is also associated with an increased incidence

\* Assistant Professor, Department of Anesthesiology, † Professor, Department of Neurology, Mayo Clinic, Rochester. ‡ Assistant Professor, Department of Anesthesiology, Mayo Clinic, Jacksonville.

Received from the Departments of Anesthesiology and Neurology, Mayo Clinic, Rochester, Minnesota; and the Department of Anesthesiology, Mayo Clinic, Jacksonville, Florida. Submitted for publication November 1, 2002. Accepted for publication June 16, 2003. Supported by a grant from the Foundation for Anesthesia Education and Research and the Mayo Clinic and Foundation, Rochester, Minnesota (to Drs. Bolton, Harrison, and Keegan), and by the Mayo Clinic and Foundation, Jacksonville, Florida (to Dr. Harrison).

Address reprint requests to Dr. Jankowski: Department of Anesthesiology, Charlton 1-145, Mayo Clinic, Rochester, Minnesota 55905. Address electronic mail to: jankowski.christopher@mayo.edu. Individual article reprints may be purchased through the Journal Web site, www.anesthesiology.org.



**Table 1. Nerve Conduction Studies**

Nerve	Amplitude (mV and $\mu$ V)			Velocity (m/s)			Distal Latency (ms)			F-Wave Latency (ms)		
	Right	Left	Normal	Right	Left	Normal	Right	Left	Normal	Right	Left	Normal
Median, motor	7.8	5.9	>4.0	51	55	>48	5.4	4.0	<4.5	27.5	25.2	<32
Median, sensory	24	28	>15		58	>56	4.5	3.3	<3.6			
Radial, sensory	51	36	>20			>49	2.3	2.2	<2.9			
Ulnar, motor	8.3	5.1	>6.0	61	58	>51	2.7	2.6	<3.6		23.9	<32
Ulnar, sensory	53	24	>10	59	57	>54	2.7	2.5	<3.1			

The findings of the nerve conduction studies should be compared with the reference values and the results from the contralateral side.

of neuropathy.<sup>2</sup> Although underreported in the anesthesia literature, there have been case reports of upper extremity tourniquet paralysis. In 1992, Hidou *et al.*<sup>9</sup> described an ASA physical class I patient undergoing axillary brachial plexus block for hand surgery. The tourniquet remained at 300 mmHg for 45 min, and, after surgery, electrophysiologic testing demonstrated a severe conduction block of sensory and motor fibers localized to the lower margin of the tourniquet.

Bolton *et al.*<sup>10</sup> published the first well-documented report of multiple limb neuropathies as a result of ischemia, a complication of arteriovenous shunt placement in uremic patients. Similar reports appeared subsequently.<sup>11,12</sup> Wilbourn *et al.*<sup>13</sup> described IMN after intra-aortic balloon insertion, after cannulation for cardiopulmonary bypass, and in thromboembolism in patients with an atheromatous aorta as well as a result of the placement of arteriovenous shunts. They attributed the ischemia associated with IMN to arterial occlusion or low flow states. Bolton *et al.*<sup>10</sup> and Wilbourn *et al.*<sup>13</sup> noted a predominance of sensory symptoms and pain over physical signs. Our patient's presentation was consistent with this.

Electrophysiologic findings of IMN include axon-loss lesions of motor and sensory nerves supplying the distal

portion of the limbs. In addition, there is evidence of denervation, distal greater than proximal. Nerve conduction studies reveal motor and sensory responses that are low in amplitude or unobtainable. Sensory fibers are more affected than motor fibers, and the decrease in amplitude is more pronounced distally. Latencies and conduction velocities are normal.<sup>14</sup> Our patient's electrophysiologic study was consistent with these findings. In tourniquet paralysis, besides the axonal neuropathy changes seen in IMN, there are electrophysiologic changes of conduction block, which may predominate. Thus, electrophysiologic studies will determine the degree of demyelination *versus* axonal degeneration. This has clinical significance, because lesions that are predominantly demyelinating in nature result in early recovery, whereas those caused by axonal degeneration are associated with delayed recovery. Autonomic changes consistent with causalgia may also occur.<sup>15</sup> A component of our patient's symptoms may have been attributable to autonomic dysfunction.

The connection or overlap between the entity of tourniquet paralysis and the syndrome of IMN is not well documented. Generally, tourniquet paralysis is thought to be the result of direct compressive injury of the nerve. Experimentally, local nerve compression from a pneumatic tourniquet displaced the nodes of Ranvier 200  $\mu$ m away from the site of compression, caused an intussusception of paranodal myelin and axon into the myelin sheath, and resulted in demyelination in the area of intussusception.<sup>16</sup> The investigators concluded that these changes were caused by direct mechanical compression. Ischemia, however, may play a role in tourniquet paralysis. Wilbourn *et al.*<sup>13</sup> hypothesized that the peripheral nerve was relatively more sensitive to ischemia than muscle or skin. Even low tourniquet inflation pressures produce nerve injury and abnormal microvascular permeability.<sup>17</sup> Neural microvascular permeability has also been demonstrated after tourniquet inflation pressures of 50–200 mmHg, especially at the edge of the compression.<sup>18</sup> Thus, there is experimental evidence to suggest both ischemic and compressive mechanisms in post-tourniquet paralysis.

Nerve injury is a significant issue for anesthesiologists. It accounts for 16% of the claims filed in the ASA Closed Claims Study database.<sup>19</sup> Of these, ulnar and brachial

**Table 2. Electromyographic Studies**

Muscle	Insertional Activity	Fibrillation Potentials	Voluntary Motor Unit Potentials
R, first dorsal interosseous	Normal	0	Normal
R, flexor carpi radialis	Normal	0	Normal
L, abductor digiti minimi	Increased	+++	
L, biceps brachii	Increased	++	
L, brachioradialis	Increased	++	
L, deltoid	Normal	0	Normal
L, extensor indicis proprius	Increased	++	
L, first dorsal interosseous	Increased	++	
L, flexor carpi radialis	Increased	+++	
L, flexor pollicis longus	Increased	+++	
L, infraspinatus	Normal	0	Normal
L, latissimus dorsi	Normal	0	Normal
L, pronator teres	Increased	+++	
L, triceps	Normal	0	Normal

Note the normal voluntary motor unit potentials and the distal left fibrillation potentials and increased insertional activity.

L = left; R = right.

plexus injuries account for 28% and 20%, respectively. Caplan<sup>20</sup> notes that only 9% of medicolegal cases of perioperative neuropathy have a recognizable cause despite extensive investigation. In a retrospective study of patients at high risk for neuropathy undergoing upper extremity surgery under axillary block, Horlocker *et al.*<sup>2</sup> determined that 11.3% of nerve injuries were anesthesia related and 88.7% were surgery related. Only clinical criteria (*i.e.*, level and distribution of the neuropathy) were used to differentiate anesthesia-related nerve injury from surgery-related nerve injury, however.

Mechanical pressure on nerve tissue has long been recognized in the pathogenesis of tourniquet paralysis. Our report illustrates that interruption of the blood supply, as occurs in IMN, may also play a role. When presented with neuropathy after upper limb surgery under axillary brachial plexus block, the anesthesiologist needs to consider all risk factors, including the tourniquet, in the differential diagnosis of the neuropathy. Importantly, electrophysiology studies, as illustrated in our case report, will determine the site and mechanism of the injury as well as the prognosis for recovery.

## References

1. Davis WJ, Lennon RL, Wedel DJ: Brachial plexus anesthesia for outpatient surgical procedures on an upper extremity. *Mayo Clin Proc* 1991; 66:470-3
2. Horlocker TT, Kufner RP, Bishop AT, Maxson PM, Schroeder DR: The risk of persistent paresthesia is not increased with repeated axillary block. *Anesth Analg* 1999; 88:382-7
3. Selander D, Dhuner KG, Lundborg G: Peripheral nerve injury due to injection needles used for regional anesthesia: An experimental study of the acute effects of needle point trauma. *Acta Anaesthesiol Scand* 1977; 21:182-8
4. Selander D: Peripheral nerve injury caused by injection needles. *Br J Anaesth* 1993; 71:323-5
5. Middleton RW, Varian JP: Tourniquet paralysis. *Aust NZ J Surg* 1974; 44:124-8
6. Sharrock NE, Savarese JJ: Anesthesia for orthopedic surgery. *Anesthesia*, 5th edition. Edited by Miller RD, Cucchiara RF, Miller ED, Reves JG, Roizen MF, Savarese JJ. Philadelphia, Churchill Livingstone, 2000, pp 2118-39
7. Love BR: The tourniquet. *Aust NZ J Surg* 1978; 48:66-70
8. Fanelli G, Casati A, Garancini P, Torri G: Nerve stimulator and multiple injection technique for upper and lower limb blockade: Failure rate, patient acceptance, and neurologic complications. *Study Group on Regional Anesthesia. Anesth Analg* 1999; 88:847-52
9. Hidou M, Huraux C, Viry-Babel F, Laxenaire MC: Pneumatic tourniquet paralysis: A differential diagnosis after loco-regional anesthesia of the upper limb. *J Chir (Paris)* 1992; 129:213-4
10. Bolton CF, Driedger AA, Lindsay RM: Ischaemic neuropathy in uraemic patients caused by bovine arteriovenous shunt. *J Neurol Neurosurg Psychiatry* 1979; 42:810-4
11. Riggs JE, Moss AH, Labosky DA, Liput JH, Morgan JJ, Gutmann L: Upper extremity ischemic monomelic neuropathy: A complication of vascular access procedures in uremic diabetic patients. *Neurology* 1989; 39:997-8
12. Kaku DA, Malamut RI, Frey DJ, Parry GJ: Conduction block as an early sign of reversible injury in ischemic monomelic neuropathy. *Neurology* 1993; 43:1126-30
13. Wilbourn AJ, Furlan AJ, Hulley W, Ruschhaupt W: Ischemic monomelic neuropathy. *Neurology* 1983; 33:447-51
14. Rudge P, Ochoa J, Gilliatt RW: Acute peripheral nerve compression in the baboon. *J Neurol Sci* 1974; 23:403-20
15. Bolton CF, McFarlane RM: Human pneumatic tourniquet paralysis. *Neurology* 1978; 28:787-93
16. Ochoa J, Fowler TJ, Gilliatt RW: Anatomical changes in peripheral nerves compressed by a pneumatic tourniquet. *J Anat* 1972; 113:433-55
17. Pedowitz RA: Tourniquet-induced neuromuscular injury: A recent review of rabbit and clinical experiments. *Acta Orthop Scand Suppl* 1991; 245:1-33
18. Rydevik B, Brown MD, Lundborg G: Pathoanatomy and pathophysiology of nerve root compression. *Spine* 1984; 9:7-15
19. Cheney FW, Domino KB, Caplan RA, Posner KL: Nerve injury associated with anesthesia: A closed claims analysis. *ANESTHESIOLOGY* 1999; 90:1062-9
20. Caplan RA: Will we ever understand perioperative neuropathy? A fresh approach offers hope and insight (editorial). *ANESTHESIOLOGY* 1999; 91:335-6