

Mean Arterial Pressure and Intracranial Pressure

To the Editor:—We read with great interest the article by Petersen *et al.*, which demonstrated the expected clinical response to the three anesthetic agents studied.^{1,2} An increase in arterial pressure may result in an increase in the cerebral perfusion pressure and reduce reflex cerebral vasodilatation, potentially resulting in reduced intracranial pressure. We note that the mean arterial pressures in the propofol group were substantially higher than in the two inhalation groups, both before and after hyperventilation. The propofol group was shown to have both a lower measured intracranial pressure and subjective surgical estimation of brain swelling at craniotomy. The influence of the potentially higher perfusion pressure on these findings in this group cannot be estimated from the study. Was this relationship between mean arterial pressure and intracranial pressure examined by the authors, and if so, could they comment on its possible significance?

Anesthesiology 2003; 99:1028

In Reply:—Thank you for your interest in our study on intracranial pressure and cerebral hemodynamic in patients with cerebral tumors. We performed an analysis of the relationship between mean arterial blood pressure and intracranial pressure (ICP) both before and during hyperventilation but found no significant correlation. The correlation coefficients, however, was negative in the propofol/fentanyl group but positive in the isoflurane/fentanyl and sevoflurane/fentanyl groups. These differences might be caused by difference in autoregulatory capacity between propofol/fentanyl and the other two groups, suggesting that cerebral autoregulation was better preserved in the propofol/fentanyl group compared with isoflurane/fentanyl and sevoflurane/fentanyl anesthetized patients, but this does not explain that ICP was significantly lower during propofol/fentanyl anesthesia. On the con-

Anesthesiology 2003; 99:1028-9

To the Editor:—We read with interest the two cases of retroperitoneal hematoma following lumbar plexus block reported by Weller *et al.*¹ These cases and the authors' conclusions prompt a number of comments. In the first case, it is clear that the introduction of the catheter was associated with significant vascular trauma, because "blood could be steadily aspirated." Those who perform continuous lumbar plexus blocks on a regular basis are certainly familiar with this complication. Although there is little doubt that the administration of enoxaparin contributed to the development of the observed retroperitoneal hematoma, it is surprising that the authors did not consider the initial vascular trauma as a major risk factor, and furthermore, that they did not at that time abort the placement of the perineural catheter. As far as the second case is concerned, the authors describe a patient who had been grossly overdosed on heparin therapy (activated partial thromboplastin time > 100) and had developed a "moderate-sized retroperitoneal hematoma." Although the authors acknowledge that spontaneous retroperitoneal bleeds are possible in anticoagulated pa-

Robert A. Fry, M.B., Ch.B.* Nigel N. Robertson, M.B., Ch.B.
*Auckland Hospital, Auckland New Zealand. robf@adhb.govt

References

1. Petersen KD, Landsfeldt U, Cold GE, Petersen CB, Mau S, Hauerberg KS: Intracranial pressure and cerebral hemodynamic in patients with cerebral tumors. *ANESTHESIOLOGY* 2003; 98:329-36
2. Holzer A, Winter W, Greher M, Reddy M, Stark J, Donner A, Zimpfer M, Illievich: UMA comparison of propofol and sevoflurane anaesthesia: Effects on aortic blood flow velocity and middle cerebral artery blood flow velocity. *Anaesthesia* 2003; 58:217-22

(Accepted for publication May 21, 2003.)

© 2003 American Society of Anesthesiologists, Inc. Lippincott Williams & Wilkins, Inc.

trary, one would expect a low ICP in the isoflurane and sevoflurane groups, because the mean arterial blood pressures were significantly lower. We also analyzed the correlation coefficients for the relationship between cerebral perfusion pressure and ICP. In all groups, the correlation coefficients were negative but insignificant. The negative correlations were not surprising, considering that cerebral perfusion pressure was calculated as the difference between mean arterial blood pressure and ICP. Because cerebral perfusion pressure and ICP are not independent variables, we did not include these data in the results.

Georg Emil Cold, M.D. Aarhus University Hospital, Århus, Denmark. gcold@akh.aaa.dk.

(Accepted for publication May 21, 2003.)

© 2003 American Society of Anesthesiologists, Inc. Lippincott Williams & Wilkins, Inc.

What Has Happened to Evidence-based Medicine?

tients, it is the introduction of a 21-gauge needle 3 days earlier that is primarily incriminated in the etiology of the hematoma.

What is particularly unfortunate is that, on the basis of these two cases, the authors go on to recommend that we apply the same guidelines for continuous lumbar plexus blocks as those proposed for neuraxial blocks, thus insinuating that performing lumbar plexus blocks in patients scheduled to be anticoagulated might be considered malpractice. Although no quantitative information is available, our group performs many of these blocks; to date, none of us has any recollection of the development of a retroperitoneal hematoma in any of our patients. We acknowledge that a perineural or retroperitoneal hematoma is a potential and rare complication, but it is also important to remember that the guidelines for neuraxial blocks in the presence of thromboprophylactic therapy were developed because a large number of patients (> 50 and, to date, probably around 80 patients) developed epidural hematoma while receiving therapeutic doses of low molecular weight heparin. The majority of those patients suffered serious neuro-

logic injury.² Of note, neither of the two patients reported by Weller *et al.* suffered neurologic injury, despite one being massively overdosed with intravenous heparin.

To conclude, there is no doubt that caution should be exercised when placing a perineural catheter, especially a lumbar plexus catheter. In any patient for whom one has evidence of significant bleeding at the time of insertion of a perineural lumbar plexus catheter, we recommend removal of the catheter at the time of insertion and the use of an alternative approach. This practice seems more measured and reasonable than offering the radical suggestion that continuous lumbar plexus block should be banned in patients receiving anticoagulant postoperatively.

Anesthesiology 2003; 99:1029

In Reply:—We appreciate the opportunity to respond to Dr. Chelly and his expert coauthors to correct an apparent misinterpretation of our discussion of retroperitoneal hematoma following posterior lumbar plexus blockade (LPB). Most important, we would like the readers of ANESTHESIOLOGY to understand that our intent was to notify clinicians of the serious complication we observed, rather than to promulgate guidelines for clinical practice. Because the use of perineural catheters and lower extremity nerve block has increased substantially in recent years,¹ we believe it is critical that complications of newer techniques are reported so that clinicians use appropriate caution as they introduce techniques novel to their practice. Because there are no data on the frequency of this complication, we believe no individual should suggest practice guidelines for others. To suggest we “insinuated malpractice” is ludicrous. We believe we were quite cautious in our discussion to emphasize that anesthesiologists must weigh the risks of concealed bleeding from deep blocks and anticoagulation with the benefits of this (and any) regional anesthetic technique. As proponents of regional anesthesia with considerable experience with continuous LBP, we simply stated how we are managing such patients at our own institution. Ultimately, experts may be able to develop a consensus statement with respect to peripheral nerve block and anticoagulation, but there are insufficient data at this time for any such statement.

We would also like to respond to Chelly *et al.*'s interpretation of the details of these two cases. We certainly considered the apparent vascular trauma in the first case a contributing factor in the complication. Repositioning of the catheter and a negative test dose suggested to us that we could provide satisfactory analgesia with the block and catheter already in place. We believe this is no different from similar practice with epidural anesthesia in which blood is initially aspirated, but the catheter is then readjusted or replaced and then used for anesthesia. Despite the authors' reference to “evidence-based medicine,” they provide none for their recommendation that we should have “aborted” the procedure with the LPB catheter already in place. In this case report, we believe the important issue was the removal of the catheter within 2 h of an enoxaparin dose. We believe this timing (as well as the known vascular trauma) contributed to the complication. In the second case, it is true that anticoagulation was excessive, but it is also important to acknowledge that unintentional excessive anticoagulation sometimes occurs in clinical medicine. The authors seem to imply that this patient's retroperitoneal hemorrhage was spontaneous (*i.e.*, due to anticoagulation without relation to the LPB.) This denies the fact that the computed tomographic scan pinpointed the location of the hematoma to the site of needle placement. Once again, needle trauma

Jacques E. Chelly, M.D., Ph.D., M.B.A.,* Jennifer R. Greger, M.D., Andrea Casati, M.D., Ralf Gebhard, M.D., Bruce Ben-David, M.D. *University of Pittsburgh School of Medicine, Pittsburgh, Pennsylvania. chelje@anes.upmc.edu

References

1. Weller RS, Gerancher JC, Crews JC, Wade KL: Extensive retroperitoneal hematoma without neurologic deficit in two patients who underwent lumbar plexus block and were later anticoagulated. ANESTHESIOLOGY 2003; 98:581-5
2. Horlocker TT, Wedel DJ: Anticoagulation and neuraxial block: Historical perspective, anesthetic implications, and risk management. Reg Anesth Pain Med 1998; 23:129-34

(Accepted for publication May 21, 2003.)

© 2003 American Society of Anesthesiologists, Inc. Lippincott Williams & Wilkins, Inc.

and anticoagulation (excessive in this case) both seemed to have contributed to the complication.

We feel compelled to respond to Chelly *et al.*'s characterization of retroperitoneal hematoma as “potential and rare.” Certainly, retroperitoneal hematoma has been reported less frequently following LPB than spinal hematoma has been reported following epidural blockade, but none would debate that the number of continuous epidural anesthetics nationwide is substantially higher than the number of continuous LPB. Retroperitoneal hematoma following LPB remains a complication with unknown incidence. Although we were fortunate that neither of our patients suffered neurologic injury,² we would like to reemphasize that retroperitoneal hematoma should be considered a significant complication—one that can result in major morbidity and death.³ In addition to retroperitoneal hematoma following LPB, Auroy *et al.*⁴ reported a rate of other serious complications following LPB that exceeds that of other peripheral nerve blocks. Finally, Chelly *et al.* may have collectively performed a large number of continuous LPBs, but they provide no evidence to support their “more measured” recommendation that the lumbar plexus approach should be aborted if “significant bleeding” occurs during placement. How is “significant bleeding” defined, and how is this recommendation any more measured than our current management? We stand by our conclusion that retroperitoneal hematoma following LPB is a serious complication whose incidence is unknown.

Robert Weller, M.D.,* J. C. Gerancher, M.D., James C. Crews, M.D., Kenneth L. Wade, M.D. Wake Forest University School of Medicine, Winston-Salem, North Carolina. rweller@wfubmc.edu

References

1. Horlocker TT: Peripheral nerve blocks: Regional anesthesia for the new millennium. Reg Anesth Pain Med 1998; 23:237-40
2. Klein SM, D'Ercole F, Greengrass RA, Warner DS: Enoxaparin associated with psoas hematoma and lumbar plexopathy after lumbar plexus block. ANESTHESIOLOGY 1997; 87:1576-9
3. Maier C, Gleim M, Weiss T, Stachetzki U, Nicolas V, Zenz M: Severe bleeding following lumbar sympathetic blockade in two patients under medication with irreversible platelet aggregation inhibitors. ANESTHESIOLOGY 2002; 97:740-3
4. Auroy Y, Benhamou D, Bargues L, Ecoffey C, Falissard B, Mercier FJ, Bouaziz H, Samii K, Mercier F: Major complications of regional anesthesia in France: The SOS Regional Anesthesia Hotline Service. ANESTHESIOLOGY 2002; 97:1274-80

(Accepted for publication May 21, 2003.)

Anesthesiology 2003; 99:1030

© 2003 American Society of Anesthesiologists, Inc. Lippincott Williams & Wilkins, Inc.

Use of Anesthesia-assisted Detoxification in the Opioid-dependent Pain Patient

To the Editor:—I read with interest the case report by Breitfeld *et al.*,¹ in which the use of clonidine to reduce symptoms of opioid withdrawal is mentioned. It should be pointed out that clonidine is a μ_2 -adrenoceptor agonist, not an antagonist as reported in this article.²

The effectiveness of this technique for detoxification from opioid addiction remains controversial. Within the actively using opioid-addicted individual, this technique has been used to “reset” the opioid receptors in persons who have lost their sensitivity to illicit opioids, thus allowing them to use again. This results in a dramatic loss in opioid tolerance, which, in the context of illicit drug use can lead to fatal overdoses. Currently, detoxification of individuals addicted to opioids by this method is experimental and without a clearly favorable cost-benefit ratio.³

Anesthesiology 2003; 99:1030

In Reply:—We appreciate Dr. Gourlay’s interest in our work.¹ Of course, we are aware that clonidine, while diminishing sympathetic neural outflow both in volunteers² and in opioid addicts,^{3,4} acts as an agonist on central α -receptors. We apologize for the typographical error that appears on page 571 of the original article.

We agree that antagonist supported detoxification from opioids during general anesthesia can restore opioid sensitivity. Accordingly, opioid receptor blockade, *e.g.*, by oral naltrexone, should be maintained in formerly addicted patients as long as possible to prevent both relapses as well as potentially fatal effects of further opioid intake. However, our patient experienced chronic pain with tolerance to the analgetic effects of administered opioids. Thus, antagonist supported detoxification was intended to restore opioid sensitivity, allowing continuation of analgesic therapy by administration of much lower opioid dosages while again achieving sufficient analgesia.

With respect to cost-benefit ratios, we expect by this procedure high rates of successful detoxification with markedly shortened hospitalization.^{5,6} Accordingly, this procedure seems to be economically attractive. However, a decrease in the number of relapses may not be expected, although little data are currently available.

Christa Breitfeld M.D.,* Matthias Eikermann, M.D., Peter Kienbaum M.D., and Jürgen Peters, M.D. *Klinik für Anästhesiologie und Intensivmedizin, Universitätsklinikum Essen, Essen, Germany. christa.breitfeld@uni-essen.de

Douglas Gourlay, M.D., F.R.C.P.C. University of Toronto, Wasser Pain Management Centre, Mount Sinai Hospital, Toronto, Ontario. doug_gourlay@camh.net

References

1. Breitfeld C, Eikermann M, Kienbaum P, Peters J: Opioid “holiday” following antagonist supported detoxification during general anesthesia improves opioid agonist response in a cancer patient with opioid addiction. *ANESTHESIOLOGY* 2003; 98:571–3
2. Kienbaum P, Heuter T, Michel MC, Scherbaum N, Gastpar M, Peters J: Sympathetic neural activation evoked by mu-receptor blockade in patients addicted to opioids is abolished by intravenous clonidine. *ANESTHESIOLOGY* 2002; 96:346–51
3. Gowing L, Ali R, White J: Opioid antagonists under heavy sedation or anaesthesia for opioid withdrawal [systematic review]. *Cochrane Drugs and Alcohol Group Cochrane Database of Systematic Reviews* 2002, issue 4

(Accepted for publication May 22, 2003.)

© 2003 American Society of Anesthesiologists, Inc. Lippincott Williams & Wilkins, Inc.

References

1. Breitfeld C, Eikermann M, Kienbaum P, Peters J: Opioid “holiday” following antagonist supported detoxification under general anesthesia improves opioid agonist response in a cancer patient with opioid addiction. *ANESTHESIOLOGY* 2003; 98:571–3
2. Muzi M, Goff DR, Kampine JP, Roerig DL, Ebert TJ: Clonidine reduces sympathetic activity but maintains baroreflex responses in normotensive humans. *ANESTHESIOLOGY* 1992; 77:864–71
3. Kienbaum P, Heuter T, Michel MC, Scherbaum N, Gastpar M, Peters J: Chronic mu-opioid receptor stimulation in humans decreases muscle sympathetic nerve activity. *Circulation* 2001; 103:850–5
4. Kienbaum P, Heuter T, Michel MC, Scherbaum N, Gastpar M, Peters J: Sympathetic neural activation evoked by mu-receptor blockade in patients addicted to opioids is abolished by intravenous clonidine. *ANESTHESIOLOGY* 2002; 96:346–51
5. Scherbaum N, Klein S, Kaube H, Kienbaum P, Peters J, Gastpar M.: Alternative strategies of opiate detoxification: evaluation of the so-called ultra-rapid detoxification. *Pharmacopsychiatry* 1998; 31:205–9
6. Kienbaum P, Scherbaum N, Thuerauf N, Michel MC, Gastpar M, Peters J: Acute detoxification of opioid-addicted patients with naloxone during propofol or methohexital anesthesia: A comparison of withdrawal symptoms, neuroendocrine, metabolic, and cardiovascular patterns. *Crit Care Med* 2000; 28:969–76

(Accepted for publication May 22, 2003.)

Anesthesiology 2003; 99:1031

© 2003 American Society of Anesthesiologists, Inc. Lippincott Williams & Wilkins, Inc.

Halloween

To the Editor:—Recently, some propofol was spilled on the floor (fig. 1) and—*Halloween!* I assure you that this white solution *is* propofol and that no actions were taken by staff to make it look like this. It just happened.

Alexander Avidan, M.D. Hebrew University Hadassah Medical

School, Hadassah University Hospital, Jerusalem, Israel.
avidan3@netvision.net.il

(Accepted for publication July 2, 2003.)

Support was provided solely from institutional and/or departmental sources.



Fig. 1. A propofol poltergeist?

Anesthesiology 2003; 99:1032

© 2003 American Society of Anesthesiologists, Inc. Lippincott Williams & Wilkins, Inc.

Perioral Stains after *Ortho*-Phthalaldehyde Disinfection of Echo Probes

To the Editor:—Our transesophageal echo probes started to leave tenacious gray-green stains on the mouths of our cardiac surgery patients. The problem began when we were required to change our probe-disinfecting procedures. We had been using glutaraldehyde, which did not stain the probes (Philips Omniplane models I and II, Philips Medical Systems, Andover, MA). Unfortunately, glutaraldehyde is volatile, and its fumes were polluting the air of our probe-cleaning workroom. Therefore, we adopted less-volatile *ortho*-phthalaldehyde (OPA) as a disinfecting agent. Ugly OPA-derived oral stains were forthcoming and were not reliably prevented by copious rinsing of the probes with water (four times, 2 l). Staining is prominent when, as is common in cardiac anesthesia, an OPA-treated probe (but not a glutaraldehyde-treated probe) remains in prolonged contact with a patient on whom an endotracheal tube is secured with cloth adhesive tape. The stain first appears on the tape (both the Kendall Curity, Mansfield, MA, and 3M Health Care, St. Paul, MN, products) and can be transferred to the lip through routine manipulation of the probe. The lip stain is initially difficult to scrub away, but it does fade in a few hours with no apparent sequelae.

OPA is well-known to form deeply colored dyes with other molecules.¹ Prolonged exposure to saliva and tape elicit visibly detectable dye from minute traces of OPA residues remaining on copiously water-rinsed echo probes. Although water rinsing does not reliably remove

chromogenic residues from the probes, no stains are elicited from OPA-treated probes that are gently wiped clean with 3% hydrogen peroxide solution after the OPA protocol.

Guidelines from one echo probe manufacturer mention that staining may occur if the standard OPA protocol is not performed "meticulously." Rather than breaching protocol, we have encountered especially favorable chromogenic conditions that unmask otherwise invisible trace residues.

It is theoretically troubling to discover that traces of OPA residue can cling to echo probes and then be transferred to patients. We have not established the identity of the staining material, nor have we determined what happens when it is inactivated by peroxide. The peroxide may remove the residues or it may merely render them nonchromogenic. We note that, like OPA, peroxide is federally approved for disinfecting endoscopy equipment. However, the common 3% solution is too dilute to be relied on for high-level disinfection.

Scott C. Streckenbach, M.D. Theodore A. Alston, M.D., Ph.D.*
*Massachusetts General Hospital, Harvard Medical School, Boston, Massachusetts. talston@partners.org

Reference

1. Venza M, Visalli M, Cicciu D, Teti D: Determination of polyamines in human saliva by high-performance liquid chromatography with fluorescence detection. *J Chromatogr B Biomed Sci Appl* 2001; 757:111-7

(Accepted for publication May 28, 2003.)

Support was provided solely from institutional and/or departmental sources.

Anesthesiology 2003; 99:1032-3

© 2003 American Society of Anesthesiologists, Inc. Lippincott Williams & Wilkins, Inc.

Interference Masquerading as Atrial Extrasystole

To the Editor:—We would like to report a source of potential electrocardiograph interference that may occur under anesthesia for laser treatment of capillary vascular malformation in children. During pulsed dye laser therapy (Scleroplus SPT-1 day; Candela, Wayland, MA) to a capillary vascular malformation that extended onto the chest, the electrocardiograph trace shown in Figure 1 was recorded. The initial diagnosis was atrial extrasystole, but there was no disturbance in the patients' radial pulse or pulse-oximetry waveform. It became apparent that each of the extra pulses on the electrocardiograph coincided with the laser being fired. The electrocardiograph was a modern Datex AS3 (Datex-Ohmeda Division, Instrumentarium Corp., Helsinki, Finland).

A relatively new development in medical laser technology is the inclusion of a dynamic cooling device as part of the laser handpiece. The cooling device is activated by the same trigger as the laser and fires a

jet of cryogen gas onto the skin before each laser pulse. This minimizes thermal injury to the epidermis and enables the patient to receive higher therapeutic laser exposure per theater session, reducing the total number of visits required. The cooling device has an actuator, which emits an electromagnetic pulse each time the laser is fired. The actuator is activated by the firing trigger either in the handset or the foot pedal.

Because it is possible to fire the laser and the cooling piece separately from each other, we have been able to prove that the cooling device alone is responsible for the electrocardiograph interference. We have also reduced the level of interference experimentally by shielding the handset in a μ -metal box, although this is practically cumbersome. The amplitude of electrocardiograph interference is inversely proportional to the distance between an electrocardiograph electrode and the dynamic cooling device. Candela indicates that all handpieces in their manufactured lasers that use the dynamic cooling device could exhibit this characteristic to varying degrees (personal written communication between author (G.T.B.) and C. Johnson, Director of Engineering, Candela Corporation, Wayland, MA, March 2003). Our advice is to be

Support was provided solely from institutional and/or departmental resources.

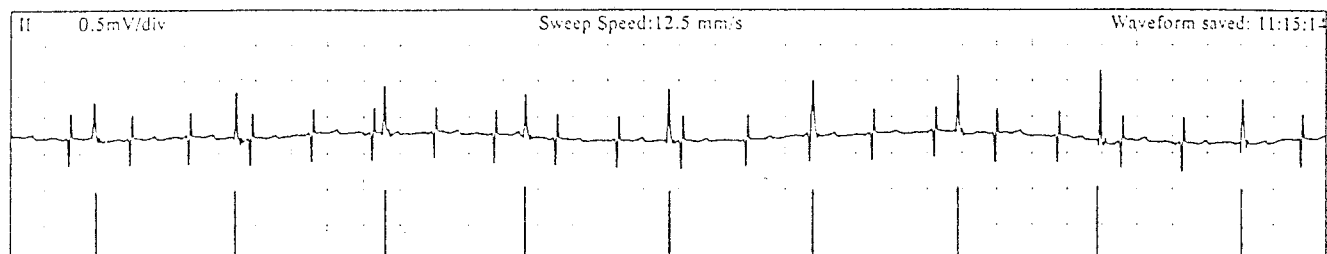


Fig. 1. Vertical black lines along baseline of electrocardiograph strip indicate when the laser and dynamic cooling device were fired.

aware of the possibility of electrocardiograph interference, perhaps with appropriate "caution" labels on the handset. Positioning electrocardiograph electrodes further away from the area requiring laser therapy will minimize interference; however, this must be balanced against the potential of reduced electrocardiograph signs of ischemia, and clinicians must consider these relative risks in any individual patient.

Graham T Bell, F.R.C.A.,* Michael Bradnam, Ph.D., Iain McKay, F.R.C.S. *Royal Hospital for Sick Children, Glasgow, United Kingdom. graham.bell@yorkhill.scot.nhs.uk

(Accepted for publication June 9, 2003.)

Anesthesiology 2003; 99:1033-4

© 2003 American Society of Anesthesiologists, Inc. Lippincott Williams & Wilkins, Inc.

Left Recurrent Laryngeal Nerve Paralysis after Interpleural Analgesia

To the Editor:—In patients with multiple rib fractures, interpleural analgesia has proved efficacious for improving the airway hygiene and reducing the need for ventilator support.¹ Despite the ease and safety with the procedure, complications such as pneumothorax,² pleural effusion,³ Horner syndrome,⁴ phrenic nerve paralysis,⁵ and unilateral bronchospasm⁶ are occasionally reported. We report a case with intermittent hoarseness due to recurrent laryngeal nerve block following each injection.

A 39-yr-old man sustained a left lung contusion and fracture of left ribs two through six after a motorcycle accident. Examination showed patient tachypneic with respiration rate of 30/min. The patient complained of severe pain on respiration, changing position, and breath holding. No paradoxical chest wall motion was observed. Radiologic findings showed, in addition to the fractures, mild parenchymal contusion and hemothorax of the left lung (fig. 1A).

Despite the use of intramuscular pethidine and external bandaging, the pain was so severe that the patient became dyspneic and hypoxemic (oxygen saturation measured by pulse oximetry: 82–85%). An interpleural block was performed. The patient was placed horizontally with the left side up. The point for injection was 5 cm medial to posterior midaxillary line, *i.e.*, 6 cm from the midline. The skin was infiltrated with lidocaine over the upper margin of the fifth rib. A 16-gauge Tuohy needle (Portex Ltd., Hythe, United Kingdom) with the bevel directed cephalad was introduced, and entry into the pleural space was identified by the "loss of resistance" technique. An epidural catheter was advanced 15 cm into the interpleural space. On aspiration, about 3 ml of bloody fluid was aspirated. We then withdrew the catheter 3 cm until no more blood was aspirated. A test dose of 1:200000 epinephrine in 3 ml of normal saline was given *via* the catheter. Because no tachycardiac response was noted within 5 min, a bolus dose of 20 ml 0.5% bupivacaine with 1:200000 epinephrine was injected. The patient remained in a left lateral decubitus position for 20 min after the injection and reported pain relief 15 min later. Peak analgesic activity was noted 45 min after the injection. A unilateral zone of analgesia to pinprick extended from the T₂ to T₁₂ dermatomal level. There was no significant change in blood pressure or heart rate.

The pain returned 6 h later, and the second dose of 20 ml 0.5% bupivacaine was given. The analgesic effect was achieved within 15 min and persisted for 12 h. However, hoarseness and mild dysphagia were noted beginning 15 min after the second injection; these symptoms disappeared 6 h later. The same response developed after a third injection of bupivacaine 12 h after the episode of hoarseness. Despite the two episodes of hoarseness, the vital signs remained stable and satisfactory analgesia was obtained.

We consulted an otolaryngologist after the second insult. Direct laryngoscopy revealed a complete paralysis of paramedian portion of the left vocal cord. Following 5 ml Angiografin (meglumine diatrizoate) injected through the catheter, a chest radiograph in the standing position showed a patchy accumulation of contrast medium in the T₆

paravertebral area and along the aortic arch at T₄ level (fig. 1B). Because the analgesic effect was satisfactory, we withdrew the catheter for 5 cm under the fluoroscopy to avoid further blockade of the left recurrent laryngeal nerve. Bupivacaine was resumed on demand. There was no hoarseness after the subsequent injections of bupivacaine. Analgesia remained satisfactory for the following 3 days. The patient was discharged 5 days later.

Left recurrent laryngeal nerve arises from vagus nerve and courses around the aortic arch near the ligamentum arteriosum. Then, it runs in the groove between the trachea and esophagus and proceeds superiorly to innervate the intrinsic muscles of the larynx.⁷ In close contact with various anatomic structures at the T₄ level, the nerve is extremely vulnerable to pathologic conditions associated with these organs, *e.g.*, dissecting aneurysm of the ascending aorta, and Pan coast tumor of the left lung. On the other hand, the right recurrent laryngeal nerve courses around the right subclavian artery that never enters the thoracic cavity.

In our case, contrast medium was accumulated near the sixth thoracic vertebral body and along the aortic arch in the standing position. Because contrast medium injected *via* the interpleural catheter has been shown to diffusely distribute along the mediastinum,^{8,9} local accumulation of dye should not be visualized when 5 ml contrast medium is injected into the interpleural space. Accordingly, our catheter could be located in the subpleural space of the upper mediastinum and resulted in block of the adjacent left recurrent laryngeal nerve. It is possible that repeated injection and body movement may in part lead to migration of the catheter into the upper mediastinum.

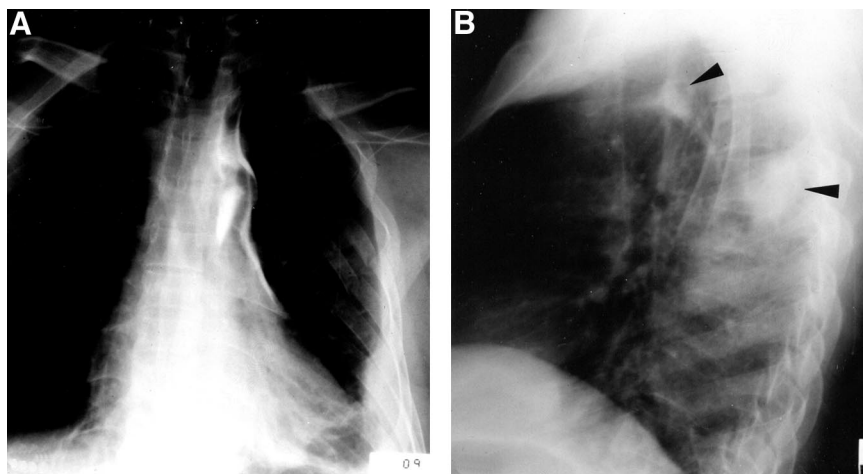
Misplacement of the catheter either into the extrapleural space or into lung tissue has been previously reported.¹⁰ Identifying the pleural space by the "loss of resistance" technique is associated with catheter displacement more frequently than by the traditional "detection of negative pressure" technique. In our case, the swollen lateral chest wall and fractured ribs were extremely tender to touch. A more medial approach, *i.e.*, 6 cm from the midline, was thus used to avoid inserting needle directly over the hematoma and the underlying fracture ribs. Therefore, the syringe had to be attached horizontally, and its entry into the interpleural space was identified by loss of resistance.

In summary, we demonstrated an intermittent blockade to the left recurrent laryngeal nerve following the inadvertent injection of 20 ml 0.5% bupivacaine into the left upper mediastinum. A sudden onset of hoarseness following the bolus injection and the local accumulation of contrast medium suggest a misplaced catheter in the subpleural space. Because subpleural block *per se* provides effective analgesia as well, the therapeutic benefit from replacing the catheter is outweighed by the potential risks with further procedures. In such situations, we recommend that the catheter be withdrawn immediately a few centimeters and replaced only if this intervention is insufficient.

Wei-Zen Sun, M.D.,* Yi Chang, M.D., Yung-Tai Chung, M.D. *National Taiwan University Hospital and National Taiwan University College of Medicine, Taipei, Taiwan. wzsun@ccms.ntu.edu.tw

Support was provided solely by institutional and/or departmental sources.

Fig. 1. Chest radiography in standing position after contrast medium injected through the catheter. (A) Posteroanterior view. (B) Lateral view. Accumulation of contrast medium near the sixth thoracic vertebral body and along the aortic arch is shown by the *arrows*.



References

1. Rocco A, Reiestad F, Gudman J, McKay W: Intrapleural administration of local anesthetics for pain relief in patients with multiple rib fractures: preliminary report. *Regional Anesth* 1987; 12:10-4
2. Stromskag KE, Minor B, Steen PA: Side effects and complications related to interpleural analgesia: An update. *Acta Anaesthesiol Scand* 1990; 34:473-7
3. Maroof M, Siddique M, Khan RM, Bonsu A: Effusion after interpleural analgesia (letter). *Can J Anaesth* 1992; 39:742
4. Sihota MK, Holmblad BR: Horner's syndrome after intrapleural anesthesia with bupivacaine for post-herpetic neuralgia. *Acta Anaesthesiol Scand* 1988; 32:593-4
5. Lauder GR: Interpleural analgesia and phrenic nerve paralysis. *Anaesthesia* 1993; 48:315-6
6. Shantha TR: Unilateral bronchospasm after interpleural analgesia. *Anesth Analg* 1992; 74:291-3
7. Crafts RC: A textbook of human anatomy, 3rd ed. New York, Wiley & Sons 1985, p. 184
8. Stromskag KE, Hauge O, Steen PA: Distribution of local anesthetic injected into the interpleural space, studied by computerized tomography. *Acta Anaesthesiol Scand* 1990; 34:323-6
9. Tase C, Kawamae K, Akama Y, Okuaki A: Catheter location and patient position affect spread of interpleural regional analgesia. *ANESTHESIOLOGY* 1993; 79:1153-4
10. Symreng T, Gomez MN, Johnson B, Rossi NP, Chiang CK: intrapleural bupivacaine: Technical considerations and intraoperative use. *J Cardiothorac Anesth* 1989; 3:139-43

(Accepted for publication October 7, 2002.)