

## Coronary Artery Spasm during Initiation of Epidural Anesthesia

R. Blaine Easley, M.D.,\* Ron E. Rosen, M.D.,\* Karen S. Lindeman, M.D.†

CORONARY artery spasm (CAS) can induce angina in patients with or without a history of coronary artery disease. CAS is presumably the underlying cause of unstable or Prinzmetal angina, which if left untreated, can result in myocardial infarction and death.<sup>1</sup> Perioperative CAS with characteristic changes on electrocardiogram has been reported in patients with<sup>1-7</sup> or without<sup>8,9</sup> a history of coronary artery disease undergoing general or regional anesthesia. We describe a patient who experienced angina and electrocardiographic changes during initiation of epidural anesthesia. This case is unique in that the events occurred before surgical stimulation in a patient without coronary artery disease. These findings strongly support the idea that epidural anesthesia can contribute to CAS in the absence of preexisting coronary artery disease.

### Case Report

A 60-yr-old, 72-kg, 132-cm woman was scheduled for an exploratory laparotomy and total abdominal hysterectomy secondary to a cystic adnexal mass. Her medical history was significant for remote tobacco use (35 yr previously), childbirth, Crohn disease, and a recent diagnosis of borderline hypertension. Her surgical history was significant for proctectomy, colectomy, ileostomy, and caesarian section. She had no history of allergies or cardiovascular symptoms. Physical examination and laboratory data were unremarkable. Chest radiography and electrocardiography were unremarkable.

On the day of surgery, her vital signs were as follows: heart rate of 66 beats/min, respiratory rate of 16 breaths/min, temperature of 36.7°C, and 100% oxygen saturation measured by pulse oximetry on room air. A blood pressure measurement of 184/95 mmHg was obtained, with a repeat reading of 127/65 mmHg. Preoperative fasting status was verified, and consent was obtained for placement of an epidural catheter. The epidural catheter was placed in the holding area per institutional routine. The patient was sitting with pulse oximetry, five-lead electrocardiography, and blood pressure monitoring. Her back was prepared with iodine, and her skin was anesthetized with 3 ml 1% lidocaine; a 17-gauge Tuohy needle was inserted by the loss of resistance technique at the T11-T12 interspace. A 20-gauge single orifice catheter was threaded 5 cm into the epidural space. After a negative aspiration test, 3 ml 2% lidocaine with 1:200,000 epinephrine was injected with no changes in heart rate or sensory block.

In the operating room, she was transferred to the operating table, placed on monitors, provided oxygen by facemask (8 l/min), and administered 1 mg midazolam intravenously for sedation. Initial vi-

tal signs were heart rate of 82 beats/min and blood pressure of 135/79 mmHg. Once the patient was supine, 5 ml 0.75% bupivacaine with 1:200,000 epinephrine was administered incrementally through the epidural catheter. Fifteen minutes after completion of dosing (total of 18 ml), the patient began complaining of left-sided jaw pain and a 2.7-mm ST segment depression was noted in leads II and V5 (fig. 1). The sensory block was T6. Blood pressure (120/60 mmHg) and heart rate (80 beats/min) were stable during this time. The surgeon was notified and the procedure cancelled. Pain subsided with administration of intravenous morphine (1 mg). A 12-lead electrocardiogram, obtained in the postanesthesia care unit, showed sinus rhythm and ST segment depression in leads II, III, AVF, and V5. Sensory level peaked by pinprick at T2. The patient chewed a 325-mg aspirin tablet, and nitroglycerin was infused intravenously at 0.25  $\mu\text{g}^{-1} \cdot \text{kg}^{-1} \cdot \text{min}^{-1}$ . After 15 min, blood pressure was 95/50 mmHg and phenylephrine was started intravenously at 0.5  $\mu\text{g}^{-1} \cdot \text{kg}^{-1} \cdot \text{min}^{-1}$ . The blood pressure returned to the baseline value (122/55 mmHg). ST segment changes resolved with the aforementioned therapy after 30 min (fig. 1). Sensory block regressed over 2 h, and the catheter was removed.

The patient was transferred to the cardiac care unit. Laboratory data after the event were as follows: troponin I, 10.48 ng/ml (reference range, 0.03-0.15 ng/ml); MB (isoenzyme of creatine kinase [CK] containing M and B subunits) fraction 33  $\mu\text{g/l}$  (reference range, 0-7  $\mu\text{g/l}$ ); and CK-MB/total CK index, 11% (reference range, 0-3%). After 8 h, enzyme levels were obtained: troponin I, 0.24 ng/ml; MB fraction, 19  $\mu\text{g/l}$ ; and CK-MB/total CK index, 7%. Based on electrocardiographic changes, troponin levels, and CK-MB fractions, the patient was diagnosed with a non-Q-wave myocardial infarction. Coronary angiography on the following day was unremarkable, and a presumptive diagnosis of CAS was made. The ECG tracing normalized, except for inverted T waves in the lateral leads, and the patient was discharged from the hospital with a prescription for 30 mg oral nifedipine per day. One week later, the patient underwent surgery under general anesthesia without problems. The patient was monitored in the intensive care unit for 24 h. Her hospital course to time of discharge was uneventful.

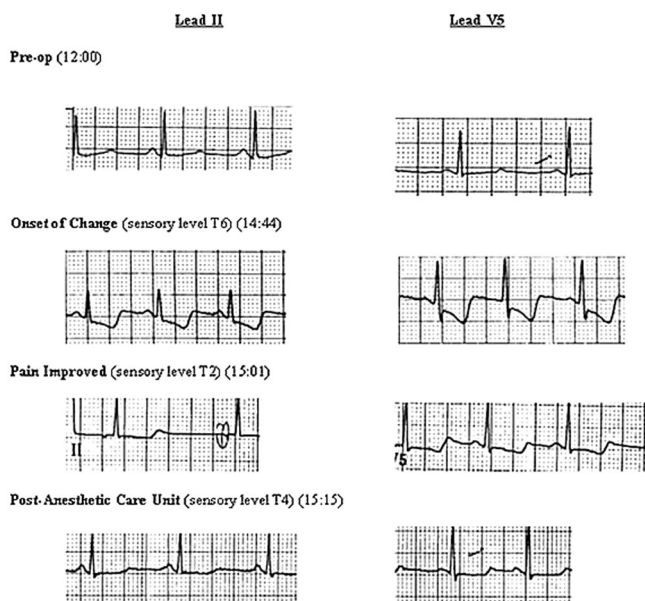
### Discussion

Coronary artery spasm can cause angina and myocardial ischemia in the absence or presence of fixed coronary artery disease, and it is a rare complication of general and regional anesthesia. The first reports in the anesthesia literature concerning unstable angina involved patients with coronary artery disease emerging from general anesthesia.<sup>6,10</sup> Additional reports<sup>1,2,4,5,7-9</sup> followed in patients with coronary artery disease undergoing cardiac or noncardiac procedures. Krantz *et al.*<sup>9</sup> first reported CAS in the setting of regional anesthesia. However, the contribution of the epidural anesthetic to the onset of CAS was difficult to interpret because of ongoing surgical stimulation and fixed coronary stenosis. Thus, it is possible that regional anesthesia played a limited role in early reports and that catecholamine surges during or after surgery may have produced myocardial ischemia by vasoconstricting areas around a pre-existing stenosis.

\* Resident and † Associate Professor, Department of Anesthesiology and Critical Care Medicine, The Johns Hopkins Medical Institutions.

Received from the Department of Anesthesiology and Critical Care Medicine, The Johns Hopkins Medical Institutions, Baltimore, Maryland. Submitted for publication September 23, 2002. Accepted for publication April 29, 2003. Support was provided solely from institutional and/or department sources.

Address reprint requests to Dr. Easley: The Johns Hopkins Medical Institute, 600 North Wolfe Street, Blalock 906, Baltimore, Maryland 21287. Address electronic mail to: beasley@jhmi.edu. Individual article reprints may be purchased through the Journal Web site, www.anesthesiology.org.



**Figure 1.** The electrocardiogram tracings from leads II (left) and V5 (right). Note the ST segment depression consistent with subendocardial ischemia and a right coronary artery distribution. The findings and lead distribution are typical of Prinzmetal angina. The jaw pain resolved in minutes, but the electrocardiographic changes required 30 min to return to baseline appearance.

Other reports of CAS during regional anesthesia have suggested that sympathetic nerve blockade and parasympathetic dominance may be one mechanism for myocardial ischemia. A case report similar to ours described CAS at the initiation of regional anesthesia. Hako *et al.*<sup>11</sup> described a patient with a history of unstable angina and multiple risk factors for coronary artery endothelial dysfunction, who experienced chest pain and electrocardiographic changes with initiation of lumbar epidural anesthesia. Symptoms began when the anesthetic level reached T4 and the patient experienced a decrease in systolic blood pressure from 110 to 86 mmHg. Therapy with nitroglycerin infusion and diltiazem was initiated 20 min after the onset of symptoms. The chest discomfort resolved. The authors postulated that the sympathetic blockade in an already susceptible patient permitted parasympathetic hyperactivity, CAS, and myocardial ischemia. Their hypothesis was supported by Yasue *et al.*,<sup>12</sup> who studied parasympathetic activity as a trigger for CAS in patients diagnosed with unstable angina. They induced CAS by intracoronary injection of acetylcholine, the neurotransmitter of the parasympathetic system. In contrast to the report by Hako *et al.*, the contribution of epidural anesthesia to the initiation of CAS is more evident in our patient, because no hemodynamic changes preceded the jaw pain or electrocardiographic changes. In addition, our patient had no history of angina, and subsequent coronary angiography showed healthy coronary arteries and normal myocardial perfusion.

An alternate mechanism of epidural anesthesia-associ-

ated CAS may be compensatory sympathetic excitation above the level of partial or complete sympathetic blockade. Baron *et al.*<sup>13</sup> evaluated forearm vascular tone and reactivity in patients during lumbar epidural anesthesia. They found increased reactivity and vasoconstriction in sympathetically intact areas. During lumbar epidural anesthesia, increased sympathetic activity above the level of sympathetic block would include the cardiac sympathetic nerves. This increase in sympathetically mediated norepinephrine may be sufficient to stimulate CAS.<sup>14</sup> In contrast, a total sympathectomy, including cardiac sympathetic blockade, should limit the likelihood of CAS. However, other authors have suggested that susceptible patients with higher resting coronary tone in this setting may have an exaggerated response to a vasoconstricting stimuli (*i.e.*, hypotension), resulting in CAS.<sup>15,16</sup>

Outside the perioperative period, many physicians prefer to treat unstable angina with calcium channel blockers. Nifedipine is often chosen, but nicardipine, diltiazem, and verapamil may also be effective.<sup>2,12</sup> Calcium antagonists prevent calcium flux, thereby relaxing the coronary vessels and preventing a response to vasoconstrictive stimuli.<sup>4</sup> In our case, the use of calcium channel blockers in the setting of acute myocardial infarction is controversial. Although CAS was considered, we opted for conventional treatment of the symptoms with rate control, aspirin, and nitroglycerin. Once stable, the cardiologist and anesthesiologist agreed that initiating and maintaining nifedipine therapy through the perioperative period would be prudent, with subsequent weaning of the calcium channel blocker over 1 or 2 weeks. The period of delay for subsequent surgery is unknown.

In summary, we present a case of variant angina at the initiation of epidural anesthesia. Our patient developed transient jaw pain, ST segment increase, increased cardiac enzymes, and non-Q-wave myocardial infarction. She did not experience chest pain, perhaps because the sensory block was effective. She subsequently was treated with nifedipine and underwent a successful operation under general anesthesia with no further episodes of CAS. This case reinforces the need for close monitoring during the initiation and regression of regional anesthesia for signs and symptoms of sensory and neurologic changes, rhythm disturbances, and myocardial ischemia, even in patients without fixed coronary artery disease.

## References

1. Imamura M, Matsukawa T, Kashimoto S, Nonaka A, Kumazawa T: A case of coronary artery spasm during spinal anesthesia. *J Clin Anesth* 1996; 8:522-4
2. Sprung J, Lesitsky MA, Jagetia A, Tucker C, Saffian M, Gottlieb A: Cardiac arrest caused by coronary spasm in two patients during recovery from epidural anesthesia. *Reg Anesth* 1996; 21:253-60
3. Mizuyama K, Dohi S, Harukuni I: Coronary artery spasm with ventricular tachycardia after administration of methoxamine during cervical epidural anesthesia: A case report. *Acta Anaesthesiol Scand* 1993; 37:79-81
4. Cohen DJ, Foley RW, Ryan JM: Intraoperative coronary artery spasm suc-

cessfully treated with nitroglycerine and nifedipine. *Ann Thorac Surg* 1983; 36:97-100

5. Briard C, Corat P, Commin P, Chollet A, Menasche P, Echter E: Coronary artery spasm during non-cardiac surgical procedure. *Anaesthesia* 1983; 38:467-70

6. Buffington CW, Ivey TD: Coronary artery spasm during general anesthesia. *ANESTHESIOLOGY* 1981; 55:466-9

7. Skarvan K, Graedel E, Hasse J, Stulz P, Pfister M: Coronary artery spasms after coronary bypass surgery. *ANESTHESIOLOGY* 1984; 61:323-7

8. DeWolf AM, Kang YG: Coronary artery spasm and ST-segment depression (letter). *ANESTHESIOLOGY* 1985; 62:368

9. Krantz EM, Viljoen JF, Gilbert MS: Printzmetal's variant angina during extradural anaesthesia. *Br J Anaesth* 1980; 52:945-9

10. Balagot RC, Selim H, Bandelin VR, Kwan BK, Ecanow B: Printzmetal's variant angina in the immediate post-anesthetic state. *ANESTHESIOLOGY* 1977; 46: 355-7

11. Hoka S, Izumi K, Matsukado T, Matsuda K, Takashadi S: Coronary artery spasm induced under lumbar epidural anesthesia. *Eur J Anaesthesiol* 1995; 6:609-12

12. Yasue H, Yutaka H, Nakamura N, Fujii H, Imoto N, Sonoda R, Kugiyama K, Obata K, Morikami Y, Kimura T: Induction of coronary artery spasm by acetylcholine in patients with variant angina: Possible role of the parasympathetic nervous system in the pathogenesis of coronary artery spasm. *Circulation* 1986; 74:955-63

13. Baron JF, Payen D, Coriat P, Edouard A, Viars P: Forearm vascular tone and reactivity during lumbar epidural anesthesia. *Anest Analg* 1988; 67:1065-70

14. Taniguchi M, Kasaba T, Takasaki M: Epidural anesthesia enhances sympathetic activity in the unanesthetized segments in cats. *Anest Analg* 1997; 84: 391-7

15. Bugiardini R, Pozzati A, Ottani F, Morgagni GL, Puddu P: Vasotonic angina: A spectrum of ischemic syndromes involving functional abnormalities of the epicardial and microvascular coronary circulation. *J Am Coll Cardiol* 1993; 22:417-25

16. Fleisher LA, Frank SM, Shir Y, Estefanous M, Kelly S, Raja SN: Cardiac sympathovagal balance and peripheral sympathetic vasoconstriction: Epidural versus general anesthesia. *Anest Analg* 1994; 79:165-71

*Anesthesiology* 2003; 99:1017-8

© 2003 American Society of Anesthesiologists, Inc. Lippincott Williams & Wilkins, Inc.

## Bilateral Cannulation of Internal Jugular Veins May Worsen Intracranial Hypertension

Nino Stocchetti, M.D.,\* Luca Longhi, M.D.,† Valerio Valeriani, M.D.†

PATIENTS with intracranial hypertension frequently require central venous catheterization. When intracranial elastance is normal, venous drainage from the brain is not usually impaired by jugular bulb cannulation,<sup>1</sup> and even during bilateral cannulation, no increase in intracranial pressure (ICP) has been reported.<sup>2</sup> However, when intracerebral compensatory mechanisms are exhausted, large-caliber catheters in the jugular veins may critically restrict venous outflow and cause a substantial increase in ICP.

We describe a patient with intracranial hypertension managed with aggressive medical treatment. We believe that in this patient, a reduction of cerebral venous drainage from bilateral cannulation of the internal jugular vein was probably the cause of an additional severe increase in ICP.

### Case Report

A 22-yr-old woman with a weight of 55 kg and height of 172 cm was admitted to the neurosurgical intensive care unit after suffering a head injury in a traffic accident. At admission, the Glasgow Coma Score was 8, and the computed tomography scan showed a fracture of the left petrous ridge, a small left temporal laceration, and bifrontal contusions.<sup>3,4</sup> A subdural catheter was placed, and ICP and mean arterial

pressure were continuously recorded and stored through an analog-digital converter in a computer for analysis.

Intracranial hypertension was present from the beginning (opening pressure, 30 mmHg) and was associated with desaturation of the jugular blood (jugular hemoglobin oxygen saturation, 44%; arteriojugular O<sub>2</sub> difference, 7.6 ml/dl). Desaturation was corrected by reducing the cerebral metabolic demand by using propofol and fentanyl and increasing the arterial oxygen content with erythrocyte transfusion, aiming at keeping the hemoglobin level in the range of 9-10 g/dl.<sup>5</sup>

Intracranial hypertension was treated according to published guidelines.<sup>6</sup> Because the usual steps failed to control it, barbiturate coma was started. Noradrenaline infusion was necessary to keep a cerebral perfusion pressure above the threshold of 60 mmHg.<sup>7</sup> It is our policy to insert a Swan-Ganz catheter in all patients who require barbiturate coma and vasopressor infusion. Because a 16-gauge catheter (Arrow International, Inc., Reading, PA) had already been retrogradely placed with the tip in the bulb of the right internal jugular vein for jugular hemoglobin oxygen saturation measurement, an 8-French introducer (Arrow International, Inc.) for the Swan-Ganz catheter was inserted in the left internal jugular vein. The patient was paralyzed, and her head and torso were placed in a flat position. The ICP and mean arterial pressure transducers, zeroed at the external meatus, followed the body position change, so that the recording continued with reliable data. The ICP increased during the maneuver and manual hyperventilation was necessary.

The head was slightly rotated for easier anatomic reference, and the left internal jugular vein punctured without problems. At the end of the cannulation, with the head and neck in a neutral position, the ICP increased to 50 mmHg. All possible causes (e.g., malpositioning of the head, pneumothorax, respiratory changes, Pao<sub>2</sub> and Paco<sub>2</sub> changes, pain, hyperthermia, seizures, and rapid changes in blood pressure) were excluded. We suspected that simultaneous cannulation of the two internal jugular veins, especially with a second large-bore catheter, might have critically reduced cerebral venous drainage. Leaving the Swan-Ganz catheter in place, we withdrew the introducer from the vein; the ICP suddenly decreased to previous values (fig. 1). No other therapeutic maneuvers were active at that moment, so a clear cause-effect relationship was identified.

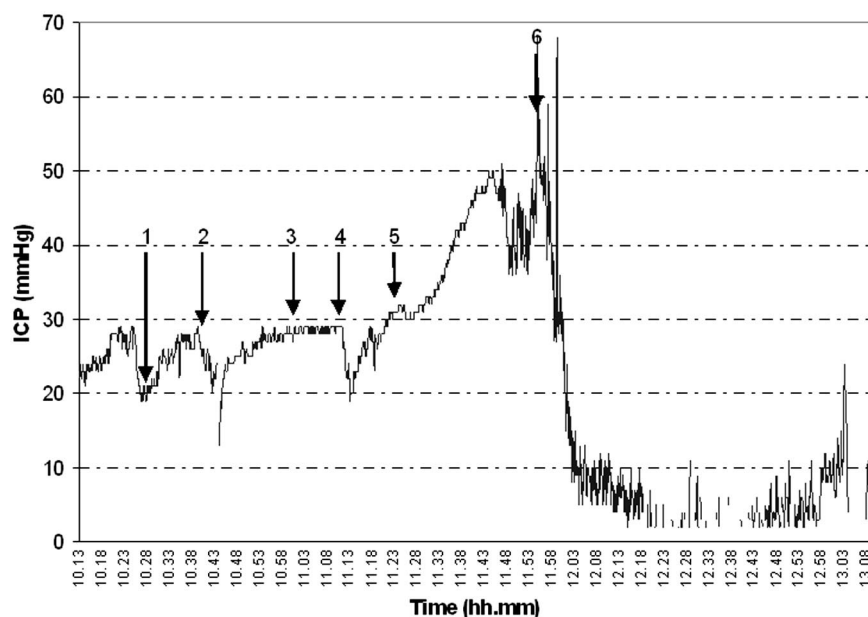
Barbiturate coma controlled the ICP, and the subsequent clinical course was unremarkable. At discharge from the intensive care unit, the patient could obey simple orders; after 6 months, she had achieved a good recovery.

\* Associate Professor, † Staff, Department of Anesthesia and Intensive Care, Milano University.

Received from the Department of Anesthesia and Intensive Care, Milano University, Ospedale Maggiore Policlinico, Istituto di Ricovero e Cura a Carattere Scientifico (IRCCS), Milan, Italy. Submitted for publication January 14, 2003. Accepted for publication April 29, 2003. This study has been supported by the current research funding for the year 2001 of the Ospedale Policlinico, IRCCS, Milan, Italy.

Address reprint requests to Dr. Stocchetti: Neuroscience ICU, Department of Anesthesia and Intensive Care, Ospedale Policlinico IRCCS, via F. Sforza 35, 20122 Milano, Italy. Address electronic mail to: Stocchet@policlinico.mi.it. Individual article reprints may be purchased through the Journal Web site, www.anesthesiology.org.





**Figure 1.** Intracranial pressure (ICP) after positioning of an 8-French Swan-Ganz introducer in the left jugular vein, with the contralateral jugular internal vein already cannulated. The patient was prepared for the Swan-Ganz insertion (1), and because the ICP was unstable, manual hyperventilation (2), myorelaxant (3), and hyperventilation (4) were used for the control of the ICP. Once the Swan-Ganz introducer was in place (5), the ICP steadily increased until the introducer was removed (6).

## Discussion

Although the intensive care unit is meant to provide a safe environment, many maneuvers are risky.<sup>8</sup> Central vein cannulation involves a risk of pneumothorax.<sup>9</sup> Cannulation of the internal jugular vein toward the mediastinum is routinely preferred because it is not associated with any greater risk than subclavian cannulation<sup>10</sup> and is widely used for Swan-Ganz catheter insertion.<sup>11</sup>

Venous drainage from the intracranial cavity is mainly through the jugular veins.<sup>12</sup> Severe reduction of their lumens therefore may impair venous outflow and cause intracranial blood volume to increase. Compression of the jugular vein is, in fact, recognized as a potential cause of intracranial hypertension.<sup>13,14</sup>

Any increase in intracranial volume will be reflected in ICP, depending on the capacity of compensatory mechanisms. Although we did not measure intracranial elastance, we can reasonably assume that this patient was at a steep point in her pressure-volume curve. ICP was greatly increased because of voluminous bifrontal contusions, and her basal cisterns were not visible on the computed tomography scan. At this critical point, even a slight increase in cerebral volume may cause a substantial increase in ICP. However, restoration of the venous drainage rapidly decreased it.

In the literature, we found no reports that ICP may be significantly affected by central vein cannulation, even when bilateral retrograde cannulation of the jugular veins is performed.<sup>15</sup>

In cases with bilateral cannulation, however, the diameters of the catheters were always smaller than the introducer used in this case. When ICP is high and limited buffer capacity of the intracranial system is suspected, maneuvers causing any additional increase in the

intracranial volume, such as bilateral cannulation of the internal jugular veins with large-bore catheters, should be avoided.

## References

- Goetting MG, Preston G: Jugular bulb catheterization does not increase intracranial pressure. *Intensive Care Med* 1991; 17:195-8
- Stocchetti N, Paparella A, Bridelli F, Bacchi M, Piazza P, Zuccoli P: Cerebral venous oxygen saturation studied with bilateral samples in the internal jugular veins. *Neurosurgery* 1994; 34:38-44
- Marshall LF, Marshall SB, Klauber MR, Clark MvB, Eisenberg HM, Jane JA, Luessen TG, Marmarou A, Foulkes MA: A new classification of head injury based on computerized tomography. *J Neurosurg* 1991; 75:S14-20
- Servadei F, Nanni A, Nasi MT, Zappi D, Vergoni G, Giuliani G, Arista A: Evolving brain lesion in the first 12 hours after head injury: Analysis of 37 comatose patients. *Neurosurgery* 1995; 37:899-906
- Gopinath SP, Robertson CS, Contant CF, Hayes C, Feldman Z, Narayan RK, Grossman RG: Jugular venous desaturation and outcome after head injury. *J Neurol Neurosurg Psychiatry* 1994; 57:717-23
- Brain Trauma Foundation, AANS Joint Section on Neurotrauma and Critical Care. Guidelines for the management of severe head injury: Critical pathway for the treatment of established intracranial hypertension. *J Neurotrauma* 2000; 17:537-8
- Rosner MJ, Rosner SD, Johnson AH: Cerebral perfusion pressure: Management protocol and clinical results. *J Neurosurg* 1995; 83:949-62
- Jones PA, Andrews PJD, Migdley S, Anderson SI, Piper IR, Tocher JL, Housley AM, Corrie JA, Slattery J, Dearden NM, Miller JD: Measuring the burden of secondary insults in head-injured patients during intensive care. *J Neurosurg Anesthesiol* 1994; 1:4-14
- Shah KB, Rao TL, Laughlin S, El-Etr AA: A review of pulmonary artery catheterization in 6,245 patients. *ANESTHESIOLOGY* 1984; 61:271-5
- Mansfield PF, Hohn DC, Fornage BD, Gregurich MA, Ota DM: Complications and failures of subclavian-vein catheterization. *N Engl J Med* 1994; 331:1735-8
- Damen J, Bolton D: A prospective analysis of 1,400 pulmonary artery catheterizations in patients undergoing cardiac surgery. *Acta Anaesthesiol Scand* 1986; 30:386-92
- Hatiboglu MT, Anil A: Structural variations in the jugular foramen of the human skull. *J Anat* 1992; 180:191-6
- Hulme A, Cooper R: The effects of head position and jugular vein compression on intracranial pressure, Intracranial Pressure III. Edited by Becks J, Bosch DA, Brock M. New York, Springer-Verlag, 1976, pp 259-63
- Woda RP, Miner ME, McCandless C, McSweeney TD: The effect of right internal jugular vein cannulation on intracranial pressure. *J Neurosurg Anesthesiol* 1996; 8:286-92
- Latronico N, Beindorf AE, Rasulo FA, Febrari P, Stefani R, Cornali C, Candiani A: Limits of intermittent jugular bulb oxygen saturation monitoring in the management of severe head injury. *Neurosurgery* 2000; 5:1131-9

## Cerebrospinal Fluid Drainage Duration after Thoracoabdominal Aortic Aneurysm Repair

Tatjana M. Fleck, M.D.,\* Herbert Koinig, M.D.,† Doris Hutschala, M.D.,‡ Ernst Wolner, M.D. § Martin Grabenwoger, M.D.¶

THE first successful resection of a descending aortic aneurysm was performed by Lam and Aram in 1951, which was also the first reported complication of partial paraplegia after thoracic aneurysm repair.<sup>1</sup> Since then, investigators have been encouraged to explore adjuncts to attempt to lower the risk for spinal cord ischemia, which varies between 3% and 26%.<sup>2</sup>

Cerebrospinal fluid drainage (CSFD) first implemented in 1988 is an often used adjunct for thoracoabdominal aortic aneurysm repair (TAAA) repair that restores blood flow in an edema-compromised spinal cord.<sup>1,3-6</sup> Although the improvements in operative technique such as sequential aortic clamping and left heart bypass have led to a reduction of immediate neurologic deficit, the mechanism that causes delayed deficits still remains to be elucidated.

Herein, we report two cases of complete reversal of delayed onset of paraplegia with the immediate resumption of CSFD after TAAA repair. The findings in our case report further support the evidence for immediate initiation of CSFD therapy in delayed neurologic deficits occurring after TAAA surgery.

### Case Reports

#### Case 1

A 60-year-old woman underwent elective surgery for a Crawford extent II aneurysm in March 2002 after a replacement of the ascending thoracic aorta was accomplished in January 2002. Beyond a history of hypertension, no other co-morbidities were present. Standard intraoperative management included distal aortic perfusion with left heart bypass (left heart bypass time: 52 min); visceral perfusion of the celiac trunk and the superior and inferior mesenteric arteries as well as both renal arteries (perfusion time: 36 min); and CSFD. The operative technique is described in detail elsewhere.<sup>7</sup> A CSFD (Cordis lumbar drain kit; Cordis, Miami, FL) was implemented between L3 and L4 by introducing a 14-gauge Tuohy needle in the intervertebral space until free-flow of liquid from the needle was achieved. Thereafter, the catheter was adjusted to maintain cerebrospinal fluid (CSF) pressure at 10 mmHg. During operation (duration 360 min), 400 ml were drained. After an uneventful intraoperative course, the patient was transferred to the intensive care unit in a hemodynamic stable condition. No

difficulties were encountered on awakening from sedation, and extubation was performed on postoperative day 1. Aside from delirium, the patient was in a stable condition. However, after 48 hours and a 250 ml drainage amount, the CSF drain was accidentally removed. Because the protocol in our department recommends duration of CSFD between 48 and 72 hours, no reinsertion of a new CSFD was attempted. One hour after removal, the patient reported weakness of the lower extremity. Neurologic status was assessed by scoring the deficit as described by Crawford *et al.*<sup>8</sup> Two hours later, the patient was unable to move her legs (score 0). A new CSFD was subsequently inserted. Liquid pressure after insertion was 20 mmHg, and 150 ml of fluid were drained to adjust the target pressure to 10 mmHg. No additional pharmacologic therapy was administered. There were no significant changes in systolic blood pressure before or during the period of neurologic deficit, with average systolic values between 120 and 150 mmHg. During the next 8 hours, the patient was again able to move her legs (score 1). The CSFD was removed after 72 hours, and the total drained volume was 610 ml. At this time, the patient had a score of 2. Complete motor function was regained during the next 2 weeks, and she could be discharged with minimal residual deficit (score 5).

#### Case 2

A 69-year-old woman with chronic renal insufficiency who was otherwise healthy was admitted for TAAA repair for a Crawford extent I aneurysm with a maximum diameter of 9 cm. She successfully underwent surgery on April 2002 (left heart bypass time: 45 min, visceral perfusion time: 19 min). For operative details, refer to reference.<sup>7</sup> A CSFD (Cordis lumbar drain; Cordis) was initiated preoperatively and was allowed to drain by gravity whenever the liquid pressure exceeds 10 mmHg. During the operation (duration: 300 min) 306 ml was drained. The patient was extubated 8 hours after surgery and was transferred to the ward on postoperative day 2. After 72 hours, the CSF catheter was removed, and the total drained volume was 550 ml. Two hours thereafter, the patient reported first signs of bilateral lower extremity weakness (score 2) and exhibited full paraparesis during the next 4 hours (score 0) until CSFD therapy was resumed with insertion of a new CSFD. Slight fluctuations in systolic blood pressure were noted before the onset of the neurologic deficit. However, systolic blood pressure was maintained above 130 mmHg. At 1 hour after reinsertion of the CSF catheter, slight improvements were noted by the patient (score 1). She was able to move her legs and could raise them after 24 hours. The drainage was left in place for 96 hours, during which 800 ml of liquid were drained. Standing up (score 3) was possible after removal of the CSF catheter after 4 days. She was discharged after 54 days with a score of 5 and showed no remaining deficits at a follow-up visit 4 months after surgery.

### Discussion

The technique of CSFD was introduced by Miyamoto *et al.* in 1960 with experiments of spinal cord protection in dogs. However, the use of CSFD remained dormant until 1988 when McCullough and Hollier revived it.<sup>2,3</sup>

The effect of CSFD is based on the hypothesis that lowering CSF pressure increases spinal cord pressure

\* Resident, § Professor and Head, || Associate Professor, Department of Cardiothoracic Surgery, and † Associate Professor, ‡ Resident, Department of Cardiothoracic and Vascular Anaesthesia, University of Vienna.

Received from the Department of Cardiothoracic Surgery, University of Vienna, Vienna, Austria. Received for publication February 13, 2003. Accepted for publication April 30, 2003. Support was provided solely from institutional and/or departmental sources.

Address reprint requests to Dr. Fleck: Department of Cardiothoracic Surgery, General Hospital of Vienna, Leitstelle 20A, Währinger Gürtel 18-20, 1090 Vienna, Austria. Address electronic mail to: t9204604@hotmail.com

and therefore ensures spinal cord perfusion. By draining excess liquid, spinal cord compression is released and perfusion is enhanced. Furthermore, through the use of distal aortic perfusion, the distal aortic pressure is elevated and further increases spinal cord perfusion.<sup>9-11</sup> The consensus regarding the target CSF pressure is that it should not exceed 10 mmHg.<sup>9</sup>

Although several studies advocate the use of CSFD, none provides recommendations regarding the duration of CSFD. After intensive literature review, we found durations between 40 hours<sup>12</sup> and 120 hours,<sup>13</sup> with 72 hours as the most common.<sup>6,9-11,14-17</sup>

Immediate reinsertion of a CSFD after recognition of delayed neurologic deficit is an established treatment method with acceptable success rates.<sup>13,18,19</sup> Safi *et al.* reviewed their experience in managing patients with delayed neurologic deficit after TAAA repair.<sup>18</sup> A spinal cord compartment syndrome triggered by unstable blood pressure and increased CSF pressure possibly caused by spinal cord edema is suggested as the primary reason for the development of delayed neurologic deficit.<sup>19</sup>

However, the possibility of epidural hematoma formation has also been considered in a patient with new onset of paraparesis after TAAA repair. Brain computed tomography is recommended for identifying this rare but serious complication that necessitates neurosurgical intervention.<sup>20</sup>

The present cases and those in the literature<sup>13,18,19</sup> indicate that 72 hours is too short to effectively prevent the development of delayed neurologic deficit, because increased CSF pressure to reperfusion edema persists for more than 72 hours. The amount of drained CSF with 550 ml and 610 ml, respectively, in our two cases further supports this hypothesis. As a consequence of these findings, we leave CSFD in place for at least 96 hours, and a drainage volume of less than 100 ml in 24 hours is required before removal of the CSFD. The last three patients treated with this regimen produced an average of 1,700 ml of liquid during CSFD duration of 120 hours, which represents a sevenfold increase in the normal 24-hour production of 250 ml liquid. We observed an increased daily volume between days 2 and 4, which let us assume that spinal cord edema persists for more than 2 days.

Nevertheless, further studies addressing the optimal drainage duration must be conducted to elucidate this still underinvestigated field of TAAA repair. Despite such recognized adjuncts such as CSFD, left heart bypass, distal aortic perfusion, and reattachment of critical intercostal arteries, paraplegia still occurs with an incidence

of 3% to 15% in experienced centers, which underlines the need for continuing research for this most feared complication after thoracoabdominal aortic aneurysm repair.<sup>3,14</sup>

## References

1. Lam CR, Aram HH: Resection of descending thoracic aorta for aneurysm: Report of the use of the homograft in case and experimental study. *Ann Surg* 1951; 134:743-52
2. Connolly JE: Prevention of spinal cord complications in aortic surgery. *Am J Surg* 1998; 176:92-101
3. McCullough JL, Hollier LH, Nugent M: Paraplegia after thoracic aortic occlusion: Influence of cerebrospinal fluid drainage—experimental and early clinical results. *J Vasc Surg* 1988; 7:153-60.
4. Ling E, Arellano R: Systematic overview of the evidence supporting the use of cerebrospinal fluid drainage in thoracoabdominal aneurysm surgery for prevention of paraplegia. *ANESTHESIOLOGY* 2000; 93:1115-22
5. Safi HJ, Miller CC: Spinal cord protection in descending thoracic and thoracoabdominal aortic repair. *Ann Thorac Surg* 1999; 67:1937-9
6. Coselli JS, LeMaire SA, Köksoy C, Schmittling ZC, Curling PE: Cerebrospinal fluid drainage reduces paraplegia after thoracoabdominal aortic aneurysm repair: Results of a randomized clinical trial. *J Vasc Surg* 2002; 35:631-9
7. Fleck T, Hamilton C, Ehrlich MP, Hutschala D, Koinig H, Wolner E, Grabenwoger M: Thoracoabdominal aortic aneurysm repair: Reducing adverse outcome with left heart bypass, visceral perfusion and renal protection. *Semin Cardiothorac Vasc Anesth* 2002; 6:287-91
8. Crawford ES, Svensson LG, Hess KR, Shenaq SS, Coselli JS, Safi HJ, Mohindra PK, Rivera V: A prospective randomized study of cerebrospinal fluid drainage to prevent paraplegia after high risk surgery on the thoracoabdominal aorta. *J Vasc Surg* 1991; 13:36-46
9. Safi HJ, Bartoli S, Hess KR, Shenaq SS, Viets JR, Butt GR, Sheinbaum R, Doerr HK, Malsbury R, Rivera VM: Neurologic deficit in patients at high risk with thoracoabdominal aortic aneurysms: The role of cerebrospinal fluid drainage and distal aortic perfusion. *J Vasc Surg* 1994; 20:434-43
10. Safi HJ, Hess KR, Randel M, Iliopoulos DC, Baldwin JC, Mootha RK, Shenaq SS, Sheinbaum R, Greene T: Cerebrospinal fluid drainage and distal aortic perfusion: Reducing neurologic complications in repair of thoracoabdominal aortic aneurysms types I and II. *J Vasc Surg* 1996; 23:223-9
11. Estrera AL, Rubenstein FS, Miller CC, Huynh TTT, Letsou GV, Safi HJ: Descending aortic aneurysm: Surgical approach and treatment using the adjuncts cerebrospinal fluid drainage and distal aortic perfusion. *Ann Thorac Surg* 2001; 72:481-6
12. Svensson LG, Hess KR, D'Agostino RS, Entrup MH, Hreib K, Kimmel WA, Nadolny E, Shahian DM: Reduction of neurologic injury after high risk thoracoabdominal aortic operation. *Ann Thorac Surg* 1998; 66:132-8
13. Azizzadeh A, Huynh TTT, Miller CC, Safi HJ: Reversal of twice delayed neurologic deficits with cerebrospinal fluid drainage after thoracoabdominal aneurysm repair: A case report and plea for a national database collection. *J Vasc Surg* 2000; 31:592-8
14. Estrera AL, Miller CC, Huynh TTT, Porat E, Safi HJ: Neurologic outcome after thoracic and thoracoabdominal aortic aneurysm repair. *Ann Thorac Surg* 2001; 72:1225-33
15. Dardik A, Perler BA, Roseborough GS, Williams GM: Subdural hematoma after thoracoabdominal aortic aneurysm repair: An underreported complication of spinal fluid drainage? *J Vasc Surg* 2002; 36:47-50
16. Jacobs MJ, Elenbaas T, Schurink GWH, Mess WH, Mochtar B: Assessment of spinal cord integrity during thoracoabdominal aortic aneurysm repair. *Ann Thorac Surg* 2002; 74:S1864-6
17. Jacobs MJ, de Mol BA, Elenbaas T, Mess WH, Kalkman CJ, Schurink GW, Mochtar B: Spinal cord blood supply in patients with thoracoabdominal aortic aneurysms. *J Vasc Surg* 2002; 35:30-7
18. Safi HJ, Miller CC, Azizzadeh A, Iliopoulos DC: Observations on delayed neurologic deficit after thoracoabdominal aortic aneurysm repair. *J Vasc Surg* 1997; 26:616-22
19. Cheung AT, Weiss SJ, McGarvey ML, Stecker MM, Hogan MS, Escherich A, Bavaria JE: Interventions for reversing delayed onset postoperative paraplegia after thoracic aortic reconstruction. *Ann Thorac Surg* 2002; 74:413-21
20. Dardik A, Perler BA, Roseborough GS, Williams GM: Subdural haematoma after thoracoabdominal aortic aneurysm repair: An underreported complication of spinal fluid drainage? *J Vasc Surg* 2002; 36:47-50



## The Elective Combined Use of a Double Lumen Tube and Endobronchial Blocker to Provide Selective Lobar Isolation for Lung Resection following Contralateral Lobectomy

Desmond P. McGlade, M.B.B.S., F.A.N.Z.C.A.,\* Peter D. Slinger, M.D., F.R.C.P.C.†

VENTILATION during lung isolation for thoracic surgery is complicated by decreased pulmonary compliance and increased venous admixture (shunt). Compared with two-lung ventilation, a higher inspired airway pressure is required to create an equivalent tidal volume, and there is a greater potential for significant hypoxemia. These problems are exaggerated when ventilation is attempted *via* a lung that has previously undergone a large resection, such as complete or partial lobectomy.

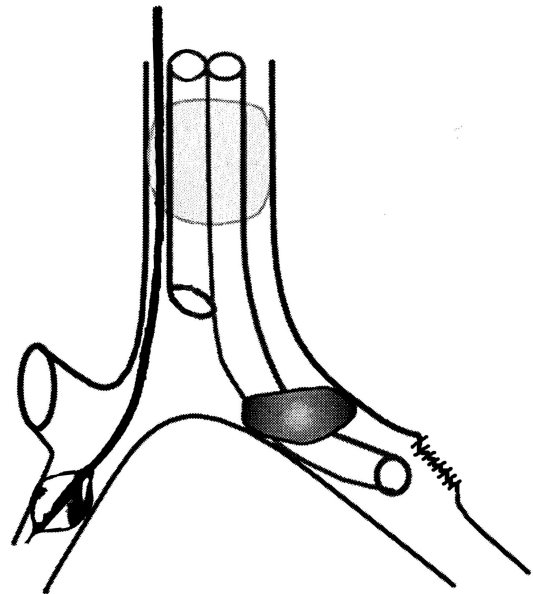
We report a novel combination of a double lumen tube (DLT) and bronchial blocker to provide suitable conditions for right upper lobe surgery in a patient who had recently undergone a left upper lobectomy.

### Case Report

A 63-year-old man was diagnosed with two concurrent primary lung tumors, one in the left upper lobe, the other in the right upper lobe. The patient was obese (body mass index,  $36 \text{ kg m}^{-2}$ ) but had no other significant comorbidities. For surgical indications, it was decided to resect the left upper lobe tumor first. The patient underwent an uneventful left upper lobectomy using a 39 F left DLT (Broncho-Cath, Mallinckrodt Inc., St. Louis, MO) for intraoperative lung isolation.

Six weeks later, the patient was rescheduled for resection of the right upper lobe tumor. An epidural catheter was placed preoperatively. Arterial blood gases while the patient was breathing room air showed a pH 7.44,  $\text{pCO}_2$  39 mmHg, and  $\text{pO}_2$  88 mmHg. After intravenous induction, an Arndt Endobronchial Blocker (Cook Inc., Bloomington, IN) was inserted and advanced through the vocal cords. The patient was then intubated with a 37 F left DLT (Broncho-Cath) placed next to the blocker. A smaller DLT was chosen on this occasion so that the airway could accommodate the two devices. A fiberoptic bronchoscope was inserted *via* the tracheal lumen of the DLT, and the bronchial cuff was positioned in the left main bronchus just beyond the carina. The blocker was then advanced under vision into the bronchus intermedius of the right main bronchus so that its balloon came to lie beyond the orifice of the right upper lobe bronchus (fig. 1). General anesthesia was maintained by sevoflurane in oxygen.

The patient was turned onto the lateral position and the surgery began. When the surgeon requested collapse of the right lung, the balloon of the blocker was inflated and the tracheal lumen of the DLT opened to the atmosphere. The right upper lobe was thus isolated



**Fig. 1.** The left-sided double lumen tube positioned in the left main bronchus (previous upper lobectomy). The endobronchial blocker positioned in the bronchus intermedius of the right lung.

from the left lung by the bronchial cuff of the DLT, and from the middle and lower lobes of the right lung by the blocker balloon. Continuous positive airway pressure (CPAP), 2 cm  $\text{H}_2\text{O}$  with 100% oxygen, was then applied to the right middle and lower lobes *via* the bronchial blocker. This arrangement allowed for unimpeded collapse of the right upper lobe and for surgery to proceed unhindered by movement within the right chest. Pressure-controlled mode was used for ventilation of the dependent lung at a rate of 14 and pressure of 28 cm  $\text{H}_2\text{O}$ , producing tidal volumes of 400 to 450 mL. Arterial blood gas analysis 15 min after this maneuver showed pH 7.37,  $\text{pCO}_2$  50 mmHg, and  $\text{pO}_2$  146 mmHg. A peripheral tumor was found in the right upper lobe and was removed by wedge resection. The arterial oxygen saturation remained at 99% throughout.

Previously undiagnosed tumors were then discovered in the right middle lobe. The surgeons requested the CPAP to be removed for their assessment and subsequent excision by wedge resections. Arterial blood gases performed 15 min after CPAP removal and collapse of the right middle and lower lobes showed a  $\text{pO}_2$  of 104 mmHg and  $\text{Sao}_2$  of 97%.

The procedure took 150 min and was uneventful. At completion, the trachea was extubated and the patient made an otherwise routine recovery.

### Discussion

We describe the combined use of DLT and bronchial blocker to electively secure selective lobar isolation.

\* Senior Staff Anesthetist, Department of Anaesthesia, St. Vincent's Hospital, Melbourne, Victoria, Australia. † Professor of Anesthesia, University Health Network.

Received from the Department of Anesthesia, Toronto General Hospital, University Health Network, University of Toronto, Toronto, Ontario, Canada. Submitted for publication December 26, 2003. Accepted for publication May 1, 2003.

Address reprint requests to Dr. McGlade: Senior Staff Anaesthetist, Department of Anaesthesia, St. Vincent's Hospital, P.O. Box 2900, Fitzroy, Victoria 3065, Australia. Address electronic mail to: mcgladp@svhm.org.au. Individual article reprints may be purchased through the Journal Web site, [www.anesthesiology.org](http://www.anesthesiology.org).

This differs from previously reported DLT-bronchial blocker combinations in which the role of the blocker has been to rescue an unexpected malposition of the DLT.<sup>1-3</sup> Our combination produced a unique situation for thoracic surgery. Oxygenation was provided *via* both the remaining ventilated left lower lobe and the CPAP applied to the isolated right middle and lower lobes. Carbon dioxide clearance was achieved *via* the ventilated left lower lobe. The right upper lobe collapsed freely and the remaining right lung remained quiescent and isolated. Peak airway pressure in the left lung was maintained at less than 30 cm H<sub>2</sub>O, and a minor degree of hypoventilation and respiratory acidosis were accepted.

According to a model for calculating the proportion of functional lung tissue remaining postresection,<sup>4</sup> our patient could be predicted to have lost 24% of lung function following his initial left upper lobectomy. A subsequent right thoracotomy with conventional lung isolation *via* a left DLT would require intraoperative gas exchange *via* 30% of the total remaining segmental lung function. In our opinion, it was unpredictable as to whether the patient would be able to tolerate this approach without risking hypoxemia, barotrauma, or pulmonary overdistention.<sup>5</sup> Hypoxemia during one lung ventilation can usually be successfully managed by applying CPAP with oxygen to the operative lung, but this provides less than optimal operating conditions. In retrospect, we acknowledge that this patient might have tolerated the entire procedure by conventional lung isolation, as demonstrated by his ability to maintain arterial oxygen saturation after the blocker was deflated and selective lobar CPAP was removed.

Selective lobar collapse, using the combination of a single lumen tube and bronchial blocker, has been described in the context of previous contralateral pulmonary resection.<sup>6,7</sup> Campos, using a single lumen tube and open channel blocker, was able to show improved oxygenation when CPAP with oxygen was applied during selective lobar isolation.<sup>8</sup> However, the use of a single lumen tube dictates selective blockade of the operative lobe. Ventilation and lung movement continue within

the surgical hemithorax, and the use of selective CPAP to the operative lobe might not be appreciated by the surgeon. Our combination of DLT with a bronchial blocker placed in the anatomically aligned bronchus intermedius provided both flexibility and stability. The motionless right chest with fully collapsed right upper lobe offered the surgeon optimal operating conditions.

With the implementation of surveillance protocols following pulmonary resection for lung cancer, we might expect a greater detection rate for patients developing a second resectable primary lung tumor.<sup>9</sup> It is also now not uncommon for patients to present for repeat thoracotomies for resection of certain types of metastatic tumors within the lungs. Therefore, in the future, it is likely that the number of patients presenting for a subsequent, often contralateral, pulmonary resection will increase. Anesthetists managing these complex thoracic cases must be able to use the full range of airway devices available, and in a manner that involves adaptation to the individual anatomic variations presented by each situation.

## References

1. Nino M, Body SC, Hartigan PM: The use of a bronchial blocker to rescue an ill-fitting double lumen endotracheal tube. *Anesth Analg* 2000; 91:1370-1
2. Capdeville M, Hall D, Koch CG: Practical use of a bronchial blocker in combination with a double lumen endotracheal tube. *Anesth Analg* 1998; 87:1239-41
3. Soonthon-Brant V, Benumof JL: Unexpected small tracheobronchial tree size and separation of the lungs (letter). *J Cardiothorac Vasc Anesth* 2002; 16:260-1
4. Nakahara K, Ohno K, Hashimoto J, Miyoshi S, Maeda H, Matsumura A, Mizuta T, Akashi A, Nakagawa K, Kawashima Y: Prediction of postoperative respiratory failure in patients undergoing lung resection for cancer. *Ann Thorac Surg* 1988; 46:549-52
5. Dreyfuss D, Soler P, Basset G, Saumon G: High inflation pressure pulmonary edema: Respective effects of high airway pressure, high tidal volume, and positive end expiratory pressure. *Am Rev Respir Dis* 1988; 137:1159-64
6. Campos JH, Ledet C, Moyers JR: Improvement in arterial oxygen saturation with selective lobar bronchial block during hemorrhage in a patient with previous contralateral lobectomy. *Anesth Analg* 1995; 81:1095-6
7. Hagihira S, Maki N, Kawaguchi M, Slinger P: Selective bronchial blockade in patients with previous contralateral lung surgery. *J Cardiothorac Vasc Anesth* 2002; 16:638-42
8. Campos JH: Effects on oxygenation during selective lobar versus total lung collapse with or without continuous positive airway pressure. *Anesth Analg* 1997; 85:583-6
9. Naunheim KS, Virgo KS: Postoperative surveillance following lung cancer resection. *Chest Surg Clin N Am* 2001; 11:213-25