

## Postextubation Severe Bronchospasm and Hypotension Triggered by Exposure to a Disinfectant Spray

Marc Licker, M.D.,\* Anastase Spiliopoulos, M.D.,† Denis Morel, M.D.,‡ Catherine Chevalley, M.D.§

IN the perioperative period, anaphylactic reactions are often induced by the intravenous administration of muscle relaxants, antibiotics, colloids, and radiocontrast materials as well as after local contact with latex-containing materials (e.g., gloves, catheters, airway tube) and chlorhexidine.<sup>1,2</sup> Inhalation of toxic and highly irritant substances contained in cleaning solutions has occasionally been incriminated to produce acute bronchospasm and hypersensitization to other allergens.<sup>3</sup> In this report, the postoperative onset of bronchospasm, hypotension, and urticaria is described and the involvement of both immune and nonimmune mechanisms is discussed.<sup>4,5</sup>

### Case Report

A 43-yr-old female nurse was referred to our hospital for open resection of a 13-mm pulmonary nodule located in the right lower lobe. She had stopped smoking 4 yr previously, and her past medical history included mild urticarial reaction to penicillin, erythromycin, codeine, and aspirin. Over the previous 6 months, the use of a disinfectant compound (Synergen®; Democal AG, Villars-sur-Glâne, Switzerland) at her workplace typically produced recurrent episodes of dry cough, breathlessness, and chest tightness. Otherwise, her medical examination, laboratory results, and functional lung volumes were all within normal values.

On the day of surgery, the patient was premedicated with 7.5 mg midazolam orally, a thoracic epidural catheter was placed, and 1.5 g cefuroxime was given intravenously for antibiotic prophylaxis. After intravenous anesthesia induction with pentobarbital (400 mg), fentanyl (100 µg), and rocuronium (40 mg), the urinary bladder was catheterized, a double-lumen bronchial tube (Mallinckrodt 37-G; Carbamed, Zurich, Switzerland) was inserted, and tube positioning was confirmed by auscultation and fiberoptic bronchoscopy. Anesthesia was maintained with inhaled desflurane (2-5%), and analgesia was provided through continuous epidural administration of bupivacaine, 0.25%, and 2 µg/ml fentanyl. Under selective left lung ventilation using a semi-closed circuit, a right minithoracotomy was performed to remove a

benign pulmonary mass (hamartoma). At the end of an uneventful surgical procedure, the patient was successfully extubated, being fully awake, pain-free, hemodynamically stable, and with adequate gas exchange (fig. 1; mean blood pressure, heart rate, and oxygen saturation measured by pulse oximetry).

After closure of the wound dressing, operating room technicians sprayed a disinfectant (Synergen®) over the surgical tables and equipment, which were located less than 2 m from the patient's face. Within the next few minutes, the patient suddenly became restless and breathing difficulties developed, which consisted of audible expiratory wheezing, increased inspiratory effort, and arterial desaturation (down to 75%). Arterial hypotension (lowest systolic value: 65 mmHg) and generalized cutaneous erythema shortly followed the onset of respiratory distress. Immediate treatment consisted of intravenous adrenaline (0.5 mg, followed by  $8.10^{-4} \cdot \text{kg}^{-1} \cdot \text{min}^{-1}$ ) with hydrocortisone (500 mg), and spontaneous ventilation with 100% oxygen was manually assisted *via* an occlusive mask in a semisitting position. Neither secretions nor gastric fluid was present in her oral cavity. Fluids were rapidly infused (250 ml hydroxyethyl starch, 5%, and 750 ml crystalloids), and ipratropium and salbutamol were given by inhalation. Over the next 3 h, the skin rash disappeared and her cardiopulmonary condition dramatically improved; blood pressure and oxygen saturation measured by pulse oximetry remained stable after withdrawal of the adrenaline infusion and positive pressure airway support. Except for moderate hyperleukocytosis, laboratory results were within normal limits. A chest radiograph showed clear lung fields and a normal cardiac shadow.

Blood taken in the postanesthesia care unit revealed elevated total immunoglobulin E (IgE) levels (899 U/ml [normal: < 100 U/ml]), and radioallergosorbent testing demonstrated raised titers of specific IgE antibodies against latex (12.9 U/ml). Retrospectively, the patient acknowledged that over the previous 12 months, mild contact dermatitis had appeared on both hands after wearing surgical gloves. In the surgical ward, the nurses were informed to keep a latex-free environment and to avoid spraying the disinfectant (Synergen®) in close vicinity to the patient. The rest of the hospital stay was unremarkable. She returned home 8 days later and resumed her job 3 weeks after surgery.

Nine weeks after surgery, a skin prick test with latex produced a 9-mm wheal and a 30-mm flare at 15 min (Stallergen). This was considered a positive result, because the histamine control gave a wheal of 4 mm and no reaction was seen in two control subjects at any concentration. Further skin testing (prick and intradermal tests) was negative with all substances to which the patient was exposed into the perioperative period, namely, thiopental, midazolam, cefuroxime, penicillin, hydroxyethyl starch, methyl paraben, bupivacaine, lidocaine, rocuronium, and chlorhexidine as well as any compounds contained in the disinfectant spray (methyl-ethyl-cetone, didecyl-dimethyl-ammonium-chloride, ethanol, and isopropanol). On the basis of these results, the patient was advised to avoid specific disinfectant products and to maintain a latex-free environment at her workplace.

In our hospital, to avoid room air pollution with potentially deleterious reactive chemicals, the medical safety committee has issued guidelines for the handling of disinfectants, warning against the application of any vaporized form.

This article is accompanied by an Editorial View. Please see: Moss J: Allergic to anesthetics. ANESTHESIOLOGY 2003; 99:521-3.

\*Department of Anesthesiology, Pharmacology, and Surgical Intensive Care, †Associate Professor, Unit of Thoracic Surgery, ‡Associate Professor of Anaesthesiology, §Staff Anesthesiologist, Division of Anesthesiology.

Received from the University Hospital, Geneva, Switzerland. Submitted for publication November 11, 2002. Accepted for publication April 18, 2003. Support was provided solely from institutional and/or departmental sources.

Address reprint requests to Dr. Licker: Département d'Anesthésiologie, Pharmacologie et Soins Intensifs Chirurgicaux, Hôpital Universitaire, rue Micheli-Ducrest, CH-1211 Genève 14, Switzerland. Address electronic mail to: Marc.Joseph.Licker@hcuge.ch. Individual article reprints may be purchased through the Journal Web site, www.anesthesiology.org.

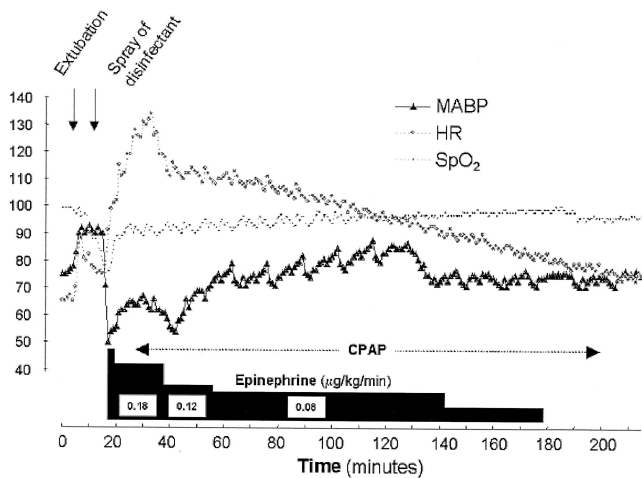


Fig. 1. Time course of mean arterial blood pressure (MABP), heart rate (HR), and oxygen saturation measured by pulse oximetry ( $SpO_2$ ) after tracheal extubation.

## Discussion

This report illustrates the postoperative acute onset of severe asthma, followed by cardiovascular collapse and skin rash after inhalation of disinfectant compounds, in a patient with the unsuspected diagnosis of latex allergy.

In connection with anesthesia, mild signs such as flushing and skin rash are rarely considered significant, because many drugs have histamine-releasing properties. Nevertheless, assessment of patients with major intraoperative anaphylaxis should include a thorough review of any previous allergic or irritative reactions, objective documentation of clinical signs and biologic response, and performance of specific allergic tests 6–8 weeks after the event.

On the basis of clinical history, skin tests, and IgE assays, latex is a frequent cause of intraoperative anaphylaxis, ranking second after neuromuscular blocking drugs.<sup>4,5</sup> In allergic subjects, direct epidermal or mucous contact with latex-containing materials provokes IgE-mediated degranulation of mastocytes accompanied by clinical signs ranging from mild cutaneous eruption to severe cardiopulmonary disturbances. Typically, a short time delay (minutes) elapses between antigen exposure and the onset of cardiopulmonary signs in a sensitized subject.

Sensitized patients often have multiple episodes of anaphylaxis before the correct agent is clearly identified. Hospital workers are regularly exposed to latex-containing products and toxic substances (*e.g.*, disinfectant) that may be implicated in various allergic and irritative reactions.<sup>1,5,6</sup> Recently, life-threatening anaphylactic reactions to chlorhexidine have also been described, particularly among patients requiring repeated invasive procedures.<sup>2,7</sup>

In our patient, mild signs of contact dermatitis had been overlooked at the preoperative consultation and a

perioperative latex-free environment was not deemed necessary. After surgery, the diagnosis of latex hypersensitivity was clearly documented by immunologic testing, although no acute symptom was elicited by direct contact with the face mask, oral airway, bronchial tube, ventilation circuit, urinary catheter, perfusion lines, or surgical gloves, which all contained latex.

A striking clinical feature was the close temporal association between a routine cleaning procedure near the extubated patient and the onset of life-threatening manifestations. Although immune hypersensitization to several reactive chemicals contained in surface disinfectant has been reported in anecdotal clinical cases,<sup>8,9</sup> allergologic investigations were all negative for intravenous drugs, surface disinfectants (including chlorhexidine), and cleaning substances, except for latex.

Several arguments suggest that inhalation of sprayed forms of disinfectant products could trigger the observed sequence of respiratory, cardiovascular, and cutaneous abnormalities. First, clinical history confirmed the hyperreactivity of the patient's airway to the same disinfectant, characterized by dry cough and dyspnea<sup>10</sup>; high airway concentrations of water-soluble substances like quaternary amines (didecyl-dimethyl-ammonium-chloride) contained in most disinfectants are known to induce reversible upper airways constriction in susceptible subjects, a so-called reactive airway dysfunction syndrome.<sup>11</sup> Second, chronic or repeated exposure to nonallergenic and irritant substances included in disinfectants has been shown to enhance IgE sensitization to common allergens (*e.g.*, latex) and has been identified as a risk factor for atopy and airway constriction.<sup>12</sup> Third, didecyl-dimethyl-ammonium-chloride is a polycationic agent whose interaction with membrane surface receptors has been shown to potentiate the release of IgE-dependent histamine from mastocytes and therefore to amplify the acute response to immunogenic agents.<sup>13</sup> Fourth, the release of inflammatory mediators (*e.g.*, cytokines, prostanoids) as a result of surgical manipulation, ischemia-reperfusion injury, and stress failure of the alveolar-capillary barrier could also amplify the anaphylactic response and its clinical manifestations.<sup>14</sup>

Taken together, these data suggest that "silent" hypersensitivity to latex could possibly be aggravated or unmasked by concomitant airway challenge with quaternary amines acting as coallergens in the context of surgical stress, airway instrumentation, and one-lung ventilation. Although intraoperative exposure to multiple latex-containing products failed to provoke an immediate allergic reaction, inhalation of disinfectant substances shortly after tracheal extubation was associated with the development of the full scale of acute respiratory, hemodynamic, and cutaneous manifestations.

## References

- Lieberman P: Anaphylactic reactions during surgical and medical procedures. *J Allergy Clin Immunol* 2002; 110:64-9
- Garvey LH, Roed-Petersen J, Husum B: Anaphylactoid reactions in anesthetized patients: Four cases of chlorhexidine allergy. *Acta Anaesthesiol Scand* 2001; 45:1290-4
- Boulet LP: Increases in airway responsiveness following acute exposure to respiratory irritants: Reactive airway dysfunction syndrome or occupational asthma? *Chest* 1988; 94:476-81
- Beach JR: Immunologic versus toxicologic mechanisms in airway responses. *Occup Med* 2000; 15:455-70
- Laxenaire MC, Mertes PM: Anaphylaxis during anaesthesia: Results of a two-year survey in France. *Br J Anaesth* 2001; 87:549-58
- Pollard RJ, Layon AJ: Latex allergy in the operating room: Case report and a brief review of the literature. *J Clin Anesth* 1996; 8:161-7
- Knight BA, Puy R, Douglas J, O'Hehir RE, Thien F: Chlorhexidine anaphylaxis: A case report and review of the literature. *Intern J Med* 2001; 31:436-7
- Bernstein JA, Stauder T, Bernstein DI, Bernstein IL: A combined respiratory and cutaneous hypersensitivity syndrome induced by work exposure to quaternary amines. *J Allergy Clin Immunol* 1994; 94:257-9
- Foreman JC, Lichtenstein LM: Induction of histamine secretion by polycations. *Biochim Biophys Acta* 1980; 22:587-603
- Brooks SM, Weiss MA, Bernstein IL: Reactive airways dysfunction syndrome (RADS): Persistent asthma syndrome after high level irritant exposures. *Chest* 1985; 88:376-84
- Purohit A, Kopferschmitt-Kubler MC, Moreau C, Popin E, Blaumeiser M, Pauli G: Quaternary ammonium compounds and occupational asthma. *Int Arch Occup Environ Health* 2000; 73:423-7
- Preller L, Dockes G, Heederik D, Vermeulen R, Vogelzang PF, Boleij JS: Disinfectant use as a risk factor for atopic sensitization and symptoms consistent with asthma: An epidemiological study. *Eur Respir J* 1996; 9:1407-13
- Zhao Z, Baldo BA, O'Brien RM, Plomley RF: Reaction with, and fine structural recognition of polyamines by human IgE antibodies. *Mol Immunol* 2000; 37:233-40
- Levine S, Saltzman A: Anaphylaxis is enhanced by increased absorption of antigen in postinflammatory state. *Int Arch Allergy Appl Immunol* 1991; 95:207-11

Anesthesiology 2003; 99:741-3

© 2003 American Society of Anesthesiologists, Inc. Lippincott Williams &amp; Wilkins, Inc.

## Latex Anaphylaxis after Tourniquet Release during Total Knee Arthroplasty

Philippe Pirat, M.D.,\* Sandrine Lopez, M.D.,\* Frédéric Motais, M.D.,\* Marie-Caroline Bonnet, M.D.,\* Xavier Capdevila, M.D., Ph.D.†

THE risk of an anaphylactoid reaction represents 9–19% of all complications associated with anesthesia, and the rate of all perioperative deaths due to anaphylactic shock has been estimated at 5–7%.<sup>1,2</sup> In France, 16.5% of anaphylactoid reactions during anesthesia involve hypersensitivity to latex,<sup>1</sup> and cases of perioperative shock have been attributed to this allergen.<sup>3–5</sup> To the best of our knowledge, there are no previous case reports of latex anaphylaxis after tourniquet release during orthopedic surgery. Our report involves a patient who developed severe anaphylactic shock when the tourniquet was deflated after knee arthroplasty. The patient's outcome was favorable.

### Case Report

A 63-yr-old woman with a history of asthma was scheduled for total knee arthroplasty. The preoperative interview revealed no allergy to medications. However, the patient described an incident of severe generalized edema after ingesting citrus fruit. Previous operations

included appendectomy with general anesthesia, knee arthroscopy, and bunionectomy with epidural anesthesia. In each case, the intervention had gone smoothly. Medications included alprazolam and cetirizine hydrochloride for allergic rhinitis.

Following placement of a femoral catheter for continuous postoperative analgesia, general anesthesia was induced using midazolam (0.05 mg/kg), propofol (3.3 mg/kg), and sufentanil (0.4  $\mu\text{g}/\text{kg}$ ) and maintained with sevoflurane (1.1 minimal alveolar concentration) and sufentanil (0.4  $\mu\text{g} \cdot \text{kg}^{-1} \cdot \text{h}^{-1}$ ). Antibiotic prophylaxis consisting of cefamandole was administered a few minutes after orotracheal intubation. A latex-free tourniquet was placed around a cloth band applied around the proximal portion of the thigh and inflated.

After 1 h 18 min of uneventful anesthetic course, the tourniquet was deflated to check for hemostasis. Four minutes thereafter, the patient had signs of cardiovascular collapse with systolic arterial pressure of 40 mmHg, tachycardia (heart rate, 130 beats/min), severe bronchospasm with a  $\text{Paco}_2$  of 21 mmHg, and an oxygen saturation measured by pulse oximetry of 88% despite manual ventilation with 100% fractional inspired oxygen tension. Redness of the face and neck was noted. Persistence of low systolic blood pressure (50 mmHg) and bradycardia (heart rate, 37 beats/min) despite infusion of 500 ml crystalloids (lactated Ringer's solution; Baxter Viaflex, France) prompted intravenous injection of 2 mg epinephrine. These measures gradually improved the patient's hemodynamic conditions. Three and 5 min after the injection of epinephrine, systolic blood pressure increased to 75 and 80 mmHg, respectively, and heart rate decreased from 135 to 110 beats/min with a return to normal tidal volumes, end-tidal  $\text{CO}_2$ , and oxygen saturation measured by pulse oximetry. A continuous infusion of epinephrine (0.25  $\mu\text{g} \cdot \text{kg}^{-1} \cdot \text{min}^{-1}$ ) was started 5 min after the onset of shock, and 60 mg intravenous methylprednisolone was administered. The surgeon ensured that the field of operation was completely sealed off in a latex-free environment. At 30 min, blood samples for the initial atopic appraisal were obtained. This workup included determination of plasma concentrations of tryptase and histamine as well as immunoglobulins (immunoglobulin E) specific for latex. In the immediate postoperative period, the patient was extubated without problem. The continuous infusion of epinephrine was stopped within 6 h. The patient was discharged 4 days after the operation.

This article is accompanied by an Editorial View. Please see: Moss J: Allergic to anesthetics. *ANESTHESIOLOGY* 2003; 99:521-3.

\* Assistant Professor of Anesthesia and Critical Care Medicine, † Professor of Anesthesia and Critical Care Medicine, Head of Department.

Received from the Department of Anesthesiology and Critical Care Medicine, Lapeyronie University Hospital, Montpellier, France. Submitted for publication October 29, 2003. Accepted for publication April 22, 2003. Support was provided solely from institutional and departmental sources.

Address correspondence to Dr. Capdevila: Département d'Anesthésie Réanimation A, Hôpital Lapeyronie, 371, Avenue du Doyen G. Giraud, 34295 Montpellier, France. Address electronic mail to: x-capdevila@chu-montpellier.fr. Individual article reprints may be purchased through the Journal Web site, www.anesthesiology.org.



The anaphylactic nature of the shock was confirmed by analysis of the perioperative samples, which showed an increase in plasma concentrations of tryptase (immunoenzymatic dosage, UniCAP Tryptase System; Pharmacia, Paris, France) and histamine (RIA Histamine®; Immunotech, Paris, France). The tryptase concentration was 26.4 µg/l (normal value, < 12 µg/l), and the histamine concentration was 68.2 nm (normal value, < 9 nm). Latex-specific immunoglobulin E (immunoenzymatic dosage, CAP Fluorescence System®; Pharmacia) was 2.39 kU/l (normal value, < 0.35 kU/l; class 2: moderate).

At a follow-up visit 6 weeks later, the patient reported an episode of edema of the lips after eating an avocado several years earlier. Interview found no occupational exposure to latex and no history of anaphylactoid reaction to domestic products containing latex.

The patient did not react to a prick test with 0.4% phenol in saline (negative control) but had a wheal of 6 mm with a prick test with 9% codeine phosphate (positive control). Prick tests with latex were performed using two different commercial fresh natural rubber latex extracts (Stallergene® [Stallergenes Laboratories, Antony, France] and Allerbio® [AB Laboratories, Varennes-en-Argonne, France]). Both extracts yielded a positive reaction. After 15 min, Stallergene® yielded a wheal of 8 mm, and Allerbio® yielded a wheal of 5 mm. A second test for latex-specific immunoglobulin E was performed, showing a high specific immunoglobulin E concentration of 12.4 kU/l (class 3). To reinforce the suspected diagnosis, an *in vitro* study of basophil degranulation was also performed. This method uses flow cytometry to quantify the amount of CD63 induced by various antigens.<sup>6</sup> The value of basophil degranulation was 16% for latex with 1 µl Stallergene® solution and 17% for latex with 10 µl Stallergene® solution. This value was 26% for avocado with 10 µl Stallergene® solution. No degranulation was induced by a kiwi antigen. No reaction was observed during antigenic stimulation with dust mites or grass seeds. Intradermal tests were performed with the other anesthetics used for the patient, but results of these tests were negative.

## Discussion

Despite that the release of metabolically active products and mediators from the acutely ischemic leg and acute loss of volume may have contributed to hypotension, the diagnosis of anaphylactic shock reaction to latex on removal of the tourniquet was quite likely. It was based on substantial clinical and biologic evidence, including positive results of skin tests. A female predominance of anaphylactic shock during anesthesia has been reported.<sup>7</sup> The patient's history of fruit allergy and atopic disease should be emphasized.<sup>8,9</sup> When the limb was revascularized, systemic dispersal of the putative antigen was immediately followed by a severe allergic reaction (grade III) in this patient. She may have developed sensitivity to latex during previous surgical or occupational exposure. This has already been demonstrated for children<sup>10</sup> and adults.<sup>11</sup> An anaphylactic reaction has been estimated to occur in one third of all patients who have a known allergy to latex.<sup>12</sup> The originality of the current case lies in the onset by cardiovascular collapse after tourniquet release.

Very similar events have been described on release of a tourniquet after applying rifamycin to an operative wound in patients who had previously been sensitized to rifamycin.<sup>13,14</sup> In these observations, shock occurred ≈

10 min after tourniquet release. Although the delay was shorter in the current case, the clinical picture was comparable. In the cases involving rifamycin, contact between the allergen and the operative site was extensive. In our case, surgical contact primarily consisted of contact with surgical instruments. There was brief contact with the surgeon's gloves during use of the trial prosthesis and application of cement. Consequently, the embolization of very few particles of latex after removal of the tourniquet was apparently sufficient to trigger the anaphylactic reaction. The same type of mechanism has been hypothesized in cases of obstetric patients who received oxytocin infusions subsequent to endouterine contact with latex gloves.<sup>7,15-17</sup> The allergen was thought to have been abruptly forced into the circulation by the induced uterine contractions leading to the immunoglobulin E-dependent reaction.

The current case report illustrates the usefulness of a thorough preanesthesia interview with an exhaustive list of all foods documented to have cross-allergies with latex (including avocado, banana, kiwi, pineapple, passion fruit, etc<sup>6,18,19</sup>). Despite the absence of glove-related skin symptoms in our patient, the cross-reactivity between latex and avocado is obvious.<sup>20,21</sup> Recent studies have reported hevein-like protein domains responsible for major cross-reacting allergen reactions with avocado.<sup>22,23</sup> Including a list of such food allergens in the preanesthesia questionnaire is recommended.<sup>1</sup> Findings of this interview would permit efficient scheduling of an allergy workup adapted to the anticipated surgical procedure, possibly reducing the number of perioperative anaphylactic incidents. This report also provides support for the policy of immediately clearing an operative wound of latex in cases of anaphylactic shock to an agent that has not been clearly identified.

## References

1. French Society of Anesthesia and Critical Care Medicine: Clinical practice, guidelines: Reducing the risk of anaphylaxis during anaesthesia. *Ann Fr Anesth Reanim* 2002;21(suppl 1):7-23
2. Currie M, Webb RK, Williamson JA, Russel W, Mackay P: The Australian incident monitoring study: Clinical anaphylaxis: An analysis of 2000 incident reports. *Anaesth Intensive Care* 1993; 21:621-5
3. Pryor JP, Vonfricken K, Seibel R, Kauder DL, Schwab CW: Anaphylactic shock from latex allergy in a patient with a spinal trauma. *J Trauma* 2001; 50:927-30
4. Nguyen DH, Burns MW, Shapiro GG, Mayo ME, Murrey M, Mitchell ME: Intraoperative cardiovascular collapse secondary to latex allergy. *J Urol* 1991; 146:571-4
5. Merguerian PA, Klein RB, Graven MA: Intraoperative anaphylactic reaction due to latex hypersensitivity. *Urology* 1991; 38:301-4
6. Paris-Kohler A, Demoly P, Persi L, Lebel B, Bousquat J, Arnoux B: In vitro diagnosis of cypress pollen allergy by using cytofluorimetric analysis of basophils (Basotest). *J Allergy Clin Immunol* 2002; 105:339-45
7. Laxenaire MC, Mertes MP, et le Groupe d'Etudes des Réactions Anaphylactoides Péranaesthésiques: Anaphylaxis during anaesthesia: Results of a two-year survey in France. *Br J Anaesth* 2001; 87:549-58
8. Rueff F, Thomas P, Reissig G, Przybilla B: Natural rubber-latex allergy in patients not intensely exposed. *Allergy* 1998; 53:445-9
9. Brehler R, Theissen U, Mohr C, Luger T: "Latex-fruit syndrome": Frequency of cross-reacting IgE antibodies. *Allergy* 1997; 52:404-10
10. Porri F, Pradal M, Lemire C, Birnbaum J, Mege JL, Lanteaume A, Charpin D,

Vervloet D, Cambouliès J: Association between latex sensitization and repeated latex exposure in children. *ANESTHESIOLOGY* 1997; 86:599-602

11. Brown RH, Shauble JF, Hamilton RG: Prevalence of latex allergy among anaesthesiologists: Identification of sensitized but asymptomatic individuals. *ANESTHESIOLOGY* 1998; 89:292-9

12. Levy DA, Leynadier F: Latex allergy: Review of recent advances. *Current Allergy Reports* 2001; 1:32-8

13. Laxenaire MC, Mouton C, Frédéric, Viry-Babel F, Bouchon Y: Anaphylactic shock after tourniquet removal in orthopedic surgery. *Ann Fr Anesth Reanim* 1996; 15:179-84

14. Cardot E, Tillie-Leblond I, Jeannin P, Facon A, Breuil K, Patte F, Tonnel AB: Anaphylactic reaction to local administration of rifamycin SV. *J Allergy Clin Immunol* 1995; 95:1-7

15. Jorrot JC, Mercier F, Pecquet C, Jacquinet P, Conseiller C: Perioperative anaphylactic shock caused by latex. *Ann Fr Anesth Reanim* 1989; 8:278-9

16. Péchinot M: Latex hypersensitivity after cesarean section. *Ann Fr Anesth Reanim* 1997; 16:79-80

17. Seigne R: Allergies and anaesthesia (letter). *Br J Anaesth* 1997; 78:778

18. Pecquet C: Risk factors for latex allergy: Diagnostic methods for aprotinin allergy. *Ann Fr Anesth Reanim* 2002; 21:123-8

19. Reche M, Pascual CY, Vicente J, Caballero T, Martin-Munoz F, Sanchez S, Martin-Esteban M: Tomato allergy in children and young adults: Cross-reactivity with latex and potato. *Allergy* 2001; 56:1197-201

20. Moller M, Kayma M, Vieluf D, Paschke A, Steinhart H: Determination and characterization of cross-reacting allergens in latex, avocado, banana and kiwi fruit. *Allergy* 1998; 53:289-96

21. Garcia Ortiz JC, Moyano JC, Alvarez M, Bellido J: Latex allergy in fruit-allergic patients. *Allergy* 1998; 53:532-6

22. Chen Z, Posch A, Cremer R, Raulf-Heimsoth M, Baur X: Identification of hevein (Hev b 602) in hevea latex as a major cross-reacting allergen with avocado fruit in patients with latex allergy. *J Allergy Clin Immunol* 1998; 102:476-81

23. Posch A, Wheeler CH, Chen Z, Flagge A, Dunn MJ, Papenfuss F, Raulf-Heimsoth M, Baur X: Class I endochitinase containing a hevein domain is the causative allergen in latex-associated avocado allergy. *Clin Exp Allergy* 1999; 29:667-72

*Anesthesiology* 2003; 99:743-4

© 2003 American Society of Anesthesiologists, Inc. Lippincott Williams & Wilkins, Inc.

## Use of Inhaled Iloprost in a Case of Pulmonary Hypertension during Pediatric Congenital Heart Surgery

Matthias Müller, M.D.,\* Stefan Scholz, M.D.,\* Myron Kwapisz, M.D.,† Hakan Akintürk, M.D.,‡ Josef Thul, M.D.,§ Gunter Hempelmann, M.D.¶

### Case Report

IMPAIRED endothelium-dependent vasodilatation is present in children with high pulmonary flow and pressure which might be exacerbated by cardiopulmonary bypass (CPB).<sup>1,2</sup> It has been reported that an increased pulmonary vascular resistance, either directly or as a surrogate of the systemic inflammatory response after cardiopulmonary bypass, has a significant effect on the postoperative recovery of infants after cardiac operations.<sup>3</sup> Iloprost is the stable carbacyclin derivative of prostaglandin I<sub>2</sub>. The use of aerosolized prostaglandin I<sub>2</sub> has shown to be safe in healthy lambs with regard to coagulation parameters, hemodynamics, and pulmonary toxicity.<sup>4,5</sup> Inhaled iloprost has been used as a diagnostic tool to assess the vasodilator capacity of the pulmonary vascular bed in children with congenital heart disease and elevated pulmonary vascular resistance, as well as intensive care unit treatment of pulmonary hypertension in a small series of children after cardiac surgery.<sup>6</sup> In adults, inhaled iloprost has been successfully used to control pulmonary hypertension after CPB.<sup>7</sup> However, no data are available about the intraoperative use of inhaled iloprost in infants younger than 1 yr with pulmonary hypertension undergoing cardiac surgery.

A 6-month-old infant girl, weighing 3.66 kg, was scheduled for atrial and ventricular septal closure. The preoperative medical history included gestational age of 29 weeks at birth, trisomy 21, and bronchopulmonary dysplasia. Preoperative cardiac catheterization revealed an unrestrictive ostium secundum type atrial septum defect and an unrestrictive perimembranous ventricular septal defect, resulting in pulmonary hypertension with a pulmonary-to-systemic perfusion ratio (Qp/Qs) of 1.4 and a pulmonary-to-systemic vascular resistance ratio (Rp/Rs) of 0.6. The preanesthetic medication consisted of aldactone, hydrochlorothiazide, digoxin, and antibiotics. In the operating room, general anesthesia was induced with fentanyl followed by pancuronium bromide and was maintained with fentanyl (total dose, 82  $\mu\text{g} \times \text{kg}^{-1}$ ), isoflurane (maximum end-tidal concentration 0.4 vol%), and midazolam (total dose, 0.4  $\text{mg} \times \text{kg}^{-1}$ ) after starting CPB. CPB was performed using nonpulsatile flow ( $2.4 \text{ l} \times \text{min}^{-1} \times \text{m}^{-2}$ ) with a membrane oxygenator in moderate hypothermia (rectal temperature  $> 33^\circ\text{C}$ ). To maintain full CPB flow at acceptable systemic pressures, the  $\alpha$ -adrenergic antagonist urapidil (total dose, 1.0  $\text{mg} \times \text{kg}^{-1}$ ) was administered to keep the mean systemic blood pressure below 40 mmHg. Cold crystalloid cardioplegia (Bretschneider [histidine tryptophane ketoglutarate] solution, 110 ml) was given before clamping the aorta. The aortic clamping time was 65 min. During reperfusion of the heart, a loading dose of milrinone (50  $\mu\text{g} \times \text{kg}^{-1}$  over 60 min) followed by a continuous infusion of 0.5  $\mu\text{g} \times \text{kg}^{-1} \times \text{min}^{-1}$  was started. After a total CPB time of 112 min, weaning off CPB was successful at the first attempt. Inhaled iloprost (2.5  $\mu\text{g} \times \text{kg}^{-1}$  over 20 min) was administered after weaning off CPB, because the mean pulmonary artery pressure/mean systemic blood pressure ratio (Pp/Ps) was increased to 0.72 and arterial oxygen saturation was 76%, despite hyperventilation (Paco<sub>2</sub>, 30-35 mmHg) with an inspired oxygen fraction of 1.0. Iloprost was prepared from a vial of Ilomedin 50 i.v.® (Schering AG, Berlin, Germany) containing iloprost 50  $\mu\text{g}/2.5 \text{ ml}$  and was diluted with isotonic saline to obtain a concentration of iloprost 2  $\mu\text{g}/\text{ml}$ . For inhalation, 4.5 ml of iloprost 2  $\mu\text{g}/\text{ml}$  were administered using an ultrasonic nebulizer. Inhaled iloprost decreased the Pp/Ps to 0.59 and increased the oxygen saturation to 90%. The hemodynamic parameters and oxygen saturation readings are summarized in table 1. The patient was transferred with stable hemodynamic parameters to the pediatric intensive care unit. However, 120 min after terminating

\* Consultant, † Resident, Department of Anaesthesiology, Intensive Care Medicine, Pain Therapy, ‡ Consultant, Department of Cardiac and Pediatric Cardiac Surgery, § Consultant, Department of Pediatric Cardiology, and ¶ Professor and Chairman, Department of Anaesthesiology, Intensive Care Medicine, Pain Therapy, University Hospital Giessen.

Received from the Department of Anaesthesiology, Intensive Care Medicine, Pain Therapy, University Hospital Giessen, Giessen, Germany. Submitted for publication December 13, 2002. Accepted for publication March 11, 2003. Support was provided solely from departmental sources.

Address reprint requests to Dr. med. Müller: Department of Anaesthesiology, Intensive Care Medicine, Pain Therapy, University Hospital Giessen, Rudolf-Buchheim-Str. 7, 35392 Giessen, Germany. Address electronic mail to: Matthias.F.Mueller@chiru.med.uni-giessen.de. Individual article reprints may be purchased through the Journal Web site, www.anesthesiology.org.

**Table 1. Changes in Hemodynamic Parameters and Arterial Oxygen Saturation**

	Before II	End of II	60 min after II	120 min after II
Heart rate, beats/min	137	143	142	162
Systemic blood pressure, mmHg	73/58/45	73/54/41	72/54/42	62/43/35
Pulmonary artery pressure, mmHg	59/42/28	46/34/25	43/32/22	47/35/26
Pp/Ps	0.72	0.63	0.59	0.81
Arterial oxygen saturation, %	76	90	90	89

II = inhaled iloprost; Pp/Ps = mean pulmonary artery pressure/mean systemic blood pressure ratio.

inhalational therapy with iloprost, the Pp/Ps increased again to 0.81. The postoperative course was complicated by recurrent pulmonary hypertensive crises during recovery from anesthesia that required prolonged sedation, relaxation, and nonselective pulmonary vasodilators despite the application of inhaled nitric oxide (iNO). We speculate that this may be because of a higher sympathetic activation during recovery from anesthesia and/or a minor response to iNO. Inhaled iloprost, however, has not been used during mechanical ventilation in the pediatric intensive care unit. The patient was ventilated for 6 postoperative days and was discharged to the referring hospital on the seventh postoperative day.

## Discussion

This case report demonstrates that a single dose of inhaled iloprost ( $2.5 \mu\text{g} \times \text{kg}^{-1}$  over 20 min) may be used to decrease Pp/Ps and to improve oxygen saturation in an infant after weaning off CPB; 120 min later the Pp/Ps returned to baseline. A documented hemodynamic effect for 1 to 2 h has previously been described.<sup>8</sup> The effective dose of inhaled iloprost in infants is not clear and seems to be dependent on the clinical setting. From previous applications, we speculate that a lower dose of inhaled iloprost is not very effective in infants after weaning off CPB, who were already hyperventilated with 100% oxygen. In accordance with Rimensberger *et al.*,<sup>6</sup> we observed no decrease in systemic blood pressure even though we used a fivefold higher dose. This may be explained by our clinical setting (*i.e.*, immediately after weaning off CPB; intraoperative use of the systemic vasodilators urapidil and milrinone). Theoretically, different characteristics of the aerosol spray may result in different intrapulmonary drug depletion characteristics, which could explain the lack of spillover into systemic circulation. However, we used a tested ultrasonic nebulizer (Optineb®; Nebu-Tec, Elsenfeld, Germany) that provided an aerosol with a mass median aerodynamic diameter of the droplets of  $3.4 \mu\text{m}$ .

Although iNO is widely used to decrease pulmonary vascular resistance in infants undergoing cardiac surgery, the effects of iNO vary among patients and cum-

bersome devices are necessary to administer iNO safely.<sup>9,10</sup> Furthermore, rebound phenomena have been described with iNO withdrawal, bearing the risk of life-threatening pulmonary hypertensive crisis (*e.g.*, during transportation to the intensive care unit).<sup>11</sup> Inhaled iloprost may, therefore, be an alternative for selective pulmonary vasodilation in infants undergoing cardiac surgery because it is effective, easy to use, and long-acting. Furthermore, from an economic point of view inhaled iloprost may be attractive because iNO became very expensive after approval by the Food and Drug Administration.

## References

- Celermajer DS, Cullen S, Deanfield JE: Impairment of endothelium-dependent pulmonary artery relaxation in children with congenital heart disease and abnormal pulmonary hemodynamics. *Circulation* 1993; 87:440-6
- Wessel DL, Adatia I, Giglia TM, Thompson JE, Kulik TJ: Use of inhaled nitric oxide and acetylcholine in the evaluation of pulmonary hypertension and endothelial function after cardiopulmonary bypass. *Circulation* 1993; 88:2128-38
- Schulze-Neick I, Li J, Penny DJ, Redington AN: Pulmonary vascular resistance after cardiopulmonary bypass in infants: Effect on postoperative recovery. *J Thorac Cardiovasc Surg* 2001; 121:1033-9
- Habler O, Kleen M, Takenaka S, Leiderer R, Pusch R, Welte M, Zwissler B, Messmer K: Eight hours' inhalation of prostacyclin (PGI<sub>2</sub>) in healthy lambs: Effects on tracheal, bronchial, and alveolar morphology. *Intensive Care Med* 1996; 22:1232-8
- Habler O, Kleen M, Zwissler B, Pusch R, Welte M, Vogelmeier C, Kempter B, Krombach F, Messmer K: Inhalation of prostacyclin (PGI<sub>2</sub>) for 8 hours does not produce signs of acute pulmonary toxicity in healthy lambs. *Intensive Care Med* 1996; 22:426-33
- Rimensberger PC, Spahr-Schopfer I, Berner M, Jaeggi E, Kalangos A, Friedli B, Beghetti M: Inhaled nitric oxide versus aerosolized iloprost in secondary pulmonary hypertension in children with congenital heart disease: Vasodilator capacity and cellular mechanisms. *Circulation* 2001; 103:544-8
- Theodoraki K, Rellia P, Thanopoulos A, Tsourelis L, Zarkalis D, Sfyarakis P, Antoniou T: Inhaled iloprost controls pulmonary hypertension after cardiopulmonary bypass. *Can J Anesth* 2002; 49:963-7
- Hoepfer MM, Olschewski H, Ghofrani HA, Wilkens H, Winkler J, Borst MM, Niedermeyer J, Fabel H, Seeger W: A comparison of the acute hemodynamic effects of inhaled nitric oxide and aerosolized iloprost in primary pulmonary hypertension. German PPH study group. *J Am Coll Cardiol* 2000; 35:176-82
- Atz AM, Wessel DL: Inhaled nitric oxide in the neonate with cardiac disease. *Semin Perinatol* 1997; 21:441-55
- Dellinger RP, Zimmerman JL, Taylor RW, Straube RC, Hauser DL, Criner GJ, Davis KJ, Hyers TM, Papadakos P: Effects of inhaled nitric oxide in patients with acute respiratory distress syndrome: Results of a randomized phase II trial. Inhaled Nitric Oxide in ARDS Study Group. *Crit Care Med* 1998; 26:15-23
- Atz AM, Adatia I, Wessel DL: Rebound pulmonary hypertension after inhalation of nitric oxide. *Ann Thorac Surg* 1996; 62:1759-64



## Intraoperative Management of Severe Pulmonary Hypertension during Cardiac Surgery with Inhaled Iloprost

Steffen Rex, M.D.,\* Thomas Busch, M.D.,† Manfred Vettelschoss, M.D.,‡ Lothar de Rossi, M.D.,§ Rolf Rossaint, M.D.,|| Wolfgang Buhre, M.D.\*\*

PULMONARY hypertension is an important risk factor for the development of acute right heart failure after cardiac surgery.<sup>1,2</sup> Even with early and adequate therapy, right ventricular (RV) failure is associated with increased morbidity and mortality.<sup>1,3</sup> We report the case of a patient with severe pulmonary hypertension related to aortic valve stenosis and mitral valve insufficiency who underwent combined bivalvular surgery and coronary artery bypass grafting. Pulmonary vascular resistance (PVR) was effectively decreased after the administration of inhaled iloprost before cardiopulmonary bypass (CPB) and during weaning from CPB. RV failure could be avoided and the perioperative course was uneventful.

### Case Report

A 78-yr-old female patient (height, 1.75 m; weight, 74 kg) presented with a history of syncope and congestive heart failure. Cardiac catheterization revealed severe aortic valve stenosis (aortic valve area, 0.49 cm<sup>2</sup>; mean pressure gradient 58 mmHg), mitral valve insufficiency (degree II), critical stenosis of the left main coronary artery, impaired left ventricular function, and hypokinesia of the anterior and apical left inferior wall. Furthermore, severe pulmonary hypertension was diagnosed (pulmonary artery pressure, 80/30 mmHg; mean pulmonary artery pressure, 65 mmHg; pulmonary artery occlusion pressure, 45 mmHg).

After the induction of anesthesia with sufentanil and midazolam, anesthesia was maintained with isoflurane and sufentanil. Hemodynamic monitoring consisted of arterial, central venous, and pulmonary artery catheterization. Hemodynamic parameters are presented in table 1. In addition, transesophageal echocardiography (Omniplane II T6210 probe; Sonos 5500, Philips Medical Systems, Best, The Netherlands) was performed intraoperatively. Before CPB, transesophageal echocardiography confirmed the diagnoses obtained by cardiac catheterization and revealed severe RV dysfunction. Detailed echocardiographic data are listed in table 2.

After the induction of anesthesia, nitroglycerin was administered intravenously to decrease PVR; however, the nitroglycerin was not effective (table 1). After sternotomy, PVR increased, probably because

of increased RV preload caused by the reduction in intrathoracic pressure. Therefore, we administered 12.5 µg aerosolized iloprost (Iloprostinol; Schering Deutschland GmbH, Berlin, Germany) over 15 min *via* a commercially available nebulizer (Aeroneb® Pro; Aerogen Inc., Mountain View, CA) connected to the inspiratory limb of the ventilator circuit. The administration of iloprost significantly decreased pulmonary artery pressure and PVR and was accompanied by an increase in cardiac output. CPB was performed using moderate hypothermia (30°C), and cardioplegic arrest was instituted with 2 l of crystalloid cardioplegia. The patient underwent aortic valve replacement, mitral valve repair, and aorto-coronary bypass grafting to the left anterior descending and circumflex arteries. The duration of ischemia was 140 min. After 80 min of reperfusion, 12.5 µg inhaled iloprost were again administered over 15 min. Weaning from CPB was completed after a reperfusion time of 97 min. Moderate doses of vasoactive agents were administered to achieve adequate hemodynamic parameters. Transesophageal echocardiography showed an improvement in RV-function parameters after CPB: the RV-fractional area change increased from 18% (pre-CPB) to 38% (post-CPB). The patient was transferred to the intensive care unit, and endotracheal extubation was performed 13 h postoperatively.

### Discussion

Impaired RV function is associated with a poor outcome in the surgical and nonsurgical settings.<sup>1,4</sup> The mortality of patients with combined arterial hypotension and severe RV dysfunction after CPB (defined as RV-fractional area change < 35%) can reach 86%.<sup>3</sup>

Adequate treatment of RV failure consists of different strategies. The main goal is to decrease RV afterload by using vasodilating agents. The use of intravenously applied vasodilators is limited, as they are not selective to the pulmonary circulation and often cause arterial hypotension. Therefore, the administration of selective pulmonary vasodilators such as inhaled nitric oxide and prostacyclin may be beneficial.<sup>5,6</sup> Inhaled prostacyclin seems to be the more favorable agent because of its lack of toxicity, ease of application, and reduced costs.<sup>5</sup> Iloprost is the stable carbacyclin derivative of prostacyclin and can be administered intermittently, as the hemodynamic effects of a single dose are sustained for approximately 60–120 min.<sup>7</sup> Although the plasma half-life time of intravenously administered iloprost is known (20–30 min), no pharmacokinetic data are available concerning the plasma half-life time and the bioavailability after administration of inhaled iloprost.<sup>8</sup>

Similar to inhaled prostacyclin, inhaled iloprost causes a more pronounced increase in cardiac output and a

\* Resident, § Staff Anesthesiologist, || Professor and Chairman, \*\* Associate Professor, Department of Anesthesiology, University Hospital, Technical University Aachen. † Associate Professor, ‡ Staff Surgeon, Department of Thoracic and Cardiovascular Surgery, University Hospital.

Received from the Department of Anesthesiology, University Hospital, Technical University Aachen, Aachen, Germany. Submitted for publication January 7, 2003. Accepted for publication May 1, 2003. Support was provided solely from institutional and departmental sources.

Address reprint requests to Dr. Rex: Klinik für Anästhesiologie, Universitätsklinikum der RWTH Aachen, Pauwelsstr. 30, D-52074 Aachen, Germany. Address electronic mail to: srex@ukaachen.de. Individual article reprints may be purchased through the Journal Web site, [www.anesthesiology.org](http://www.anesthesiology.org).

**Table 1. Hemodynamic Data**

	Preoperative*	Pre-CPB			Post-CPB†	
		After Anesthesia Induction	Chest Open	After 12.5 µg Inhaled Iloprost	Chest Open	Chest Closed
MAP, mmHg	100	78	72	62	66	57
CVP, mmHg	10	15	11	8	13	13
MPAP, mmHg	65	43	42	21	33	29
PAOP, mmHg	45	30	23	14	17	14
TPG, mmHg	20	13	19	7	15	15
HR, min <sup>-1</sup>	80	60	77	66	87	83
CO, l/min	3.5	2.5	2.5	5.2	5.7	5.0
SV, ml	32	41	32	78	65	60
SVR, dyne · s · cm <sup>-5</sup>	2,057	2,016	1,952	830	743	704
PVR, dyne · s · cm <sup>-5</sup>	457	416	608	107	224	240
PVR/SVR ratio	0.22	0.21	0.31	0.13	0.30	0.34
Epinephrine, µg · kg <sup>-1</sup> · min <sup>-1</sup>					0.07	0.07
Norepinephrine, µg · kg <sup>-1</sup> · min <sup>-1</sup>					0.05	0.05
Nitroglycerin, µg · kg <sup>-1</sup> · min <sup>-1</sup>			1	1		
Milrinone, µg · kg <sup>-1</sup> · min <sup>-1</sup>					0.5	0.25

\* Data obtained by cardiac catheterization. † After 12.5 µg of inhaled iloprost.

CO = cardiac output; CPB = cardiopulmonary bypass; CVP = central venous pressure; HR = heart rate; MAP = mean arterial pressure; MPAP = mean pulmonary artery pressure; PAOP = pulmonary artery occlusion pressure; PVR = pulmonary vascular resistance; SV = stroke volume; SVR = systemic vascular resistance; TPG = transpulmonary gradient (MAP – PAOP).

greater degree of PVR-reduction when compared with inhaled nitric oxide.<sup>7</sup> Inhaled iloprost has been successfully used in the long-term therapy of pulmonary hypertension and in the testing of pulmonary vascular responsiveness.<sup>9,10</sup> To our knowledge, only three reports are available concerning the use of inhaled iloprost during cardiac surgery, two of them in patients awaiting or having undergone heart transplantation.<sup>11-13</sup>

In the present case, we used inhaled iloprost as part of a stepwise approach to prevent RV failure in a patient with severe pulmonary hypertension undergoing combined valve surgery and coronary artery bypass grafting.

**Table 2. Intraoperative Changes for Hemodynamic Data Obtained by Transesophageal Echocardiography**

	Pre-CPB*	Post-CPB†
LV-EDA, cm <sup>2</sup>	32.3	27.0
LV-ESA, cm <sup>2</sup>	24.0	21.6
LV-FAC, %	25.70	20
LVVD, ml	118	86.5
LVVS, ml	63.3	60.7
LVEF, %	46.36	29.83
LVIDD, cm	5.00	5.26
LVIDS, cm	3.01	3.74
FS, %	39.80	28.90
RV-EDA, cm <sup>2</sup>	18.7	7.74
RV-ESA, cm <sup>2</sup>	15.3	4.83
RV-FAC, %	18.18	37.60

Mid-esophageal four-chamber view and the short axis of transgastric view were evaluated.

\* Closed chest, before administration of iloprost. † Closed chest, after administration of 12.5 µg inhaled iloprost.

CPB = cardiopulmonary bypass; EDA = end-diastolic area; EF = ejection fraction (determined by "Simpson's rule"); ESA = end-systolic area; FAC = fractional area change; FS = fractional shortening; IDD = end-diastolic inner diameter; IDS = end-systolic inner diameter; LV = left ventricular; RV = right ventricular; VD = end-diastolic volume; VS = end-systolic volume.

Administration of inhaled iloprost before CPB showed that the substance acted as an effective pulmonary vasodilator in our patient. Despite a concomitant decrease in mean arterial pressure and systemic vascular resistance (SVR), iloprost led to a more pronounced reduction of pulmonary artery pressure and PVR, so that the PVR/SVR ratio was remarkably decreased before CPB. During reperfusion, iloprost was again administered. PVR and pulmonary artery pressure were significantly decreased when compared with the preoperative values. However, the PVR/SVR ratio was increased after CPB, which can be attributed to an increase of PVR due to CPB-induced pulmonary vascular injury and to a decrease in SVR. Reduction of SVR after CPB is a well-known phenomenon mainly caused by hemodilution and activation of inflammatory mechanisms by extracorporeal circulation. The additional use of milrinone contributed to the decrease in SVR.

We used inhaled iloprost during weaning from CPB as an integral part of the therapy and not as a rescue medication. This is in contrast to other case reports, in which inhaled nitric oxide, prostacyclin, or iloprost were used after RV failure had already occurred.<sup>14,15</sup> The most effective dose and the best time for the administration of iloprost are still unknown. We used a dose of iloprost that is within the range described in the literature,<sup>7,11</sup> and we administered the second dose before starting the weaning from CPB. Thus, an effective RV unloading could be expected in the immediate post-CPB period. RV failure with the need for an excessive dosage of catecholamines or even for reinstatement of CPB could be avoided. Despite the use of positive inotropic substances and surgical correction of valvular disease, echocardiographic parameters indicated a significant impair-



ment of left ventricular function after CPB, most probably caused by severe myocardial stunning. Thus, it seems unlikely that improvement of RV function was caused solely by the surgical procedure.

## References

1. Kaul TK, Fields BL: Postoperative acute refractory right ventricular failure: Incidence, pathogenesis, management and prognosis. *Cardiovasc Surg* 2000; 8:1-9
2. Zwissler B: Acute right heart failure: Etiology—pathophysiology—diagnosis—therapy. *Anaesthesist* 2000; 49:788-808
3. Reichert CL, Visser CA, van den Brink RB, Koolen JJ, van Wezel HB, Mouljin AC, Dunning AJ: Prognostic value of biventricular function in hypotensive patients after cardiac surgery as assessed by transesophageal echocardiography. *J Cardiothorac Vasc Anesth* 1992; 6:429-32
4. Bueno H, Lopez-Palop R, Bermejo J, Lopez-Sendon JL, Delcan JL: In-hospital outcome of elderly patients with acute inferior myocardial infarction and right ventricular involvement. *Circulation* 1997; 96:436-41
5. Lawson SM: Inhaled alternatives to nitric oxide. *ANESTHESIOLOGY* 2002; 96:1504-13
6. Zwissler B: Inhaled vasodilators. *Anaesthesist* 2002; 51:603-24
7. Hoepfer MM, Olschewski H, Ghofrani HA, Wilkens H, Winkler J, Borst MM, Niedermeyer J, Fabel H, Seeger W: A comparison of the acute hemodynamic effects of inhaled nitric oxide and aerosolized iloprost in primary pulmonary hypertension. German PPH study group. *J Am Coll Cardiol* 2000; 35:176-82
8. Grant SM, Goa KL: Iloprost: A review of its pharmacodynamic and pharmacokinetic properties, and therapeutic potential in peripheral vascular disease, myocardial ischaemia and extracorporeal circulation procedures. *Drugs* 1992; 43:889-924
9. Olschewski H, Simonneau G, Galie N, Higenbottam T, Naeije R, Rubin IJ, Nikkho S, Speich R, Hoepfer MM, Behr J, Winkler J, Sitbon O, Popov W, Ghofrani HA, Manes A, Kiely DG, Ewert R, Meyer A, Corris PA, Delcroix M, Gomez-Sanchez M, Siedentop H, Seeger W: Inhaled iloprost for severe pulmonary hypertension. *N Engl J Med* 2002; 347:322-9
10. Sablotzki A, Czeslick E, Schubert S, Friedrich I, Muhling J, Dehne MG, Grond S, Hentschel T: L'iloprost ameliora l'hemodynamique chez des malades souffrant d'insuffisance cardiaque chronique et d'hypertension arterielle pulmonaire [Iloprost improves hemodynamics in patients with severe chronic cardiac failure and secondary pulmonary hypertension]. *Can J Anaesth* 2002; 49:1076-80
11. Theodoraki K, Rellia P, Thanopoulos A, Tsourelis L, Zarkalis D, Sfyraakis P, Antoniou T: Inhaled iloprost controls pulmonary hypertension after cardiopulmonary bypass. *Can J Anaesth* 2002; 49:963-7
12. Langer F, Wendler O, Wilhelm W, Tscholl D, Schafers HJ: Treatment of a case of acute right heart failure by inhalation of iloprost, a long-acting prostacyclin analogue. *Eur J Anaesthesiol* 2001; 18:770-3
13. Wittwer T, Pethig K, Struber M, Hoepfer M, Harringer W, Haverich A, Franke U, Wahlers T: Aerosolized iloprost for severe pulmonary hypertension as a bridge to heart transplantation. *Ann Thorac Surg* 2001; 71:1004-6
14. Lawson SM, Doctor A, Walsh BK, Doorley PA: Inhaled prostacyclin for the treatment of pulmonary hypertension after cardiac surgery. *Crit Care Med* 2002; 30:2762-4
15. Schroeder RA, Wood GL, Plotkin JS, Kuo PC: Intraoperative use of inhaled PGI(2) for acute pulmonary hypertension and right ventricular failure. *Anesth Analg* 2000; 91:291-5