

Possible Pulmonary Gas Embolism Associated with Localized Thermal Therapy of the Liver

Ryosuke Nakayama, M.D.,* Toshiyuki Yano, M.D.,† Etsuko Mizutamari, M.D.,‡ Kazuo Ushijima, M.D.,§ Hidenori Terasaki, M.D.,||

EXTERNAL heating by conventional electric cautery or by laser provides coagulation of the tissue by conducting the heat from the surface to the inside of the tissue. Conversely, internal heating is the method for necrotizing tumor and hemostasis by means of a dielectric heating electrode, which is inserted into the tissue or tumor. The two methods of administering localized internal thermal therapy of the liver are microwave coagulation therapy (MCT)¹ and radiofrequency ablation (RFA).^{2,3}

A venous air embolism, a potential complication of surgery in the sitting position⁴ or of laparoscopy,^{5,6} is unlikely to occur during laparotomy in a horizontal position. However, we experienced a case with abrupt decreases in end-tidal carbon dioxide partial pressure (PETCO₂) and hemoglobin oxygen saturation (SpO₂) during laparotomic MCT in the left lateral recumbent position, probably due to pulmonary gas emboli. We believe that the case discussed below is the first detailed report of a pulmonary gas embolism caused by localized thermal therapy of the liver.

Case Report

A 71-yr-old man (weight, 44 kg) was scheduled to undergo right segmentectomy of the liver for the removal of a single hepatoma nodule (2 × 3 cm) under general anesthesia. The patient, classified as American Society of Anesthesiologists (ASA) physical status 2 because of emaciation, had no contributory past or family history, and the preoperative laboratory data were within normal ranges. After premedication with atropine and hydroxyzine and placement of both standard ASA monitors and an intraarterial catheter, an epidural catheter was inserted at T8-T9. Anesthesia was induced with fentanyl, thiamylal, and vecuronium; thereafter, anesthesia was maintained with isoflurane in a 1:1 gas mixture of oxygen and nitrous oxide, and supplemental fentanyl and vecuronium in the left lateral decubitus position. PETCO₂ was 25-30 mmHg.

* Instructor, § Associate Professor and Vice Director, Surgical Center, Kumamoto University Hospital. † Assistant Professor, ‡ Staff Anesthesiologist, and || Professor and Chairman, Department of Anesthesiology, Kumamoto University School of Medicine.

Received from the Surgical Center, Kumamoto University Hospital, Kumamoto, Japan. Submitted for publication November 20, 2002. Accepted for publication February 13, 2003. Support was provided solely from institutional and departmental sources. Presented in part at the annual meeting of the American Society of Anesthesiologists, Orlando, Florida, October 16, 2002.

Address correspondence to Dr. Nakayama: Surgical Center, Kumamoto University Hospital, 1-1-1 Honjo, Kumamoto 860-8556, Japan. Address electronic mail to: ryosuke@kaiju.medic.kumamoto-u.ac.jp. Individual article reprints may be purchased through the Journal Web site, www.anesthesiology.org.

After the right segmentectomy, MCT (Microtaze[®] Model OT-110 M, Nippon Shoji, Osaka, Japan) was repeatedly applied to the liver for hemostasis at the output of 60 W and the frequency of 2,450 MHz for 60-120 s at a time. After several applications of MCT, an abrupt decrease in PETCO₂ from 27 to 10 mmHg occurred with concomitant decrease in SpO₂ from 100 to 96%. The blood pressure was stable, and the electrocardiogram trace showed no change. We suspected that pulmonary gas embolism caused sudden decreases in PETCO₂ and SpO₂. Immediately, nitrous oxide was discontinued and the patient was placed in a head-down position. Several minutes after the interruption of MCT, PETCO₂ and SpO₂ value returned to baseline. The patient recovered from anesthesia uneventfully, and there were no significant postoperative complications.

This case prompted us to further investigate whether gas emboli would be produced by localized internal thermal therapy of the liver. With approval from our University Ethical Committee and informed consent, eight patients, classified as ASA physical status 2, undergoing MCT (three male and one female, aged 56-70 yr, 49-70 kg; Microtaze[®] Model OT-110 M), or RFA (four male, aged 58-77 yr, 49-56 kg; Cool-tip[®], RF System, Radionics, Burlington, MA) for hepatocellular carcinoma in a supine or left lateral recumbent position were studied. None of the patients had evidence of esophageal varices. After induction of anesthesia and tracheal intubation with intravenous fentanyl, thiamylal, and vecuronium, a four-chamber view of the heart was monitored using a 5 MHz transducer (PEF-507SB[®]; Toshiba Medical, Tokyo, Japan) for a transesophageal echocardiogram. Anesthesia was maintained with inhalation of isoflurane or sevoflurane in a 1:1 gas mixture of oxygen and nitrous oxide. The output/frequencies of MCT and RFA were 60 W/2,450 MHz and 70-90 W/350-450 KHz, respectively.

In all eight cases, MCT or RFA resulted in gas bubbles in the right atrium or right ventricle. Bubbles were identified as highly echogenic dots with high mobility. A gas-bubble-like image also appeared in the left atrium and left ventricle in one patient undergoing MCT (fig. 1). The occurrence of gas emboli continued throughout the thermal intervention, then gradually decreased after the end of heating. There were, however, no remarkable changes in the other variables, including PETCO₂ during MCT or RFA.

Discussion

Venous gas emboli can occur during several types of hepatic interventions, such as electrocauterization,⁷ argon-enhanced coagulation,^{8,9} and water jet dissection.¹⁰ The present report showed the generation of gas emboli detected by transesophageal echocardiogram during hepatic surgery using MCT or RFA.

MCT has been applied clinically to obtain hemostasis during transection of the hepatic parenchyma and in the treatment of nonresectable liver cancer. Microwave electrodes induce a rapidly alternating electromagnetic field. As water molecules follow the changing polarity of the field, heat is generated within the tissue, resulting in

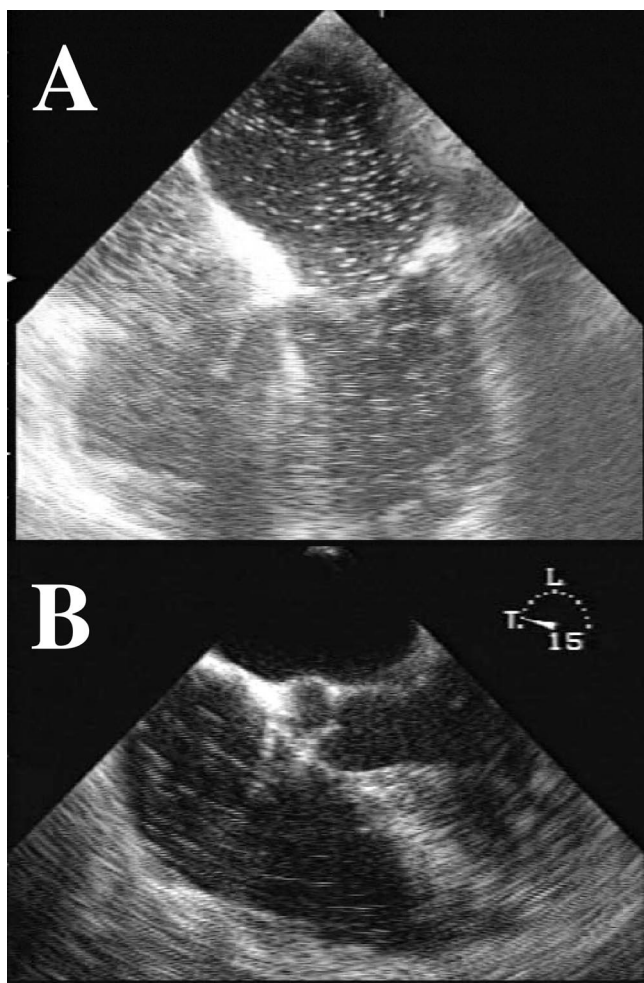


Fig. 1. Representative transesophageal two-dimensional echocardiographic images depicting intracardiac gas-like bubbles defined as hyperechoic dots. (A) During microwave coagulation therapy, many gas-like bubbles were detected in not only the right but also the left atrium and ventricle in this patient. (B) Radiofrequency ablation caused numerous gas-like bubbles in the right atrium and ventricle.

coagulation necrosis and hemostasis. RFA is a thermal technique that causes local tissue destruction by coagulation necrosis. Rather than serving as an external source of tissue heating, radiofrequency waves induce ionic

agitation, which results in frictional heat production within the tissue.

The etiology of gas emboli during these interventions is unclear. Although the exact temperature around the electrode is unknown, the electrode tip temperature will reach more than 80°C.³ We speculate that evaporation of gases, including nitrous oxide dissolved in the blood and tissue, is a cause of gas bubbles produced during MCT or RFA. Also, the entrainment of atmospheric air from the opened venous sinuses of the liver may exacerbate gas embolism during laparotomic MCT or RFA.

There have been no clinical reports on harmful embolisms caused by MCT or RFA. However, we make the following recommendations for these procedures: (1) The minimal duration of MCT or RFA application required to achieve tissue necrosis should be selected. (2) Precautions should be taken for harmful gas embolism, particularly in patients with the potential for intracardiac right to left shunt, such as persistent foramen ovale. (3) Appropriate monitors, including transesophageal echocardiography, should be used in cases in which extensive therapy is planned.

References

1. Hamazoe R, Hirooka Y, Ohtani S, Katoh T, Kaibara N: Intraoperative microwave tissue coagulation as treatment for patients with nonresectable hepatocellular carcinoma. *Cancer* 1995; 75:794–800
2. Wood BJ, Ramkaransingh JR, Fojo T, Walther MM, Libutti SK: Percutaneous tumor ablation with radiofrequency. *Cancer* 2002; 94:443–51
3. Solbiati L, Goldberg SN, Ierace T, Livraghi T, Meloni F, Dellanoce M, Sironi S, Gazelle GS: Hepatic metastases: Percutaneous radio-frequency ablation with cooled-tip electrodes. *Radiology* 1997; 205:367–73
4. Papadopoulos G, Kuhly P, Brock M, Rudolph KH, Link J, Eyrich K: Venous and paradoxical air embolism in the sitting position: A prospective study with transesophageal echocardiography. *Acta Neurochir* 1994; 126:140–3
5. Diakun TA: Carbon dioxide embolism: Successful resuscitation with cardiopulmonary bypass. *ANESTHESIOLOGY* 1991; 74:1151–53
6. Hashizume M, Takenaka K, Yanaga K, Ohta M, Kajiyama K, Shirabe K, Itasaka H, Nishizaki T, Sugimachi K: Laparoscopic hepatic resection for hepatocellular carcinoma. *Surg Endosc* 1995; 9:1289–91
7. Hatano Y, Murakawa M, Segawa H, Nishida Y, Mori K: Venous air embolism during hepatic resection. *ANESTHESIOLOGY* 1990; 73:1282–85
8. Veyckemans F, Michel I: Venous gas embolism from an Argon coagulator. *ANESTHESIOLOGY* 1996; 85:443–44
9. Palmer M, Miller CW, van Way CW III, Orton EC: Venous gas embolism associated with argon-enhanced coagulation of the liver. *J Invest Surg* 1993; 6:391–9
10. Smith JA: Possible venous air embolism with a new water jet dissector. *Br J Anaesth* 1993; 70:466–67

Neuraxial Opioids and Koebner Phenomenon: Implications for Anesthesiologists

Rajesh Mahajan, M.D.* Vinod Kumar Grover, M.D., M.N.A.M.S.†

NEURAXIAL opioids are widely used in clinical practice. However, their use is associated with various adverse effects, pruritus being prominent among them.¹ This can be distressing to the patient. In most cases pruritus has no adverse consequences. However, in patients with preexisting dermatologic disease, pruritus may lead to an exacerbation of the skin disease.^{2,3}

Case Reports

Case 1

A 42-yr-old man weighing 76 kg with a 20-yr history of psoriasis vulgaris presented for open reduction and internal fixation of a femur fracture. His dermatologic history was suggestive of remissions and relapses. His multiple therapies included topical anthralin, tar, steroids, systemic methotrexate, and phototherapy. Currently, he was receiving oral and topical steroids and anthralin. Care was taken during surgery to avoid pressure and trauma during positioning, placement of monitoring devices, securing of venous access, and administration of regional anesthesia. A combined spinal-epidural approach was used. Spinal anesthesia was performed with 3.0 ml intrathecal 0.5% heavy bupivacaine. At the end of a 90-min procedure, epidural catheter placement was validated by a preliminary dose of 3 ml lignocaine 2% with adrenaline 1:200,000. Once confirmed, 4 mg morphine in 10 ml 0.125% bupivacaine was administered into the epidural space. The patient reported good postoperative analgesic effects. Two hours after administration of epidural morphine, the patient complained of itching of his trunk, face, and legs. He also reported having nausea. Although the nausea responded to intravenous metoclopramide 10 mg, the pruritus increased in severity and the patient started scratching. Incremental intravenous doses of naloxone diluted to 0.04 mg/ml were administered, after which the patient had relief from the pruritus. The rest of the postoperative period was uneventful. However, by postoperative day 7, fresh lesions of psoriasis vulgaris had appeared on his face, trunk, and legs, corresponding to the sites of postoperative scratching. Dermatologic consultation was sought and a diagnosis of Koebner phenomenon was made. The patient was advised to continue with topical and oral steroid therapy, and photochemotherapy with psoralen and ultraviolet A was instituted. He was further followed up in the dermatology clinic.

Case 2

A 37-yr-old woman weighing 60 kg with a 9-yr history of lichen planus presented for open reduction and internal fixation of fractures

in both bones of the right leg. She was receiving treatment with topical clobetasol propionate 0.05%. A combined spinal-epidural approach was used. Spinal anesthesia was administered with mixture of 20 μ g fentanyl and 7.5 mg bupivacaine. At the end of the 2 h procedure and after validating the position of the epidural catheter, postoperative analgesia was achieved with an epidural infusion of 10 ml 0.0625% bupivacaine with fentanyl 30 μ g/h. One hour after starting the infusion, patient began having itching in the groin, anterior aspect of the trunk, and medial side of the thighs. The epidural infusion was stopped. Intravenous pheniramine was of no avail, and the patient was in great distress. Intravenous naloxone in titrated doses of 1-2 μ g/kg, to a total of 0.3 mg, relieved the itching. The rest of the postoperative period was uneventful. Patient was discharged on 6th postoperative day. However, the patient presented to the dermatology outpatient department after 10 days with exacerbation of the disease. She was found to have developed fresh lichen planus papules in a linear array, which were localized in the initial areas of pruritus; *i.e.*, groin, anterior aspect of the trunk, and medial aspect of the thighs. The patient was reassured and was advised to continue taking the topical steroids.

Discussion

Pruritus after neuraxial administration of opioids is a well-known adverse effect with a wide reported range of incidence of 0-100%.^{4,5} The incidence is higher with spinal opioids as compared with epidural opioids (46% *vs.* 8%).⁶ This compares with a very low incidence of only 1% after the systemic administration of morphine.^{1,6} Neuraxial morphine has been consistently associated with a higher incidence of pruritus than other opioids.⁷ Pruritus after neuraxial administration of opioids is unpleasant and difficult to manage. It responds poorly to histamine (H₁) blockers and other conventional treatments.⁸ Naloxone and propofol are two drugs that have been found to be effective against opioid-induced pruritus.^{9,10}

Isomorphic, or Koebner, phenomenon was described originally by Henrich Koebner in 1876.² In persons with certain skin diseases, trauma is followed by new lesions in the traumatized but otherwise normal skin, and these new lesions are identical to those in the diseased skin. Although best known in psoriasis, it may also occur in other skin diseases, notably lichen planus, lichen nitidus, pityriasis rubra pilaris, vitiligo, and Darier's disease. Koebner phenomenon usually begins 8-10 days after the injury.³ However, it may appear within 3 days or may be delayed as long as 18 days.³ Those who develop psoriasis at an early age and require multiple therapies to control their disease are more likely to develop Koebner phenomenon.¹¹ When Koebner phenomenon follows medical therapy, it may have medicolegal implications.³

* Senior Resident, † Professor, Department of Anaesthesia and Intensive Care, Postgraduate Institute of Medical Education and Research.

Received from the Department of Anaesthesia and Intensive Care, Postgraduate Institute of Medical Education and Research, Chandigarh, India. Submitted for publication September 10, 2002. Accepted for publication March 12, 2003. Financial support for this work was provided by the Postgraduate Institute of Medical Education and Research, Chandigarh, India.

Address reprint requests to Dr. Grover, Professor, Department of Anaesthesia and Intensive Care, PGIMER, Chandigarh-160012, India. Address electronic mail to: suman_vinod@yahoo.co.in. Individual article reprints may be purchased through the Journal Web site, www.anesthesiology.org.

In addition to skin trauma, various other forms of skin irritation, such as stripping of the horny layer by adhesive tape, wounding, pressure, shaving, incision, and surgery itself can provoke this phenomenon^{2,3}. Any of the above-mentioned factors could have led to exacerbation of the disease in our patients, with the appearance of new lesions. However, we took due precautions to avoid trauma to the skin and mucous membranes, and we avoided the use of strapping and adhesive electrodes. Although surgical stress can provoke Koebner phenomenon, the peculiar location of fresh lesions at the site of scratching and the linear arrangement along the scratch marks in our patients tacitly implied the itching after administration of neuraxial opioids as a causative factor.

Opioids *per se* have not been implicated to induce Koebner phenomenon. The exacerbation of the disease in our cases can be attributed to the scratching, opioids being coincidentally the cause of pruritus and, hence, scratching. This may not be uncommon in usual clinical practice. However, the late manifestation of Koebner phenomenon after the skin trauma, and the loss of contact between the anesthesiologist and the patient by this time in most of the cases, may have precluded this clinical problem being noted by the anesthesia fraternity. Furthermore, most cases of exacerbation of the disease may have been ascribed simply to various surgical factors and the stress of surgery, thereby overlooking pruritus due to the use of neuraxial opioids.

Considering the high incidence of pruritus with neuraxial opioids,^{4,5} as well as Koebner phenomenon in patients with psoriasis and lichen planus to the extent of 30–50%,^{2,3} anesthesiologists should be aware of this complication that might result from pruritus induced by neuraxial opioids.

References

1. Gustein HB, Akil H: Opioid analgesic. Goodman and Gillman's The Pharmacological Basis of Therapeutics, 10th edition. Edited by Hardman JG, Limbird LE. New York, McGraw Hill, 2001, pp 569–620
2. Falco OB, Plewig G, Wolff HH, Winkelmann RK: Dermatology, 3rd edition. New York: Springer Verlag, 1984, pp 403–6
3. Ramsay DL, Hurlay HJ: Papulosquamous eruptions and exfoliative dermatitis, Dermatology, 2nd edition. Edited by Moschella and Hurley. Philadelphia, Saunders, 1985, pp 499–556
4. Pleifer B, Sernaker H, Terhorst U: Pain scores and ventilatory and circulatory sequelae of epidural morphine in cancer patients with and without prior narcotic therapy. *Anesth Analg* 1988; 67:838–42
5. Rawal N, Schott U, Dahlstrom B, Inturrisi C, Tandon B, Sjostrand U, Wennhager M: Influence of naloxone infusion on analgesia and respiratory depression following epidural morphine. *ANESTHESIOLOGY* 1986; 64:194–201
6. Ballantyne JC, Loach ANB, Carr DB: Itching after epidural and spinal opiates. *Pain* 1988; 33:149–60
7. Ackerman W, Juneja M, Kaczorowski D, Colclough G: A comparison of the incidence of pruritus following epidural opioid administration in the parturient. *Can J Anaesth* 1989; 36:388–91
8. Cousins MJ, Mather LE: Intrathecal and epidural administration of opioids. *ANESTHESIOLOGY* 1984; 67:276–310
9. Harrison DM, Sinatra R, Morgese I, Chung JH: Epidural narcotics and patient controlled analgesia for post cesarean section pain relief. *ANESTHESIOLOGY* 1988; 68:454–7
10. Borgeat A, Wilder-Smith OHG, Saiah M, Rifat K: Subhypnotic doses of propofol relieve pruritus induced by epidural and intrathecal opioids. *ANESTHESIOLOGY* 1992; 76:510–12
11. Melski JW, Bernhard JD, Stern RS: The Koebner (isomorphic) response in psoriasis. *Arch Dermatol* 1983; 119:655–9

Anesthesiology 2003; 99:230–1

© 2003 American Society of Anesthesiologists, Inc. Lippincott Williams & Wilkins, Inc.

Psoas Abscess Complicating Femoral Nerve Block Catheter

Frédéric Adam, M.D.,* Souhail Jaziri, M.D.,† Marcel Chauvin, M.D.,‡

CONTINUOUS three-in-one blockade is widely used for providing postoperative analgesia after knee surgery. Distinct serious complications have been described after femoral nerve block: neurologic injury as well as hematoma compressive and epidural anesthesia.^{1–2} We report a case of psoas abscess complicating a continuous three-in-one blockade.

Case Report

A 35-yr-old woman, American Society of Anesthesiologists physical status 1, was admitted for a knee arthroscopic arthrolysis. Before

induction of anesthesia, a femoral catheter was placed aseptically. The anesthetist wore a cap, a face mask, and sterile gloves. The skin was prepared with 1% polyvidone iodine and was draped with sterile drape. Continuous three-in-one blockade was performed following Winnie *et al.* landmarks.³ An insulated short-beveled needle with an 18-gauge cannula (Mini Set[®]; Pajunk, Geisingen, Germany) was inserted cranially until muscle contraction in the quadriceps was observed. The needle was removed, and a 20-gauge multiorifice catheter was then easily placed. After a negative aspiration test, 20 ml of ropivacaine, 0.75%, was injected. A micropore flat bacterial filter 0.2 μ m (Portex LTD, Hythe, Kent, England) was connected to the hub of the femoral catheter, which was secured with a transparent adhesive dressing.

Postoperative analgesia was provided by a continuous infusion of ropivacaine, 0.2%, at 8 ml/h on the femoral catheter. Four days after surgery, the femoral catheter was removed. The nurse noted no evidence of superficial infection at the catheter insertion site. On the next day, the patient reported pain in her left lower quadrant associated with fever and an elevated leukocyte count. Four days after the catheter was removed, the patient remained febrile and the abdominal pain persisted. A pelvic echograph showed a psoas mass. Abscess formation was treated with computed tomographic scan-guided percutaneous puncture (fig. 1). The copious amounts of pus subsequently indicated *Staphylococcus aureus*. The infection was treated with a 1-month

* Assistant Professor, † Resident, ‡ Professor and Chair, Department of Anesthesiology, Hôpital Ambroise Paré.

Received from Hôpital Ambroise Paré, Boulogne-Billancourt, France. Submitted for publication December 27, 2002. Accepted for publication March 25, 2003. Support was provided solely from institutional and/or departmental sources.

Address reprint requests to Dr. Adam: Department of Anesthesiology, Hôpital Ambroise Paré, Assistance Public Hôpitaux de Paris, 9 Avenue Charles de Gaulle, Boulogne-Billancourt, 92100, France. Address electronic mail to: frederic.adam@apr.ap-hop-paris.fr. Individual reprints may be purchased through the Journal Web site, www.anesthesiology.org.

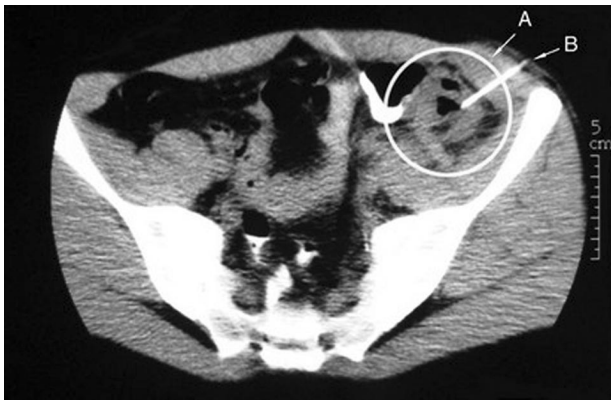


Fig. 1. Treatment of psoas abscess by percutaneous drainage under computed tomography guidance. The abscess is circled in white (A). The percutaneous puncture point is identified by B.

course of antibiotics, after which a second computed tomographic scan showed no recurrence of the psoas mass.

Discussion

The main infectious complication reported after a regional nerve block technique is the uncommon but potentially deleterious epidural abscess.⁴ Recently, it was shown that after 48 h, 57% of femoral nerve catheters had positive bacterial colonization; however, no patient developed an abscess.⁵ In our patient, a culture was not performed on the catheter because on the day of removal the patient reported no discomfort. Yet *S. aureus* found with computed tomographic scan puncture is the most common causative organism cultured from epi-

dural abscess after epidural anesthesia.⁶ Pyogenic psoas abscesses are most often associated with vertebral osteomyelitis or Crohn disease.⁷ In our patient, the abscess probably resulted from catheter colonization at a superficial site and subsequently wicked the infection from the skin to the psoas space.

This case illustrates the importance of the golden aseptic rules during puncture and catheter insertion for regional anesthesia. In any patient who shows an infectious syndrome and has or has had a continuous nerve block, the possibility of a complication of regional anesthesia should be considered until proof of the contrary, even if the patient had no evidence of superficial infection at the catheter insertion site.

References

1. Singelyn FJ, Contreras V, Gouverneur JM: Epidural anesthesia complicating continuous 3-in-1 lumbar plexus blockade. *ANESTHESIOLOGY* 1995; 83:217-20
2. Auroy Y, Benhamou D, Bargues L, Ecoffey C, Falissard B, Mercier F, Bouaziz H, Samii K: Major complications of regional anesthesia in France: The SOS Regional Anesthesia Hotline Service. *ANESTHESIOLOGY* 2002; 97:1274-80
3. Winnie AP, Ramamurthy S, Durrani Z: The inguinal paravascular technic of lumbar plexus anesthesia: The "3-in-1 block." *Anesth Analg* 1973; 52:989-96
4. Phillips JM, Stedeford JC, Hartsilver E, Roberts C: Epidural abscess complicating insertion of epidural catheters. *Br J Anaesth* 2002; 89:778-82
5. Cuvillon P, Ripart J, Lalourcey L, Veyrat E, L'Hermite J, Boisson C, Thouabtia E, Eledjam JJ: The continuous femoral nerve block catheter for postoperative analgesia: Bacterial colonization, infectious rate and adverse effects. *Anesth Analg* 2001; 93:1045-49
6. Kindler CH, Seeberger MD, Staender SE: Epidural abscess complicating epidural anesthesia and analgesia: An analysis of the literature. *Acta Anaesthesiol Scand* 1998; 42:614-20
7. Kao PF, Tsui KH, Leu HS, Tsai MF, Tzen KY: Diagnosis and treatment of pyogenic psoas abscess in diabetic patients: Usefulness of computed tomography and gallium-67 scanning. *Urology* 2001; 57:246-51