

Thiopental and Nuclear Factor κ B: Some Questions

To the Editor:—In their very interesting study, Loop *et al.*¹ demonstrate an inhibitory effect of thiopental on nuclear factor κ B (NF- κ B) activation in T cells.

However, we missed some essential background information in the discussion. First, the concentration of thiopental used in this study is much higher than plasma concentrations² noted in clinical practice or in other models presenting inhibitory effects of thiopental on interferon γ (IFN- γ) production.³ Second, the fact that thiopental suppresses NF- κ B translocation in T cells may not directly reflect general immune suppression. Regulation of cytokines in T cells is simplified in this article and may lead to false interpretation.

Therefore, it would be helpful to give some more information beyond that provided by the authors in their statement that “other transcription factors may be involved.”¹

Cytokine expression is regulated in a cell-type and stimuli-specific manner. This might explain why Loop *et al.*¹ were not able to demonstrate any effect of propofol on cytokine production or NF- κ B activation, whereas Takaono *et al.*⁴ describe inhibition of interleukin 6 (IL-6) production in lipopolysaccharide-stimulated peripheral blood mononuclear cells after propofol treatment. In the same study, thiopental (up to 200 μ g/ μ l) had no significant effect on IL-6 production.

Furthermore, the ability of transcription factors to bind DNA and modulate gene transcriptions is tightly regulated in normal cells. There are four transcription factors that play a major role in the regulation of inflammatory gene expression: activator protein 1, activating transcription factor 2, signal transducers and activators of transcription, and NF- κ B (and, in T cells, nuclear factor of activated T cells [NFAT]). The pattern of their activation regulates expression of inflammatory mediators. Inhibition of one transcription factor may include enhanced activation of another factor.⁵ Loop *et al.*¹ show that thiopental reduces the production of IL-2, IL-6, and IFN- γ in phorbol-12-myristate-13-acetate-stimulated peripheral blood mononuclear cells. The authors conclude that this is due to the inhibitory effect of thiopental on NF- κ B activation. However, the transcription of IL-2 and IFN- γ requires the activation of NFAT and activator protein 1 more than that of NF- κ B.⁶ This is of importance since NFAT is also required for transcription of IL-10, an antiinflammatory cytokine induced by thiopental.⁴ In this regard it also must be mentioned that the regulation of IFN- γ seems to be different in Jurkat cells than in “normal” T cells.⁷ In addition, the

presentation of NFAT binding in the presence of other anesthetics would have been very interesting since it has been shown that ketamine decreases cytokine production in whole blood preparations at concentrations comparable to those used by Loop *et al.*^{1,8} Furthermore, it has been shown that ketamine suppresses endotoxin-induced NF- κ B activation in other models.⁹ Therefore, it is surprising that Loop *et al.*¹ do not see any effect of ketamine on NF- κ B activation in T cells or on cytokine production in peripheral blood mononuclear cells.

Helene A. Haerberle, M.D.,* Ralph T. Kiefer, M.D. *Tuebingen University Hospital, Tuebingen, Germany. helene.haerberle@unituebingen.de

References

1. Loop T, Liu Z, Humar M, Hoetzel A, Benzing A, Pahl HL, Geiger KK, BH JP: Thiopental inhibits the activation of nuclear factor kappaB. *ANESTHESIOLOGY* 2002; 96:1202–13
2. Turcant A, Delhumeau A, Premel-Cabic A, Granry JC, Cottineau C, Six P, Allain P: Thiopental pharmacokinetics under conditions of long-term infusion. *ANESTHESIOLOGY* 1985; 63:50–4
3. Salo M, Pirttikangas CO, Pulkki K: Effects of propofol emulsion and thiopentone on T helper cell type-1/type-2 balance in vitro. *Anaesthesia* 1997; 52:341–4
4. Takaono M, Yogosawa T, Okawa-Takatsuki M, Aotsuka S: Effects of intravenous anesthetics on interleukin (IL)-6 and IL-10 production by lipopolysaccharide-stimulated mononuclear cells from healthy volunteers. *Acta Anaesthesiol Scand* 2002; 46:176–9
5. Jimenez JL, Punzon C, Navarro J, Munoz-Fernandez MA, Fresno M: Phosphodiesterase 4 inhibitors prevent cytokine secretion by T lymphocytes by inhibiting nuclear factor-kappaB and nuclear factor of activated T cells activation. *J Pharmacol Exp Ther* 2001; 299:753–9
6. Rao A, Luo C, Hogan PG: Transcription factors of the NFAT family: Regulation and function. *Annu Rev Immunol* 1997; 15:707–47
7. Sweetser MT, Hoey T, Sun YL, Weaver WM, Price GA, Wilson CB: The roles of nuclear factor of activated T cells and ying-yang 1 in activation-induced expression of the interferon-gamma promoter in T cells. *J Biol Chem* 1998; 273:34775–83
8. Kawasaki T, Ogata M, Kawasaki C, Ogata J, Inoue Y, Shigematsu A: Ketamine suppresses proinflammatory cytokine production in human whole blood in vitro. *Anesth Analg* 1999; 89:665–9
9. Sakai T, Ichijima T, Whitten CW, Giesecke AH, Lipton JM: Ketamine suppresses endotoxin-induced NF-kappaB expression. *Can J Anaesth* 2000; 47: 1019–24

(Accepted for publication September 15, 2002.)

In Reply:—We appreciate the points raised by Drs. Haerberle and Kiefer and offer the following responses.

First, Drs. Haerberle and Kiefer state that the concentration of thiopental used in our study would be “much higher than plasma concentrations noted during clinical practice or in other models presenting inhibitory effects of thiopental on IFN- γ production.” However, in addition to the study cited by them, much higher plasma concentrations of thiopental have been reported to occur in patients during long-term administration of thiopental for the treatment of intracranial hypertension—concentrations that are comparable to those used in the present study.¹ Moreover, as already pointed out in detail within the article, tissue concentrations of thiopental in organs that play a central role in the development of nosocomial infections may be even 3 to 10 times higher than the plasma concentrations.²

Second, Drs. Haerberle and Kiefer note, “inhibition of NF- κ B activation may not reflect general immune suppression.” However, we nei-

ther conclude nor state this. In our article, we wrote that our results “may provide a molecular mechanism for some of the immunosuppressing effects associated with thiopental treatment.” Nuclear factor κ B (NF- κ B) plays a crucial role in the control of the activation, proliferation, and differentiation of neutrophils, macrophages, and T and B lymphocytes.³ Therefore, the reduced function of immune cells “would be consistent with an inhibition of NF- κ B by thiopental.”

Third, the authors suggest, “it would be helpful to give some more information beyond that provided by the authors in their statement that ‘other transcription factors may be involved.’” In view of the large amount of data included within our article, communicating additional results about the effect of barbiturates on other transcription factors was far beyond the scope of the paper. However, we do have evidence that thiopental may also inhibit the nuclear factor of activated T cells in human T lymphocytes. These findings were presented at the 10th Meeting of the European Society of Anesthesiologists (2002) in Nice, France.⁴

Fourth, Drs. Haeberle and Kiefer state, "cytokine expression is regulated in a cell-type and stimuli-specific manner." We fully agree with this statement. To briefly recapitulate, we examined the effects of anesthetics in T lymphocytes on the tumor necrosis factor- dependent activation of NF- κ B, as well as the cytokine expression induced by phorbol-12-myristate-13-acetate (125 ng/ml) in mononuclear cells. Therefore, the cited study⁵ is not comparable because cytokine expression in mononuclear cells was induced by lipopolysaccharide. Likewise, in this study, the effects of thiopental were investigated at concentrations of less than 200 μ g/ml, whereas we used 400- μ g/ml thiopental. At this lower concentration, Takaono *et al.*⁵ did not note a significant effect; however, a trend toward inhibition could be observed.

Later in their letter, Haeberle and Kiefer state that "ketamine decreases cytokine production...and suppresses endotoxin-induced NF- κ B activation." These studies used whole blood,⁶ a human glioma cell line, or extracts of mice brain.⁷ Kawasaki *et al.*⁶ observed the inhibition of tumor necrosis factor-induced interleukin 6 and interleukin 8 production by ketamine at concentrations higher than 100 μ g/ml. In contrast, we used 60 μ g/ml or less ketamine in our study. Sakai *et al.*,⁷ while observing an inhibition of lipopolysaccharide-induced NF- κ B activation at 30 μ g/ml, used a glioma cell line and brain extracts in these experiments. Therefore, we believe that the comparability of these studies with ours is impaired because of the different experimental settings and the fact that cytokine expression is, indeed, "regulated in a cell-type and stimuli-specific manner."

Torsten Loop, M.D., Benedikt H. J. Pannen, M.D.* *University Hospital, Freiburg, Germany, pannen@nz.ukl.uni-freiburg.de

References

1. Neuwelt EA, Kikuchi K, Hill SA, Lipsky P, Frenkel E: Barbiturate inhibition of lymphocyte function: Differing effects of various barbiturates used to induce coma. *J Neurosurg* 1982; 56:254-9
2. Yasuda T, Yamaba T, Sawazaki K, Masuyama F, Nadano D, Takeshita H, Kishi K: Postmortem concentrations of thiopental in tissues: A sudden death case. *Int J Legal Med* 1993; 105:239-41
3. Ghosh S, May MJ, Kopp EB: NF- κ B and Rel proteins: Evolutionarily conserved mediators of immune responses. *Annu Rev Immunol* 1998; 16:225-60
4. Humar M, Pischke S, Loop T, Hoetzel A, Pahl H, Geiger K, Pannen B: Thiopental inhibits NFAT activation in human T lymphocytes (abstract). *Eur J Anaesth* 2002; 19(suppl 24):A-442
5. Takaono M, Yogasawa T, Okawa-Takatsuki M, Aotsuka S: Effects of intravenous anesthetics on interleukin (IL)-6 and IL-10 production by lipopolysaccharide-stimulated mononuclear cells from healthy volunteers. *Acta Anaesthesiol Scand* 2002; 46:176-9
6. Kawasaki T, Ogata M, Kawasaki C, Ogata J-I, Inoue Y, Shigematsu A: Ketamine suppresses proinflammatory cytokine production in human whole blood in vitro. *Anesth Analg* 1999; 89:665-9
7. Sakai T, Ichijima T, Whitten CW, Giesecke AH, Lipton JM: Ketamine suppresses endotoxin-induced NF- κ B expression. *Can J Anesth* 2000; 47:1019-24

(Accepted for publication September 15, 2002.)

Anesthesiology 2003; 98:1021-2

© 2003 American Society of Anesthesiologists, Inc. Lippincott Williams & Wilkins, Inc.

Is the Combitube Traumatic?

To the Editor:—We read with interest the article published by Keller *et al.*,¹ who tested the Combitube 37 F SA (Kendall-Sheridan Catheter Corp., Argyle, NY). Our main observations about the study are as follows.

First, contrary to their ethical consideration of not using the recommended volumes in elective surgery patients because of the high risk of trauma, the authors used much greater volumes than those they wanted to avoid. The manufacturer recommends 85 ml (not 100 ml) of air for the pharyngeal balloon and 12 ml (not 20 ml) for the distal cuff of the 37 F SA model,² which are inflation volumes for only emergency intubation. In elective cases, the minimal leakage technique should be used to minimize pressure exerted on the pharyngeal mucosa, which means that from 40 up to 85 ml and less than 12 ml, respectively, are usually sufficient to achieve a tight seal.^{3,4}

Furthermore, use of the Combitube is contraindicated when the gag reflexes are intact, as occurs in awake, nonanesthetized patients, a fact that the authors completely overlooked. This seems unethical to us because without sufficient knowledge of the basics of what they intended to test, the investigators exposed the volunteers to an increased risk of complications. In fact, all of them reported sore throat.

Second, the main implications of the study relate to the safety of using the Combitube in elective surgery patients. Other investigators⁴⁻⁶ have tested the device in such a population, concluding that elective use of the Combitube is not only safe but also reliable and feasible in most patients. Thus, the results of a study involving only four patients must be interpreted cautiously.

Third, concerning the cause of pharyngeal-esophageal lesions, although it has not been fully investigated, our impression is that, as with other procedures in anesthesia, they relate much more to the performing hands than to the device itself. According to the American Society of Anesthesiologists closed claims database,⁷ most claims for esophageal injuries were for esophageal perforation (43 of 48; 90%), which involved difficult tracheal intubation in 67% of cases (n = 29). In

addition, the intubating laryngeal mask airway⁸ has been reported to cause fatal esophageal perforation during elective general anesthesia.

Nevertheless, the authors do not label the laryngeal mask airway as risky as they so superficially did with the Combitube. The cited reports of esophageal lesions associated with Combitube use are incidental cases involving paramedics in an out-of-hospital emergency setting who, exactly like the authors themselves, did not follow the recommendations. According to the criteria of evidence-based medicine, such reports should be classified as class C evidence, and they represent a poor basis for analysis.⁹

Fourth, we missed in this study some essential qualities of good trial design, such as randomization or blind assessment of outcome.^{10,11}

In conclusion, we are alarmed that colleagues who are not very experienced with these aspects of clinical investigation might falsely interpret this article. Finally, we are worried that biased studies could overshadow serious attempts to investigate in clinical practice.

Ricardo M. Urtubia, M.D.,* Rodrigo R. Gazmuri, M.D. *Mutual de Seguridad Hospital, Santiago, Chile. rurtubia@netline.cl

References

1. Keller Ch, Brimacombe J, Boehler M, Loeckinger A, Puchringer F: The influence of cuff volume and anatomic location on pharyngeal, esophageal, and tracheal mucosal pressures with the esophageal tracheal Combitube. *ANESTHESIOLOGY* 2002; 96:1074-7
2. Frass M: The Combitube: esophageal/tracheal double lumen airway, *Airway Management: Principles and Practice*. Edited by Benumof JL. St. Louis, Mosby, 1996, pp 444-54
3. Urtubia RM, Aguila CM, Cumsille MA. Combitube: A study for proper use. *Anesth Analg* 2000; 90:958-62
4. Hartmann T, Krenn CG, Zoeggeler A, Hoerauf K, Benumof JL, Krafft P: The oesophageal-tracheal Combitube Small Adult. *Anaesthesia* 2000; 55:670-5
5. Gaitini LA, Vaida SJ, Mostafa S, Yanovski B, Croitoru M, Capdevilla MD, Sabo E, Ben-David B: The Combitube in elective surgery: A report of 200 cases. *ANESTHESIOLOGY* 2001; 94:79-82
6. Walz R, Davis S, Panning B: Is the Combitube a useful emergency airway device for anesthesiologists? *Anesth Analg* 1999; 88:233

7. Domino KB, Posner KL, Caplan RA, Cheney FW: Airway injury: A closed claim analysis. *ANESTHESIOLOGY* 1999; 91:1703-11

8. Branthwaite MA: An unexpected complication of the intubating laryngeal mask. *Anaesthesia* 1999; 54:166-7

9. Ackman ML, Druteika D, Tsuyuki RT: Levels of evidence in cardiovascular clinical practice guidelines. *Can J Cardiol* 2000; 16:1249-54

10. Todd MM: Clinical research manuscripts in anesthesiology [editorial]. *ANESTHESIOLOGY* 2001; 95:1051-3

11. Pua HL, Lerman J, Crawford MW, Wright JG: An evaluation of the quality of clinical trials in anesthesiology. *ANESTHESIOLOGY* 2001; 95:1068-73

(Accepted for publication November 4, 2002.)

Anesthesiology 2003; 98:1022

© 2003 American Society of Anesthesiologists, Inc. Lippincott Williams & Wilkins, Inc.

Is It Unethical to Use the Combitube in Elective Surgery Patients?

To the Editor:—We read with interest the article by Keller *et al.*¹ entitled "The Influence of Cuff Volume and Anatomic Location on Pharyngeal, Esophageal, and Tracheal Mucosal Pressures with the Esophageal Tracheal Combitube."

The authors used a cadaver model and healthy volunteers to measure the pressures exerted by the esophageal-tracheal Combitube 37 F SA (ETC; Kendall-Sheridan Catheter Corp., Argyle, NY) on the pharyngeal, esophageal, and tracheal mucosa. To our knowledge, this is the first description of the use of the Combitube in awake volunteers. The very low amount and concentration of local anesthetic used (10 puffs of 1% lidocaine) demonstrate the ease of esophageal insertion of the device, even in awake volunteers. We appreciate the work of the authors but want to comment on several other aspects of their paper.

The authors inflated the oropharyngeal balloon and distal cuff to a maximum volume of 100 and 20 ml, respectively, which is far above the maximum volume recommended by the manufacturer (85 and 12 ml, respectively). The authors observed relatively high mucosal pressures, potentially exceeding mucosal perfusion pressures, and do not recommend the ETC for routine anesthesia cases. However, several recent publications have clearly shown that neither the oropharyngeal balloon nor the distal cuff has to be inflated to the maximum volume recommended, and that much lower volumes are sufficient in the majority of patients.

Hartmann *et al.*² demonstrated that an oropharyngeal balloon inflation volume of 55 ± 13 ml is sufficient in the majority of patients, especially in elective surgery patients. Similar results were obtained by Urtubia *et al.*,³ and even by Keller *et al.*¹ in the present paper, because a volume of 47 ± 12 ml was enough to reach an oropharyngeal seal pressure of 30 cm H₂O. This indicates that the ETC used at low inflation volumes provides an oropharyngeal seal that can never be reached with use of a standard laryngeal mask airway (oropharyngeal leak pressure at maximum inflation, 16 cm H₂O [range, 12-19]) or even an *LMA-ProSeal*TM (Laryngeal Mask Company, San Diego, CA, USA; 27 cm H₂O [range, 21-32]).⁴

Therefore, the higher volumes used by Keller *et al.*¹ are unnecessary, potentially traumatizing, and not recommended by the manufacturer. Moreover, we assume that the incidence of pharyngeal trauma induced by the oropharyngeal balloon is more dependent on inflation velocity than on maximum inflation volume.² In experienced hands, the incidence of minor complications like traces of blood on the ETC on removal can be reduced to 27%⁵ or 10%,² and postoperative com-

plaints like dysphagia and sore throat can be reduced to 16% and 8%, respectively.^{2,3}

With regard to the cadaver data on tracheal mucosal pressure exerted by the ETC, an ETC inserted into the trachea works like a standard endotracheal tube, and therefore inflation to just-sealing volume and pressure is enough. We inserted the ETC into the trachea of three patients (body weight, 66, 80, and 87 kg) and inflated the cuff to obtain a leak pressure of 30 cm H₂O or more. The resulting sealing volumes and intracuff pressures were 4, 5, and 6 ml and 26, 31, and 32 cm H₂O, respectively. Therefore, in tracheal position the distal cuff acts as a low-pressure cuff, and inflation to a volume of up to 20 ml (approximately twice as high as recommended) not only is unnecessary but also may even result in severe tracheal damage. Moreover, the ETC almost never blindly enters the trachea in emergency situations.

In conclusion, we are not convinced that the data presented by Keller *et al.*¹ preclude the use of the Combitube 37 F SA in routine anesthesia. To the contrary, the ETC provides a very good airway seal and aspiration prophylaxis when used properly in the esophageal position. We recommend strict adherence to the manufacturer's guidelines, rather slow inflation of the oropharyngeal balloon, and use of the lowest inflation volumes (mainly in the range of 40-60 ml) to obtain an airtight seal.

Peter Krafft, M.D.,* Thomas Hartmann, M.D., Felice Agro, M.D., Luis A. Gaitini, M.D., Sonia J. Vaida, M.D. *University of Vienna, Vienna, Austria. peter.krafft@akh-wien.ac.at

References

1. Keller C, Brimacombe J, Boehler M, Loekinger A, Puehringer F: The influence of cuff volume and anatomic location on pharyngeal, esophageal, and tracheal mucosal pressures with the esophageal tracheal Combitube. *ANESTHESIOLOGY* 2002; 96:1074-7
2. Hartmann T, Krenn CG, Zoeggeler A, Hoerauf K, Benumof JL, Krafft P: The esophageal-tracheal Combitube Small Adult. *Anaesthesia* 2000; 55:670-5
3. Urtubia RM, Aguila CM, Cumsille MA: Combitube: A study for proper use. *Anesth Analg* 2000; 90:958-62
4. Keller C, Brimacombe J: Mucosal pressure and oropharyngeal leak pressure with the ProSeal versus laryngeal mask airway in anesthetized paralyzed patients. *Br J Anaesth* 2000; 85:262-6
5. Gaitini LA, Vaida SJ, Mostafa S, Yanovski B, Croitoru M, Capdevila MD, Sabo E, Ben-David B, Benumof J: The Combitube in elective surgery: A report of 200 cases. *ANESTHESIOLOGY* 2001; 94:79-82

(Accepted for publication November 4, 2002.)

Anesthesiology 2003; 98:1022-4

© 2003 American Society of Anesthesiologists, Inc. Lippincott Williams & Wilkins, Inc.

In Reply:—We would like to thank Drs. Krafft, Hartmann, Agro, Gaitini, and Vaida and Drs. Urtubia and Gazmuri for their interest in our study that demonstrated high pharyngeal and esophageal mucosal pressures with the esophageal-tracheal Combitube (ETC; Kendall-Sheridan Catheter Corp., Argyle, NY) in fresh cadavers and awake volunteers.¹ We will respond to each point in turn, dealing with the former group first.

We were aware that our maximum cuff volumes exceeded those for the small-adult ETC. In clinical practice, recommended volumes are

frequently exceeded, either by initial overinflation (both accidental and deliberate) or through nitrous oxide diffusion (and subsequent failure to limit intracuff pressure increases), and we wished to test these conditions. The maximum volumes we chose were those recommended for the normal-adult ETC. Our subjects, both living and dead, were adults of normal—not small—size.

Obviously, and as we showed in our study, an effective pharyngeal seal can be obtained at lower cuff volumes, but many patients still

Table 1. Composite Data for Directly Measured Mucosal Pressures in the Anterior (Base of Tongue), Lateral, and Posterior Pharynx for Six Modern Extraglottic Airway Devices at a Pharyngeal Seal Pressure of 30 cm H₂O or at Maximum Seal

	<i>LMA-Classic</i> TM *†	<i>LMA-ProSeal</i> TM *	Laryngeal Tube Airway (Cadaver)	Cuffed Oropharyngeal Airway†	Intubating Laryngeal Mask Airway	Esophageal Tracheal Combitube (Cadaver)‡	Esophageal Tracheal Combitube (Volunteer)‡
Lateral pharynx	3 (1–4)	10 ± 9	13 ± 13	24 (16–33)	28 (14–70)	44 ± 33	76 ± 52
Posterior pharynx	7 (1–15)	25 ± 13	41 ± 24	53 (27–78)	54 (19–90)	99 ± 62	127 ± 66
Base of tongue	11 (8–14)	23 ± 14	31 ± 16	36 (17–56)	40 (13–66)	60 ± 49	60 ± 38

Units are cm H₂O. Data from Keller *et al.*^{1,2,21,23} and Brimacombe *et al.*²²

* Laryngeal Mask Company, San Diego, CA. † Maximum seal. ‡ Kendall-Sheridan Catheter Corp., Argyle, NY.

require the maximum volume. Krafft *et al.* seem to ignore the fact that we measured mucosal pressures over the full inflation range and found that even when cuff volume was reduced to the minimum required to form a pharyngeal seal of 30 cm H₂O, mucosal pressures were still two or three times higher than mucosal perfusion pressure. A meta-analysis of data from similar studies suggests that when cuff volumes are reduced so that the pharyngeal seal is no greater than 30 cm H₂O, pharyngeal mucosal pressures for the ETC are the highest among modern extraglottic airway devices (table 1).

Krafft *et al.* suggest that a pharyngeal seal of 30 cm H₂O can never be reached with use of an *LMA-Classic*TM (Laryngeal Mask Company, San Diego, CA) or an *LMA-ProSeal*TM (Laryngeal Mask Company) and quote a study by our group in which the mean pharyngeal seals were 16 and 27 cm H₂O, respectively.² However, if the authors had read the studies more carefully they would have realized that these results were from a mixed male and female population in which the size 4 laryngeal masks were used. The mean ± SD maximum pharyngeal seal for the size 4 *LMA-Classic*TM and *LMA-ProSeal*TM in women is 21 ± 3 cm and 36 ± 6 cm H₂O,³ respectively, and the maximum pharyngeal seal for the size 5 *LMA-Classic*TM and *LMA-ProSeal*TM in men is 24 ± 5 cm⁴ and 32 ± 7 cm H₂O,⁴ respectively. These values are by no means the highest reported in the literature, and both values for the *LMA-ProSeal*TM exceed 30 cm H₂O.

Citing two studies,^{5,6} Krafft *et al.* state that the incidence of bleeding, dysphagia, and sore throat for routine anesthesia can be reduced by experienced users to 10–27%, 16%, and 8%, respectively. However, another study by experienced users showed that the incidence of bleeding, dysphagia, and sore throat was 36%, 68%, and 48%, respectively. Interestingly, in the former two studies the ETC was inserted with laryngoscopic guidance,^{5,6} and in the latter study it was inserted blindly.⁷ Perhaps it is the insertion technique rather than the experience level that reduces morbidity.

The authors imply that inflation of the distal cuff to the maximum recommended volume is safe because it “almost never blindly enters the trachea.” This statement is astonishing given that one of the authors (Dr. Agro) recently wrote a review on the ETC.⁸ A more careful analysis of the literature reveals that the mean incidence of tracheal placement when it is inserted blindly is 9% (range, 3–17%).^{9–12} Furthermore, accidental tracheal placement can occur even in an attempt to insert the distal cuff into the esophagus with laryngoscopic guidance, as demonstrated by yet another one of the authors (Dr. Gaitini).⁵

Krafft *et al.* state that the ETC provides aspiration prophylaxis when used properly in the esophageal position, but they cite no evidence. Two studies have addressed this issue. One revealed no evidence of gastroesophageal reflux, as determined by swallowed dye, but the other showed that the incidence of aspiration was 12% with the ETC in the esophageal position, as determined by tracheal pH changes. Other evidence that the esophageal cuff does not always seal off the esophagus is that gastric insufflation can still occur. One recent study showed an incidence of 2.5%.¹³ In addition, gastric rupture^{14,15} has been reported to occur with the esophageal obturator airway, which also uses an esophageal cuff. The most likely explanation for failure of the esophageal seal is that the recommended volumes are too low.

We were unable to find any data about the cuff volume required to seal off the human esophagus. The only data we could find come from a 1974 study in which a canine model was used, which showed that inflation of a Foley catheter cuff with 30 ml prevented pharyngeal regurgitation of fluid.¹⁶ The implication is that the manufacturer's recommended cuff volume of 12–20 ml may be below that which is needed to provide protection. Interestingly, our study suggested that esophageal mucosal blood flow might be impeded at cuff volumes as low as 6 ml.¹

Drs. Urtubia and Gazmuri imply that it was unethical to insert the ETC into awake volunteers because the manufacturer considers it contraindicated for patients with intact gag reflexes. However, these recommendations relate to its use in semicomatose patients and not awake volunteers. We believe that using the ETC was entirely ethical for two reasons. First, numerous studies have been conducted on other airway devices in awake volunteers with potentially intact gag reflexes; for example, Benumof¹⁷ used 60 such volunteers to test a new airway device. Second, all volunteers understood the risks involved, topical anesthesia was applied, the efficacy of topicalization was tested with a spatula, and none of the subjects (as it happened) gagged with the ETC. We used only four volunteers to minimize risk.

Urtubia and Gazmuri are somewhat contradictory in their comments, claiming on the one hand that it was unethical to use awake volunteers and claiming on the other that we should have studied more. We agree that data from only four patients should be interpreted cautiously, but the main findings of our study were based on data from 20 fresh cadavers. In our study we presented evidence that a fresh cadaver is a reasonable model of the anesthetized, paralyzed patient.¹

Urtubia and Gazmuri state that 12 ml is usually sufficient to achieve an airtight seal with the esophagus. However, as mentioned earlier, little is known about the volumes required to form an airtight seal in the esophagus. Furthermore, the distal cuff volume cannot be reduced to the minimum required to form an effective seal since there is no easy way of measuring the esophageal seal, unlike the pharyngeal seal.

Urtubia and Gazmuri state that the ETC is safe for elective surgery. To date there have been only three studies in which the ETC was used for elective surgery, and, indeed, there have been no major complications in a metapopulation of 275 patients.^{5–7} However, these numbers are too small to claim that a technique is safe. In addition, Klein *et al.*¹⁸ reported that in a patient undergoing elective surgery with the ETC as part of a clinical trial, an esophageal tear occurred after difficult blind placement. Direct trauma or increased intraluminal pressure distal to the cuff may have caused the tear. The patient underwent a thoracotomy for esophageal repair and fortunately survived. The patient was only the ninth enrolled in the study. The incidence of esophageal tearing according to data collected so far is therefore 0.4% (1 of 284), a figure that could hardly be considered to confirm the safety of use of the ETC in patients undergoing elective surgery.

Urtubia and Gazmuri state that esophageal lesions associated with the ETC are incidental cases involving paramedics in out-of-hospital emergency settings and that according to the criteria of evidence-based medicine, these reports form a poor base for analysis. However, the case of Klein *et al.*¹⁸ occurred in a prospective study performed by

anesthetists presumably adhering to the guidelines. The out-of-hospital evidence of major trauma is not just incidental. One such study showed that 0.7% of patients (8 of 1,139) developed subcutaneous emphysema,¹⁹ and another showed that major tissue trauma occurred in 0.6% (10 of 1,563).²⁰

Finally, we take offense to the authors' suggestion that our study lacked good design in terms of randomization and blinding. There was nothing to randomize and nothing to blind other than perhaps the volume of air in the cuff. Blinding with respect to whether the subject was a cadaver or an awake volunteer would have been difficult.

Joseph R. Brimacombe, M.B., Ch.B., F.R.C.A., M.D.,* Christian Keller, M.D. *Cairns Base Hospital, University of Queensland, Queensland, Australia. jbrimacombe@austarnet.com.au

References

- Keller C, Brimacombe J, Boehler M, Loeckinger A, Puehringer F: The influence of cuff volume and anatomic location on pharyngeal, esophageal and tracheal mucosal pressures with the esophageal tracheal Combitube. *ANESTHESIOLOGY* 2002; 96:1074-7
- Keller C, Brimacombe J: Mucosal pressure and oropharyngeal leak pressure with the ProSeal versus the Classic laryngeal mask airway. *Br J Anaesth* 2000; 85:262-6
- Brimacombe J, Keller C, Boehler M, Puehringer F: Positive pressure ventilation with the ProSeal versus Classic laryngeal mask airway: A randomized, crossover study of healthy female patients. *Anesth Analg* 2001; 93:1351-3
- Brimacombe J, Keller C: Stability of the ProSeal and standard laryngeal mask airway in different head and neck positions: A randomised crossover study. *Eur J Anaesthesiol* 2003; (in press)
- Gaitini LA, Vaida SJ, Mostafa S, Yanovski B, Croitoru M, Capdevila MD, Sabo E, Ben-David B, Benumof J: The Combitube in elective surgery: A report of 200 cases. *ANESTHESIOLOGY* 2001; 94:79-82
- Hartmann T, Krenn CG, Zoeggeler A, Hoerauf K, Benumof JL, Krafft P: The esophageal-tracheal Combitube Small Adult. *Anaesthesia* 2000; 55:670-5
- Oczenski W, Krenn H, Bahaba AA, Binder M, El-Schahawi-Kienzl I, Kohout S, Schwarz S, Fitzgerald RD: Complications following the use of the Combitube, tracheal tube and laryngeal mask airway. *Anaesthesia* 1999; 54:1161-5
- Agro F, Frass M, Benumof J, Krafft P, Urtubia R, Gaitini L, Giuliano I: The esophageal tracheal Combitube as a non-invasive alternative to endotracheal intubation: A review. *Minerva Anestesiologica* 2001; 67:863-74
- Frass M, Frezner R, Zdrahal F, Hoflehner G, Porges P, Lackner F: The esophageal tracheal Combitube: Preliminary results with a new airway for cardiopulmonary resuscitation. *Ann Emerg Med* 1987; 16:768-72
- Atherton GL, Johnson JC: Ability of paramedics to use the Combitube in prehospital cardiac arrest. *Ann Emerg Med* 1993; 22:1263-8
- Ochs M, Vilke GM, Chan TC, Moats T, Buchanan J: Successful prehospital airway management by EMT-IDs using the Combitube. *Prehosp Emerg Care* 2000; 4:333-7
- Wafai Y, Salem MR, Lang DJ, el-Orbani M, Podraza AG: Evaluation of a new Combitube SA [abstract]. *Anesth Analg* 1997; 84:S276
- Mercer MH, Gabbott DA: The influence of neck position on ventilation using the Combitube airway. *Anaesthesia* 1998; 53:146-50
- Crippen D, Olvey S, Graffis R: Gastric rupture: an esophageal obturator airway complication. *Ann Emerg Med* 1981; 10:370-3
- Adler J, Dykan M: Gastric rupture: An unusual complication of the esophageal obturator airway. *Ann Emerg Med* 1983; 12:224-5
- Greenbaum DM, Poggi J, Grace WJ: Esophageal obstruction during oxygen administration: A new method for use in resuscitation. *Chest* 1974; 5:188-91
- Benumof JL: The glottic aperture seal airway: A new ventilatory device. *ANESTHESIOLOGY* 1998; 88:1219-26
- Klein H, Williamson M, Sue-Ling HM, Vucevic M, Quinn AC: Esophageal rupture associated with the use of the Combitube. *Anesth Analg* 1997; 85:937-9
- Dounas M, Leon O, Bonnet V, Peyrol MT, Mercier FJ, Benhamou D: Learning placement of a new oropharyngeal intubation (Copa). *Ann Fr Anesth Reanim* 1999; 18:309-12
- Tanigawa K, Shigematsu A: Choice of airway devices for 12,020 cases of nontraumatic cardiac arrest in Japan. *Prehosp Emerg Care* 1998; 2:96-100
- Keller C, Brimacombe J: Pharyngeal mucosal pressures, airway sealing pressures, and fiberoptic position with the intubating versus the standard laryngeal mask airway. *ANESTHESIOLOGY* 1999; 90:1001-6
- Brimacombe J, Keller C, Roth W, Loeckinger A: The influence of cuff volume and anatomic location on pharyngeal mucosal pressures with the laryngeal tube airway. *Can J Anaesth* 2002; 49:1084-7
- Keller C, Brimacombe J: Mucosal pressures from the cuffed oropharyngeal airway vs the laryngeal mask airway. *Br J Anaesth* 1999; 82:922-4

(Accepted for publication November 4, 2002.)

Anesthesiology 2003; 98:1024-5

© 2003 American Society of Anesthesiologists, Inc. Lippincott Williams & Wilkins, Inc.

Myocardial Protection with Esmolol during Coronary Artery Bypass Grafting Surgery

To the Editor:—In a recent study by Booth *et al.*,¹ the authors noted improved left-ventricular function resulting from intravenous esmolol infusion in a model of myocardial ischemia-reperfusion injury and cardiopulmonary bypass (CPB). We read this article with great interest, as it contributes further evidence of the cardioprotective properties of β -blockade in an experimental model resembling the conditions of emergent coronary artery bypass grafting (CABG) surgery. However, we beg to differ with the authors' statement that "a paucity of studies exist on effectiveness, rationale, and/or mechanisms underlying the use of β AR [β -adrenergic receptor] antagonists in this setting" (*i.e.*, CABG surgery during acute myocardial ischemia).

We would like to remark that the intraoperative use of esmolol is now a well established technique of myocardial protection that was clinically introduced 10 yr ago.² A number of clinical studies have investigated the impact of intraoperative esmolol administration on outcome.³⁻⁶ We also take issue with the authors' perception that "most animal models to date have focused on CPB alone. The criticism of those models is that no human undergoes CPB alone, and therefore, the model does not reflect CABG surgery."

A number of experimental studies, some of which were conducted by our group, have investigated the impact of esmolol in models of CPB and acute myocardial ischemia-reperfusion injury and showed that esmolol improved myocardial function and reduced infarct size.⁷⁻⁹ We believe that the discussion in this otherwise excellent paper by

Booth *et al.*¹ suffers significantly from the failure to consider this previous work.

Another detail of concern is the combination of esmolol and cold crystalloid cardioplegia in the treatment group, which makes no sense from a cardiac surgeon's point of view. Intraoperative myocardial protection with esmolol is considered an alternative rather than an adjunct to cardioplegic arrest. In fact, combining both principles sacrifices the major advantages of the esmolol technique, such as the avoidance of additional global myocardial ischemia and prevention of crystalloid perfusion-induced myocardial edema.

Hans J. Geissler, M.D.,* Uwe Mehlhorn, M.D., Glen A. Laine, Ph.D., Steven J. Allen, M.D. *University of Cologne, Koeln, Germany. hans.geissler@medizin.uni-koeln.de

References

- Booth JV, Spahn DR, Mc Rae RL, Chesnut LC, El-Moalem H, Atwell DM, Leone BJ, Schwinn DA: Esmolol improves left ventricular function via enhanced β -adrenergic receptor signalling in a canine model of coronary revascularization. *ANESTHESIOLOGY* 2002; 97:162-9
- Sweeney MS, Frazier OH: Device-supported myocardial revascularization: Safe help for sick hearts. *Ann Thorac Surg* 1992; 54:1065-70
- Mehlhorn U, Sauer H, Kuhn-Regnier F, Sudkamp M, Dhein S, Eberhardt F, Grond S, Horst M, Hekmat K, Geissler HJ, Warters RD, Allen SJ, de Vivie ER: Myocardial β -blockade as an alternative to cardioplegic arrest during coronary artery surgery. *Cardiovasc Surg* 1999; 7:549-57

4. Kuhn-Regnier F, Natour E, Dhein S, Dapunt O, Geissler HJ, LaRose K, Gorg C, Mehlhorn U: Beta-blockade versus Buckberg blood-cardioplegia in coronary bypass operation. *Eur J Cardiothorac Surg* 1999; 15:67-74
5. Pirk J, Kellovsky P: An alternative to cardioplegia. *Ann Thorac Surg* 1995; 60:464-5
6. Peterzen B, Lonn U, Babi'c A, Carnstam B, Rutberg H, Casimir-Ahn H: Anesthetic management of patients undergoing coronary artery bypass grafting with the use of an axial flow pump and a short-acting beta-blocker. *J Cardiothorac Vasc Anesth* 1999; 13:431-6
7. Laub GW, Muralidharan S, Reibman J, Fernandez J, Anderson WA, Gu J, Dalosio C, McGrath LB, Mulligan LJ: Esmolol and percutaneous cardiopulmonary

bypass enhance myocardial salvage during ischemia in a dog model. *J Thorac Cardiovasc Surg* 1996; 111:1085-91

8. Geissler HJ, Davis KL, Laine GA, Ostrin EJ, Mehlhorn U, Hekmat K, Warters RD, Allen S: Myocardial protection with high-dose beta-blockade in acute myocardial ischemia. *Eur J Cardiothorac Surg* 2000; 17:63-70

9. Geissler HJ, Davis KL, Buja LM, Laine GA, Brennan ML, Mehlhorn U, Allen SJ: Esmolol and cardiopulmonary bypass during reperfusion reduce myocardial infarct size in dogs. *Ann Thorac Surg* 2001; 72:1964-9

(Accepted for publication November 4, 2002.)

Anesthesiology 2003; 98:1025

© 2003 American Society of Anesthesiologists, Inc. Lippincott Williams & Wilkins, Inc.

In Reply:—We thank Drs. Geissler, Mehlhorn, Laine, and Allen for commenting positively on our recent article.¹ We agree that the authors have contributed significantly over the past 10 yr to demonstrating the safety and efficacy of intracoronary β -adrenergic receptor (β -AR) antagonists as an alternative to cardioplegia in the setting of coronary artery bypass grafting surgery. In contrast, our study does not compare or contrast methods for administration of β -ARs during coronary artery bypass grafting surgery, but, rather, the mechanisms by which protection might occur. As such, our comments on “the paucity of data” in the area of β -AR antagonists during cardiac surgery refers to both a lack of mechanistic data demonstrating the rationale for beneficial effects and a lack of large-scale, randomized, clinical trials.

To support this claim, we cited recent American College of Cardiology and American Heart Association concerns,² as well as American College of Cardiology and American Heart Association guidelines that state that, at this time, “there is no universally applicable myocardial protection technique” for reducing the risk of perioperative myocardial dysfunction.³ Geissler *et al.* further comment that the use of intravenous esmolol as an adjunct to cold crystalloid cardioplegia (*e.g.*, rather than intracoronary esmolol) makes “no sense from a cardiac surgeon’s point of view.” However, the model used in our study was based on the common practice in the United States of intravenous β -blockade during cardiopulmonary bypass, a strategy that has recently been shown to have benefit in terms of neuroprotection in humans.⁴

Our study¹ also clearly demonstrates prevention of acute myocardial β -AR desensitization in a canine model with use of this approach. Crystalloid cardioplegia has been supplemented with many agents over the years in the quest for better myocardial protection; Geissler *et al.* have contributed in very positive ways to alternative thinking in this regard in their use of esmolol as a sole “cardioplegic” agent. Our study does not purport to answer this controversial question. Rather, our quest for understanding the mechanisms by which stress affects the

myocardium, in this case *via* β -ARs, is based on the hope that such insight may lead to novel approaches for protecting the heart during cardiac surgery in the future.

John V. Booth, M.B., Ch.B., F.R.C.A., Debra A. Schwinn, M.D.* *Duke University Medical Center, Durham, North Carolina. schwi001@mc.duke.edu

References

1. Booth JV, Spahn DR, McRae RL, Chesnut LC, El-Moalem H, Atwell DM, Leone BJ, Schwinn DA: Esmolol improves left ventricular function via enhanced β -adrenergic receptor signaling in a canine model of coronary revascularization. *ANESTHESIOLOGY* 2002; 97:162-9
2. Ryan TJ, Antman EM, Brooks NH, Califf RM, Hillis LD, Hiratzka LF, Rapaport E, Riegel B, Russell RO, Smith EE 3rd, Weaver WD, Gibbons RJ, Alpert JS, Eagle KA, Gardner TJ, Garson A Jr, Gregoratos G, Smith SC Jr: 1999 update: ACC/AHA guidelines for the management of patients with acute myocardial infarction. A report of the American College of Cardiology/American Heart Association Task Force on Practice Guidelines (Committee on Management of Acute Myocardial Infarction). *J Am Coll Cardiol* 1999; 34:890-911
3. Eagle KA, Guyton RA, Davidoff R, Ewy GA, Fonger J, Gardner TJ, Gott JP, Herrmann HC, Marlow RA, Nugent W, O'Connor GT, Orszulak TA, Rieselbach RE, Winters WL, Yusuf S, Gibbons RJ, Alpert JS, Garson A Jr, Gregoratos G, Russell RO, Ryan TJ, Smith SC Jr: ACC/AHA guidelines for coronary artery bypass graft surgery: Executive summary and recommendations: A report of the American College of Cardiology/American Heart Association Task Force on Practice Guidelines (Committee to revise the 1991 guidelines for coronary artery bypass graft surgery). *Circulation* 1999; 100:1464-80
4. Amory DW, Grigore A, Amory JK, Gerhardt MA, White WD, Smith PK, Reves JG, Schwinn DA, Newman MF: Neuroprotection is associated with β -adrenergic receptor antagonists during cardiac surgery: Suggestive evidence from 2,575 patients. *J Cardiothorac Vasc Anesth* 2002; 16:270-7

(Accepted for publication November 4, 2002.)

Anesthesiology 2003; 98:1025-6

© 2003 American Society of Anesthesiologists, Inc. Lippincott Williams & Wilkins, Inc.

Use of Recombinant Activated Factor VII in Patients with Severe Coagulopathy and Bleeding

To the Editor:—The emergence of recombinant activated factor VII (rFVIIa) as potentially a panhemostatic agent that will “save the day” for patients with severe hemorrhage is truly exciting. The positive experiences reported by Tobias,¹ Slappendel *et al.*,² and Svartholm *et al.*³ add valuable data to help define the role of this agent in clinical practice. With time, however, it is likely that we will find out that, in addition to cost advantages, there are problems and limitations associated with the use of rFVIIa. Just as antibiotics have not eliminated the need for infection control and for expert management of infections in

patients, rFVIIa will not replace the need for aggressive prevention and reversal of coagulopathy in patients.

By definition, dilutional coagulopathy suggests that insufficient coagulation factors have been given during the course of severe hemorrhage and blood product replacement. It is therefore theoretically preventable and reversible, mainly with the use of adequate amounts of fresh frozen plasma (FFP). In the first case presented by Tobias,¹ the patient was clearly having significant ongoing bleeding, as indicated by chest tube drainage, deterioration of the coagulation indices and hematocrit, and other evidence. When the international normalized ratio reached 2.0, plasma factor concentrations had probably decreased to just slightly above 30% of normal.⁴ At that point, the inadequate use of

Support was provided solely from departmental and/or institutional sources.

Anesthesiology, V 98, No 4, Apr 2003

FFP continued with the transfusion of only 1 unit of FFP in the face of ongoing bleeding.

In Tobias's¹ second case, the patient's coagulation indices at 12 h postoperatively indicated severe dilutional coagulopathy, suggesting that in the ensuing hours little or no coagulation factors were given in spite of continuing hemorrhage. From our experience and on the basis of calculations, the prevention of severe dilutional coagulopathy involves the use of FFP by the time the coagulation factors reach 40–50% of normal, and FFP must be given henceforth if significant bleeding continues, at a ratio of at least 1 unit of FFP for every unit of packed erythrocytes transfused.

In regard to the case presented by Slappendel *et al.*,² we are surprised that the patient's hemostatic parameters were not at least partially corrected before the elective surgery, especially in light of the type of surgery being performed and the use of spinal anesthesia. Intraoperatively, the use of cell saver does not prevent further dilution of coagulation factors, as is clearly reflected in the abnormal laboratory results. The appropriate action should have been the transfusion of FFP before surgery or, at the very least, as soon as bleeding started.

In the case presented by Svartholm *et al.*,³ the patient had received 19 l (equivalent by our calculation to 63 units) of packed erythrocytes and 4.5 l (18 units) of FFP. If we assume that some crystalloid or colloid solution had also been given (such that the patient's hematocrit was not excessively high due to the large amount of packed erythrocytes and the relatively small volume of FFP), then using this amount of FFP equaled transfusing whole blood with a plasma coagulation factor concentration of 30% or less. In the face of severe hemorrhage, such a low level of FFP dosing is inadequate. Prothrombin complex concentrate does not contain all of the factors. Exacerbating the situation was that another 8 l of packed erythrocytes was given over the next 11 h,

with no apparent supplementation with FFP. With coagulation factor concentrations low and continuing to dwindle, the reliance on pharmacologic supplements rather than on coagulation factor replenishment seemed inappropriate.

We respectfully suggest that in all of the aforementioned cases^{1–3} the patients might have suffered from an underdosing of FFP. This likely resulted in the transfusion of increased amounts of blood products. While we are excited by the impressive evidence accumulating on the use of rFVIIa in "refractory" bleeding, we wish to caution against an excessive and premature reliance on the use of this (or any new) technology to bail us out of difficult situations that we could have avoided getting into in the first place.

Anthony M.-H. Ho, M.Sc., M.D., F.R.C.P.C., F.C.C.P.,* Peter W. Dion, Ph.D., M.D., F.R.C.P., Manoj K. Karmakar, M.D., F.R.C.A.
*Prince of Wales Hospital, Shatin, NT, Hong Kong. hoamh@cuhk.edu.hk

References

1. Tobias JD: Synthetic factor VIIa to treat dilutional coagulopathy during posterior spinal fusion in two children. *ANESTHESIOLOGY* 2002; 96:1522–5
2. Slappendel R, Huvers FC, Benraad B, Novakova I, van Hellemond GG: Use of recombinant factor VIIa (NovoSeven) to reduce postoperative bleeding after total hip arthroplasty in a patient with cirrhosis and thrombocytopenia. *ANESTHESIOLOGY* 2002; 96:1525–7
3. Svartholm E, Annerhagen V, Lanne T: Treatment of bleeding in severe necrotizing pancreatitis with recombinant factor VIIa. *ANESTHESIOLOGY* 2002; 96:1528
4. Reiss RF: Hemostatic defects in massive transfusion: rapid diagnosis and management. *Am J Crit Care* 2000; 9:158–67

(Accepted for publication November 17, 2002.)

Anesthesiology 2003; 98:1026

In Reply:—Drs. Ho, Dion, and Karmakar suggest that hemostasis in the patients reported by Tobias,¹ Svartholm *et al.*,² and Slappendel *et al.*³ might have been achieved with administration of additional fresh frozen plasma. Ho *et al.* point out, as did I in the editorial⁴ that accompanied these reports, that recombinant activated coagulation factor VII (rFVIIa) has not been shown to be efficacious for states of dilutional coagulopathy. Parenthetically, it should be noted that when massive transfusion (one blood volume or more) is expected or achieved, use of whole blood rather than packed erythrocytes will provide the required coagulation factors and obviate or decrease the need for administration of plasma.⁵ The only currently approved use for rFVIIa is for patients who have hemophilia with inhibitors of coagulation factors VIII or IX. Part of the value of the case reports detailing "off-label" uses of rFVIIa is that the reports have provided a stimulus for the initiation of prospective, controlled, randomized, blinded studies examining the efficacy and safety of rFVIIa administered for bleeding secondary to causes other than hemophilia.

While there are sound theoretical rationales and laboratory data to suggest that rFVIIa might be efficacious for treating a variety of coagulation defects, demonstration of clinical efficacy awaits the results of these ongoing clinical trials. These trials should also produce data regarding the incidence (if any) of the possible theoretical adverse responses: vascular thrombosis and embolism, myocardial infarction, and coagulopathy resulting from intravascular coagulation. My previous comments continue to pertain: "diagnosis of the specific [hemo-

static] defect and therapy with specific coagulation factors, plasma, or platelets remain the appropriate therapies. . . ." "it would not be appropriate, at this time, to attempt to replace standard diagnostic measures and standard accepted therapy with the use of rFVIIa," and "when these measures truly fail, it may be reasonable to use rFVIIa as an attempted 'rescue' therapy."⁴

After the completion of the studies in progress, we should have sufficient data on which to base decisions regarding the relative benefits and risks of the use of rFVIIa *versus* components derived from human blood for coagulopathies unrelated to hemophilia.

Richard B. Weiskopf, M.D., University of California, San Francisco, California. weiskopf@anesthesia.ucsf.edu

References

1. Tobias JD: Synthetic factor VIIa to treat dilutional coagulopathy during posterior spinal fusion in two children. *ANESTHESIOLOGY* 2002; 96:1522–5
2. Svartholm E, Ammerhagen V, Lanne T: Treatment of bleeding in severe necrotizing pancreatitis with recombinant factor VIIa (letter). *ANESTHESIOLOGY* 2002; 96:1528
3. Slappendel R, Huvers FC, Benraad B, Novakova I, van Hellemond GG: Use of recombinant factor VIIa to reduce postoperative bleeding after total hip arthroplasty in a patient with cirrhosis and thrombocytopenia. *ANESTHESIOLOGY* 2002; 96:1525–7
4. Weiskopf R: Intraoperative use of recombinant activated coagulation factor VII. *ANESTHESIOLOGY* 2002; 96:1287–9
5. Weiskopf RB: More on the changing indications for transfusion of blood and blood components during anesthesia (editorial). *ANESTHESIOLOGY* 1996; 84:498–501

(Accepted for publication November 17, 2002.)

Dr. Weiskopf consults for Novo Nordisk A/S (Copenhagen, Denmark) regarding their product, recombinant activated coagulation factor VII.

Anesthesiology 2003; 98:1027

© 2003 American Society of Anesthesiologists, Inc. Lippincott Williams & Wilkins, Inc.

In Reply:—The reaction of Drs. Ho, Dion, and Karmakar in their letter to the editor is clear and simple: the best way to act on a dilution coagulopathy is to recognize it early and to treat it using adequate amounts of fresh frozen plasma. In our view, the main reason to avoid fresh frozen plasma or any homolog blood products in cases of orthopedic surgery¹ is also simple. Since the first human blood transfusion there have been unnecessary related risks: administration and handling mistakes², transmission viruses, transfusion reactions, and immunosuppression.^{3–7} Transfusion-related immunosuppression is considered to favor postoperative infections, to perturb postoperative wound healing, and thereby to result in a protracted hospital stay.^{3–7}

The availability of new recombinant DNA medicine, like recombinant activated factor VII, is very promising because of the nearly complete lack of side effects. We agree with Ho *et al.* that treatment with fresh frozen plasma for dilution coagulopathy is, at present, the first choice. We expect that it's only a matter of time (for double-blinded, randomized trials) and money before recombinant DNA drugs such as recombinant activated factor VII replace (classic) coagulant drugs such as aprotinin and desmopressin.

Robert Slappendel, M.D., Ph.D.,* **Frank C. Huvers, M.D., Ph.D.,** **Bart Benraad, M.D.,** **Irena Novakova, M.D., Ph.D.,** **Gijs G. van Hellemond, M.D.** *Sint Maartenskliniek, Nijmegen, The Netherlands. r.slappendel@maartenskliniek.nl

Anesthesiology 2003; 98:1027

In Reply:—We are grateful for the interesting responses to our article concerning the use of recombinant activated factor VII (rFVIIa).¹ Drs. Ho, Dion, and Karmakar discuss the place of rFVIIa in refractory bleeding and wish to caution against “premature” use of this drug or any new technology. We fully agree that all other conventional techniques or pharmaceutical agents have to be used primarily. This was also stated in the last few sentences of our report. However, we do not agree that further supplementation with only fresh frozen plasma would have saved our patient.

First, there was no tendency of hemostasis during or shortly after the fresh frozen plasma infusion. Second, there was abrupt stabilization already after administration of the first dose of rFVIIa. This indicates that the amounts of other coagulation factors were enough to stop the bleeding after rFVIIa had initiated the first step, although Ho *et al.* are correct that the amount of fresh frozen plasma given to our patient could have been increased. It has been shown that pharmacologic doses of rFVIIa enhance thrombin generation on already activated platelet surfaces on which negatively charged phospholipids are being exposed.²

Furthermore, a full thrombin burst is known to be necessary for a stable fibrin hemostatic plug to be formed. By enhancement of thrombin generation, the formation of a tight fibrin structure is ensured. In situations with increased fibrinolytic activity, which often is seen in extensive tissue damage, it may be helpful to make sure that a tight

References

1. Slappendel R, Huvers FC, Benraad B, Novakova I, van Hellemond GG: Use of recombinant factor VIIa (NovoSeven) to reduce postoperative bleeding after total hip arthroplasty in a patient with severe cirrhosis and thrombocytopenia. *ANESTHESIOLOGY* 2002; 96:1525–7
2. Linden JV, Wagner K, Voytovich AE, Sheehan J: Transfusion errors in New York State: An analysis of 10 years' experience. *Transfusion* 2000; 40:1207–13
3. Blumberg N: Allogenic transfusion and infection: Economic and clinical implications. *Semin Hematol* 1997; 34:34–40
4. Murphy P, Heal JM, Blumberg N: Infection or suspected infection after hip replacement surgery with autologous or homologous blood transfusions. *Transfusion* 1991; 31:212–7
5. Bierbaum BE, Callaghan JJ, Galante JO, et al.: An analysis of blood management in patients having a total hip or knee arthroplasty. *J Bone Joint Surg Am* 1999; 81:2–10
6. Innerhofer P, Walleczek C, Luz G, et al.: Transfusion of buffy coat-depleted blood components and risk of postoperative infection in orthopedic patients. *Transfusion* 1999; 39:625–32
7. Borghi B, Casati A: Incidence and risk factors for allogenic blood transfusion during major joint replacement using an integrated autotransfusion regimen. The Rizzoli Study Group on Orthopaedic Anaesthesia. *Eur J Anaesthesiol* 2000; 17: 411–7

(Accepted for publication November 17, 2002.)

© 2003 American Society of Anesthesiologists, Inc. Lippincott Williams & Wilkins, Inc.

fibrin plug, resistant against premature lysis, is being formed. In fact, preliminary data from the use of rFVIIa in trauma patients do suggest a beneficial effect on profuse, extensive bleeding.³

A wide range of therapeutic modalities is therefore necessary for critically ill bleeding patients, but, again, newly developed therapeutic modalities must be critically evaluated before use in clinical situations.

Erik Svartholm, M.D., Ph.D.,* **Veronica Annerhagen, M.D.,** **Toste Lanne, M.D.** *Jämköping Hospital, Jämköping, Sweden. erik.svartholm@ltjkpg.se

References

1. Svartholm E, Annerhagen V, Lanne T: Treatment of bleeding in severe necrotizing pancreatitis with recombinant factor VIIa. *ANESTHESIOLOGY* 2002; 96: 1528
2. Monroe D, Hoffmann M, Oliver J, Roberts H: Platelet activity of high-dose factor VIIa is independent of tissue factor. *Br J Haematol* 1997; 99:542–7
3. Martinowitz U, Kenet G, Segal E, Luboshitz J, Lubetsky A, Ingerslev J, Lynn M: Recombinant activated factor VII for adjunctive hemorrhage control in trauma. *J Trauma* 2001; 51:431–8

(Accepted for publication November 17, 2002.)

Propofol Preservation of Myocardial Function in Patients Undergoing Coronary Surgery Using Cardiopulmonary Bypass is Dose Dependent

To the Editor:—We read with great interest the article recently published by De Hert *et al.*¹ entitled “Sevoflurane but Not Propofol Preserves Myocardial Function in Coronary Surgery Patients.” In this study, the authors based their conclusion primarily on myocardial mechanics measured before and 15 min after cardiopulmonary bypass. Hearts were paced at 90 beats/min during the measurements. This approach makes the cardiac mechanics measured more comparable between groups.

It would be very helpful for us to know if the plasma concentration of propofol is available and/or if the hemodynamic data are comparable at 12 h or more postoperatively in this study. An experimental study has shown that the protective effect of propofol on myocardial function following global myocardial ischemia and reperfusion is dose dependent, being effective at concentrations of 30 μM or more and not effective at concentrations of 10 μM or less.² This may explain why propofol is not cardiac protective at “clinically relevant” concentrations of 1 $\mu\text{g}/\text{ml}$ (5.6 μM)³ or up to 10 μM .⁴ Our preliminary clinical study indicated that propofol is cardiac protective in a dose-dependent manner in coronary surgery patients when applied at “clinically achievable” concentrations of 4 and 11.8 $\mu\text{g}/\text{ml}$ during surgery. This was evident when the cardiac index beyond 12 h post-cardiopulmonary bypass was compared.⁵

To understand this we conducted an experiment in an isolated heart model, applying 12 $\mu\text{g}/\text{ml}$ (67 μM) propofol during global myocardial ischemia and during the early phase of reperfusion and then 5 $\mu\text{g}/\text{ml}$ after 15 min of reperfusion (to avoid the depressant effect of high-dose propofol on myocyte contraction). We have observed that this approach provides better long-term myocardial functional recovery than 5 $\mu\text{g}/\text{ml}$ propofol applied throughout ischemia and reperfusion.⁶

De Hert *et al.* should be congratulated for their efforts. They provided evidence that cardiac troponin I was significantly lower in the sevoflurane group than in the propofol group up to 36 h postoperatively, a cardiac protection probably related to the preconditioning effects of sevoflurane. It should be noted, however, that from 24 to 36 h postoperatively, cardiac troponin I levels decreased in all 10

patients in the propofol group, while they increased in 2 or 3 patients (2 of 10 or 3 of 10) in the sevoflurane group. This is a significant difference between groups.

We must point out that a decrease in heart rate and/or the depression of cardiac contraction during the early phase of reperfusion might be an integral part of the cardiac-protective effect of propofol in the long run. Given that cardiac output increased from post-cardiopulmonary bypass to the end of the operation only in the propofol group and that there was no difference in clinical outcome between groups, we feel that the statement “propofol is not myocardial protective,” as implied in the title of the article by De Hert *et al.*,¹ is somewhat misleading.

David M. Ansley, M.D.,* Zhengyuan Xia, M.D. *University of British Columbia, Vancouver, British Columbia, Canada. daansley@interchange.ubc.ca

References

1. De Hert SG, ten Broecke PW, Mertens E, Van Sommeren EW, De Blier IG, Stockman BA, Rodrigus IE: Sevoflurane but not propofol preserves myocardial function in coronary surgery patients. *ANESTHESIOLOGY* 2002; 97:42–9
2. Ko SH, Yu CW, Lee SK, Choe H, Chung MJ, Kwak YG, Chae SW, Song HS: Propofol attenuates ischemia-reperfusion injury in the isolated rat heart. *Anesth Analg* 1997; 85:719–24
3. Ebel D, Schlack W, Comfere T, Preckel B, Thamer V: Effect of propofol on reperfusion injury after regional ischaemia in the isolated rat heart. *Br J Anaesth* 1999; 83:903–8
4. Tamaki F, Oguchi T, Kashimoto S, Nonaka A, Kumazawa T: Effects of propofol on ischemia and reperfusion in the isolated rat heart compared with thiamylal. *Jpn Heart J* 2001; 42:193–206
5. Ansley DM, Sun J, Visser WA, Dolman J, Godin DV, Garnett ME, Qayumi AK: High dose propofol enhances red cell antioxidant capacity during CPB in humans. *Can J Anaesth* 1999; 46:641–8
6. Xia Z, Godin DV, Chang TKH, Ansley DM: Dose-dependent protection of cardiac function by propofol during ischemia and early reperfusion in rats: Effect of 15-F_{2t}-isoprostane formation. *Can J Physiol Pharmacol* 2003; 81:14–21

(Accepted for publication November 20, 2002.)

In Reply:—We appreciate the interest of Drs. Ansley and Xia regarding our study on the preservation of myocardial function by sevoflurane in coronary surgery patients.¹ Transient myocardial dysfunction after coronary bypass surgery is a well known phenomenon,² but its pathophysiologic mechanisms still are not fully elucidated. Although its causes are multifactorial, reperfusion injury is thought to play an important role.

Recently, increasing evidence has indicated that anesthetic agents may have a potential beneficial role in the prevention and/or treatment of reperfusion injury. Volatile anesthetics have been shown to directly precondition or indirectly enhance ischemic preconditioning, resulting in protection of the myocardium, with the adenosine triphosphate-regulated potassium channel playing an important role. Central to the pathogenesis of ischemia-reperfusion injury is the production of free radicals. Several reports have demonstrated that propofol may enhance antioxidant capacity, and this property has been claimed to protect the myocardium. However, data on this subject are essentially experimental, and, to date, few studies have demonstrated a potential beneficial

effect of anesthetic agents in myocardial stunning in the clinical situation.

For the volatile anesthetics, the beneficial effects were demonstrated on both functional hemodynamic parameters and biochemical markers of myocardial damage. For propofol, the evidence of a myocardial protective effect is mainly circumstantial. Several studies have, indeed, demonstrated that propofol increases the antioxidant capacity of erythrocytes and tissue. However, the possible implications of this increase in antioxidant capacity for preservation of tissue function remain to be demonstrated.

Ebel *et al.*³ found no protective effect of propofol (at clinically relevant concentrations) against myocardial reperfusion injury, but Ko *et al.*⁴ demonstrated that propofol at higher concentrations (100 μM) attenuated mechanical, biochemical, and histologic changes caused by myocardial ischemia and reperfusion. In a recent publication, Ansley *et al.*⁵ observed that high-dose propofol (a 2–2.5-mg/kg bolus followed by a continuous infusion of 200 $\mu\text{g} \cdot \text{kg}^{-1} \cdot \text{min}^{-1}$) enhances erythrocyte antioxidant capacity during cardiopulmonary bypass in humans. Eryth-

rocyte antioxidant capacity with low-dose propofol or isoflurane anesthesia, on the contrary, was similar.

Ansley and Xia related this increased antioxidant capacity in the high-dose propofol group to improved myocardial function (higher cardiac index) 12 h postoperatively. However, the cardiac index in the low-dose propofol group was similar, despite the difference observed in the antioxidant capacity. It seems, therefore, that the suggested relation between improved cardiac function with propofol and its antioxidant properties is not supported by the data presented. Instead, it seems more likely that differences in cardiac loading conditions are responsible for the observed differences in cardiac index between the isoflurane and propofol groups.

In our study,¹ propofol was administered by means of a target-controlled infusion system, which was set to achieve a target plasma propofol concentration of 2–4 µg/ml. This plasma concentration is far beyond the concentration at which Ansley and Xia have observed “cardioprotective” effects (12 µg/ml). Still, it is the concentration that is clinically applied in patients with compromised cardiac function, which is not the case for concentrations up to 12 µg/ml. From a clinical point of view, the agents that have potential beneficial effects on ischemia-reperfusion injury should also exert their action at clinically relevant concentrations.

Under the conditions of our study, sevoflurane at clinically relevant concentrations protected against the transient myocardial dysfunction related to coronary surgery, whereas propofol did not (lower cardiac index until the end of the operation). The suggestion that the title of

our article, “Sevoflurane but Not Propofol Preserves Myocardial Function in Coronary Surgery Patients,” is misleading is therefore not correct. The data and conclusions clearly refer to clinically relevant concentrations and do not comment on possible properties at concentrations that are much higher than those used in clinical practice.

Stefan G. De Hert, M.D., Ph.D.,* Pieter W. ten Broecke, M.D., Inez E. Rodrigus, M.D. *University Hospital Antwerp, Antwerp, Belgium. sdehert@uia.ac.be

References

1. De Hert SG, ten Broecke PW, Mertens E, Van Sommeren EW, De Blier IG, Stockman BA, Rodrigus IE: Sevoflurane but not propofol preserves myocardial function in coronary surgery patients. *ANESTHESIOLOGY* 2002; 97:42–9
2. Breisblatt WM, Stein KL, Wolfe CJ, Follansbee WP, Capozzi J, Armitage JM, Hardesty RL: Acute myocardial dysfunction and recovery: a common occurrence after coronary bypass surgery. *J Am Coll Cardiol* 1990; 15:1261–9
3. Ebel D, Schlack W, Comfère T, Preckel B, Thämer V: Effect of propofol on reperfusion injury after regional ischaemia in the isolated rat heart. *Br J Anaesth* 1999; 83:903–8
4. Ko SH, Yu CW, Lee SK, Choe H, Chung MJ, Kwak YG, Song HS: Propofol attenuates ischemia-reperfusion injury in the isolated rat heart. *Anesth Analg* 1999; 85:719–24
5. Ansley DM, Sun J, Visser WA, Dolman J, Godin DV, Garnett ME, Qayumi AK: High dose propofol enhances red cell antioxidant capacity during CPB in humans. *Can J Anaesth* 1999; 46:641–8

(Accepted for publication November 20, 2002.)

Anesthesiology 2003; 98:1029

© 2003 American Society of Anesthesiologists, Inc. Lippincott Williams & Wilkins, Inc.

Effect of Nitrous Oxide on Sevoflurane Vaporizer Setting

To the Editor:—I read the article by Hendrickx *et al.*¹ with great interest. In their study, the authors found that during minimal-flow anesthesia (MFA; 0.5 l/min), the vaporizer dial setting required to maintain the end-tidal sevoflurane concentration constant at 1.3% is lower when sevoflurane is delivered in an oxygen-nitrous oxide mixture than in oxygen alone because less gas and vapor are wasted through the pop-off valve with the oxygen-nitrous oxide mixture. During low-flow anesthesia (LFA; 1 l/min), however, vaporizer dial settings are similar with oxygen-nitrous oxide or oxygen, presumably because the proportion of excess gas leaving the pop-off valve relative to the amount taken up by the patient increases. However, I carefully examined the authors' experimental design and found that the vaporizer setting required to maintain the end-tidal sevoflurane concentration constant at 1.3% is lower when sevoflurane is delivered in an oxygen-nitrous oxide mixture than in oxygen alone during MFA, simply because of the differences in the initial flow setup and not because less gas and vapor are wasted through the pop-off valve. We must recognize that the very large space of the anesthesia circuit (4.3 l)

and the patient's functional residual capacity (2.5–3 l) existed before the patient's alveolar membrane; therefore, the use of MFA with oxygen alone certainly requires a much higher vaporizer dial setting to maintain the end-tidal sevoflurane concentration constant at 1.3%. On the other hand, MFA with oxygen-nitrous oxide mixture and a high fresh gas flow of 6 l/min was used for 10 min; therefore, the circuit and functional residual capacity were prefilled to keep the end-tidal sevoflurane concentration constant at 1.3%. Certainly lower sevoflurane vaporizer dial settings are required afterwards, even at MFA.

Chung-Yuan Lin, M.D., University of Chicago, Chicago, Illinois. licy@airway.uchicago.edu

Reference

1. Hendrickx JFA, Coddens J, Callebaut F, Artico H, Deloof T, Demeyer I, De Wolf AM: Effect of N₂O on sevoflurane vaporizer settings during minimal- and low-flow anesthesia. *ANESTHESIOLOGY* 2002; 97:400–4

(Accepted for publication November 20, 2002.)

Anesthesiology 2003; 98:1029

© 2003 American Society of Anesthesiologists, Inc. Lippincott Williams & Wilkins, Inc.

In Reply:—We appreciate the comments made by Dr. Lin. He correctly points out that the anesthesia circuit and the patient's functional residual capacity can be considered to be a reservoir of vapor (in this study, sevoflurane). However, because the desired end-expired sevoflurane concentration was obtained within 5 min in all groups, and because the sevoflurane concentration was kept constant throughout the study period (10–60 min), the anesthesia circuit and functional residual capacity are not a “source” of sevoflurane thereafter nor do they contribute to sevoflurane consumption during the observation

period. In other words, the anesthesia circuit and the patient's functional residual capacity, once saturated at the desired sevoflurane concentration, do not affect the vaporizer setting required to keep end-expired sevoflurane concentration constant. This concept is not influenced by the initial fresh gas flow settings.

Andre M. De Wolf, M.D.,* Jan F. A. Hendrickx, M.D. *Northwestern University Medical School, Chicago, Illinois. a-dewolf@nwu.edu

(Accepted for publication November 20, 2002.)

Anesthesiology 2003; 98:1030

© 2003 American Society of Anesthesiologists, Inc. Lippincott Williams & Wilkins, Inc.

Isoflurane Causes Vasodilation in the Coronary Circulation

To the Editor:—We read with interest the article by Gamperl *et al.*,¹ which describes studies evaluating effects of isoflurane on isolated porcine coronary microvessels. The main finding from this well-performed study was that isoflurane caused dilation, which confirmed our results in a similar model.²

The data from Gamperl *et al.*¹ add to the existing body of compelling evidence that isoflurane is a dilator in the coronary circulation and not a constrictor, as was previously argued.³ We hope that these findings will finally put to rest the controversy relating to the vasomotor effect of isoflurane in the coronary circulation.

Over the past decade, studies in our laboratory^{2,4-10} and others^{1,11,12} have sought to clarify the effects of the volatile anesthetics in the coronary circulation. From these studies, several definitive findings have emerged. First, the volatile anesthetics, as a class of drugs, are dose-dependent coronary vasodilators.^{1,2,4,6,7,10,11} The coronary vasodilating effect of isoflurane is, by far, greater than that of the other volatile anesthetics (halothane, enflurane, sevoflurane, and desflurane). Second, volatile anesthetic-induced coronary vasodilation is mediated by the adenosine triphosphate-sensitive potassium channels^{1,2,9,10,12} and is endothelium dependent,¹ although nitric oxide does not appear to be involved.⁵ Third, coronary vascular smooth muscle adapts to the relaxing effect of volatile anesthetics^{2,5,8}; thus, the coronary vasodilation caused by these anesthetics is minimized by slow or extended administrations.

It is worth recognizing that these findings in the coronary circulation served as a springboard for studies demonstrating that the volatile anesthetics may precondition the myocardium against reperfusion injury,¹³ an action that may have enormous therapeutic value in patients undergoing surgical and nonsurgical coronary revascularization procedures.

George J. Crystal, Ph.D.,* M. Ramez Salem, M.D. *Advocate Illinois Masonic Medical Center, Chicago, Illinois. gcrystal@uic.edu

References

1. Gamperl AK, Hein TW, Kuo L, Cason BA: Isoflurane-induced dilation of porcine coronary microvessels is endothelium dependent and inhibited by glibenclamide. *ANESTHESIOLOGY* 2002; 96:1465-71
2. Zhou X, Abboud W, Manabat NC, Salem MR, Crystal GJ: Isoflurane-induced dilation of porcine coronary arterioles is mediated by ATP-sensitive potassium channels. *ANESTHESIOLOGY* 1998; 89:182-9
3. Park KW, Dai HB, Lowenstein E, Darvish A, Sellke FW: Heterogeneous vasomotor responses of rabbit coronary microvessels to isoflurane. *ANESTHESIOLOGY* 1994; 81:1190-7
4. Crystal GJ, Kim SJ, Czinn EA, Salem MR, Mason WR, Abdel-Latif M: Intracoronary isoflurane causes marked vasodilation in canine hearts. *ANESTHESIOLOGY* 1991; 74:757-65
5. Crystal GJ, Kim SJ, Salem MR, Khoury E, Gurevicius J: Nitric oxide does not mediate coronary vasodilation by isoflurane. *ANESTHESIOLOGY* 1994; 81:209-20
6. Crystal GJ, Khoury E, Gurevicius J, Salem MR: Direct effects of halothane on coronary blood flow, myocardial oxygen consumption, and myocardial segmental shortening in *in situ* canine hearts. *Anesth Analg* 1995; 80:256-62
7. Gurevicius J, Holmes CB, Salem MR, Abdel-Halim A, Crystal GJ: The direct effects of enflurane on coronary blood flow, myocardial oxygen consumption, and myocardial segmental shortening in *in situ* canine hearts. *Anesth Analg* 1996; 83:68-74
8. Crystal GJ, Czinn EA, Silver JM, Salem MR: Coronary vasodilation by isoflurane: abrupt vs. gradual administration. *ANESTHESIOLOGY* 1995; 82:542-9
9. Crystal GJ, Gurevicius J, Salem MR, Zhou X: Role of adenosine triphosphate-sensitive potassium channels in coronary vasodilation by halothane, isoflurane, and enflurane. *ANESTHESIOLOGY* 1997; 86:448-58
10. Crystal GJ, Zhou X, Gurevicius J, Czinn EA, Salem MR, Alam S, Piotrowski A, Hu G: Direct coronary vasomotor effects of sevoflurane and desflurane in *in situ* canine hearts. *ANESTHESIOLOGY* 2000; 92:1103-13
11. Hickey RF, Cason BA, Shubayev I: Regional vasodilating properties of isoflurane in normal swine myocardium. *ANESTHESIOLOGY* 1994; 80:574-81
12. Cason BA, Shubayev I, Hickey RF: Blockade of adenosine triphosphate-sensitive potassium channels eliminates isoflurane-induced coronary arterial vasodilation. *ANESTHESIOLOGY* 1994; 81:1245-55
13. Kersten JR, Schmeling TJ, Pagel PS, Gross GJ, Warltier DC: Isoflurane mimics ischemic preconditioning via activation of K_{ATP} channels: Reduction of myocardial infarct size with an acute memory phase. *ANESTHESIOLOGY* 1997; 87:361-70

(Accepted for publication November 26, 2002.)

Anesthesiology 2003; 98:1030-1

© 2003 American Society of Anesthesiologists, Inc. Lippincott Williams & Wilkins, Inc.

Unusual Cause of Intraoperative Urinary Retention

To the Editor:—While intraoperative oliguria in not a reliable predictor of postoperative renal dysfunction, vigilant effort is made by the anesthesiologist to keep the patient's urine output at an acceptable level. The total absence of urine in the collection bag suggests either a mechanical obstruction or extreme renal hypoperfusion and subsequent lack of glomerular filtration. We describe an "epidemic" of intraoperative anuria due to defective Foley catheters.

A 45-yr-old patient presented for sigmoid colectomy. Prior to the abdominal incision, the operating room nurse placed a Foley catheter (Foley tray; Bard Medical, Covington, GA). Three hours later, the patient was anuric despite receiving 3 l of lactated Ringer's solution. The surgeon examined the exposed bladder and reported that it was "empty." Furosemide, 5 mg intravenously, was given in an unsuccessful attempt to promote a diuresis. After completion of surgery, we attempted to irrigate the Foley catheter but without success. The catheter was replaced, resulting in the brisk return of copious urine. Examination of the original Foley catheter revealed a manufacturer's defect: absence of the end hole (fig. 1).

An 85-yr-old woman underwent coronary artery bypass surgery with aortic valve replacement. A Foley catheter was placed (CRITICORE




Fig. 1. Two Foley catheters: the top catheter is normal, and the lower catheter is defective, with lack of an orifice.

Support was provided solely from institutional and/or departmental sources.

Foley tray; Bard Medical) following induction of anesthesia. The lack of urine draining into the catheter prompted a call to the urology service. After establishing correct placement (transabdominal palpation of inflation and deflation of the Foley catheter balloon), irrigation was attempted without success. The catheter was then replaced. The replaced Foley catheter was examined and found to be lacking an orifice (same defect as depicted in fig. 1).

While intraoperative oliguria is indicative of renal hypoperfusion, anuria suggests the possibility of either catheter occlusion or the detachment of the tubing from the collection bag. Irrigation of the Foley catheter always should be the first step in the evaluation of the anuric patient. In these two cases, it was not possible to irrigate the bladder due to a lack of

communication between the catheter lumen and the patient's bladder. As the first patient voided immediately prior to his arrival in the operating room, the initial lack of return of urine into the Foley collection bag, even with suprapubic compression, was not surprising. Since anesthesiologists rely on urine output as an indicator of renal perfusion, confirming proper placement and function of the catheter by demonstrating the flow of urine should be a routine procedure prior to the beginning of surgery.

Bradley D. Bergman, D.O., Juraj Sprung, M.D., Ph.D.* *Mayo Clinic, Rochester, Minnesota. sprung.juraj@mayo.edu

(Accepted for publication August 20, 2002.)

Anesthesiology 2003; 98:1031-2

© 2003 American Society of Anesthesiologists, Inc. Lippincott Williams & Wilkins, Inc.

The Use of Three-dimensional Computed Tomography to Visualize Thoracic Epidural Catheters

To the Editor:—Thoracic epidural catheterization was implemented in a 62-yr-old woman scheduled for subtotal gastrectomy. A FlexTip Plus[®] epidural catheter (single end hole; Arrow International, Reading, PA) was inserted at the T9–T10 intervertebral space and directed cephalad for 5 cm. With the patient's consent, a 10-cm slab of a thin-cut spiral computed tomography (CT) scan was obtained through T6–T12 with 1-mm collimation at a pitch of 2, 140 kVp and 160 mA and with a 13-cm field of view (HiSpeed Advantage scanner; GE Medical Systems, Milwaukee, WI).

The raw data were processed with a 0.5-mm overlap using the GE Advantage workstation (DentaScan, GE Medical Systems). The axial transverse section of the CT image demonstrated the existence of a catheter in the epidural space (fig. 1A). With an oblique view, the path of the catheter in the epidural space was displayed with multiplanar reconstruction (fig. 1B) or a three-dimensional surface-shaded display

(fig. 2). There was no kinking or knotting of the catheter despite the curved path in the epidural space.

A substantial incidence of failed or unilateral epidural block may be due to the complexity of the epidural space.¹ When looping, kinking, entrapment, or knotting of epidural catheters occurs, it is not easy to visualize the path of the radiopaque catheter within the epidural space.^{2,3} Although conventional radiography,^{4,5} ultrasonographic imaging,⁶ epidurography with contrast medium,⁷ CT,^{8–10} or magnetic resonance imaging¹¹ might be useful, a potential allergic reaction to contrast medium, interference with metal coils, or blockade or occlusion of the epidural catheter could still be problematic. Thin-cut volumetric CT scanning, coupled with two-dimensional multiplanar or three-dimensional model reconstruction, has been used for evaluation of the upper airway anatomy.¹²

Given the exquisite tissue contrast of CT in displaying the epidural space, its potential in the evaluation of a problematic epidural catheter has never been explored. An axial scan shows the exact location of the

Support was provided solely from institutional and/or departmental sources.

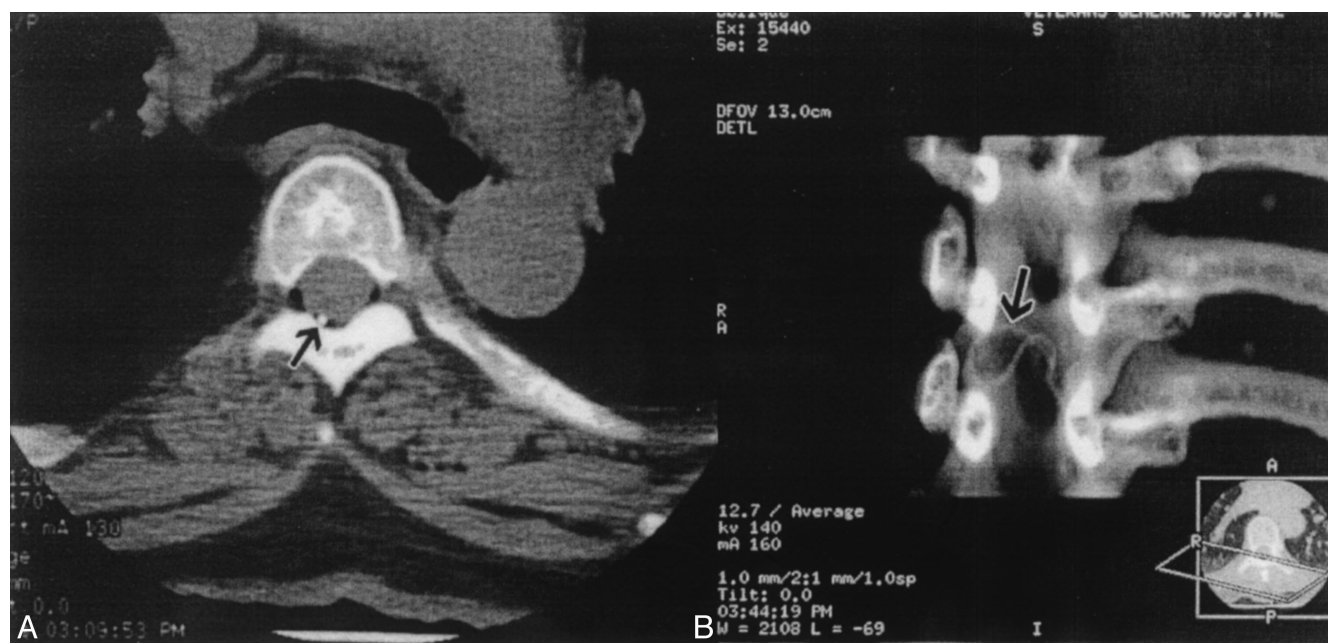


Fig. 1. (A) An axial computed tomography image shows the epidural catheter between the spinal lamina and the dural sac. The epidural catheter contains radiopaque metal spring coils. (B) A multiplanar reconstructed image of the lower thoracic spine in an oblique coronal section shows the complex but smooth, looping course of the epidural catheter (arrow), without kinking.

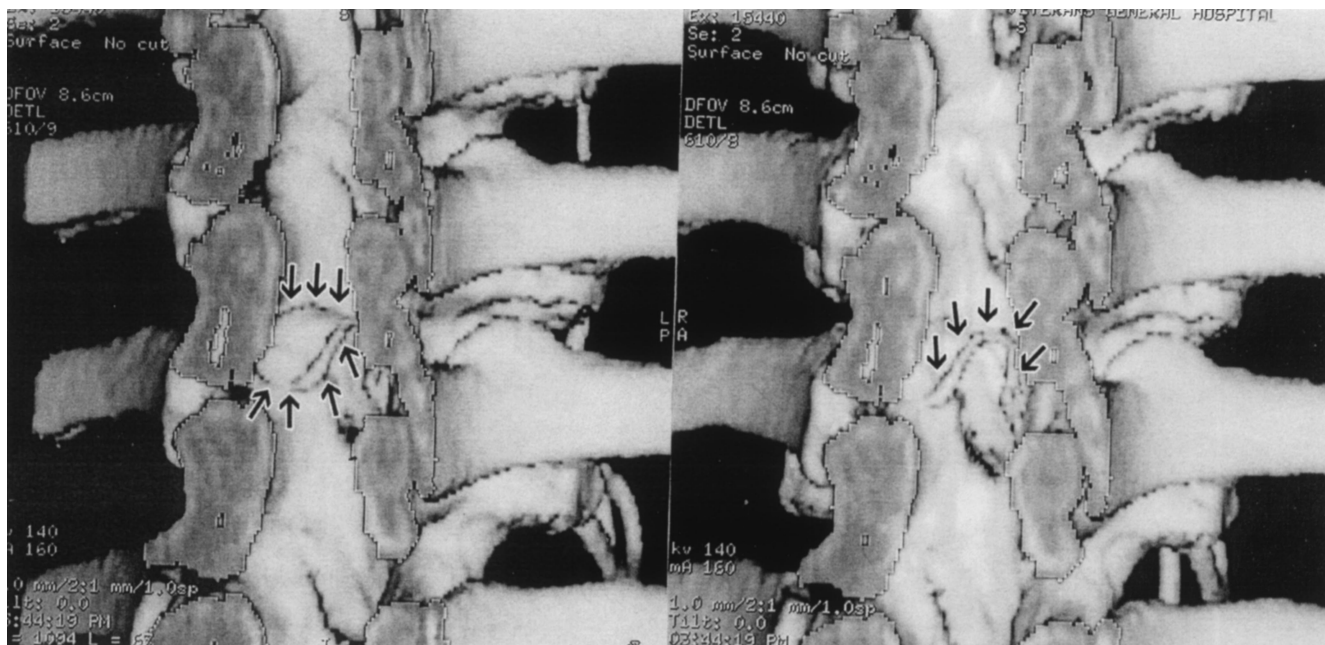


Fig. 2. Surface display images (three-dimensional) of the epidural catheter in the thoracic epidural space. The arrows depict the path of the catheter. The laminae were removed during the reconstruction process.

catheter in the epidural space and thus is useful in detecting malposition. With two-dimensional multiplanar and three-dimensional surface display models, the course of the catheter in the epidural space is depicted. In conclusion, three-dimensional CT imaging appears to be a novel tool to visualize the position and path of an epidural catheter.

Shih-Tai Hsin, M.D., Kee-Min Yeow, M.D, Chih-Hsiang Tsou, M.D., Hung-Pin Liu, M.D., Hsiang-Ning Luk, M.D., M.S., Ph.D.,* Hong-Zhi Ren, M.D. *Chang-Gung Memorial Hospital, Linkou, Taoyuan, Taiwan. luk1015@adm.cgmh.org.tw

References

- Hogan QH: Lumbar epidural anatomy: A new look by cryomicrotome section. *ANESTHESIOLOGY* 1991; 75:767-75
- Hsin ST, Chang FC, Tsou MY, Liao WW, Lee TY, Lui PW, Luk HN: Inadvertent knotting of a thoracic epidural catheter. *Acta Anaesthesiol Scand* 2001; 45:255-7
- Renahan EM, Peterson RA, Penning JP, Rosaeg OP, Chow D: Visualization of a looped and knotted epidural catheter with a guidewire. *Can J Anaesth* 2000; 47:329-33
- Muneyuki M, Shirai K, Inamoto A: Roentgenographic analysis of the positions of catheters in the epidural space. *ANESTHESIOLOGY* 1970; 33:19-24
- Hendriks GW, Hasenbos MA, Gielen MJ, van Egmond J, Barentsz JO: Evaluation of thoracic epidural catheter position and migration using radio-opaque catheters. *Anaesthesia* 1997; 52:457-9
- Grau T, Leipold RW, Delorme S, Martin E, Motsch J: Ultrasound imaging of the thoracic epidural space. *Reg Anesth Pain Med* 2002; 27:200-6
- Seeling W, Tomczak R, Merk J, Mrakovic N: CT-epidurography. A comparison of conventional and CT-epidurography with contrast medium injection through a thoracic peridural catheter. *Anaesthesist* 1995; 44:24-36
- Harrison GR: Topographical anatomy of the lumbar epidural region: An in vivo study using computerized axial tomography. *Br J Anaesth* 1999; 83:229-34
- Ghia JN, Arora SK, Castillo M, Mukherji SK: Confirmation of location of epidural catheters by epidural pressure waveform and computed tomography cathetergram. *Reg Anesth Pain Med* 2001; 26:337-41
- Hogan Q: Epidural catheter tip position and distribution of injectate evaluated by computed tomography. *ANESTHESIOLOGY* 1999; 90:964-70
- Westbrook JL, Renowden SA, Carrie LES: Study of the anatomy of the extradural region using magnetic resonance imaging. *Br J Anaesth* 1993; 71:495-8
- Kanaya N, Kawana S, Watanabe H, Niiyama Y, Niiya T, Nakayama M, Namiki A: The utility of three-dimensional computed tomography in unanticipated difficult endotracheal intubation. *Anesth Analg* 2000; 91:752-4

(Accepted for publication November 8, 2002.)

Anesthesiology 2003; 98:1032-3

© 2003 American Society of Anesthesiologists, Inc. Lippincott Williams & Wilkins, Inc.

Unilateral Presentation of a Large Epidural Hematoma

To the Editor:—Epidural hematoma formation following lumbar regional anesthesia is a rare complication, with incidences of 1 in 220,000 after spinal anesthesia and 1 in 150,000 after epidural anesthesia.¹ While severe lower back pain that is enhanced by percussion or movements of the spine typically represents the initial clinical symptom of a large epidural hematoma,² cauda equina syndrome with paraparesis and dysfunctions of the bladder and bowel may develop after a delay of several hours.

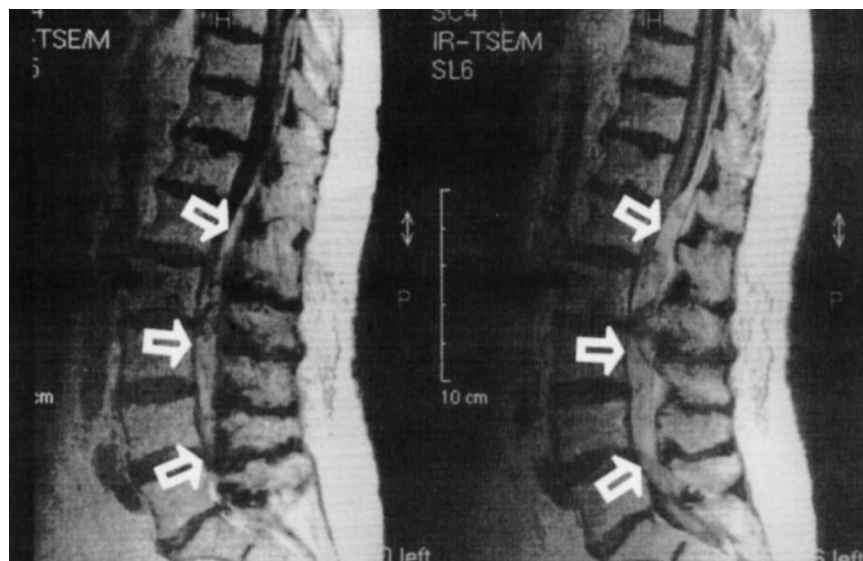
We report the case of an 83-yr-old woman who underwent spinal anesthesia for minor gynecologic surgery. Preoperative evaluation revealed an ASA physical status of III with atrial fibrillation, discrete pretibial edema, and chronic rheumatoid pain in both legs. Blood chemistry values and coagulation status were normal. Daily medication, including 1,000 mg naproxen, was discontinued on the evening before surgery.

Due to degeneration of the spine, puncture of the lumbar subarachnoid space required multiple attempts at intervertebral spaces L2-L3 and L3-L4, with use of a 27-gauge Quincke needle. After appearance of clear cerebrospinal fluid without shooting pain or paresthesia, 75 mg hyperbaric lidocaine was injected.

Support was provided solely from institutional and/or departmental sources.

Anesthesiology, V 98, No 4, Apr 2003

Fig. 1. Magnetic resonance images obtained 1 day after spinal anesthesia. T₂-weighted fluid-attenuated inversion recovery sagittal turbo spin echo images show a dorsally fixed, large space-occupying mass reaching from the L2 to L5 level, a typical aspect of an epidural hematoma.



In the early postoperative period, the patient reported her typical rheumatoid pain in the legs, and diclofenac was administered topically. Seventeen hours after surgery, a neurologic examination revealed monoparesis of the right leg in the absence of back pain. Sensory functions were reduced in radicular segments L4–L5 and S1–S4 on the right side. The right patellar tendon reflex was reduced, and ankle tendon reflexes were absent on both sides. There were no signs of bladder or bowel dysfunction. Primarily, a pressure palsy of the lumbar plexus or the femoral and sciatic nerves was assumed.

Lumbar computed tomographic images were obtained and revealed high-grade compression of the dural sac by a large, hyperdense mass. Subsequent magnetic resonance imaging (MRI) of the lumbar spine (fig. 1) demonstrated a subtotal obstruction of the spinal canal at the L2 and L3 levels. As imaging findings were highly suggestive of a large epidural hematoma, the patient underwent urgent decompressive laminectomy of L2–L4, and the hematoma was removed.

Postoperatively, the patient initially showed no significant benefit from decompressive therapy, although MRI examinations 3 weeks after the procedure confirmed complete removal of the hematoma. Following a rehabilitation process of 3 months, neurologic function was recovered and the patient was able to walk independently.

Major risk factors for bleeding complications following spinal or epidural anesthesia include impaired coagulation, difficult or multiple punctures,³ and insertion of a catheter.⁴

Naproxen, a nonsteroidal antiinflammatory drug, may also have played a causal role in the development of the epidural hematoma, because platelet aggregation is normal in only 50% of patients 2 days after withdrawal of naproxen,⁵ and in our patient naproxen was withdrawn 12 h before surgery.

The strictly unilateral sensorimotor dysfunction of a radicular pattern without lower back pain in our patient was certainly an atypical clinical presentation of a large epidural hematoma expanding from the lower thoracic to the lower lumbar spine. Furthermore, in view of the age of the patient, the absence of ankle tendon reflexes on both sides might, instead, have been attributed to mild polyneuropathy than to an impairment of the first sacral root on both sides.

Magnetic resonance imaging is the diagnostic procedure of choice to

verify an epidural hematoma.⁶ Therapy consists of urgent decompressive surgery with removal of the hematoma, usually in combination with hemilaminectomy.^{7,8} While outcome is influenced mainly by the severity of neurologic impairment at the time of surgical intervention, data and clinical experience suggest that the length of the delay before surgery also is important to recovery. Minor neurologic disturbances and treatment within 12 h⁹ and up to 36 h² are correlated with a better prognosis for recovery,² but patients may continue to benefit from surgical therapy up to 3 weeks¹⁰ after damage.

Michael Zink, M.D.,* Manfred Rath, M.D., Andreas Waltensdorfer, M.D., Jörg Engler, M.D., Gudrun Rumpold-Seitlinger, M.D., Wolfgang Toller, M.D., Frank Reinhardt, M.D. *University of Graz, Graz, Austria. michael.zink@uni-graz.at

References

1. Tryba M: Epidural regional anesthesia and low molecular heparin: Pro. *Anesthesiol Intensivmed Notfallmed Schmerzther* 1993; 28:179–81
2. Groen RJ, van Alphen HA: Operative treatment of spontaneous spinal epidural hematomas: a study of the factors determining postoperative outcome. *Neurosurgery* 1996; 39:494–508; discussion 508–9
3. Vandermeulen EP, Van Aken H, Vermeylen J: Anticoagulants and spinal epidural anesthesia. *Anesth Analg* 1994; 79:1165–77
4. Wulf H: Epidural anaesthesia and spinal haematoma. *Can J Anaesth* 1996; 43:1260–71
5. Cronberg S, Wallmark E, Soderberg I: Effect on platelet aggregation of oral administration of 10 non-steroidal analgesics to humans. *Scand J Haematol* 1984; 33:155–9
6. Di Lorenzo N, Rizzo A, Fortuna A: Spontaneous spinal epidural hematoma: Pre-operative diagnosis by MRI. *Clin Neurol Neurosurg* 1990; 92:357–9
7. Daentzer D, Boker DK: Spontaneous spinal hemorrhage: Outcome after surgical therapy of epidural hematomas. *Nervenzentr* 2000; 71:116–22
8. Pear BL: Spinal epidural hematoma. *Am J Roentgenol Radium Ther Nucl Med* 1972; 115:155–64
9. Lawton MT, Porter RW, Heiserman JE, Jacobowitz R, Sonntag VK, Dickman CA: Surgical management of spinal epidural hematoma: Relationship between surgical timing and neurological outcome. *J Neurosurg* 1995; 83:1–7
10. Buhl R, Kretschmer H: Spontaneous spinal epidural hematoma: Good outcome after delayed treatment. *Zentralbl Neurochir* 1998; 59:109–12

(Accepted for publication November 26, 2002.)