

Neuroprotective Effect of Urinary Trypsin Inhibitor against Focal Cerebral Ischemia-Reperfusion Injury in Rats

Toshiyuki Yano, M.D., Ph.D.,* Sakiko Anraku, M.D.,† Ryosuke Nakayama, M.D.,‡ Kazuo Ushijima, M.D., Ph.D.§

Background: Acute inflammatory reactions cause neuronal damage in cerebral ischemia-reperfusion. Urinary trypsin inhibitor (UTI), a serine protease inhibitor, is cytoprotective against ischemia-reperfusion injury in the liver, intestine, kidney, heart, and lung through its antiinflammatory activity. Neuroprotective action of UTI on transient global cerebral ischemia has been documented. This is the first study to determine whether UTI is neuroprotective against transient focal cerebral ischemia.

Methods: Adult male Wistar rats were randomly assigned to the following treatment groups: 0.9% saline (control, $n = 9$); 100,000 U/kg UTI ($n = 9$); and 300,000 U/kg UTI ($n = 9$). Treatments were performed intravenously 10 min before right middle cerebral artery occlusion for 2 h and subsequent reperfusion. Ninety-six hours after the onset of reperfusion, the motor neurologic deficit and the cerebral infarct size were evaluated. Furthermore, immunohistochemical staining for myeloperoxidase and nitrotyrosine to count infiltrating neutrophils and nitrated cells, respectively, was performed on the brain sections.

Results: Infarct volume in the 300,000 U/kg UTI group was smaller than in the 100,000 U/kg UTI and saline control groups ($P < 0.05$). Treatment with 300,000 U/kg UTI showed a trend to improve neurologic outcome but did not reach statistical significance ($P = 0.0693$). The significant decrease in neutrophil infiltration was observed in the ischemic hemisphere treated with 300,000 U/kg UTI compared with saline control ($P < 0.05$). Nitrotyrosine deposition in the ischemic hemisphere was significantly reduced in the 300,000 U/kg UTI group compared with saline control and 100,000 U/kg UTI groups ($P < 0.05$).

Conclusions: Intravenous pretreatment with 300,000 U/kg UTI reduces focal ischemia-reperfusion injury in the rat brain, potentially opening a novel therapeutic avenue for the treatment of cerebral ischemia.

STROKE is one of the major complications in the perioperative period of neurosurgery and cardiovascular surgery. Although restoration of cerebral blood flow in the ischemic territory has been feasible by thrombolytic agents such as the tissue plasminogen activator, the likelihood of reperfusion injury represented by brain edema and hemorrhage especially increases beyond an optimal therapeutic window (within 3 h of symptom onset) of the thrombolytic treatment.^{1,2} Prophylactic

pharmacological interventions for neuroprotection against cerebral ischemia-reperfusion injuries could bring about significant benefits in patients undergoing those surgeries and the following intensive care. However, efficacious and safe neuroprotective agents have not yet been established.

Ample accumulating evidence suggests that an acute inflammatory response associated with cerebral ischemia-reperfusion contributes to the development of brain damage.³ Because the inflammatory response takes place immediately and lasts for at least a few days after ischemic brain injury,⁴ these responses would be a promising target for antiinflammatory approaches to neuroprotection. Urinary trypsin inhibitor (UTI; ulinastatin), a serine protease inhibitor derived from human urine, has an antiinflammatory activity to suppress the infiltration of neutrophils and the release of elastase and chemical mediators from neutrophils.⁵⁻¹⁰ Recent studies have shown that UTI may be cytoprotective against ischemia-reperfusion injury in the liver, intestine, kidney, heart, and lung.^{5,11-14} Neuroprotective action of UTI on global ischemia-reperfusion in the brain has been documented.¹⁵ However, the effects of UTI on focal cerebral ischemia-reperfusion injury remain to be elucidated. The purpose of this study was to identify whether pretreatment with UTI reduces cerebral injury due to transient middle cerebral artery occlusion (MCAO).

Materials and Methods

Subjects, Preparation, and Laser Doppler Flowmetry

We performed all animal care procedures in this study according to the Guidelines for Animal Experiments of the Kumamoto University School of Medicine (Kumamoto, Japan). The Animal Care and Use Committee for our institute approved the study protocol. We used adult male Wistar rats weighing between 250 and 330 g. The animals were given free access to food and water. At the time of the experiment, the animal was anesthetized with 5% isoflurane in a mixture of nitrous oxide and oxygen (fraction of inspired oxygen [FiO_2], 0.33) in a box, and anesthesia was maintained at 1.5% isoflurane in the same gas mixture using a face mask. The pericranial temperature was continuously monitored between the right temporal muscle and temporal bone with a tissue-implantable thermocouple microprobe (IT-14; Physitemp Instruments Inc., Clifton, NJ) and maintained at $37.5 \pm 0.5^\circ\text{C}$ during the surgery, brain ischemia, and recovery from anesthesia with the use of a temperature

* Assistant Professor, † Staff Anesthesiologist, Department of Anesthesiology, Kumamoto University School of Medicine, ‡ Instructor, § Associate Professor and Vice Director, Surgical Center, Kumamoto University Hospital.

Received from the Laboratory of Department of Anesthesiology, Kumamoto University School of Medicine, Kumamoto, Japan. Submitted for publication July 1, 2002. Accepted for publication October 8, 2002. Supported by Grant-in-Aid for Scientific Research No. 12671480 from the Ministry of Education, Culture, Sports, Science and Technology, Tokyo, Japan.

Address reprint requests to Dr. Yano: Department of Anesthesiology, Kumamoto University School of Medicine, 1-1-1 Honjo, Kumamoto 860-8556, Japan. Address electronic mail to: tymac@kaijuu.medic.kumamoto-u.ac.jp. Individual article reprints may be purchased through the Journal Web site, www.anesthesiology.org.

controller (TCAT-1A; Physitemp Instruments Inc.) and a radiant heating lamp. The tail artery was cannulated for monitoring of arterial pressure and analysis of arterial blood gases, glucose, and hematocrit. The animal was placed on a stereotaxic instrument (Model 900; David Kopf, Tujunga, CA) in the prone position, and a burr hole (diameter, 2 mm) was drilled in the right cranium at 2 mm posterior and 6 mm lateral to the bregma over the middle cerebral artery (MCA) territory. An acrylic guide cannula (OD, 2 mm; ID, 1 mm; length, 6 mm; NS Sheath; Advance Co. Ltd., Tokyo, Japan) was placed perpendicularly on the surface of the intact dura and fixed to the cranium using acrylic cement. One end of the guide cannula has a transparent septum, which directly comes in contact with the dura. The guide cannula was filled with distilled water, and a laser Doppler flowmetry probe (diameter, 1 mm; NSS; Advance Co. Ltd.) connected to a laser Doppler flowmeter (ALF 2100; Advance Co. Ltd.) was inserted until the tip reached the septum of the cannula to allow for continuous measurement of the regional cerebral blood flow (rCBF). The steady state baseline rCBF value was measured before ischemia and was defined to be 100%. The rCBF values are expressed as a percentage of the baseline value (%rCBF).

Middle Cerebral Artery Occlusion

The right MCA was occluded for 2 h using our modification of an intraluminal filament method as previously described by Yamada *et al.*¹⁶ In brief, the right common carotid artery (CCA) was exposed through a midline neck incision, and the right external carotid artery (ECA) was ligated and cut at a site 3 mm distal to the bifurcation of the CCA. After the extracranial branch of the ECA was coagulated and cut, a microvascular clip was placed across the CCA. A silicon-coated 4-0 nylon monofilament suture was then inserted *via* a small incision in the ECA and advanced into the internal carotid artery until resistance was felt, so that the leading tip of the filament occluded the origin of the right MCA. The microvascular clip was removed, and the incision was closed. Achievement of MCAO was confirmed by both a reduction of 50% or more in rCBF to the baseline value¹⁷ and a counterclockwise circling movement due to paresis of the left limbs 20 min after the emergence of anesthesia. After 120 min of MCA occlusion, the rats were reanesthetized, and the wound was reopened. Reperfusion of the MCA was initiated by removing the MCA occlusive filament and was ascertained by restoration of rCBF. The incision was closed, and the tail arterial catheter and laser Doppler flowmetry probe were removed. The pericranial temperature was kept at $37.5 \pm 0.5^\circ\text{C}$ until the rats recovered from anesthesia completely. The temperature probe was removed, and the rats were then returned to cages in a 25°C -controlled environment. Free access to food and water was allowed until the rats were sacrificed.

Experimental Design

Twenty-seven rats were randomly allocated to one of three groups to be treated with 0.9% saline (control, $n = 9$), 100,000 U/kg UTI ($n = 9$), or 300,000 U/kg UTI ($n = 9$). UTI (Mochida Pharmaceutical Co., Ltd, Tokyo, Japan) was dissolved in distilled water. Saline or UTI, 0.5 ml in volume, was intravenously administered *via* the left external jugular vein 10 min before the initiation of MCAO. All outcome variables were obtained 96 h after the onset of reperfusion. The rats not surviving for 96 h were excluded from the study.

Assessment of Motor Neurologic Deficit

Motor neurologic deficits were evaluated 96 h following MCAO in a blind fashion using a five-point scoring system previously described by Mokudai *et al.*¹⁸: 0 = no observable deficit; 1 = forelimb flexion; 2 = forelimb flexion and decreased resistance to lateral push; 3 = forelimb flexion, decreased resistance to lateral push, and unilateral circling; 4 = forelimb flexion and being unable or difficult to ambulate.

Quantification of Infarct Area and Volume

After the neurologic assessment, the rats were sacrificed under intraperitoneal pentobarbital anesthesia (100 mg/kg) and were then perfused transcardially with heparinized normal saline (4 U/ml). The brains were rapidly removed and sliced at 2–14 mm posterior to the frontal pole into six 2-mm-thick coronal sections using a rat brain slicer (RBS-02; Neuroscience, Inc., Tokyo, Japan). The sections were immersed in 1% 2,3,5-triphenyl-tetrazolium chloride (TTC; Research Organics, Inc., Cleveland, OH) dissolved in phosphate-buffered saline (PBS; pH 7.4) and incubated at room temperature for 30 min, and then they were fixed in 10% neutral buffered formalin overnight. Infarct size was evaluated by an inspector blinded to intervention according to the method described by Yang *et al.*¹⁹ Briefly, the rostral sides of each fixed section were directly scanned with a flatbed color scanner (OPAL ultra; Heidelberg Japan, Tokyo, Japan) linked with a computer (Power Mac G3; Apple Japan, Inc., Tokyo, Japan) and controlled with supplied software (LinoColor Elite, version 5.1.7; Heidelberg Japan). The margins of the infarct area in the captured digital images were manually outlined, and a pixel-based area calculation was performed using NIH Image 1.61 (National Institutes of Health, Bethesda, MD). The total infarct volume was calculated by summing the infarct area in each section and multiplying by the section thickness.

Histopathology and Immunohistochemistry

After the scanning for infarct quantification, the sections were dehydrated with graded alcohols, embedded in paraffin, and sliced into 5- μm -thick coronal sections.

Table 1. Physiologic Variables

Variable	Urinary Trypsin Inhibitor, U/kg		
	0 (saline)	100,000	300,000
Number	9	8	9
Body weight, g	280 ± 20	288 ± 28	288 ± 12
Body weight loss, g*	81 ± 21	76 ± 14	81 ± 9
Hematocrit, %	39 ± 2	39 ± 2	40 ± 2
Blood glucose, mg/dl	133 ± 12	131 ± 5	133 ± 7
Mean arterial pressure, mmHg			
Baseline	95 ± 8	92 ± 10	93 ± 8
During ischemia†	101 ± 11	102 ± 7	102 ± 11
During reperfusion‡	104 ± 9	108 ± 8	101 ± 8
Pao ₂ , mmHg			
Baseline	168 ± 33	179 ± 15	161 ± 13
During ischemia†	163 ± 33	173 ± 13	160 ± 10
During reperfusion‡	163 ± 23	173 ± 10	170 ± 12
Paco ₂ , mmHg			
Baseline	38 ± 3	39 ± 2	39 ± 2
During ischemia†	38 ± 3	40 ± 4	39 ± 3
During reperfusion‡	39 ± 3	39 ± 1	38 ± 2
Arterial pH			
Baseline	7.43 ± 0.02	7.42 ± 0.02	7.43 ± 0.02
During ischemia†	7.43 ± 0.03	7.40 ± 0.02	7.42 ± 0.02
During reperfusion‡	7.42 ± 0.02	7.41 ± 0.02	7.43 ± 0.03
Pericranial temperature, °C			
Baseline	37.2 ± 0.1	37.2 ± 0.1	37.2 ± 0.1
During ischemia†	37.3 ± 0.2	37.4 ± 0.3	37.3 ± 0.2
During reperfusion‡	37.6 ± 0.2	37.4 ± 0.3	37.4 ± 0.3

Data are mean ± SD * at 96-h reperfusion, † at 120 min after the onset of ischemia, ‡ at 15 min after the onset of reperfusion during anesthesia.

Hematoxylin and eosin (HE) staining was performed to identify the lesion.

Antisera. Rabbit polyclonal antibodies against myeloperoxidase (1:200 dilution; Neo Markers, Fremont, CA) were used to visualize polymorphonuclear neutrophils (PMNs). Nitrotyrosine was detected with mouse monoclonal antibodies (1:100 dilution; Upstate Biotechnology, Lake Placid, NY).

Immunostaining Procedure. We used an avidin-biotinylated enzyme complex system (Vectastain Universal Elite ABC kit; Vector Laboratories, Burlingame, CA). In brief, sections on the slides were dehydrated with graded alcohols, washed in PBS, and then quenched with 3% H₂O₂ in PBS. The sections were subsequently preincubated for 30 min in a solution containing 2.5% normal horse serum to block nonspecific binding of biotinylated antibody. The sections were then incubated with rabbit polyclonal antimyeloperoxidase antibody or mouse monoclonal antinitrotyrosine antibody in 2.5% normal horse serum at 4°C overnight. After the primary incubation, the sections were rinsed in PBS and subsequently incubated with the biotinylated secondary antibody for 30 min. The sections were then rinsed and incubated with avidin-biotinylated peroxidase conjugate for 30 min. They were finally colorized with diaminobenzidine and H₂O₂ and then counterstained with methyl green acetate. Negative control staining was performed with normal rabbit or mouse sera as a substitute

for the primary antimyeloperoxidase or antinitrotyrosine antibody, respectively.

Polymorphonuclear Neutrophil and Nitrotyrosine-positive Cell Counts. The number of myeloperoxidase- or nitrotyrosine-positive cells was counted at ×200 magnification in the brain parenchyma of the entire ischemic hemisphere at approximately 6 mm from the frontal pole in a blind fashion.

Statistics

Values are expressed as mean ± SD. Body weight, hematocrit, blood glucose, infarct volume, and immunoreactive cell counts were analyzed using one-way analysis of variance. The Tukey-Kramer multiple comparison procedure was then used to determine which pairs of means differed. Differences in mean arterial pressure, arterial blood gases, pericranial temperature, and %rCBF were analyzed using repeated-measures analysis of variance. The Kruskal-Wallis test was used to test the difference in motor neurologic scores. A *P* value less than 0.05 was defined as significant.

Results

One animal from the 100,000 U/kg UTI group died of subarachnoid hemorrhage early after the onset of reperfusion and was excluded from the study.

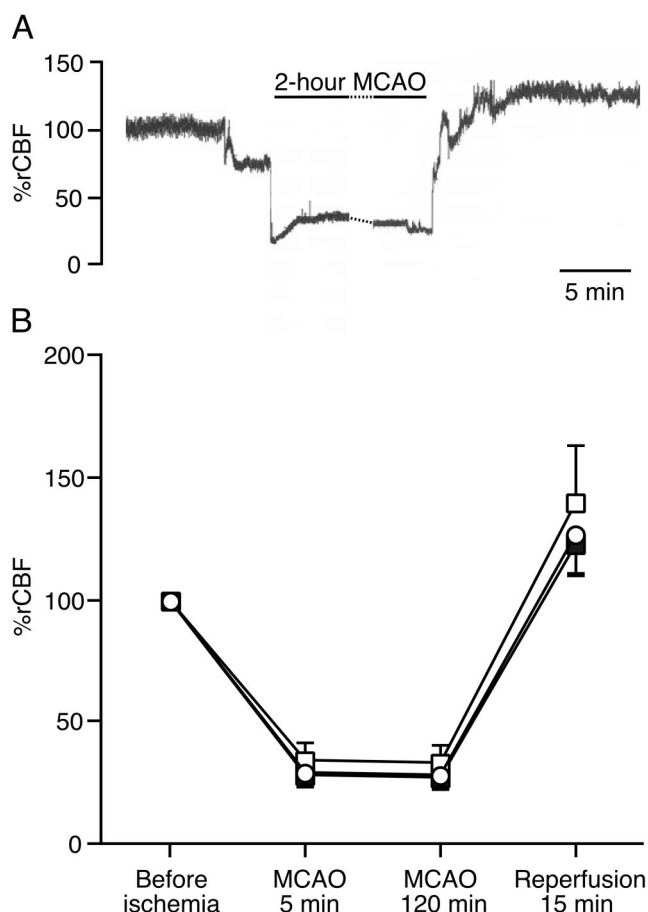


Fig. 1. Relative regional cerebral blood flow (%rCBF) over the right middle cerebral artery (MCA) territory during right MCA occlusion-reperfusion. (A) A demographic record of %rCBF from a saline control rat. (B) Effect of urinary trypsin inhibitor (UTI) pretreatment on changes in %rCBF. No significant difference was observed between the saline control ($n = 9$; open circle), 100,000 U/kg UTI ($n = 8$; open square), and 300,000 U/kg UTI ($n = 9$; closed square) treatment groups ($P = 0.4317$). Data are mean \pm SD. MCAO = middle cerebral artery occlusion.

Physiologic variables in all the groups are shown in table 1. Initial body weight, hematocrit, and blood glucose concentration were not significantly different between the saline, 100,000 U/kg UTI, and 300,000 U/kg UTI treatment groups. Mean arterial pressure, arterial blood gases, and pericranial temperature did not differ significantly among the three treatment groups.

Figure 1 shows the changes in %rCBF over the MCA territory through ischemia and reperfusion. All the experimental groups exhibited a reduction of %rCBF by approximately 70% during MCAO. After 120 min of MCAO, the MCA occlusive filament was withdrawn, and %rCBF was restored and reached to over the 100% level. There were no significant differences in %rCBF among the three groups ($P = 0.4317$).

Figure 2 exhibits the motor neurologic scores at 96 h following 2 h of MCAO. All the animals had some motor neurologic deficits at this time point. In the saline and 100,000 U/kg UTI treatment groups, scores from indi-

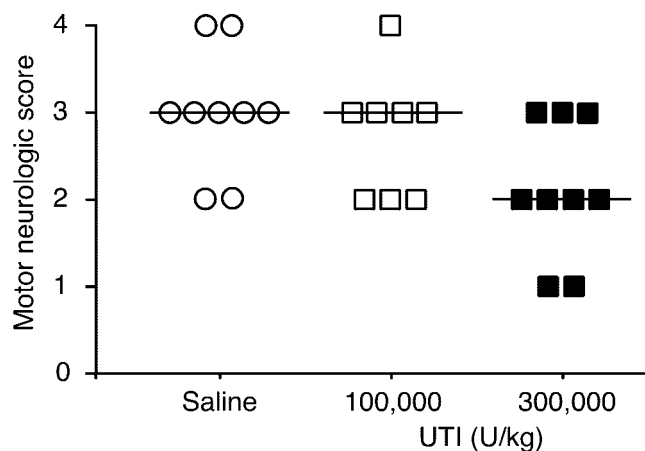


Fig. 2. Motor neurologic scores at 96 h of reperfusion after right middle cerebral artery occlusion. No significant difference was detected among the three treatment groups ($P = 0.0693$). The following five-point scoring scale was used: 0 = no observable deficit; 1 = forelimb flexion; 2 = forelimb flexion and decreased resistance to lateral push; 3 = forelimb flexion, decreased resistance to lateral push, and unilateral circling; 4 = forelimb flexion and being unable or difficult to ambulate. Each symbol depicts the score for an individual rat. Horizontal bars depict median values for each group. UTI = urinary trypsin inhibitor.

vidual animals were distributed between 2 and 4 (median, 3). On the other hand, the distribution of scores from individual animals treated with 300,000 U/kg UTI was between 1 and 3 (median, 2). However, the difference in neurologic scores among the three treatment groups did not reach a significant level ($P = 0.0693$). Body weight loss determined at 96 h after MCAO was similar in all the experimental groups (table 1).

Effects of UTI treatment on the infarct size 96 h after 2 h of MCAO are shown in figures 3 and 4. The total infarct volume was $223 \pm 62 \text{ mm}^3$ in saline control animals. Treatment with 300,000 U/kg UTI significantly reduced the total infarct volume ($119 \pm 50 \text{ mm}^3$) by approximately 50% compared with saline treatment, whereas treatment with 100,000 U/kg UTI showed no significant reducing effects on the total infarct volume ($199 \pm 50 \text{ mm}^3$).

The infiltration of PMNs determined by myeloperoxidase immunoreactivity was observed in the ischemic hemisphere, but few PMNs were seen in the contralateral nonischemic hemisphere (data not shown) from all the animals in each treatment group 96 h after transient MCAO. In all the treatment groups, most of the PMNs in the ischemic hemisphere spanned the infarct region (determined by comparing with the adjacent HE section) and its boundary zone (fig. 5A). The number of PMNs in the ischemic hemisphere is shown in figure 5B. UTI, 300,000 U/kg (117 ± 74), but not 100,000 U/kg UTI (220 ± 126) significantly attenuated the number of PMNs in comparison with saline (251 ± 96) ($P < 0.05$). The difference between both UTI treatment groups did not reach a significant level.

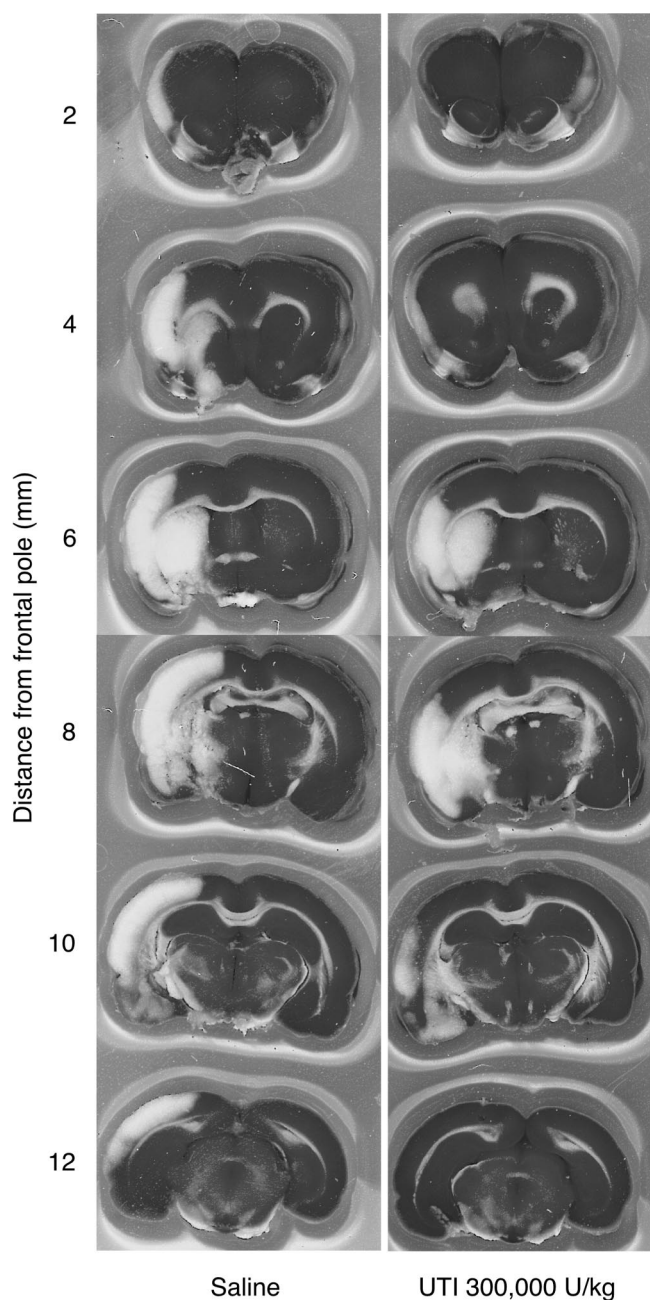


Fig. 3. Representative images of triphenyltetrazolium chloride-stained brain coronal slices captured by the scanner at 96 h of reperfusion after right middle cerebral artery occlusion; gray (originally red) is viable tissue, and white is nonviable infarct tissue. White matter tracts including the corpus callosum also appear white with this stain. Rats pretreated with 300,000 U/kg UTI (*right*) showed less infarct area than saline-pretreated control rats (*left*).

Immunohistochemical reaction of nitrotyrosine, a biochemical marker of peroxynitrite, was detected in the ischemic hemisphere but not in the contralateral non-ischemic hemisphere (data not shown) 96 h following 2 h of MCA occlusion. Nitrotyrosine immunoreactivity was predominantly located in the entire extent of the infarct region (determined by comparing with the adjacent HE section; fig. 6A). The number of nitrotyrosine-

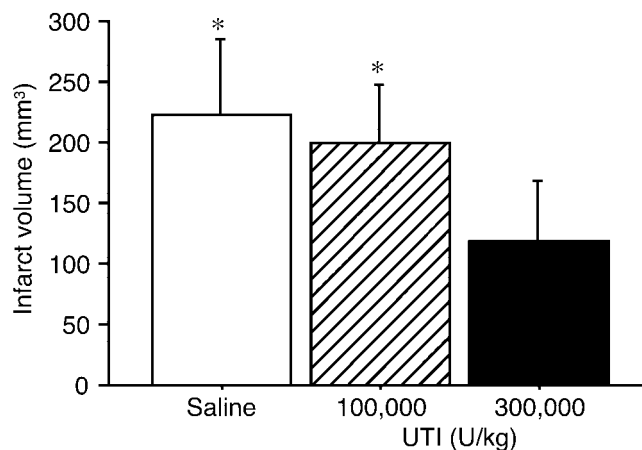


Fig. 4. Effect of urinary trypsin inhibitor (UTI) on the volume of infarct at 96 h of reperfusion after right middle cerebral artery occlusion. There was a significant difference among the three treatment groups ($P = 0.0014$). UTI, 300,000 U/kg ($n = 9$), decreased the volume of infarct compared with saline ($n = 9$) and 100,000 U/kg UTI ($n = 8$). Data are mean \pm SD. * $P < 0.05$ versus 300,000 U/kg UTI.

positive cells in the ischemic hemisphere is shown in figure 6B. UTI, 300,000 U/kg (118 ± 44), reduced the number of nitrotyrosine-positive cells compared with saline (243 ± 102) and 100,000 U/kg UTI (207 ± 54) ($P < 0.05$).

Discussion

Our findings demonstrate that 300,000 U/kg intravenous UTI, administered 10 min before 2-h MCAO, was neuroprotective when evaluated by infarct size, neutrophil infiltration, and nitrotyrosine deposition in the ischemic hemisphere. The treatment tended to improve neurologic outcome but did not reach statistical significance. There are several possible mechanisms for beneficial actions of UTI, which has an antiinflammatory activity, in the brain subjected to focal ischemia-reperfusion.

For the infarct measurement, we used TTC staining at 96 h after MCAO. Liszczak *et al.*²⁰ have reported that there is 93% correlation between histopathology and TTC staining results in the brain specimens subjected to 2 h of MCAO and following reperfusion for 2–48 h. They also have pointed out the limitation of TTC staining in detecting cerebral infarcts. In chronic infarcts, infiltrating macrophages and other inflammatory cells replace damaged neurons and contribute to the red staining with TTC resulting in discoloration in the white region indicative of infarct.²⁰ Their finding suggests that TTC staining underestimates infarct area. In our study, however, the white regions were little discolored and clearly delineated as shown in figure 3. Other investigators who evaluated infarct area at 7 days after MCAO demonstrated good correlation between the histopathology and TTC-determined infarct delineation.^{21,22} TTC staining at

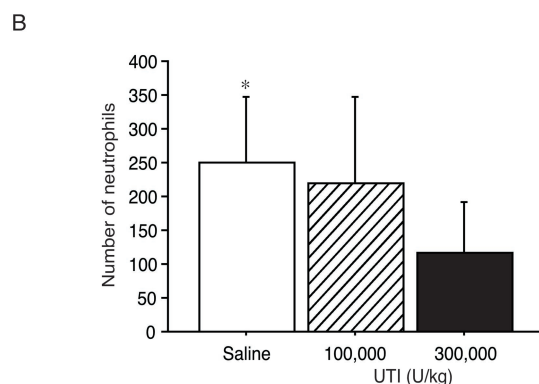
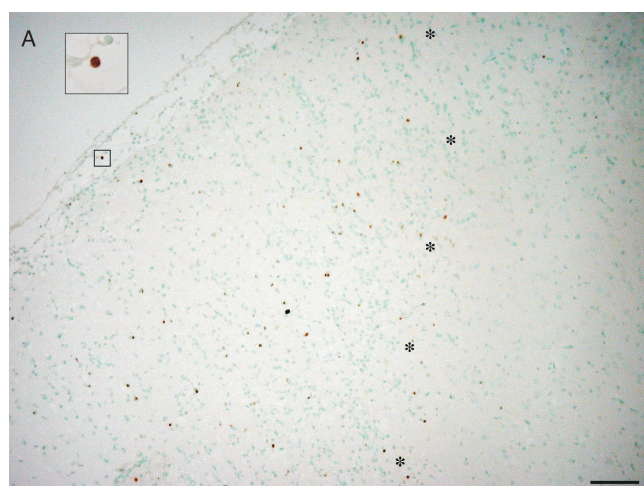


Fig. 5. (A) Photomicrographs of myeloperoxidase-immunostained neutrophils infiltrating in the ischemic hemisphere at 96 h of reperfusion after right middle cerebral artery occlusion in the saline control rat. The large boxed region is an enlargement of the small boxed region, revealing a brown, round cell with myeloperoxidase immunoreactivity. Asterisks indicate a borderline of the infarct zone. Bar = 100 μ m. (B) Number of parenchymal polymorphonuclear neutrophils in the ischemic hemisphere at 96 h of reperfusion after right middle cerebral artery occlusion. Myeloperoxidase-positive cells were counted in 5- μ m-thick sections at approximately 6 mm from the frontal pole. There was a significant difference among the three treatment groups ($P = 0.0247$). Urinary trypsin inhibitor (UTI), 300,000 U/kg ($n = 9$), but not 100,000 U/kg UTI ($n = 8$) decreased the number of polymorphonuclear neutrophils compared with saline ($n = 9$). Data are mean \pm SD. * $P < 0.05$ versus 300,000 U/kg UTI.

96 h after MCAO would have not much complicated the determination of infarct area in the current study.

The evaluation of the functional outcome as well as the histologic morphometry of the infarct region is increasingly acknowledged in the experimental stroke model²³ because improvement of the functional outcome would be a primary goal of cerebroprotective therapies. The five-point scale that we used for the motor neurologic evaluation is easy to carry out and is described to be sensitive to lesions of cortex and basal ganglia after transient MCAO²³; nevertheless, the infarct reduction by 300,000 U/kg UTI did not lead to a significant improvement of the motor neurologic deficit, but only demonstrated a trend toward a lower motor deficit in the

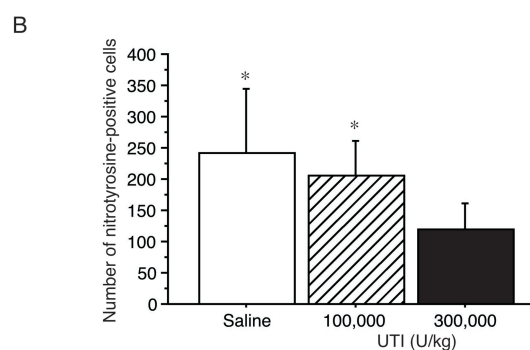
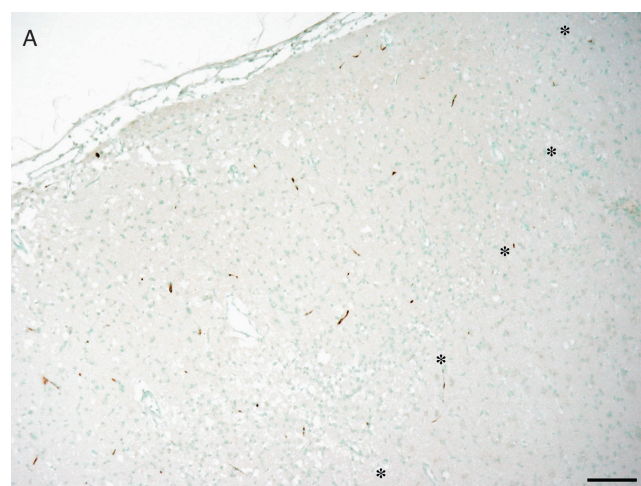


Fig. 6. (A) Photomicrographs of nitrotyrosine immunoreactivity in the ischemic hemisphere at 96 h of reperfusion after right middle cerebral artery occlusion in the saline control rat. Asterisks indicate a borderline of the infarct zone. Bar = 100 μ m. (B) Number of nitrotyrosine-positive cells in the ischemic hemisphere at 96 h of reperfusion after right middle cerebral artery occlusion. Nitrotyrosine-positive cells were counted in 5- μ m-thick sections at approximately 6 mm from the frontal pole. There was a significant difference among the three treatment groups ($P = 0.0042$). Urinary trypsin inhibitor (UTI), 300,000 U/kg ($n = 9$), decreased the number of nitrotyrosine-positive cells compared with saline ($n = 9$) and 100,000 U/kg UTI ($n = 8$). Data are mean \pm SD. * $P < 0.05$ versus 300,000 U/kg UTI.

current study. It is probable that increasing the number of animals in each group would have resulted in a significant improvement of the neurologic scores in the 300,000 U/kg UTI group. Alternatively, the extension of the neurologic scale for higher sensitivity (e.g., the six-point scale including "unilateral circling only if pulled by tail"²⁴) or the use of other kinds of behavioral tasks recognizing functional deficits from cortical or subcortical infarction (e.g., beam balance, prehensile traction, or rotarod²³) might have been required in differentiating between varying degrees of neurologic impairment. Further investigations would therefore be needed to determine the effects of UTI on the motor function after temporary MCAO.

Neutrophil infiltration, the hallmark of acute inflammation, in the ischemic zone occurs to a greater extent in reperfused tissue than in tissue permanently deprived of blood supply in the brain.³ Our results show that UTI

attenuates infiltration of neutrophils in the reperfused brain similarly to the results in the liver and intestine subjected to ischemia-reperfusion obtained by other investigators.^{5,11} In rat liver ischemia-reperfusion, UTI treatment decreases tumor necrosis factor α concentrations in the liver tissue, resulting in reduced infiltrating neutrophils.¹⁰ Tumor necrosis factor α recruits and activates neutrophils and leads to increased neutrophil-endothelial adhesion.³ UTI reduces the production of cytokine-induced neutrophil chemoattractant (the rat form of interleukin 8), blunts neutrophil accumulation, and attenuates injury in the rat liver subjected to ischemia-reperfusion.⁶ The transendothelial migration of neutrophil stimulated by interleukin 8 is also inhibited by UTI.⁷ UTI is a putative inhibitor of neutrophil chemoattractants in the brain and would modify acute inflammatory response emerging from neutrophil infiltration.

Proteases secreted from activated neutrophils in acute inflammation degrade the extracellular matrix, thus leading to tissue destruction.²⁵ Neutrophil elastase, the strongest serine protease, degrades elastin, fibronectin, proteoglycan, and collagen as components of the extracellular matrix.²⁵ The endothelial basement membrane, which restricts the extravasation of granulocytes, is also a target of elastase.²⁶ UTI has been shown not only to inactivate elastase secreted by neutrophils, but also to suppress the production and secretion of elastase from neutrophils.^{8,9} ONO-5046, a neutrophil elastase inhibitor, reduces the size of cerebral infarct elicited by transient MCAO.²⁷ UTI could reduce neutrophil elastase-mediated tissue injury induced by focal cerebral ischemia-reperfusion.

The weight of evidence from well-conducted studies in the brain supports the concept that activated neutrophils play a causative role in the development of ischemia-reperfusion injury since neutropenia attenuates the size of infarct due to transient MCAO.³ The number of neutrophils in the ischemic hemisphere reaches a peak between 24 and 96 h after reperfusion in the rodent model of transient MCAO.^{28,29} However, neutrophil infiltration is still relatively low when the infarct region evaluated by HE staining is near maximal by 12 h after transient MCAO.³⁰ Emerich *et al.*³¹ argue that neutrophil accumulation after transient MCAO is a secondary pathologic and inflammatory reaction in response to the infarct formation. A direct cause and effect relation between the pathogenesis of infiltrating neutrophils and the infarct formation remains controversial. It is still uncertain to what extent the decrease in neutrophil infiltration with UTI treatment contributes to the decrease in infarct size observed in our investigation.

Inflammatory cells, including neutrophils, generate nitric oxide and oxygen free radicals in the course of ischemia-reperfusion.^{32,33} Not only are nitric oxide and superoxide themselves reactive, but they also combine to form the more cytotoxic peroxynitrite, which devas-

tates proteins and tissues.³⁴ The presence of immunoreactivity of nitrotyrosine, a nitration product of tyrosine residues primarily by peroxynitrite, suggests active nitric oxide and superoxide production and resultant cell damage. It has been reported in the transient MCAO model that immunoreactivity of nitrotyrosine found in the infarct region was decreased by inhibition of a nitric oxide synthase.³⁵⁻³⁷ In our model of stroke, diminished nitrotyrosine deposition is indicative of mitigation of acute inflammatory response and coexisting tissue injury mediated by peroxynitrite in the UTI-treated ischemic hemisphere.

During reperfusion, recruited neutrophils aggregate and bind to endothelial cells and plug up the recirculated capillaries, thereby causing perfusion defects after the reestablishment of cerebral circulation and exacerbating ischemic damage.³⁸ It has been shown that UTI inhibits intercellular adhesion molecule 1 expression on endothelial cells stimulated with tumor necrosis factor α ³⁹ and mitigates neutrophil-mediated endothelial injury.⁹ UTI also decreases concentrations of endothelin 1 and angiotensin II and attenuates vasoconstriction to improve microcirculation at acute circulatory insufficiency.^{40,41} There is a possibility that UTI ameliorates the microcirculatory environment in the reperfused brain with a minimum microvascular plugging. Alternatively, UTI may preserve microcirculation in the penumbra, an area of relatively decreased blood flow lying between the ischemic core and the normal brain during ischemia, likely through its action on microvessels. Effects of UTI on infarct size, neutrophil infiltration, and nitrotyrosine formation in our study might have been more directly related to an improvement in microvascular blood flow.

That a single dose of UTI, administered before a 2-h period of ischemia, was neuroprotective is also our concern. The plasma half-life of ¹²⁵I-UTI administered intravenously was 9 min in the initial phase of elimination, and 15% of the radioactivity remained in plasma after 1 h in rats.⁴² The maximum accumulation of ¹²⁵I-UTI radioactivity in the murine brain was obtained at 1 min after the intravenous injection, amounting to 0.24% of total amount of administered ¹²⁵I-UTI.⁴³ The levels of radioactivity declined rapidly to one sixth and one twenty-fourth of the maximum level after 1 and 4 h, respectively, and no radioactivity was detected 12 h later in the brain.⁴³ The blood-brain barrier permeability of UTI with a molecular weight of 67,000 is unknown in the injured brain. Kuroiwa *et al.*⁴⁴ demonstrated a biphasic opening of the blood-brain barrier to proteins occurring first at 15 min and then at 5-72 h following temporary MCAO. The passage of UTI through the blood-brain barrier might increase shortly after the onset of reperfusion. A 6- to 10-times-higher dose of UTI (300,000 U/kg) in our investigation compared with that in the liver or intestine ischemia-reperfusion^{5,6,11} might have contributed to the blood-brain barrier penetration of UTI given

before MCAO. We further speculate the higher dose of UTI effectively inhibited intraluminal key events for the initiation of acute inflammatory response (e.g., the expression of inflammatory mediators such as inflammatory cytokines, chemokines, and adhesion molecules).

UTI in the human cerebrospinal fluid increases in patients with brain tumor or subarachnoid hemorrhage, but it is not affected by systemic UTI.⁴⁵ A UTI-like immunoreactive substance with trypsin-inhibitory activities has been found in the murine brain, and its content was increased by brain injury.⁴⁶ Protease inhibitors derived from neuronal cells have been reported to function as regulators of neurite outgrowth and regeneration.⁴⁷ These findings hint that UTI, produced in the brain parenchyma, is involved in repair processes of injured neurons. It is unknown whether exogenous UTI has a similar action in the brain parenchyma in our model of cerebral injury.

In conclusion, prophylactic use of intravenous UTI is neuroprotective against focal ischemia-reperfusion injury in the brain, possibly through the antiinflammatory action. With the available data, precise mechanisms of this neuroprotection remain obscure. UTI has been clinically applied for the treatment of acute pancreatitis and shock without major side effects.^{48,49} UTI could potentially be beneficial for patients undergoing surgeries prone to stroke.

References

- Barone FC, Feuerstein GZ: Inflammatory mediators and stroke: New opportunities for novel therapeutics. *J Cereb Blood Flow Metab* 1999; 19:819-34
- Larrue V, von Kummer RR, Muller A, Bluhmki E: Risk factors for severe hemorrhagic transformation in ischemic stroke patients treated with recombinant tissue plasminogen activator: A secondary analysis of the European-Australasian Acute Stroke Study (ECASS II). *Stroke* 2001; 32:438-41
- Jean WC, Spellman SR, Nussbaum ES, Low WC: Reperfusion injury after focal cerebral ischemia: The role of inflammation and the therapeutic horizon. *Neurosurgery* 1998; 43:1382-96
- Becker KJ: Inflammation and acute stroke. *Curr Opin Neurol* 1998; 11:45-9
- Li XK, Matin AF, Suzuki H, Uno T, Yamaguchi T, Harada Y: Effect of protease inhibitor on ischemia/reperfusion injury of the rat liver. *Transplantation* 1993; 56:1331-6
- Yamaguchi Y, Ohshiro H, Nagao Y, Odawara K, Okabe K, Hidaka H, Ishihara K, Uchino S, Furuhashi T, Yamada S, Mori K, Ogawa M: Urinary trypsin inhibitor reduces C-X-C chemokine production in rat liver ischemia/reperfusion. *J Surg Res* 2000; 94:107-15
- Okumura Y, Inoue H, Fujiyama Y, Bamba T: Effects of serine protease inhibitors on accumulation of polymorphonuclear leukocytes in the lung induced by acute pancreatitis in rats. *J Gastroenterol* 1995; 30:379-86
- Endo S, Inada K, Yamashita H, Takakuwa T, Nakae H, Yamada Y, Kasai T, Taki K, Yoshida M: The inhibitory actions of protease inhibitors on the production of polymorphonuclear leukocyte elastase and interleukin 8. *Res Commun Chem Pathol Pharmacol* 1993; 82:27-34
- Nakatani K, Takeshita S, Tsujimoto H, Kawamura Y, Sekine I: Inhibitory effect of serine protease inhibitors on neutrophil-mediated endothelial cell injury. *J Leukoc Biol* 2001; 69:241-7
- Aihara T, Shiraishi M, Hiroyasu S, Hatsuse K, Mochizuki H, Seki S, Hiraide H, Muto Y: Ulinastatin, a protease inhibitor, attenuates hepatic ischemia/reperfusion injury by downregulating TNF- α in the liver. *Transplant Proc* 1998; 30:3732-4
- Li XK, Suzuki H, Kimura T, Kawabe A, Uno T, Harada Y: Ulinastatin, a protease inhibitor, attenuates intestinal ischemia/reperfusion injury. *Transplant Proc* 1994; 26:2423-5
- Nakahama H, Obata K, Sugita M: Ulinastatin ameliorates acute ischemic renal injury in rats. *Ren Fail* 1996; 18:893-8
- Cao ZL, Okazaki Y, Naito K, Ueno T, Natsuaki M, Itoh T: Ulinastatin attenuates reperfusion injury in the isolated blood-perfused rabbit heart. *Ann Thorac Surg* 2000; 69:1121-6
- Horiguchi T, Harada Y: The effect of protease inhibitor on reperfusion injury after unilateral pulmonary ischemia. *Transplantation* 1993; 55:254-8
- Abe H, Sugino N, Matsuda T, Kanamaru T, Oyanagi S, Mori H: Effect of ulinastatin on delayed neuronal death in the gerbil hippocampus [in Japanese]. *Masui* 1996; 45:38-43
- Yamada K, Goto S, Yoshikawa M, Okamura A, Ushio Y: Continuous intraventricular drug infusion for the in vivo study of transneuronal degeneration in the striatonigral system of the rat. *Brain Res Brain Res Protoc* 1997; 1:371-7
- Prestigiacomo CJ, Kim SC, Connolly ES Jr, Liao H, Yan SF, Pinsky DJ: CD18-mediated neutrophil recruitment contributes to the pathogenesis of reperfusion but not nonreperfusion stroke. *Stroke* 1999; 30:1110-7
- Mokudai T, Ayoub IA, Sakakibara Y, Lee EJ, Ogilvy CS, Maynard KI: Delayed treatment with nicotinamide (Vitamin B₃) improves neurological outcome and reduces infarct volume after transient focal cerebral ischemia in Wistar rats. *Stroke* 2000; 31:1679-85
- Yang Y, Shuaib A, Li Q: Quantification of infarct size on focal cerebral ischemia model of rats using a simple and economical method. *J Neurosci Methods* 1998; 84:9-16
- Liszczak TM, Hedley-Whyte ET, Adams JF, Han DH, Kolluri VS, Vacanti FX, Heros RC, Zervas NT: Limitations of tetrazolium salts in delineating infarcted brain. *Acta Neuropathol (Berl)* 1984; 65:150-7
- Sager TN, Hansen AJ, Laursen H: Correlation between N-acetylaspartate levels and histopathologic changes in cortical infarcts of mice after middle cerebral artery occlusion. *J Cereb Blood Flow Metab* 2000; 20:780-8
- Nakamura M, Nakakimura K, Matsumoto M, Sakabe T: Rapid tolerance to focal cerebral ischemia in rats is attenuated by adenosine A₁ receptor antagonist. *J Cereb Blood Flow Metab* 2002; 22:161-70
- Zausinger S, Hungerhuber E, Baethmann A, Reulen H, Schmid-Elsaesser R: Neurological impairment in rats after transient middle cerebral artery occlusion: A comparative study under various treatment paradigms. *Brain Res* 2000; 863:94-105
- Menzies SA, Hoff JT, Betz AL: Middle cerebral artery occlusion in rats: A neurological and pathological evaluation of a reproducible model. *Neurosurgery* 1992; 31:100-6
- Owen CA, Campbell EJ: The cell biology of leukocyte-mediated proteolysis. *J Leukoc Biol* 1999; 65:137-50
- Zimmerman BJ, Granger DN: Reperfusion-induced leukocyte infiltration: Role of elastase. *Am J Physiol* 1990; 259:H390-4
- Shimakura A, Kamanaka Y, Ikeda Y, Kondo K, Suzuki Y, Umemura K: Neutrophil elastase inhibition reduces cerebral ischemic damage in the middle cerebral artery occlusion. *Brain Res* 2000; 858:55-60
- Matsuo Y, Onodera H, Shiga Y, Nakamura M, Ninomiya M, Kihara T, Kogure K: Correlation between myeloperoxidase-quantified neutrophil accumulation and ischemic brain injury in the rat. Effects of neutrophil depletion. *Stroke* 1994; 25:1469-75
- Stevens SL, Bao J, Hollis J, Lessov NS, Clark WM, Stenzel-Poore MP: The use of flow cytometry to evaluate temporal changes in inflammatory cells following focal cerebral ischemia in mice. *Brain Res* 2002; 932:110-9
- Zhang RL, Chopp M, Chen H, Garcia JH: Temporal profile of ischemic tissue damage, neutrophil response, and vascular plugging following permanent and transient (2H) middle cerebral artery occlusion in the rat. *J Neurol Sci* 1994; 125:3-10
- Emerich DF, Dean RL 3rd, Bartus RT: The role of leukocytes following cerebral ischemia: Pathogenic variable or bystander reaction to emerging infarct? *Exp Neurol* 2002; 173:168-81
- Dinaghi U, Iadecola C, Moskowitz MA: Pathobiology of ischaemic stroke: An integrated view. *Trends Neurosci* 1999; 22:391-7
- Forster C, Clark HB, Ross ME, Iadecola C: Inducible nitric oxide synthase expression in human cerebral infarcts. *Acta Neuropathol (Berl)* 1999; 97:215-20
- Nakazawa H, Fukuyama N, Takizawa S, Tsuji C, Yoshitake M, Ishida H: Nitrotyrosine formation and its role in various pathological conditions. *Free Radic Res* 2000; 33:771-84
- Eliasson MJ, Huang Z, Ferrante RJ, Sasamata M, Molliver ME, Snyder SH, Moskowitz MA: Neuronal nitric oxide synthase activation and peroxynitrite formation in ischemic stroke linked to neural damage. *J Neurosci* 1999; 19:5910-8
- Parmentier-Batteur S, Bohme GA, Lerouet D, Zhou-Ding L, Beray V, Margail I, Plotkine M: Antisense oligodeoxynucleotide to inducible nitric oxide synthase protects against transient focal cerebral ischemia-induced brain injury. *J Cereb Blood Flow Metab* 2001; 21:15-21
- Gürsoy-Özdemir Y, Bolay H, Saribas O, Dalkara T: Role of endothelial nitric oxide generation and peroxynitrite formation in reperfusion injury after focal cerebral ischemia. *Stroke* 2000; 31:1974-80
- del Zoppo GJ, Schmid-Schonbein GW, Mori E, Copeland BR, Chang CM: Polymorphonuclear leukocytes occlude capillaries following middle cerebral artery occlusion and reperfusion in baboons. *Stroke* 1991; 22:1276-83
- Aosasa S, Ono S, Seki S, Takayama E, Tadakuma T, Hiraide H, Mochizuki H:

Inhibitory effect of protease inhibitor on endothelial cell activation. *J Surg Res* 1998; 80:182-7

40. Tani T, Abe H, Endo Y, Hanasawa K, Kodama M: Effects of a urinary trypsin inhibitor on acute circulatory insufficiency after surgical operation. *Am J Surg* 1998; 175:142-5

41. Nakajima K, Goto Y: Differentiation of the anti-shock effect of ulinastatin from steroid hormone, by the continuous observation of microcirculation dynamics. *Circ Shock* 1992; 36:284-9

42. Jönsson-Berling BM, Ohlsson K: Distribution and elimination of intravenously injected urinary trypsin inhibitor. *Scand J Clin Lab Invest* 1991; 51:549-57

43. Sugiki M, Sumi H, Maruyama M, Yoshida E, Mihara H: Clearance and distribution of acid-stable trypsin inhibitor (ASTI). *Enzyme* 1989; 42:31-8

44. Kuroiwa T, Ting P, Martinez H, Klatzo I: The biphasic opening of the

blood-brain barrier to proteins following temporary middle cerebral artery occlusion. *Acta Neuropathol (Berl)* 1985; 68:122-9

45. Iwama H, Ohmori S, Tsutsumi T: Detectable concentrations of urinary trypsin inhibitor in cerebrospinal fluid. *J Neurosurg Anesthesiol* 2000; 12:29-32

46. Shikimi T, Wessel T, Joh TH, Takahashi M, Kaneto H, Hattori K, Takaori S: Demonstration of a human urinary trypsin inhibitor (urinastatin)-like substance in the murine brain. *Brain Res* 1993; 616:230-5

47. Monard D: Cell-derived proteases and protease inhibitors as regulators of neurite outgrowth. *Trends Neurosci* 1988; 11:541-4

48. Takeda K: Protease inhibitors in the treatment of pancreatitis [in Japanese]. *Nippon Rinsho* 1991; 49:2125-9

49. Motoki R, Inoue H: Protease inhibitors in shock [in Japanese]. *Nippon Rinsho* 1991; 49:2090-4