

Ambient O.R. Temperatures and Datex-Ohmeda 7900 SmartVent Malfunction

To the Editor:—I read with great interest the report by Cantillo *et al.*,¹ regarding malfunction of flow sensors on the Datex-Ohmeda 7900 SmartVent (Madison, WI). Our department owns 15 such ventilators. We too experienced moisture buildup resulting in problems generating the desired tidal volume. Similar to the authors, our anesthesia assistants and engineers were asked to replace sensors, or the system integration board, on several occasions in 2000.

Our own experience differs from that reported in that we do not routinely use heated humidifiers. We did not experience this problem initially (1997–1999). During this period, the 7900s were located in the pediatric operating rooms, where the procedures are brief, and the ambient temperature warm. In 2000, these machines were placed in the adult orthopedic operating rooms where ambient temperatures are routinely low, the cases frequently exceed 3 h, and fresh gas flow is usually less than 2 l.

I believed that factors other than active humidification (low ambient temperature, low gas flows) contributed to this problem, and contacted Datex-Ohmeda. After several meetings with their engineers and

customer representatives, they produced a flow sensor designed to minimize moisture buildup. As a result of this and nightly moisture inspections by our anesthesia assistants, the problem has all but vanished.

The authors suggest that Datex-Ohmeda issue a warning regarding heated, humidified circuits. I would be interested to learn if other anesthesiologists have experienced altered performance of this equipment as a result of cold operating rooms. If so, then perhaps the product warning should also include a statement to this effect.

Jordan L. Blinder, M.D. Department of Anesthesiology, Baystate Medical Center, Springfield, Massachusetts. mdjlb@aol.com

Reference

1. Cantillo J, Domskey R, Gratz I, Goldberg M: Ventilatory Failures with the Datex-Ohmeda 7900 SmartVent. *ANESTHESIOLOGY* 2002; 96:766–768

(Accepted for publication July 27, 2002.)

In Reply:—We wish to thank the editor for allowing us to reply to Dr. Blinder's correspondence.¹

As stated in our case report² we have eliminated heated circuits from our anesthesia machines that have the SmartVent 7900 ventilator (Datex-Ohmeda, Madison, WI). This has dramatically decreased the problem described in our case report.

We agree with Dr. Blinder that low gas flows contribute to the condensation in the ventilator sensor. However, we feel that ambient temperature plays a minor role in sensor malfunction. The Smart Vent 7900 anesthesia machines are used extensively in our trauma rooms, which are kept warm to avoid patient heat loss. We have experienced the same rate of sensor malfunction in these suites compared with our regular operating room suites, which are kept much cooler. We do find that long cases, over 3 to 4 h, play a role in the sensor malfunctioning. Recently, one of the system integration boards (SIB) was replaced on one of the anesthesia machines used in one of the trauma rooms.

The revised flow sensors from Datex-Ohmeda minimize the moisture buildup that cause the sensors to fail. We have had a very good experience with them.

Joaquin Cantillo, M.D.,* Irwin Gratz, D.O., Richard Domskey, M.D., Michael E. Goldberg, M.D. The Cooper Health System, Camden, New Jersey. jicantillo@cs.com

References

1. Binder JL, Ambient OR: Temperatures and Datex-Ohmeda 7900 SmartVent Malfunction: Letter to the Editor, *ANESTHESIOLOGY* 2002; 97:1645
2. Cantillo J, Domskey R, Domskey R, Goldberg M: Ventilatory Failures with the Datex-Ohmeda 7900 Smart Vent. *ANESTHESIOLOGY* 2002; 96:766–768

(Accepted for publication July 27, 2002.)

Traumatic Retropharyngeal Hematoma Necessitating Emergency Intubation

To the Editor:—In patients with cervical spine trauma (CST) it is possible for a hematoma to form in the potential space between the pharynx and cervical spine. Retropharyngeal hematoma (RPH) large enough to require tracheal intubation is rare, but can be a life threatening emergency.

A 37-yr-old man was admitted to the emergency department of the Amiens University Hospital 1 h after being injured in a motor vehicle collision. After a brief loss of consciousness, the patient noted pain at the base of the neck. His cervical spine had been

immobilized at the scene of the accident. When he arrived at the hospital, he was alert and orientated. His pulse was 90 beats/min, blood pressure 140/70 mmHg and his respiratory rate was 12 breaths/min. Neurologic examination revealed no motor deficit and all cranial nerves were intact. The patient was not dyspneic, his chest was clear, and his heart had a regular rate and rhythm. The abdominal examination was normal.

The laboratory values were within normal limits. A chest radiograph revealed a fracture of the right clavicle. A computed tomography (CT) scan of the cervical spine showed a fracture of the body of the sixth cervical vertebra with a hematoma that extended from the forth cer-

Support was provided solely from institutional and/or departmental sources.

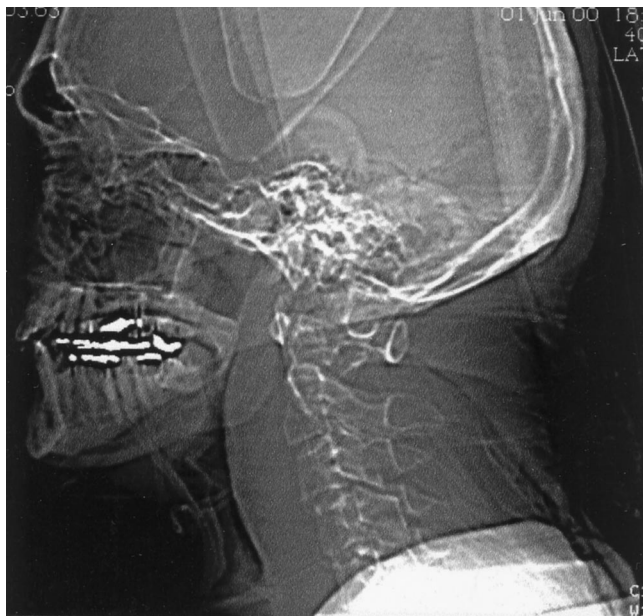


Fig. 1. A computed tomography (CT) scan of the cervical spine shows a fracture of the body of the sixth cervical vertebra with a hematoma that extends from the forth cervical vertebra to the upper mediastinum and occupies the pharyngeal space.

vical vertebra to the upper mediastinum and occupied the pharyngeal space (fig. 1). The head CT scan was normal.

The neurosurgeon recommended continuation of strict cervical spine immobilization, and the patient was transferred to the Department of Neurosurgery.

Ten hours after the patient's admission, he began complaining of dysphagia and neck pain, and he quickly developed marked stridor and dyspnea. Peripheral saturation of oxygen was 86%.

The patient was immediately transferred to the intensive care unit. An awake fiberoptic nasal intubation was done. During endoscopy a posterior soft tissue swelling that extended from oropharynx to the glottis was noted. The vocal cords were easily visualized; a 7.5 mm endotracheal tube was passed over the bronchoscope. After intubation, the patient remained alert, cooperative, and neurologically intact. He was sedated (Midazolam 5 mg/h and Sufentanil 15 μ g/h and received mechanical ventilation. On the sixth day after admission, a direct laryngoscopic examination of the airway revealed a diminution of the soft tissue swelling. The patient was weaned easily from the ventilator and the trachea was extubated. He was then able to maintain adequate oxygenation on 2 l/min of oxygen by nasal cannula; he was comfortable with no dyspnea or stridor.

A conservative approach with cervical brace was chosen and the patient was discharged home 9 days after initial presentation.

Although soft-tissue swelling is common with cervical spine injuries, there are few reports of airway obstruction secondary to retropharyngeal hematomas in the literature.¹ Penning² reported that 18 of 30 patients hospitalized for CST had widening of prevertebral soft tissue due to hematoma.

In trauma patients, retropharyngeal hematomas are associated with a range of conditions including cervical extension and flexion severe injury and whiplash injury in great-vessel trauma,³ minor blunt head trauma with hyperextension of the neck⁴, or minor motor vehicle collision with air bag deployment.⁵ The possibility of RPH should be taken into account after CST or head trauma in all patients regardless of age, severity of trauma, or lack of symptoms.

The mechanism of hemorrhage is unclear. One possible mechanism involves tearing of the longus colli muscles along the anterior aspect of

the vertebral bodies during hyperextension. Alternatively, hyperextension injuries may rupture the anterior muscular and spinal branches of the vertebral column.²

The signs of RPH include those of superior mediastinal obstruction and bruising on the neck and spreading to the chest wall. The symptoms may include neck pain, dysphagia, dyspnea, and a hoarse voice. Although most retropharyngeal hematomas present immediately or within hours after they arise, delays of 2–5 days from the onset of initial symptoms to airway obstruction have been reported.¹

A lateral radiograph or CT scan of the neck, which will show a widening of prevertebral space, aids the diagnosis. Symptoms may take hours to develop and initial cervical radiographs often fail to show evidence of retropharyngeal swelling and impending airway obstruction. The majority of the hematomas occurred at C1–C4 and this phenomenon has not been reported in injuries below C6.¹ The normal width of the prevertebral soft tissue is 3.2 mm measured at C2. In our patient the width of prevertebral soft tissue at C5 was 8 mm.

Treatment depends on the location and size of the hematoma as well as the clinical course of the patient. Patients with small, nonexpanding, hematomas should be observed in hospital.⁶ Resolution of the hematoma can be assessed regularly radiographically. Penning also reported that radiographic resolution of the prevertebral hematomas occurred within 14 days.²

Symptomatic patients should be strictly monitored to promptly establish airway patency. Equipment should be assembled and ready for immediate use. In the case of lower RPH after CST, tracheal intubation may be needed and great care should be taken to protect the spinal cord. Blind nasotracheal approach can be attempted but oral or nasal fiberoptic intubation has become a mainstay in the management of patients with CST. An oral fiberoptic intubation would have been attempted if the patient had signs or documentation of nasal or basilar skull fractures, or if it was believed that nasal approach might rupture the hematoma. Direct laryngoscopy with a rigid blade may produce some movements of the column, but it is the only choice in an emergency setting, the physician should avoid lateral and rotational movements and remember that extension of the neck widens, rather than constricts, the spinal canal.⁷

A tracheostomy may be needed if there is upper airway obstruction or a difficult intubation. Surgical evacuation of the hematoma is indicated when there is life threatening airway obstruction or a rapidly expanding hematoma, and in those that fail to reabsorb.⁶

Retropharyngeal hematomas must be considered as a cause of airway obstruction following cervical spine trauma. A high index of suspicion and early lateral neck radiograph is essential for safe management of this rare but potentially life-threatening injury.

Chafik El Kettani, M.D., Rachid Badaoui, M.D.,* François Xavier Lesoin, M.D., Daniel Le Gars, M.D., Michel Ossart, M.D. *Amiens University Hospital, Place Victor Pauchet, 80054 Amiens, France. badaouir@voila.fr

References

1. Kuhn JE, Graziano GP: Airway compromise as a result of retropharyngeal hematoma following cervical spine injury. *J Spinal Disord* 1991; 4:264–9
2. Penning L: Prevertebral hematoma in cervical spine injury: Incidence and etiologic significance. *Am J Roentgenol* 1981; 136:553–61
3. Myssuikrek D, Shalmi C: Traumatic retropharyngeal hematoma. *Arch Otolaryngol Head Neck Surg* 1989; 115:1130–2
4. Smith JP, Morrissey P, Hemmick RS, Haas AF, Bodai BI: Retropharyngeal hematomas. *J Trauma* 1988; 28:553–4
5. Tenofsky PL, Porter SW, Shaw JW: Fatal airway compromise due to retropharyngeal hematoma after airbag deployment. *Am Surg* 2000; 67:692–4
6. Daniello NJ, Goldstein SI: Retropharyngeal hematoma secondary to minor blunt head and neck trauma. *Ear Nose Throat J* 1994; 73:41–3
7. Piek J, Bock WG, Vollmer DG: Management of the patient with acute spinal cord injury: Pre-ICU treatment. In Hacke W (ed): *Neurocritical care*. Berlin, Heidelberg: Springer-Verlag 1994, p 718.

(Accepted for publication June 11, 2002.)

Fiberoptic Transorbital Intubation: Alternative for Tracheotomy in Patients after Exenteration of the Orbit

To the Editor:—Anesthesiologists are occasionally faced with patients who develop a seriously compromised ability to open their mouths due to previous otolaryngeal operations, which often prevents conventional intubation. We are reporting the case of a patient with a frozen temporomandibular joint due to a previous radical resection of a maxillary carcinoma with orbital exenteration, who could only be fiberoptically intubated *via* his orbit. This 49-yr-old man was scheduled for closure of a fistula between the oral cavity and the maxillary sinus. A nasal and oral fiberoptic approach was not possible because of excessive scarring in the patient's nasopharynx and due to a frozen temporomandibular joint. Therefore, the only possible way to avoid tracheotomy was fiberoptically-guided intubation through the patient's orbit. We decided to perform awake fiberoptic intubation to maintain spontaneous breathing throughout the whole procedure. After adequate premedication the bronchoscope was prepared with an 8.5 mm endotracheal tube and inserted into the orbit. It was easily passed through the neo-maxillary sinus into the larynx. After visualization of the vocal cords the 8.5 mm endotracheal tube was placed without any difficulty into the trachea with the 25 cm mark at the edge of the orbit (fig. 1). The patient was breathing spontaneously and oxygen saturation remained at 100% throughout the procedure.

To the best of our knowledge this is the first time that a fiberoptically-guided intubation, using the orbit and maxillary sinus to access the trachea, has been reported. There have only been two reports of similar approaches to the patient's airway after head and neck surgery. However, in the case of Brusis and Hoepfner¹ as well as in the case of Foroughi *et al.*,² general anesthesia was induced before the airway was secured. This does not seem to be state of the art, because if there are indications that ventilation *via* facemask might be insufficient or even impossible, the main advantage in the spontaneously breathing patient is that the procedure can safely be discontinued if the attempt fails.³ Thus, the orbital approach in the spontaneous breathing patient was the easiest, safest, and also most convenient way of intubation.

In conclusion, the technique we describe for the first time offers safe and elegant airway management for patients with a frozen temporomandibular joint and airway alterations, including a communication

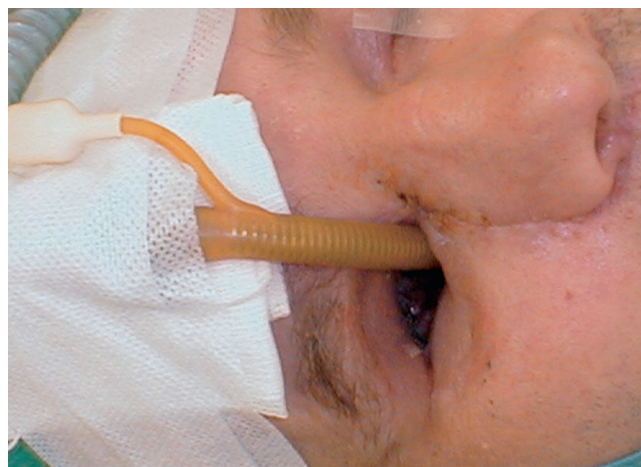

Fig. 1. The endotracheal tube was placed fiberoptically through the right orbit, which was communicating with the larynx.

between the orbit and the larynx. This case reminds the anesthesiologist that a full understanding of prior head and neck surgery can lead to case-specific insights about airway management that may be superior to conventional approaches.

Michael Sander, M.D.,* Christian Lehmann, M.D., Cyrus Djamchidi, M.D., D.D.S., Konrad Haake, M.D., D.D.S., Claudia D. Spies, M.D., Wolfgang J. Kox, M.D., Ph.D. F.R.C.P. University Hospital Charité, Humboldt University Berlin, Germany. michael.sander@charite.de

References

1. Brusis T, Hoepfner J: Eine ungewöhnliche Intubation (letter). *Anaesthesist* 1975; 24:461
2. Foroughi V, Williams EL, Ferrari HA: Transorbital endotracheal intubation after maxillectomy and orbital exenteration. *Anesth Analg* 1994; 79:801-2
3. Benumof JL: Management of the difficult adult airway. *ANESTHESIOLOGY* 1991; 75:1087-110

(Accepted for publication July 24, 2002.)

Support was provided solely from institutional and/or departmental sources.

Chewing Gum on a Laryngeal Mask Airway™

To the Editor:—We recently had a case that we would like to bring to the attention of the anesthesia community. A 52-yr-old woman was admitted to our hospital as an outpatient to have a right breast mass excised. Her American Society of Anesthesiologists physical status was II; her Mallampati airway score was also II. She reported ingesting nothing by mouth (NPO) for more than 6 h. Her preoperative examination was unremarkable, other than hypertension. The importance of being NPO was explained previously by the surgeon's office, and it was reconfirmed during our preoperative examination the morning of surgery. The patient volunteered that she had not even drank water since midnight.

Support was provided solely from institutional and/or department sources.

After a slow induction by propofol (2.5 mg/kg) and fentanyl (100 µg), the patient was intubated with a #4 disposable *Laryngeal Mask Airway™* (LMA North America, Inc., San Diego, CA) on the first attempt with no difficulties. The cuff of the *Laryngeal Mask Airway™* was inflated with 30 ml of air. After the intubation, a leak test was performed, and leak pressure was recorded as 30 cm H₂O. Anesthesia was maintained with 1 minimum alveolar concentration (MAC) desflurane for about 140 min in the supine position with maximum of 23 cm H₂O peak airway pressure to provide approximately 700 ml tidal volume with assisted spontaneous breathing. Flawless emergence of the patient was followed by the extubation of the *Laryngeal Mask Airway™*. At that time, we discovered a green gummy mass at the tip of the *Laryngeal Mask Airway™*. Other

than a slight dirty appearance on the inner surface of the *Laryngeal Mask AirwayTM*, nothing was out of the ordinary.

The patient was followed in the recovery room for an hour; she was fully awake and oriented. She didn't complain of sore throat, nausea, dysphagia, or dysphonia. When asked, she said that she was chewing a gum on the way to the hospital, but couldn't remember whether she threw it away before going into surgery. None of the holding-area nurses, the nurse-anesthetist, nor the attending anesthesiologist (myself) realized that the patient had been chewing gum preoperatively.

It appears that some patients do not consider chewing gum as a part of their NPO status; therefore, it would be wise to question patients specifically for nonnutritious products such as chewing gum.

Mary Wenke, C.R.N.A., Ozan Akça, M.D. University of Louisville, Louisville, Kentucky. ozan.akca@louisville.edu

(Accepted for publication August 22, 2002.)