

Decompression of Ludwig Angina under Cervical Block

Manish Mehrotra, M.D.,* Sandeep Mehrotra, M.S., D.N.B.†

LUDWIG angina is a potentially lethal, rapidly spreading cellulitis involving the floor of the mouth and neck.¹ Without aggressive management it often results in life threatening upper airway obstruction.² Prompt airway management is critical, but the presence of swelling of the neck, glottic edema, elevation of the tongue, trismus, or pharyngeal edema create formidable problems.¹ There is no consensus in the literature regarding airway management. The published recommendations vary and are based on each author's personal experience and available resources. We report a patient with Ludwig angina and severe airway compromise who presented at a remote field hospital. We successfully relieved airway obstruction by surgical decompression alone, using a cervical plexus block.

Case Report

A 42-yr-old woman from a remote border village was brought to our field hospital in respiratory distress. She had a 5-day history of increasing pain and swelling in the left submandibular region associated with fever and dysphagia. For the last 24 h she had been unable to speak and had respiratory difficulty. Treatment using indigenous medicines and balms had been ineffective. The patient weighed 45 kg, had a respiratory rate of 44 breaths/min with intercostal retraction and stridor. Her blood pressure record was 110/70 mmHg with pulse rate of 110 beats/min and temperature of 38.8°C. Examination showed a marked brawny edema over the left submental and submandibular spaces, extending across to the right and down to the anterior chest. There was significant trismus with protrusion of the grossly edematous and elevated tongue. Examination of the oropharynx was not possible (fig. 1). Administration of oxygen was started immediately with a Bain breathing system and a facemask using a flow rate of 6 l/m and further investigations were undertaken. She had leucocytosis (WBC 18,600/mm³) and normal hemoglobin of 11 g/dl. Soft tissue radiograph of the neck showed a narrowed glottic opening. Intravenous antibiotics were started (cefotaxime, amikacin, and metronidazole). In view of her respiratory distress and stridor, urgent surgical decompression was deemed necessary. She was taken to the operating room for airway control as she became increasingly restless with increase in tachypnea to 60 breaths/min. At this time, her SpO₂ was 86% by pulse oximetry. Due to gross trismus and swelling of the tongue and oropharyngeal tissues, an orotracheal or awake blind nasotracheal intubation was not considered feasible. It was thus decided to attempt a trial of decompression under cervical plexus block. Complete preparations for an emergency tracheostomy were also made.

She was given 0.2 mg of intravenous glycopyrrolate and standard

monitors were placed. An intradermal wheal was raised over the left C3 and C4 transverse processes after preparing the area aseptically. Deep cervical plexus was blocked with single injection over C4 using 4 ml of 1% lignocaine. A needle was introduced through the skin over C3 transverse process and 6 ml of 1% lignocaine was injected both cephalad and caudal along the posterior inferior border of sternocleidomastoid. By this method, superficial cervical plexus was blocked.

Dense anesthesia was established in about 7 min. A rapid decompression of the left submandibular region was done and the mylohyoid transected with resultant lowering of the floor of mouth. There was little discharge from the wound, which was lightly packed and dressed. The patient was observed for 30 min in the operating room where her stridor and respiratory distress showed remarkable improvement. Her respiratory rate stabilized to 24 breaths/min after 1 h of observation in the acute ward. Her subsequent convalescence was rapid and uneventful and she resumed oral diet on the second postoperative day.

Discussion

The danger of airway obstruction from soft tissue swelling in the head and neck has been appreciated since antiquity, with specific references being made by Hippocrates, Galen, Aretius, and Paulus of Aegin. Wilhelm Frederick von Ludwig in 1836 described "repeated recent occurrence of a certain type of inflammation of the throat, which, despite the most skillful treatment, is almost always fatal."³ It was known as *Morbus Strangulatorius* and *Garotillo* (Spanish for hangman's loop); all names alluding to the respiratory obstruction so prominent in disease morbidity.⁴ Ludwig angina is defined as a potentially lethal, rapidly spreading cellulitis, involving the sublingual and submandibular spaces, and is manifested by a brawny suprahyoid induration, tender swelling in the floor of the mouth, and elevation and posterior displacement of the tongue.⁵

Oral or dental infections are implicated in up to 70% of cases. Poor dental hygiene, gingivitis, and periapical abscesses are commonly involved in the pathogenesis. The organisms most commonly cultured from oral infections include *Streptococcus viridans* and *Staphylococcus aureus*, as well as anaerobic *B. melaninogenicus* and *peptostreptococcus*.⁶ Isolation of gram-negative organisms like *H. influenza*, *E. coli*, *Pseudomonas*, and *Neisseria* are not frequent.

In the preantibiotic era, a mortality of 54% was reported.⁷ Presently, mortality rates, for patients treated with antibiotics, vary between 0-8.5%.²

In an exhaustive review of the literature, from 1945 to 1979, 75 cases of Ludwig angina were found, and the authors strongly advocate elective tracheostomy under local anaesthesia.⁸ However, there may be good reason to avoid tracheostomy. Cellulitis of the neck with in-

* Anaesthesiologist, † Surgical Specialist.

Received from the Indian Army, New Delhi, India. Submitted for publication May 3, 2001. Accepted for publication June 26, 2002. Support was provided solely from institutional and/or departmental sources.

Address reprint requests to Dr. Mehrotra: 56/7, Defense Officers Enclave, Manekshaw Marg., Delhi Cantt, New Delhi, 110010, India. Address electronic mail to: mann110@rediffmail.com. Individual article reprints may be purchased through the Journal Web site, www.anesthesiology.org.

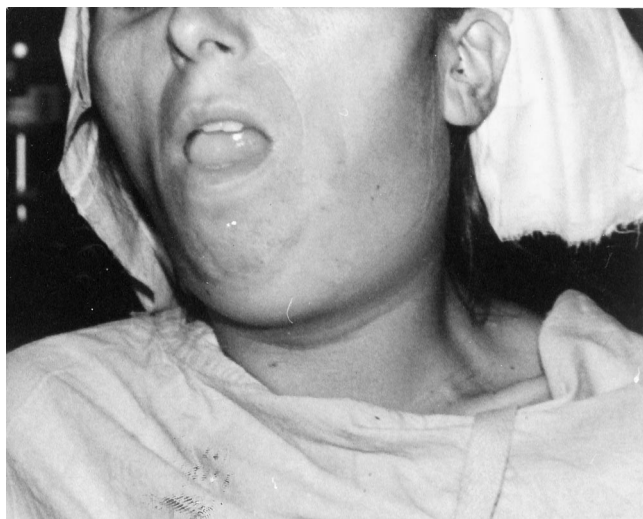

Fig. 1. Case of Ludwig angina showing marked edema over submandibular and submental region with restricted mouth opening.

involvement of the tracheostomy site makes it a more difficult procedure. Moreover, surgical dissection of the fascial planes in the neck may actually open and contaminate the pathways, leading to life-threatening mediastinal invasion.⁶ More recent reviews of anesthesia management report good results without the use of tracheostomy.^{2,3} Other options for airway management may include orotracheal, blind nasotracheal, and fiber optic intubation or cricothyroidotomy with jet insufflation.

Incision and drainage provides some decompression and can result in immediate relief of airway obstruction.⁹ Patients, however, must be closely monitored for signs of airway obstruction, and if increasing symptoms are evident an artificial airway must be created. The problem of anesthesia when using incision and drainage is not

addressed by most authors advocating an artificial airway, where general anesthesia is an obvious option. Local infiltration is unlikely to be fully effective in cellulitis, is cumbersome in an obviously sick and restless patient, and does not permit a thorough exploration. We chose to employ a cervical plexus block as anesthesia for surgical decompression. The block permitted a thorough incision and drainage, including transection of mylohyoid with lowering of the floor of mouth and rapid relief of respiratory obstruction. The patient's respiratory status rapidly improved, and hence, tracheostomy was not required. However, we are inclined to believe that superficial cervical plexus block alone would suffice.

While more sophisticated airway management methods may be advisable, cervical plexus block permits a surgical decompression. In remote hospitals with limited resources it should be considered as an option in selected cases. In case the airway compromise is not relieved, emergency tracheostomy remains a lifesaving procedure.

References

1. Allen D, Loughnan TE, Ord RA: A reevaluation of the role of tracheostomy in Ludwig's angina. *J Oral Maxillofac Surg* 1985; 43:436-9
2. Neff SPW, Merry AF, Anderson B: Airway management in Ludwig's angina. *Anaesth intensive Care* 1999; 27:659-61
3. Loughnan TE and Allen DE. Forum: Ludwig's angina. The anaesthetic management of nine cases. *Anaesthesia* 1985; 40:295-7
4. Meyers BR, Lawson W, Hirschman Z: Ludwig's angina. Case report, with review of bacteriology and current therapy. *Am J Med* 1972; 53:257-60
5. Patterson H, Kelly JH, Strone M: Ludwig's angina: An update. *Laryngoscope* 1982; 92:370
6. Snow N, Lucas AE, Grau M, Steiner M: Purulent mediastinal abscess secondary to Ludwig's angina. *Arch Otolaryngol* 1983; 109:53-5
7. Williams AC: Ludwig's angina: Surgery, gynaecology and obstetrics. 1940; 70:140-43
8. Hought RT, Fitzgerald BE, Latta JE, Zallen RD: Ludwig's angina: A report of two cases and review of the literature from 1945 to January 1979. *J Oral Surg* 1980; 38:849-55
9. Iwu CO: Ludwig's angina: Report of seven cases and review of current concepts in management. *Br J Oral Maxillofac Surg* 1990; 28:189-93

Intraoperative Transesophageal Echocardiography To Assess Septic Coronary Embolism

Holger K. Eltzschig, M.D.,* Robert W. Lekowski, Jr., M.D.,† Stanton K. Shernan, M.D.,‡ Srdjan S. Nedeljkovic, M.D.,† John G. Byrne, M.D.,§ Raila Ehlers, M.D.,|| Sary F. Aranki, M.D.**

SEPTIC coronary embolism is a rare complication of endocarditis. Aortic valve (AV) vegetations have been described as a source of coronary embolism resulting in myocardial infarction.¹ The use of diagnostic coronary angiography to localize the obstruction is often considered contraindicated, since the intervention might promote further embolic events.² Alternatively, transesophageal echocardiography (TEE) can be used to assess proximal coronary blood flow,^{3,4} however its utility in the management of a patient with suspected septic coronary embolism has not been described previously.

We report a case of AV endocarditis following epidural steroid injection for treatment of lower back pain. The patient developed cardiogenic shock with electrocardiography and echocardiography indicating acute ischemia. Despite a suspected coronary embolism, angiography was not performed. The patient was taken to the operating room for emergency AV replacement (AVR) and possible coronary artery bypass grafting (CABG). However, CABG was abandoned, since precardiopulmonary-bypass TEE demonstrated laminar blood flow in the left sided coronary arteries and a resolution of regional wall motion abnormality after the AVR.

Case Report

A 54-yr-old male was brought emergently to the operating room for AVR and CABG in the setting of endocarditis and cardiogenic shock due to suspected septic coronary embolism. His medical history was significant for chronic eczema and discogenic disease affecting the right fifth lumbar nerve route. He underwent an uneventful epidural injection with methyl-prednisone (120 mg) and lidocaine (30 mg) resulting in resolution of his back pain. Two days after the injection, he

became febrile (39°C), however did not seek medical attention until 6 days later when presenting to the emergency room. Magnetic resonance imaging (MRI) of his lower back showed fluid collections in the paraspinal muscles posterior to the spinal column near the level of the epidural injection. He subsequently developed aphasia and right-sided hemiplegia. Computed tomography findings were consistent with an infarction in the distribution of the left middle-cerebral artery. Blood cultures grew *Staphylococcus aureus* repeatedly, and transthoracic echocardiography (TTE) and TEE revealed AV vegetations as well as severe aortic regurgitation. At that point, surgery was withheld due to the potential risk of intracranial hemorrhage. Five days after his admission, the patient became hemodynamically unstable and required inotropic support. His electrocardiogram showed 2 mm ST-depression in leads V₂-V₆ and TTE demonstrated left ventricular anterior and lateral wall hypokinesis. He was taken emergently to the operating room with a diagnosis of AV endocarditis and coronary embolus. Intraoperative TEE showed severe aortic regurgitation with destruction of the coronary cusp (fig. 1), and a fistula between the aortic root and right ventricular outflow tract (fig. 2). Two-dimensional TEE imaging of the proximal coronary arteries revealed an open lumen of the left main, left anterior descending and circumflex arteries. Color flow Doppler demonstrated laminar blood flow in these vessels, suggesting coronary artery patency (fig. 3). The patient underwent closure of the fistula using a pericardial patch and homograft AVR including reinsertion of the coronaries. After the patient was weaned from cardiopulmonary bypass, TEE demonstrated normal wall motion and electrocardiography showed normal ST-segments. Therefore, CABG was not performed. The patient was transferred to the intensive care unit where he remained hemodynamically stable while inotropic support was withdrawn within 24 h. A brain abscess, requiring drainage, complicated his postoperative course further. Cultures from the brain abscess as well as from the paraspinal fluid collection grew *Staphylococcus aureus*. Twenty-five days after his heart surgery, he was discharged to a rehabilitation facility with persistent aphasia and right-sided hemiplegia.

Comment

TEE is an established diagnostic technique in the management of patients with infective endocarditis.⁵ In this case, the combined TEE findings of coronary artery patency and restored wall motion strongly influenced the surgical decision to abandon CABG. The use of TEE to evaluate coronary arteries has been described previously.^{3,4,6} However, the intraoperative use of TEE to rule out coronary artery stenosis is not commonly necessary, since most patients undergo coronary angiography prior to surgery. In contrast, angiography was considered contraindicated in this patient due to the risk of embolization.² Intraoperative TEE demonstrated nonturbulent flow in the proximal left coronary arteries suggesting coronary patency. Intraoperative echocardiography also showed severe aortic insufficiency with destruction of the left coronary cusp and revealed a previously undiagnosed aorta to right ventricular outflow tract fistula. Aortic insufficiency can decrease

* Clinical Fellow, † Instructor, ‡ Assistant Professor, Department of Anesthesiology, Perioperative and Pain Medicine, § Assistant Professor, ** Associate Professor, Division of Cardiac Surgery, || Research Fellow, Cardiovascular Division, Brigham and Women's Hospital, Harvard Medical School, Boston, Massachusetts.

Received from the Department of Anesthesiology, Perioperative and Pain Medicine and Division of Cardiac Surgery, Brigham and Women's Hospital, Harvard Medical School, Boston, Massachusetts. Submitted for publication March 28, 2002. Accepted for publication June 26, 2002. Support was provided solely from institutional and/or departmental sources.

Address reprint requests to Dr. Aranki: Associate Professor, Division of Cardiac Surgery, Brigham and Women's Hospital, Harvard Medical School, 75 Francis Street, Boston, MA 02115. Address electronic mail to: saranki@partners.org. Individual article reprints may be purchased through the Journal Web site, www.anesthesiology.org.

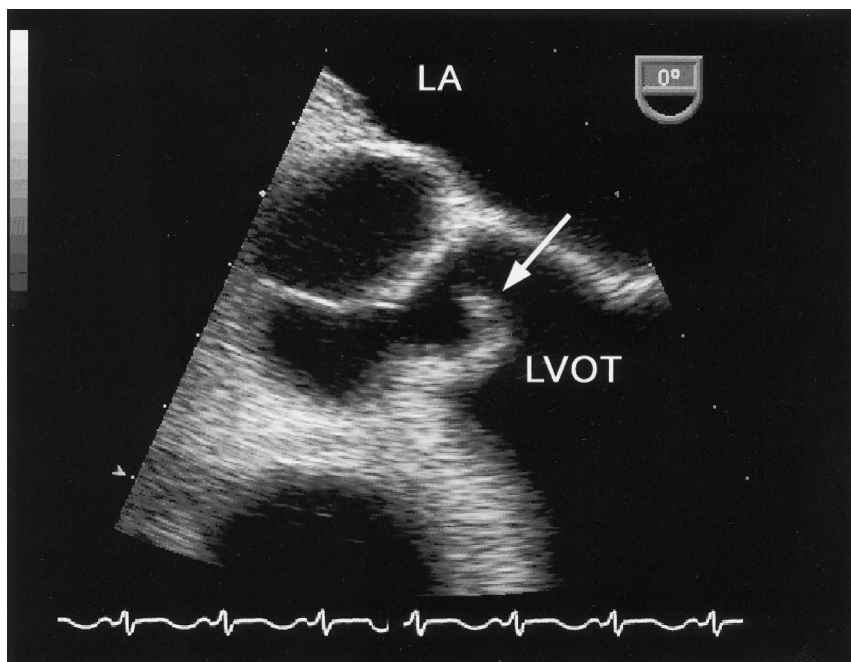


Fig. 1. Intraoperative transesophageal echocardiography (mid-esophageal four chamber view) shows the aortic valve and the left ventricular outflow tract (LVOT). The arrow points toward a flail coronary cusp of the aortic valve. LA = left atrium.

coronary reserve and thus account for acute ischemia even in the absence of coronary artery obstruction.⁷ The presence of an aorto-ventricular fistula could in addition compromise coronary artery perfusion. Alternatively, a septic embolus occluding the patient's proximal coronary circulation could have been lysed "naturally" during the time from onset of ischemia until the patient had surgery. TEE only allows visualization of the proximal coronary circulation. Therefore, a distal coronary obstruction could not be excluded *via* direct visualization or color flow Doppler. However, the regional wall-motion abnormality had resolved upon completion of the surgery.

The potential causes of this patient's bacteremia are multi-fold. The patient had a long-standing history of chronic eczema and scratching, possibly leading to intermittent episodes of bacteremia seeding his AV.

In addition, retrospective review of preprocedure MRI scans raises the possibility of a discitis, which also may have been a source of bacterial seeding. The systemic immunosuppressive effects of the epidural steroids could have exacerbated either condition leading to fulminant endocarditis. However, the time course of events with an onset of fever 2 days after an epidural steroid injection raises the possibility that seeding of skin-borne staphylococcus into the musculature instigated the cascade of events leading to bacteremia and endocarditis. Two facts may weigh against this line of reasoning. First, the patient never developed an epidural infection, which would be expected if a needle became contaminated on penetrating the skin. Second, there were multiple paraspinal fluid collections demonstrated on the MRI performed after the procedure, not one focal area of infection.

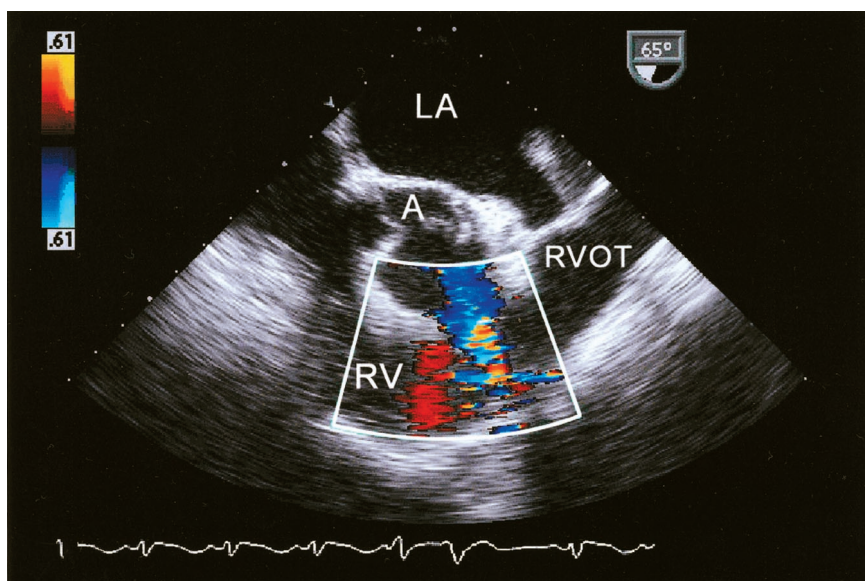
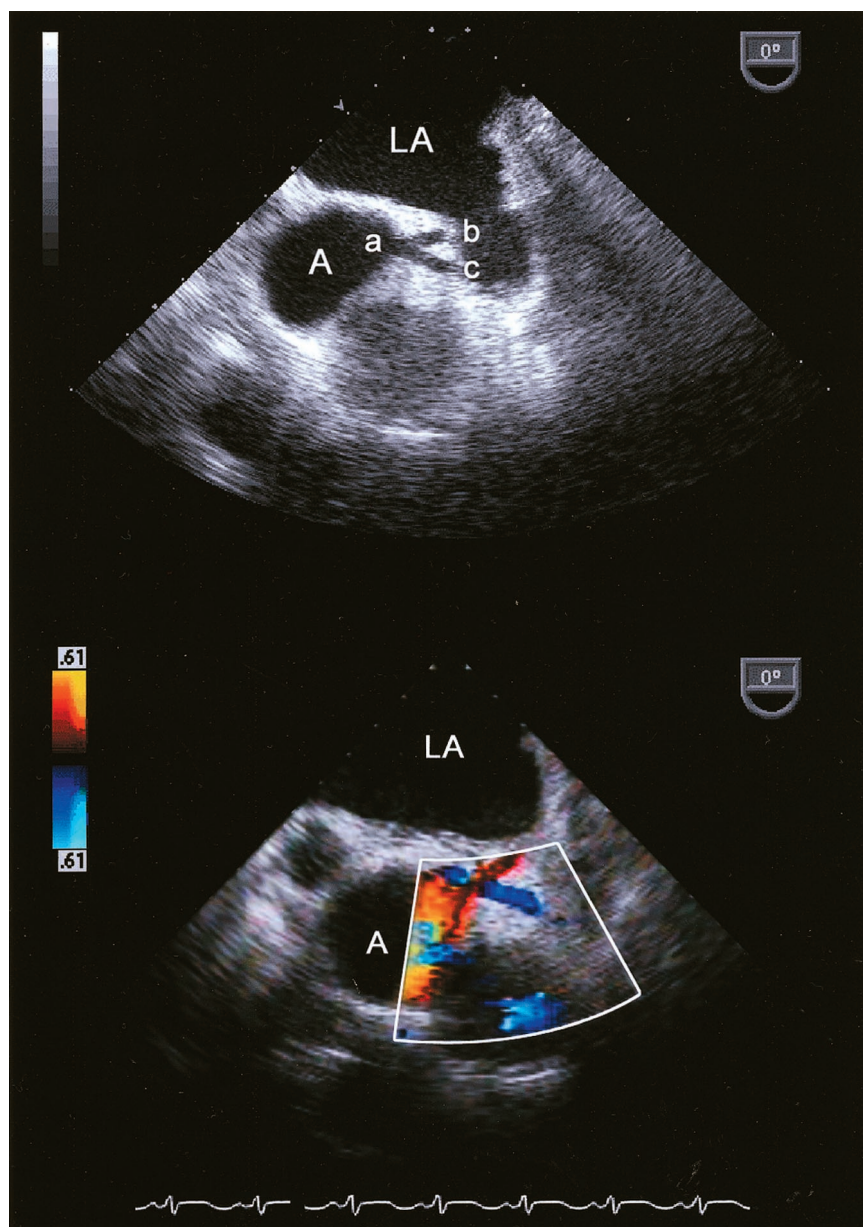


Fig. 2. Intraoperative transesophageal echocardiography (mid-esophageal RV inflow-outflow view) demonstrates a fistula between the aortic root and right ventricular outflow tract with left to right shunt. A = aorta, LA = left atrium, RV = right ventricle, RVOT = right ventricular outflow tract.

Fig. 3. Intraoperative transesophageal echocardiography (mid-esophageal ascending aortic short axis view) shows the left main (a), proximal left circumflex (b) and left anterior descending (c) coronary arteries. Color-flow Doppler demonstrates laminar flow (Red = left circumflex; Blue = left anterior descending coronary artery). A = aorta, LA = left atrium.



References

1. Perera R, Noack S, Dong W: Acute Myocardial infarction due to septic coronary embolism. *N Engl J Med* 2000; 342(13):977-8
2. Shamsham F, Safi AM, Pomerenko I, et al.: Fatal left main coronary artery embolism from aortic valve endocarditis following cardiac catheterization. *Catheter Cardiovasc Interv* 2000; 50(1):74-7
3. Biederman RW, Sorrell VL, Nanda NC, Voros S, Thakur AC: Transesophageal echocardiographic assessment of coronary stenosis: A decade of experience. *Echocardiography* 2001; 18(1):49-57
4. Firstenberg MS, Greenberg NL, Lin SS, Garcia MJ, Alexander LA, Thomas JD: Transesophageal echocardiography assessment of severe ostial left main coronary stenosis. *J Am Soc Echocardiogr* 2000; 13(7):696-8
5. Fowler VG, Jr, Li J, Corey GR, et al.: Role of echocardiography in evaluation of patients with *Staphylococcus aureus* bacteremia: Experience in 103 patients. *J Am Coll Cardiol* 1997; 30(4):1072-8
6. Practice guidelines for perioperative transesophageal echocardiography. A report by the American Society of Anesthesiologists and the Society of Cardiovascular Anesthesiologists Task Force on Transesophageal Echocardiography. *ANESTHESIOLOGY*. 1996; 84(4):986-1006
7. Ardehali A, Segal J, Cheitlin MD: Coronary blood flow reserve in acute aortic regurgitation. *J Am Coll Cardiol* 1995; 25(6):1387-92

Management of Unexplained Antepartum Circulatory Collapse Directed by Transesophageal Echocardiography Findings

Andrea Nowitz, M.B.B.Ch., F.A.N.Z.C.A.

PRIMARY nontraumatic spontaneous coronary artery dissection (SCAD) is a rare cause of myocardial infarction that occurs predominantly in young women. Although myocardial infarction in pregnancy itself is rare, and the etiology of SCAD is uncertain, approximately one-third of reported SCAD in women occurs between the third trimester of pregnancy and 4 months postpartum.¹

We report a previously healthy 19-yr-old woman being treated for premature labor who presented with acute circulatory collapse at 32 weeks gestation. After resuscitation and emergency Cesarean section, the use of transeophageal echocardiography (TEE) excluded the diagnosis of pulmonary embolism or aortic dissection as possible causes of her collapse. Instead, the finding on TEE of left ventricular akinesis in the distribution of the left main coronary artery prompted urgent angiography to delineate the etiology.

Case Report

A healthy 19-yr-old G1P0 female was admitted to the labor service at 31 weeks gestation for premature labor. She was managed with, and responded to, magnesium tocolysis and antibiotic therapy. After several days of observation without magnesium therapy, she resumed uterine contractions and intravenous magnesium was restarted. Again, she responded to treatment and the magnesium infusion was decreased incrementally. Her blood pressure was stable at 100-115/70 mmHg.

On the eighth day after admission, she complained of sudden onset of chest pressure and shortness of breath. She also complained of nausea and became diaphoretic. The first recorded blood pressure after the onset of distress was 60/49 mmHg at which time the patient was minimally responsive to commands. She rapidly became unconscious and cyanotic with poor peripheral pulses and was immediately taken to the operating room for advanced resuscitation and simultaneous emergency Cesarean section.

The airway was secured and the presence of bilateral breath sounds was confirmed with the end-tidal carbon dioxide recorded as 35 mmHg. Surgical incision followed instantly while the patient was ventilated with 100% oxygen and anesthesia was maintained with boluses of intravenous fentanyl. The systemic blood pressure was restored with administration of crystalloid, and supported with continued administration of intravenous fluids, boluses of ephedrine, and a titrated phenylephrine infusion. A Swan Ganz catheter was inserted into the right internal jugular vein. The initial pulmonary artery pressure re-

corded was 36/16 mmHg. The electrocardiogram showed a sinus tachycardia of 120 beats/min with a slightly widened QRS complex.

A viable infant was delivered promptly but during subsequent closure of the surgical incision, 30 min after initial collapse, the maternal condition deteriorated. The patient rapidly became cyanotic and hypotensive. The cardiac rhythm changed to a wide complex tachycardia followed by a bradycardia at a rate of 30-40 beats/min and the systolic blood pressure dropped to 60 mmHg. The central venous pressure was 20 mmHg and the pulmonary artery pressure was 32/18 mmHg.

Resuscitative measures continued with the presumed diagnosis of pulmonary embolism. Amniotic fluid embolism was ruled out because of the absence of signs of coagulopathy or hemolysis. Wound closure was achieved 67 min after incision, after which the patient was transferred urgently to the cardiac operating room for possible pulmonary embolectomy after TEE.

The TEE showed akinesis of the entire left ventricle in the distribution of the left main coronary artery and associated moderate to severe mitral regurgitation. The left atrium was dilated. The right ventricle was of normal size and the free wall was functioning normally. There was no evidence of thrombus in the main or right pulmonary arteries. The aortic valve was morphologically normal and competent. There was no dissection in the ascending aorta and color Doppler imaging of blood flow demonstrated patency of the left main coronary ostium, although distal flow was not well seen. A twelve-lead electrocardiogram was performed simultaneously and was consistent with an acute anterolateral infarct. The diagnosis of an acute coronary syndrome was made and pulmonary embolism excluded. The patient was transferred to the cardiac catheterization laboratory for angiography and possible percutaneous intervention.

Cardiac catheterization demonstrated an occluded left main coronary artery attributed to spontaneous dissection that could not be opened by percutaneous transluminal angioplasty or stent placement. She was transported emergently back to the operating room for coronary artery bypass grafting of the left anterior descending artery and the circumflex artery. Due to extensive myocardial injury and severe left ventricular failure the patient required a ventricular assist device to be weaned from cardiopulmonary bypass before being taken to the intensive care unit.

The patient recovered to her normal neurologic status after surgery. The baby progressed well and remained healthy. The patient required ongoing in-hospital support from the ventricular assist device over the next 6 months, which was finally withdrawn after she suffered an intracranial hemorrhage resulting in significant neurologic compromise.

Discussion

The pattern and severity of presentation of SCAD are variable and relate to the extent of the dissection, its rate of development, and the vessel involved.² The left main coronary artery is affected in less than 1% of cases, with the left anterior descending artery being the most common (75%) followed by the right main coronary artery (20%).³ The prognosis is poor because of the resultant large area of threatened or infarcted myocardium associated with pump failure, malignant arrhythmias, and sudden death.²

Acting Assistant Professor.

Received from the Department of Anesthesiology, University of Washington, Seattle, Washington. Submitted for publication March 7, 2002. Accepted for publication June 27, 2002. Support was provided solely from institutional and/or departmental sources.

Address reprint requests to Dr. Nowitz: Department of Anaesthesia, The Prince Charles Hospital, Rode Road, Chermiside, Queensland 4032, Australia. Address electronic mail to: a.nowitz@hotmail.com. Individual article reprints may be purchased through the Journal Web site, www.anesthesiology.org.

A high index of suspicion and prompt diagnosis is critical for optimizing the chances of survival and facilitating the choice of intervention in a patient with SCAD. Treatment options at the time of clinical diagnosis of SCAD are controversial and include thrombolysis, percutaneous transluminal coronary angioplasty or stent placement, and acute coronary artery bypass surgery. The choice of intervention is dependent on the patient's clinical condition and associated angiographic findings such as coexisting coronary spasm, atherosclerosis, or the presence of intracoronary thrombosis.^{1,2,3}

TEE is recommended to diagnose and direct further investigation or treatment in hemodynamically unstable patients presenting with cardiogenic shock or cardiac arrest. Treatment of these patients has been demonstrated to change after TEE diagnosis.^{4,5} The anatomic and hemodynamic information obtained by TEE may be sufficient to prompt a major surgical intervention without confirmatory tests in cases of massive pulmonary embolism, pericardial tamponade, papillary muscle rupture, and aortic dissection.^{4,5,6} TEE can reliably establish the cause of a circulatory arrest during resuscitation with a sensitivity of 93%, specificity of 50%, and positive predictive value of 87%.⁵

The diagnosis of pulmonary embolism by direct visualization of thrombus on TEE occurs in less than 10% of patients with pulmonary emboli.⁶ The indirect findings include a dilated right atrium and right ventricle and tricuspid regurgitation.^{5,6}

In the presented case, the preliminary diagnosis of pulmonary embolism was ruled out by TEE. The TEE demonstrated an extensive and severe wall motion abnormality indicating an acute coronary syndrome in the distribution of the left main coronary artery. Specific findings can suggest the etiology of a coronary occlusion but delineation of the nature and extent of pathology in most cases requires angiography to direct further treatment.

Detection by TEE of extension of an aortic dissection through the ostium and into the left main coronary artery has been reported in a patient with thoracic pain and no evidence of myocardial ischemia or infarction.⁷ In that patient, the dissection flap was clearly seen to enter the ostium and color Doppler imaging demonstrated the distinction between the true and false lumen of the left coronary main stem. The left ventricle showed concentric hypertrophy without impaired systolic function. The patient was treated surgically with a supracoronary aortic graft.

Dissection of the proximal left anterior descending artery was suggested by TEE and confirmed angiographi-

cally in a young male patient who presented with electrocardiogram evidence of an acute myocardial infarct following blunt chest trauma in a motorcycle accident.⁸ Transthoracic echocardiography revealed poor left ventricular contractility with septal and apical akinesis. The subsequent TEE identified a short intimal flap located at the proximal left anterior descending artery, which was slightly thickened and pointed to the orifice of the left main coronary artery. The patient was treated medically.

A previously healthy 40-yr-old woman, with no cardiac risk factors, was reported to have presented 1 week postpartum following successful resuscitation after cardiac arrest.⁹ Her electrocardiogram was consistent with acute anterior infarction. A TEE was performed to exclude aortic dissection. The TEE showed severe hypokinesis of the anteroapical wall. The proximal left anterior descending artery was thickened, with a linear density in the wall, suggestive of SCAD without intimal flap. Coronary angiography confirmed a luminal irregularity and the patient was treated medically, but subsequently required stent placement.

SCAD and associated myocardial infarction is a rare but important etiology of peripartum circulatory collapse. Early diagnosis is critical for the survival of these patients. TEE has been demonstrated to suggest the diagnosis of SCAD and distinguish it from other causes of coronary artery dissection.^{7,8,9} Features on two-dimensional imaging may include a visible flap or thickening of the coronary artery wall. Color Doppler imaging may show a disturbance of, or obstruction to, blood flow. SCAD can subsequently be confirmed with coronary angiography.

References

1. Elming H, Køber L: Spontaneous coronary artery dissection: Case report and literature review. *Scand Cardiovasc J* 1999; 33:175-9
2. Sharma AD, Sreeram G, Slaughter TF: Spontaneous coronary artery dissection in a healthy 24 year old woman. *J Cardiothorac Vasc Anesth* 2000; 14(3):312-3
3. Thistlewaite PA, Tarazi RY, Giordano FJ, Jamieson SW: Surgical management of left main coronary artery dissection. *Ann Thorac Surg* 1998; 66:258-60
4. Sohn D-W, Shin G-J, Oh JK, Tajik AJ, Click RL, Miller FA, Seward JB: Role of transesophageal echocardiography in hemodynamically unstable patients. *Mayo Clin Proc* 1995; 70:925-31
5. van der Wouw PA, Koster RW, Delemarre BJ, de Vos R, Lampe-Schoenmaeckers AJEM, Lie KI: Diagnostic accuracy of transesophageal echocardiography during cardiopulmonary resuscitation. *J Am Coll Cardiol* 1997; 30:780-3
6. Klein AL, Stewart WC, Cosgrove DM, Mick MJ, Salcedo E: Visualization of acute pulmonary emboli by transesophageal echocardiography. *J Am Soc Echo* 1990; 3:412-5
7. Jakob M, Ritter M, Rickli H, Jenni R: Transesophageal colour Doppler detection of coronary artery dissection. *Lancet* 1994; 343:1574-5
8. Chermg W-J, Bullard MJ, Chang H-J, Lin F-C: Diagnosis of coronary artery dissection following blunt chest trauma by transesophageal echocardiography. *J Trauma Injury Infect Crit Care* 1995; 39(4):772-4
9. Lerakis S, Manoukian S, Martin RP: Transesophageal echo detection of postpartum coronary artery dissection. *J Am Soc Echocardiogr* 2001; 14:1132-3

Perioperative Bilateral Median Neuropathy

Giorgia Melli, M.D.* Vinay Chaudhry, M.D.† Todd Dorman, M.D.‡ David R. Cornblath, M.D.§

NERVE injuries associated with surgical operations are well recognized and described in literature.^{1,2} Ulnar neuropathy, brachial plexus, and lumbosacral roots injuries are the most frequent, as shown by two large reviews on anesthesia-related nerve damage from the American Society of Anesthesiologists closed claims study.^{3,4} Several factors such as section, compression, traction, and ischemia, contribute to the nerve injuries but the exact mechanism(s) in an individual case often is unclear.^{4,5}

We describe a case of perioperative bilateral median neuropathy at the distal forearm, an uncommon site of nerve injury, which we ascribe to demyelinative conduction block secondary to nerve compression.

Case Report

A 60-yr-old man (86 kg, 180 cm) with a history of ulcerative colitis had an operation for recurrent urethroperineal fistula. His routine preoperative blood tests were normal. Intravenous access was through the right hand and right internal jugular vein. A total of 7 l was given during the procedure. A lumbar epidural was placed followed by a standard general anesthetic with tracheal intubation. The epidural was test dosed with 2% lidocaine with epinephrine followed by 12 ml of the same solution; the patient was positioned supine. His arms were placed on padded arm boards that were abducted to less than 90°. A bubble wrap was positioned around the elbows bilaterally, and the arms were affixed to the arm boards with tape. The upper limbs were checked to ensure that the shoulders were not over-abducted, that the elbows were not over-extended, and that the arms were loose underneath the tape but secure enough to not be able to fall off of the arm boards. The surgery lasted 6 h. During the surgery, the patient was moved several times from supine to extreme Trendelenburg as well as into extreme reverse Trendelenburg. The patient tolerated the procedure without hypotension or other incident and was extubated and taken to the intensive care unit. Later that night, the patient complained of numbness and tingling in bilateral digits 1-3 and the palm. Examination 22 h after surgery showed a reduction of light touch, pin prick, and vibratory sensation in the median nerve distribution and weakness of abductor pollicis brevis (Medical Research Council 4/5) in both hands; Tinel's sign was not present over the median nerve at the wrist. There was swelling of hands and forearms.

A nerve conduction study was performed 26 h after surgery. Antidromic sensory nerve conduction studies were performed recording at the digit 2 and stimulating at the palm, wrist, forearm, and elbow segments. Distal median sensory nerve action potential amplitudes

stimulating at the wrist were normal (52 μ V on the right and 47 μ V on the left; normal > 10 μ V). Inching studies with stimulation at the palm and calculating conduction velocity in the palm to wrist segment failed to show focal reduction in conduction velocity in the carpal tunnel segment. Proximal stimulation in the forearm on the right and at the elbow on the left revealed complete conduction block (fig. 1).

Median motor conduction studies were done with recording at the thenar eminence and stimulating at precisely the same sites as the sensory conduction study. Wrist stimulation showed normal distal latencies and compound muscle action potential amplitudes (11.3 mV on the right and 11 mV on the left; normal > 4 mV). Proximal stimulation in the right forearm, 140 mm above the wrist, showed partial motor conduction block (34% decrease in negative peak area) and reduced conduction velocity (40 m/s; normal > 50 m/s) (fig. 2). On the left, proximal stimulation showed a partial motor conduction block (25% decrease in amplitude and negative peak area) and mild reduction in conduction velocity (48 m/s) with stimulation at the elbow. Right sided ulnar sensory and motor conduction studies were normal. Symptoms resolved by 48 h, and a repeat neurologic examination was normal.

Discussion

Median neuropathy is a distinctly uncommon perioperative neuropathy. When reported, the usual vulnerable site for the median nerve is in the antecubital fossa where the nerve lies adjacent to the medial cubital and basilic veins. At this site, the nerve may be damaged during injection into or cannulation of a vein or artery.⁶ A preexisting median neuropathy at the wrist, subclinical carpal tunnel entrapment, may become symptomatic. Motor fibers that contribute to the median nerve may also be injured with stretch at the level of the lower trunk or medial cord of the brachial plexus. Perioperative anterior interosseous nerve damage has been recently described. The possible mechanisms of injury for this nerve seem to be needle stick, hematomas, and traction in the antecubital fossa.⁷ Lastly, although not directly related to surgery, selective damage to the median or anterior interosseous nerve fibers may be a part of idiopathic brachial neuritis.⁸

We describe a man who developed bilateral median neuropathy in the distal forearm following prolonged abdominal surgery. Nerve conduction studies precisely localized the area of abnormality. Given the conduction block and the rapid recovery of symptoms, the injury was neuropraxia rather than axonotmesis. Corresponding to his clinical symptoms, physiologically sensory fibers were more severely affected than the motor fibers.

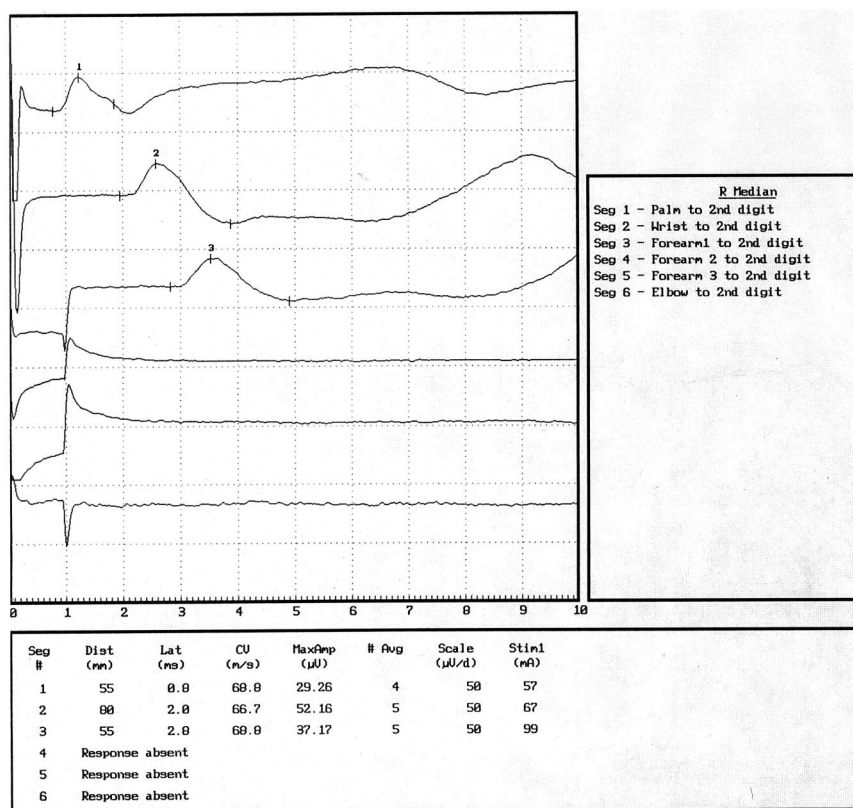
Given the bilateral symmetrical findings, the documented conduction block, and the rapid recovery, we postulate that the injury to the median nerves was from compression rather than nerve ischemia-infarction or

* Neurology Fellow, † Associate Professor of Neurology, ‡ Associate Professor of Anesthesiology and Critical Care Medicine, § Professor of Neurology.

Received from the Johns Hopkins University School of Medicine, Baltimore, Maryland. Submitted for publication March 6, 2002. Accepted for publication July 9, 2002. Supported was provided solely from institutional and/or departmental sources.

Address reprint requests to Dr. Cornblath: Meyer 6-181a, Johns Hopkins Hospital, Baltimore, Maryland, 21287-7681. Address electronic mail to: dcornbl@jhmi.edu. Individual article reprints may be purchased through the Journal Web site, www.anesthesiology.org.

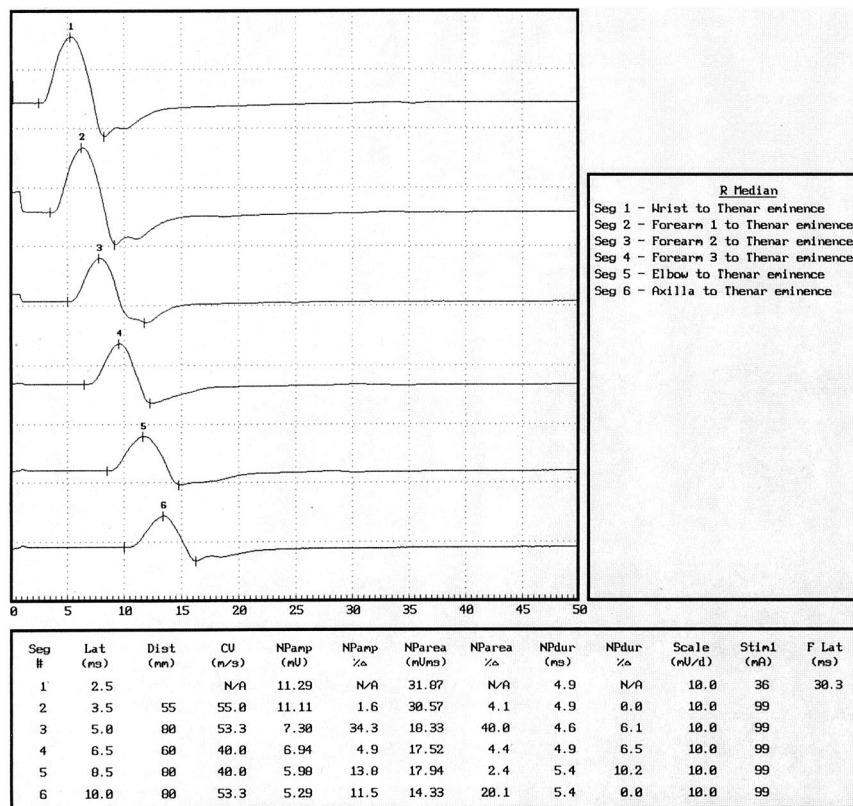
Fig. 1. Sensory nerve conduction study of the right median nerve recording from digit 2 demonstrating a complete conduction block between stimulation sites 3 and 4, 55–80 mm proximal to the wrist crease.



transection. In the forearm, the median nerve descends along the midline in a relatively deep position lying on the anterior face of flexor digitorum profundus, beneath

the posterior face of flexor digitorum superficialis. For this reason stretch of the nerve or a direct penetrating trauma to the nerve seems unlikely, and there was no

Fig. 2. Motor nerve conduction study of the right median nerve recording from the thenar eminence demonstrating partial motor conduction block between stimulation sites 2 and 3, 55–80 mm proximal to the wrist crease.



evidence of either. The possible causes of the compression include the tape over the volar forearm used to affix the arms to the padded arm board, an unexpected venous tourniquet effect in the face of third spacing, or generalized soft tissue swelling. A case of bilateral symmetric transient radial nerve injury in an infant after cardiac surgery has been described. In that case, the injury occurred from tight wrapping of hand splints for many days after surgery, which the authors speculate, caused prolonged compression to the posterior interosseous nerve.⁹ In addition to defining the mechanism of injury, this case raises questions regarding the underlying pathology. Although the presence of "true" conduction block is pathognomonic of "demyelination," given the recovery in less than 24 h, it is unlikely that structural demyelination and remyelination took place in that short time period. Studies on acute compression block in animal models have shown that under certain circumstances, nerve fibers can sustain local compression damage, without Wallerian degeneration and from which recovery is relatively rapid.¹⁰ This kind of injury results from mechanical distortion of fibers with the node of Ranvier and the attached myelin sheath being displaced from the compression site toward the uncompressed site, leading to invagination of one internode into the next. In this situation, the degree of conduction block (percent of fibers that are electrically inexcitable proximal to the lesion) is directly proportional to both the amount and duration of the compression. The time of recovery is related to the force and duration of initial compression, to the length of nerve compressed, and to the number of nodes of Ranvier affected.¹⁰ The relatively fast recovery in our patient is best explained by a narrow compression force inducing paranodal changes in a limited number of nodes of Ranvier.

The possible role of ischemia in determining the nerve lesion in this case still is questionable. Animal studies have shown mammalian nerve fibers can withstand 4–6 h of ischemia without development of structural damage. Moreover, there is no evidence that ischemia for 4 h

exaggerates the effect of mechanical pressure on nerves.¹¹ Ischemia generally produces a lesion of Wallerian-like degeneration. It has also been shown that if pressure is applied at extremely high levels or for a long period of time, the blood vessels may undergo ischemic necrosis prior to similar changes in the nerve.¹²

There is a limited understanding of the relationships between conventional perioperative care and the genesis of peripheral nerve lesions.¹³ In our experience, most patients with perioperative nerve injuries are referred for electrophysiological evaluation late and when spontaneous recovery is delayed or absent. This is because the majority of these nerve injuries is due to focal demyelination, and as in our case, recover quickly. In selected cases, nerve conduction studies at the onset of symptoms may provide insights into localization, mechanism, and prognosis.

References

1. Dhuner K: Nerve injuries following operations: A survey of cases occurring during a 6 year period. *ANESTHESIOLOGY* 1950; 11:289–93
2. Lincoln JR, Sawyer HP: Complications related to body positions during surgical procedures. *ANESTHESIOLOGY* 1961; 22:800–9
3. Kroll DA, Caplan RA, Posner K, Ward RJ, Cheney FW: Nerve injury associated with anesthesia. *ANESTHESIOLOGY* 1990; 73:202–7
4. Cheney FW, Domino KB, Caplan RA, Posner K: Nerve injury associated with anesthesia: A close claims analysis. *ANESTHESIOLOGY* 1999; 90:1062–9
5. Stoelting RK: Postoperative ulnar nerve palsy: Is it a preventable complication? *Anesth Analg* 1993; 76:7–9
6. Britt BA, Joy N, Mackay MB: Anesthesia-related trauma caused by patient malpositioning. *Complications in Anesthesiology*, 2nd edition. Edited by Gravenstein N, Kirby RR. Philadelphia, Lippincott-Raven Publishers, 1996, pp 365–89
7. Contreras MG, Warner MA, Carmichael SW, Spinner RJ: Perioperative anterior interosseous neuropathy. *ANESTHESIOLOGY* 2002; 96:243–5
8. Malamut RI, Marques W, England JD, Sumner AJ: Postsurgical idiopathic brachial neuritis. *Muscle Nerve* 1994; 17:320–4
9. Shime N, Kato Y, Tanaka Y, Kim WC: Bilateral transient radial nerve palsies in an infant after cardiac surgery. *Can J Anaesth* 2001; 48(2):200–3
10. Gilliat RW: Acute compression block: The physiology of peripheral nerve disease. Edited by Sumner AJ. Philadelphia, WB Saunders Company 1980, pp 287–315
11. Williams IR, Jefferson D, Gilliat RW: Acute nerve compression during limb ischaemia: An experimental study. *J Neurol Sci* 1980; 46:199–207
12. Lundborg G: Ischemic nerve injury. Experimental studies on intraneural microvascular pathophysiology and nerve function in a limb subjected to temporary circulatory arrest. *Scand J Plast Reconstr Surg Suppl* 1970; 6:3–113
13. Caplan RA: Will we ever understand perioperative neuropathy? *ANESTHESIOLOGY* 1999; 91:335–6

Positive Malignant Hyperthermia Susceptibility *In Vitro* Test in a Patient with Mitochondrial Myopathy and Myoadenylate Deaminase Deficiency

Ruth M. Fricker, M.D.,* Thomas Raffelsberger, M.D.,† Sigrid Rauch-Shorny, M.D.,‡ Josef Finsterer, M.D.,§ Clemens Müller-Reible, Ph.D.,|| Hermann Gilly, Ph.D.,** Reginald E. Bittner, M.D.††

MALIGNANT hyperthermia (MH) is a life-threatening anesthesia-related complication characterized by a hypermetabolic response of skeletal muscle which can be triggered by anesthetic drugs such as halothane and succinylcholine.¹ Although some genes have been identified to be involved in MH (such as the ryanodine receptor gene [RYR1] and the dihydropyridine receptor [DHP] gene) the underlying molecular defect remains unclear in the majority of MH-cases. However, apart from central core disease, which is regularly associated with MH-susceptibility, the association of other neuromuscular diseases with MH has been reported anecdotally.

Here we report a 41-yr-old man with a long history of progressive muscle weakness, myalgia, and recurrent myoglobinuria due to two unrelated metabolic defects, *i.e.*, mitochondrial myopathy in combination with myoadenylate deaminase (MAD) deficiency. The patient tested positive for malignant hyperthermia susceptibility (MHS) by the halothane caffeine *in vitro* contracture testing (IVCT) procedure.

Case Report

A 41-yr-old man, who had been under medical observation for 27 yr because of severe exercise intolerance with long-standing myalgia, muscle cramps, recurrent myoglobinuria, and progressive muscle weakness, was admitted to our unit for MH testing prior to umbilical hernia surgery. The relief of the proximal limb muscles was slightly reduced and signs of muscle weakness were apparent (difficulties in

climbing stairs and in elevating his arms). Serum creatine kinase and lactate dehydrogenase levels at rest were strikingly elevated, CK 3,700 U/l (normal 80 U/l); LDH 395 U/l (normal 240 U/l), but a previous muscle biopsy from the rectus femoris muscle was reported as unremarkable. Because clinical symptoms progressively deteriorated, an extensive clinical reassessment was undertaken at age 35, but no additional clues establishing a definite diagnosis could be deduced. At the age of 41 yr a myosonographic examination of the quadriceps femoris muscle was suggestive of a myopathic lesion. The patient had not, nor had any member of his family, ever experienced an anesthetic complication. Remarkably, his mother was reported as having suffered from progressive muscle weakness. She died at the age of 65 yr suffering cognitive impairment (progressive presenile dementia), generalized stiffness of the musculature with slowness and awkwardness of movements, resembling combined Parkinson and Alzheimer disease. The maternal brother, as well as the patient's brother, were both described as normal. The patient had no children.

To assess the patient's MH status we performed IVC testing according to the protocol of the European MH Group.² Muscle bundles from the vastus lateralis were excised under regional anesthesia, and halothane and caffeine were administered to viable muscle fascicles of 16–25 mm resting length.

The IVCT test with caffeine and halothane (contracture at 1.5 mM caffeine: 4.5 mN and at 0.11 mM halothane: 2.5 mN, respectively) established the diagnosis MHS (contracture thresholds: more than 2 mN at ≤ 2 mM caffeine and ≤ 0.44 mM halothane) in this patient (fig. 1).

To screen for a possible genetic defect related to MHS, molecular genetic analysis of the patient's ryanodine-receptor 1 (RYR1) gene ruled out any of the five most common RYR1-mutations related to MH, which are found in approximately 25% of MH-patients in central Europe: G1021A = Gly341Arg, C1840T = Arg614Cys, C6487T = Arg2163Cys, G6502A = Val2168Met, G7300A = Gly2434Arg.

Subsequent histologic examination of a separately excised muscle sample revealed myopathic changes such as increased variability of fiber diameters, mildly proliferated endomysial connective tissue, single necrotic muscle fibers, as well as internally nucleated fibers (fig. 2A). However, immunohistochemical and Western-blot investigation with respect to the expression of muscular-dystrophy-related proteins such as dystrophin, sarcoglycans (α , β , γ , δ), dystroglycans, merosin, caveolin-3, calpain-3, and dysferlin yielded normal results.

Though no typical ragged red fibers were observed in the Gomori-trichrome stain, the sarcoplasm of many fibers had a coarse appearance (fig. 2A, asterisk). By enzyme histochemistry, almost complete lack of MAD-activity was disclosed (fig. 2B). This finding was corroborated on the molecular level when we identified a homozygous C34T mutation according to Fishbein *et al.*³ in the patient's AMPD 1 gene.

By oxidative enzyme histochemistry (reduced nicotinamide adenine dinucleotide-tetrazolium reductase (NADH-TR), succinate dehydrogenase (SDH), cytochrome-c-oxidase [CCO]), subsarcolemmal mitochondrial aggregates became visible. Approximately 10% of the muscle fibers showed a marked decreased reactivity of CCO in the respective stain (fig. 2C). At the ultrastructural level, the mitochondria showed multiple structural abnormalities, such as paracrystalline inclusions (fig. 2D).

To further delineate a suspected mitochondrial myopathy, we screened the mitochondrial DNA extracted from the patient's muscle for all known pathogenic point mutations according to Raffelsberger *et*

* Staff Anesthesiologist, Department of Anesthesiology and General Intensive Care, University of Vienna. Current position: Staff Anesthesiologist, Department of Internal Medicine VI, Clinical Pharmacology and Pharmacoeconomics, University Hospital, Heidelberg, Germany. † Staff Anatomist, ‡ Professor of Anatomy, Institute of Anatomy, Neuromuscular Research Department, University of Vienna. § Staff Neurologist, § Professor of Neurology, Neurological Hospital Rosenhügel, L. Boltzmann Institute for Epilepsy and Neuromuscular Disorders, Vienna. || Professor of Human Genetics, Institute of Human Genetics, University of Würzburg, Germany. ** Professor of Biomedical Engineering, Department of Anesthesiology and General Intensive Care (B), University of Vienna, and L. Boltzmann Institute for Experimental Anesthesiology and Research in Intensive Care Medicine, Vienna.

Received from the Department of Anesthesiology and General Intensive Care (B), and Institute of Anatomy, Neuromuscular Research Department, Vienna Medical School, University of Vienna, Vienna, Austria. Submitted for publication June 27, 2002. Accepted for publication July 11, 2002. Supported by the Austrian Federal Ministry for Social Security and Generations, Vienna, Austria, and by the Austrian Society for Research on Neuromuscular Disorders in Children, Vienna, Austria.

Address reprint requests to Dr. Bittner: Institute of Anatomy, Neuromuscular Research Department University of Vienna, Währinger Straße 13, A-1090 Vienna, Austria. Address electronic mail to: reginald.bittner@univie.ac.at. Individual article reprints may be purchased through the Journal Web site, www.anesthesiology.org.

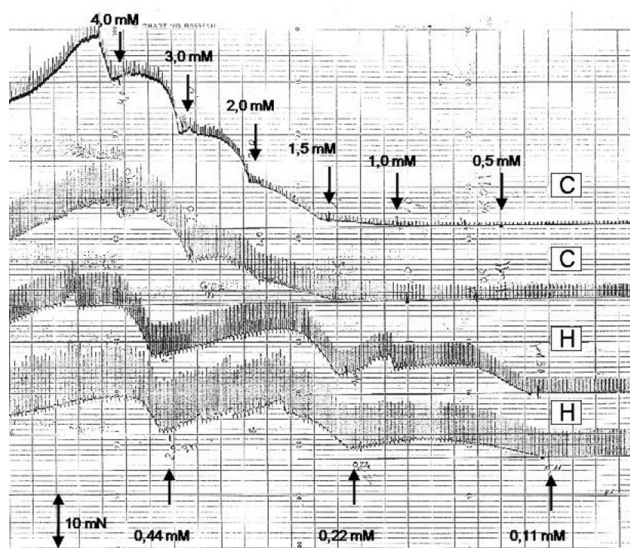


Fig. 1. *In vitro* contracture test recording with cumulative titration of halothane (H) (0.11, 0.22, and 0.44 mM) and caffeine (C) (0.5, 1.0, 1.5, 2.0, 3.0, and 4.0 mM). Note that contraction exceeds 2 mN at 0.11 mM halothane and 1.5 mM caffeine.

*al.*⁴ We identified a nucleotide exchange C-T at nucleotide position 10084 within the ND3 gene, which encodes a subunit of the complex I of the mitochondrial respiratory chain. This base pair substitution replaces the amino acid isoleucine by a threonine in the transcribed polypeptide. The substitution was detected at an almost 100% level in

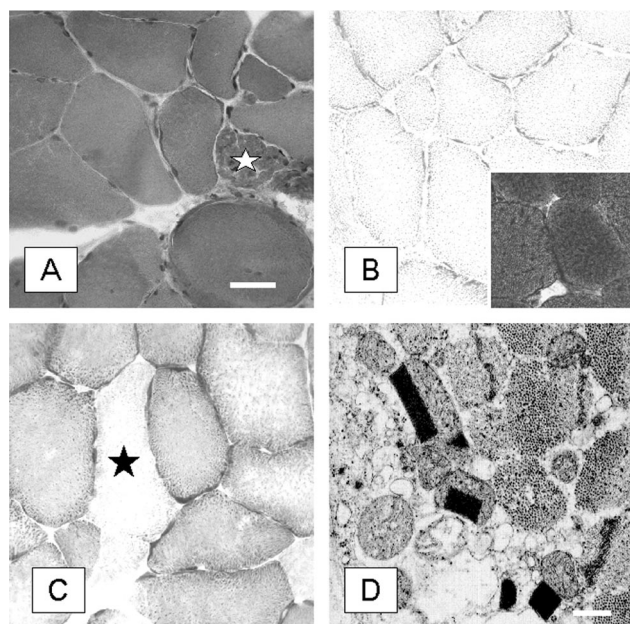


Fig. 2. (A) Myopathic changes (increased variability of fiber diameters, increased endomysial connective tissue, several internal myonuclei) and a "ragged" fiber (asterisk). Bar represents 25 μ m. (B) Almost negative enzyme histochemical reaction for myoadenylate deaminase activity in the patient's muscle. Insert: normal human control. Same magnification as in (A). (C) Cytochrome-C-oxidase (CCO) stain (enzyme histochemistry) reveals multiple fibers with hyporeactive central zones. A single fiber (asterisk) lacks CCO activity. Same magnification as in (A). (D) Multiple mitochondria with "paracrystalline", electron-dense inclusions (electron microscopy, magnification 12,000).

the mtDNA isolated from skeletal muscle. This base pair exchange has not been reported to be pathogenic so far. No other alterations of the mtDNA were detected such as deletions or duplications using Southern-blotting (not shown).

As the results of all morphologic investigations of the muscle biopsy were consistent with the diagnosis of a mitochondrial myopathy, the patient was further clinically tested by bicycle ergometry (30 watt for 15 min). Indeed, already before the patient underwent this test pathologic lactate values were detected: (before exercise: 3.7 mM; normal: ≤ 2 mM). After 15 min bicycle riding at 30 watts, lactate levels increased up to 4.0 mM whereas in normal probands lactate remains within the normal range. Even 30 min after ergometry, lactate was still elevated (2.4 mM). These test results were reproducible in a second setting performed 1 week later.

Discussion

This case report describes the combination of a slowly progressive muscle disorder caused by two distinct metabolic defects and malignant hyperthermia susceptibility (MHS). The relevance of the pathogenic role of the metabolic defects detected is strengthened by the fact that the most common mutations in the RYR1 gene were excluded as a possible cause of MHS in this patient. Both metabolic defects which we disclosed in the patient's skeletal muscle are related to the energy-metabolism of the muscle.

The muscle-specific enzyme myoadenylate deaminase is involved in the energy metabolism of the skeletal muscle by conversion of adenosine monophosphate to ammonia and inosine monophosphate and thereby facilitating the regeneration of ATP from ADP. MAD deficiency represents a frequent defect of skeletal muscle caused by mutations in the AMPD1-gene, characterized by symptoms like myalgia and cramps, exercise intolerance, elevated CK levels and rhabdomyolysis.^{5,6} The patient reported here showed all these clinical symptoms as well as increased CK-values.

The second defect affecting the energy metabolism in muscle was a mitochondrial dysfunction leading to severe, slowly deteriorating muscle-related symptoms such as weakness, myalgia and cramps, and recurrent myoglobinuria. On the one hand, this diagnosis was strongly supported by the specific findings in the muscle biopsy. On the other hand, pathologically increased levels of lactate in the serum at rest as well as an abnormal increase of serum lactate levels during bicycle exercise were found.

Mitochondrial diseases represent disorders caused by functional impairment of mitochondrial energy metabolism affecting primarily tissues and organs with a high-energy demand like skeletal and cardiac muscle and the central nervous system. Clinical manifestations of mitochondrial disorders are variable, ranging from isolated myopathy to complex multisystem syndromes.⁷ More than 40 years ago, the combination of myopathy and severe hypermetabolic symptoms resembling a hyperthyroidism syndrome were assigned to the defective

respiratory control of mitochondria.^{8,9} Meanwhile, a huge variety of well-defined syndromes due to mitochondrial dysfunctions have been identified.¹⁰

In the mitochondrial DNA from our patient, we excluded all pathogenic point mutations known to date by sequencing all regions of the mitochondrial genome where these point mutations are located ("hot spots"). Moreover, any gross rearrangements of the mitochondrial DNA such as duplications or deletions were ruled out by Southern blotting. However, we detected a base pair substitution T→C at nucleotide-position 10084 in the mitochondrial DNA within the ND3 gene. This substitution was detected in a high proportion (more than 75%) of mitochondrial genomes in muscle. Although this base-pair substitution is not highly conserved among several species, it might represent a mitochondrial "at-risk haplotype" for MH-susceptibility. The ND3 gene encodes a polypeptide which is assembled to the multi-protein-complex-I of the mitochondrial respiratory chain and thus is directly involved in the mitochondrial-based energy metabolism by conferring ATP to the cells.

Concerns about MH susceptibility in patients suffering from mitochondrial disorders are based on a possible mitochondrial involvement in the pathogenesis of MH. Defects in the mitochondrial function seem to play a major role in the development of a MH crisis¹¹ and mitochondrial Ca²⁺ efflux is known to be involved in the perpetuation of MH. Guidelines for the anesthetic management of these patients are lacking and clinical case reports are contradictory: Ohtani *et al.*¹² reported on a MH crisis in a mitochondrial myopathic patient after induction with succinylcholine. The patient was treated promptly and successfully, but whether a subsequent IVCT confirmed or ruled out MH susceptibility remains unreported. It is noteworthy that other patients suffering from mitochondrial myopathies seem to have received

MH triggering substances (halothane, succinylcholine) not leading to any complications.¹³

Our data do not yet confirm an association between MHS and combined metabolic defects in skeletal muscle such as MAD deficiency and mitochondrial myopathy, both affecting the energy metabolism. However, this case report extends the spectrum of metabolic defects of the skeletal muscle as a possible cause of MHS and may warrant the consideration of MH susceptibility in patients with metabolic muscle disorders.

References

1. Ording H: Pathophysiology of malignant hyperthermia. *Ann Fr Anesth Reanim* 1989; 8:411-6
2. The European Malignant Hyperpyrexia Group: A protocol for the investigation of malignant hyperpyrexia (MH) susceptibility: *Br J Anaesth* 1984;56:1267-9
3. Fishbein WN, Davis JI, Foellmer JW, Nieves S, Merezhinskaya NA: Competitive Allele-specific Oligomers Polymerase Chain Reaction Assay for the cis Double Mutation in AMPD1 That Is the Major Cause of Myo-adenylate Deaminase Deficiency. *Mol Diagn* 1997; 2:121-128
4. Raffelsberger T, Rossmannith W, Thaller-Antlanger H, Bittner RE: CPEO associated with a single nucleotide deletion in the mitochondrial tRNA(Tyr) gene. *Neurology* 2001; 57:2298-301
5. Fishbein WN: Primary, secondary, and coincidental types of myoadenylate deaminase deficiency. *Ann Neurol* 1999; 45:547-8
6. Fishbein WN, Muldoon SM, Deuster PA, Armbrustmacher VW: Myoadenylate deaminase deficiency and malignant hyperthermia susceptibility: Is there a relationship? *Biochem Med* 1985; 34:344-54
7. Morgan-Hughes JA, Hanna MG: Mitochondrial encephalopathies: The enigma of genotype versus phenotype. *BBA-Bioenergetics* 1999; 1410:125-45
8. Luft R, Ikkos D, Palmieri G, Ernster L, Afzelius B.A.: A case of severe hypermetabolism of non thyroid origin with a defect in the maintenance of mitochondrial respiratory control: A correlated clinical, biochemical and morphological study. *J. Clin. Invest* 1962; 41:1776-804
9. Ernster L, Ikkos D, Luft R: Enzymatic activities of human skeletal muscle mitochondria: A tool in clinical metabolic research. *Nature* 1959; 184:1851-4
10. Howell, N: Human mitochondrial diseases: answering questions and questioning answers. *Int Rev Cytol* 1999; 186:49-116
11. Fletcher JE, Rosenberg H: Pathophysiology of malignant hyperthermia. Hyperthermic and hypermetabolic disorders, exertional heat stroke, malignant hyperthermia, and related syndromes. Edited by Hopkins PM, Ellis FR. Cambridge University Press 1996,132-56
12. Ohtani Y, Miike T, Ishitsu T: A case of malignant hyperthermia with mitochondrial dysfunction (letter). *Brain Dev* 1985; 7:249
13. Burns A, Shelley M: Anaesthesia for patients with mitochondrial myopathy. *Anaesthesia* 1989; 14:975-7

Pregnant Patient with Primary Pulmonary Hypertension: General Anesthesia and Extracorporeal Membrane Oxygenation Support for Termination of Pregnancy

Hitoaki Satoh, M.D.,* Yuichiro Masuda, M.D.,† Shinichiro Izuta, M.D.,† Hideaki Yaku, M.D., Ph.D.,‡ Hidefumi Obara, M.D., Ph.D.§

PRIMARY pulmonary hypertension (PPH) is a progressive and fatal disease characterized by elevation of the pulmonary vascular resistance and right heart failure.^{1,2} PPH often becomes evident during pregnancy and may lead to maternal death during pregnancy, labor, or in the postpartum period. We describe a case of a pregnant woman with severe PPH and heart failure who underwent Cesarean section for termination of pregnancy under general anesthesia with the assistance of extracorporeal membrane oxygenation (ECMO).

Case Report

A 33-yr-old primigravida woman (147 cm, 39.5 kg, body surface area 1.28 m²) was transferred at 18 weeks gestation for evaluation of heart failure. Her sister had died suddenly of unknown causes at 5 yr of age. The patient had been asymptomatic over the preceding few years except for shortness of breath on exertion. She had experienced increasing shortness of breath over several weeks and on the day of admission was dyspneic at rest.

A 12-lead electrocardiograph demonstrated a sinus tachycardia (104 beats/min) with right axis deviation and incomplete right bundle branch block. Transthoracic echocardiography demonstrated right ventricular dilatation with compression of the ventricular septum toward the left ventricle. Defects of the atrial and ventricular septum were not detected. A pulmonary artery and radial artery catheter were inserted under local anesthesia. The hemodynamic parameters obtained on the day of hospital admission are presented in table 1. The respiratory rate was 28 breaths/min. Blood tests revealed a white blood cell count 12,300/ μ l, hemoglobin 12.6 g/dl and platelet count 6.6×10^4 / μ l while arterial blood gases on room air were pH 7.395, PaCO₂ 28.4 mmHg, PaO₂ 85.8 mmHg and base excess -6.4 mm. Pulmonary arteriography excluded a pulmonary embolism. On the basis of these data, a clinical diagnosis of PPH was made. The patient was treated with heparin 10,000 U/day, nitroglycerin $0.5 \mu\text{g} \cdot \text{kg}^{-1} \cdot \text{min}^{-1}$, and antithrombin III 1,500 unit by intravenous administration.

The patient developed worsening dyspnea on the second day after admission. The pulmonary artery pressure (PAP) further increased to 100/60 mmHg (mean 74), exceeding the systemic arterial pressure (SAP) of 98/64 mmHg (mean 77); the ratio of mean PAP to mean SAP

(Pp/Ps) increased from 0.52 to 0.96. The platelet count decreased to 5×10^4 / μ l. It was decided that interruption of pregnancy was in the best interest of the patient. The obstetricians judged that a vaginal evacuation at 18 weeks gestation was inappropriate in view of the immaturity of the uterine cervix and the anticoagulant therapy. Therefore, a Cesarean section was planned under general anesthesia with the support of ECMO. ECMO was composed of a centrifugation pump and a pump controller (Capiiox SP-101, Terumo Inc., Tokyo, Japan), a heparin-bonding ECMO circuit (Capiiox-SX EBS cardiopulmonary kit, Terumo Inc.), and heparin-bonding cannulae (Capiiox percutaneous catheter, Terumo Inc.). After a small incision to expose the femoral artery and vein under local anesthesia, a 21-French draining cannula was inserted into the right atria through the femoral vein and a 17-French perfusion cannula was inserted through the femoral artery, in the fluoroscopy room. ECMO was started at a flow rate of $1.5 \text{ l} \cdot \text{min}^{-1} \cdot \text{m}^{-2}$.

In the operating room, general anesthesia was induced with midazolam (2 mg), fentanyl (200 μ g), and vecuronium (10 mg) allowing tracheal intubation. Anesthesia was maintained with intravenous fentanyl (200 μ g/h) and propofol (100 mg/h). The patient was on mechanical ventilation with oxygen and air (FIO₂ = 0.4). ECMO flow was maintained between 2.5–4.0 l/min throughout the anesthesia. SAP and cardiac output (CO), which was measured by continuous thermodilution (Vigilance, Continuous cardiac output monitor, Edwards Lifesciences, Irvine, CA), were essentially unchanged following induction and tracheal intubation. The PAP gradually decreased while the SAP was unchanged through the general anesthesia. The operation was performed uneventfully with 470 g of blood loss. The activated clotting time (ACT) was 150 s and 144 s at the start and the end of anesthesia respectively.

The patient was admitted to the intensive care unit for postoperative management and was extubated 4 h after the end of the anesthesia. We were unable to wean the patient from ECMO by simply lowering the flow rate, because lowering of the ECMO flow rate resulted in an increase in the PAP and cardiac index (CI) and a fall in the SAP (fig. 1). On the fourth postoperative day (POD), nitric oxide inhalation was commenced through a semiclosed circuit with a tight fitting facemask. In addition, an epoprostenol (prostacyclin) infusion was commenced via the pulmonary artery catheter, and was continued at a dose of $4.5\text{--}6.5 \text{ ng} \cdot \text{kg}^{-1} \cdot \text{min}^{-1}$ throughout the patient's stay in the intensive care unit. PAP was 93/36 mmHg (mean 56), 96/36 mmHg (mean 57), and 95/19 mmHg (mean 45) before, during 10 parts per million, and 20 parts per million of nitric oxide inhalation, respectively, while ECMO flow was set at $1.2 \text{ l} \cdot \text{min}^{-1} \cdot \text{m}^{-2}$. Nitric oxide inhalation was discontinued on the sixth POD, as it was ineffective.

The ECMO flow rate was slowly tapered and the ECMO circuit required changing on the ninth, thirteenth, and seventeenth POD as a result of degradation and coagulation of the artificial lung. When the flow rate was decreased to $0.3 \text{ l} \cdot \text{m}^{-2}$ on the eighteenth POD, the PAP was 89/22 mmHg (mean 45), SAP was 105/55 mmHg (mean 72), and the Pp/Ps ratio was 0.63, which was comparable to the value on the fourth POD. Although lung transplantation was considered as an alternate therapeutic strategy, there was no suitable brain-dead or live related donor available. The patient died of right heart failure 7 h after the withdrawal of ECMO on the nineteenth POD. An autopsy revealed

* Resident, † Instructor, ‡ Associate Professor, Department of Anesthesiology and Division of Intensive Care Medicine. § Professor and Chair, Kobe University Graduate School of Medicine, Faculty of Medical Sciences, Department of Anesthesia and Perioperative Medicine.

Received from Kobe University Hospital, Kobe, Japan. Submitted for publication February 22, 2002. Accepted for publication July 23, 2002. Support was provided solely from institutional and/or departmental sources.

Address reprint requests to Dr. Yaku: Department of Anesthesiology and Division of Intensive Care Medicine, Kobe University Hospital, 7-5-2 Kusunoki-cho Chuo-ku Kobe 650-0017, Japan. Address electronic mail to: yaku@med.kobe-u.ac.jp. Individual article reprints may be purchased through the Journal Web site, www.anesthesiology.org.

Table 1. Hemodynamic Parameters on Hospital Admission Day

Heart rate (beat/min)	110
Right atrial pressure (mmHg) (mean)	22/18 (14)
PCWP (mmHg) (mean)	(15)
Right ventricular pressure (mmHg) (mean)	78/-4 (24)
Pulmonary arterial pressure (mmHg) (mean)	77/33 (47)
Systemic arterial pressure (mmHg) (mean)	122/73 (90)
Cardiac output (l/min)	2.3
Cardiac index ($\text{l} \cdot \text{min}^{-1} \cdot \text{m}^{-2}$)	1.8
Pp/Ps ratio	0.52
Systemic vascular resistance ($\text{dyne} \cdot \text{s}^{-1} \cdot \text{cm}^{-5}$)	2643
Pulmonary vascular resistance ($\text{dyne} \cdot \text{s}^{-1} \cdot \text{cm}^{-5}$)	1113

PCWP = pulmonary capillary wedge pressure; Pp/Ps ratio = ratio of mean pulmonary arterial pressure to mean systemic arterial pressure.

pathologic evidence of PPH with medial thickening and narrowing of the lumina of the pulmonary arteries.

Discussion

PPH is a very rare disease, but the onset of PPH is most common in young to middle-aged women.^{1,2} Pregnancy often precedes the development of symptoms of PPH. Indeed, the mortality rate of pregnant patients with PPH is very high, at about 30%.³ During the first, second, and

third trimesters the total blood volume increases above the prepregnant level by 10%, 30%, and 45% respectively.⁴ This is associated with an increase in the end diastolic volume and heart rate while CO increases by 50% by the second trimester during a normal pregnancy.⁵ Pregnant women with PPH tolerate this hemodynamic stress very poorly and may therefore develop heart failure during pregnancy, particularly in the second and third trimester.⁶ Moreover, the vast majority of patients with PPH die in the postpartum period, because venous return is suddenly increased as the blood volume retained in the dilated veins of the gravid uterus returns to circulation by uterine contraction.⁷ PPH patients, classified in the New York Heart Association (NYHA) function classes I and II, exhibit a significant fall in pulmonary vascular resistance with nitric oxide, epoprostenol, or adenosine, and can be managed by the use of these drugs or calcium-channel blockers.² However, severe PPH, classified in NYHA function classes III and IV, are treated by epoprostenol administration or lung transplantation.^{2,8,9}

The optimal method to anesthetize patients with PPH for Cesarean section is controversial but depends on the severity of the disease in individual cases.¹⁰ Most previous reports describing successful management of such patients utilized epidural anesthesia.¹¹⁻¹⁶ All PPH patients described in these reports exhibited a normal CO in the preoperative period and lowering of the PAP following the administration of vasodilators or nitric oxide inhalation.¹¹⁻¹⁶ General anesthesia is also of potential use for PPH patients,¹⁷ but does have significant disadvantages, such as increased pulmonary vascular resistance by positive pressure ventilation or nitrous oxide inhalation,¹⁸ and reduced cardiac contractility by volatile anesthetic agents. Since the patient in this report exhibited a low CO and was classified in NYHA IV in the preoperative period, we used ECMO for the perioperative cardiopulmonary management.

ECMO by means of peripheral cannulation is also called percutaneous cardiopulmonary support, and is an established therapeutic strategy in adult patients with cardiopulmonary failure. ECMO is mostly used for cardiac support and is rarely used for respiratory distress. ECMO involves partial cardiopulmonary support and should be applied for a short duration. Therefore ECMO is most appropriate for the patient whose cardiopulmonary function is expected to recover within a few days. Acute pulmonary embolism accompanied by pulmonary hypertension and right heart failure is a suitable indication for ECMO,^{19,20} because the heart failure and pulmonary hypertension may be ameliorated following surgical embolectomy. Although all components of ECMO were heparin-bonded, use of an anticoagulant drug is recommended so that ACT is kept over 150 s. Heparin-bonded components of ECMO would be advantageous for minimizing operative bleeding by administering none or the least dose of anticoagulant drugs.

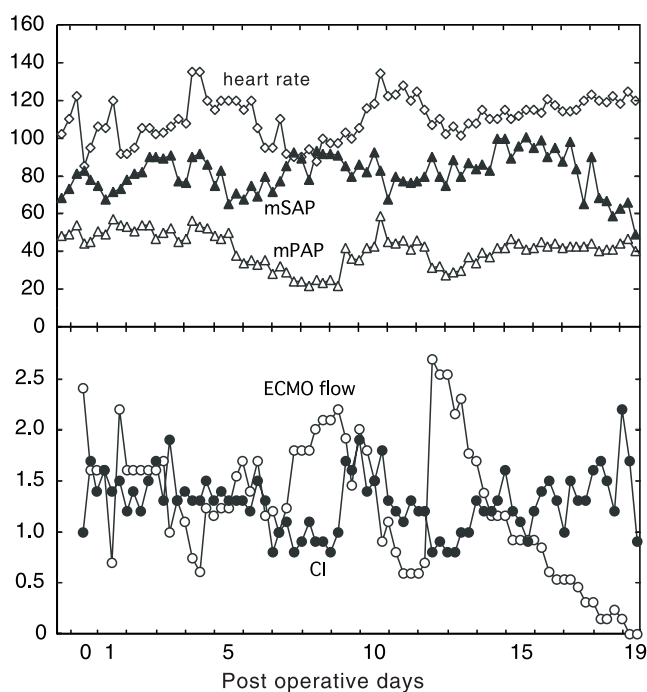


Fig. 1. The clinical course of the patients. Upper section indicates heart rate (beat/min) (open diamond), mean systemic arterial pressure (mSAP) (mmHg) (closed diamond) and mean pulmonary artery pressure (mPAP) (mmHg) (open square). Lower section demonstrates the values of cardiac index (CI) ($\text{l} \cdot \text{min}^{-1} \cdot \text{m}^{-2}$) (open circle), ECMO flow per body surface area ($\text{l} \cdot \text{min}^{-1} \cdot \text{m}^{-2}$) (closed circle).

There are few reports about the application of ECMO during general anesthesia for patients with pulmonary hypertension. In an earlier report of a patient with chronic pulmonary hypertension, ECMO was successfully applied to a patient scheduled to undergo Cesarean section using general anesthesia.²¹ Previous reports describe the use of ECMO in the successful recovery of a patient with severe PPH following a cardiac arrest during the induction of anesthesia for lung transplantation.^{22,23} Since the pulmonary vascular resistance of patients with severe PPH might be fixed or progressively increase, we were unable to wean our patient off ECMO after the termination of the pregnancy despite the administration of nitroglycerin and epoprostenol and nitric oxide inhalation.^{24 14 16}

Although no conclusion can be drawn from this case, we suggest that ECMO should be considered for the perioperative management of patients with severe PPH to prevent circulatory failure or as a bridging therapy prior to lung transplantation.

References

1. Rubin LJ: Primary pulmonary hypertension. *N Engl J Med* 1997; 336:111-7
2. Gaine SP, Rubin LJ: Primary pulmonary hypertension. *Lancet* 1998; 352:719-25
3. Weiss BM, Zemp L, Seifert B, Hess OM: Outcome of pulmonary vascular disease in pregnancy: A systematic overview from 1978 through 1996. *J Am Coll Cardiol* 1998; 31:1650-7
4. Ueland K: Maternal cardiovascular dynamics. VII. Intrapartum blood volume changes. *Am J Obstet Gynecol* 1976; 126:671-7
5. Thornburg KL, Jacobson SL, Giraud GD, Morton MJ: Hemodynamic changes in pregnancy. *Semin Perinatol* 2000; 24:11-4
6. Roberts NV, Keast PJ: Pulmonary hypertension and pregnancy: A lethal combination. *Anaesth Intensive Care* 1990; 18:366-74
7. Demas NW: Maternal death due to primary pulmonary hypertension. *Trans Pac Coast Obstet Gynecol Soc* 1972; 40:64-7
8. McLaughlin VV, Gentner DE, Panella MM, Rich S: Reduction in pulmonary vascular resistance with long-term epoprostenol (prostacyclin) therapy in primary pulmonary hypertension. *N Engl J Med* 1998; 338:273-7
9. Barst RJ, Rubin LJ, Long WA, McGoon MD, Rich S, Badesch DB, Groves BM, Tapson VF, Bourge RC, Brundage BH, Koerner SK, Langleben D, Keller CA, Murali S, Uretsky BF, Clayton LM, Jobsis MA, Blackburn SD, Shortino D, Crow DW: A comparison of continuous intravenous epoprostenol (prostacyclin) with conventional therapy for primary pulmonary hypertension. *N Engl J Med* 1996; 334:296-302
10. Thornhill ML, Camann WR: Cardiovascular Disease, Obstetric anesthesia: Principles and practice. Edited by Chestnut DH. St. Louis, MO, Mosby, 1994, pp 746-79
11. Breen TW, Janzen JA: Pulmonary hypertension and cardiomyopathy: Anaesthetic management for caesarean section. *Can J Anaesth* 1991; 38:895-9
12. Weiss BM, Maggiorini M, Jenni R, Lauper U, Popov V, Bombeli T, Spahn DR: Pregnant patient with primary pulmonary hypertension: Inhaled pulmonary vasodilators and epidural anesthesia for cesarean delivery. *ANESTHESIOLOGY* 2000; 92:1191-4
13. Nelson DM, Main E, Crafford W, Ahumada GG: Peripartum heart failure due to primary pulmonary hypertension. *Obstet Gynecol* 1983; 62:58s-63s
14. Lam GK, Stanford RE, Thorp J, Moise KJ, Cairns BA: Inhaled nitric oxide for primary pulmonary hypertension in pregnancy. *Obstet Gynecol* 2001; 98:895-8
15. Slomka F, Salmeron S, Zetlaoui P, Cohen H, Simonneau G, Samii K: Primary pulmonary hypertension and pregnancy: Anesthetic management for delivery. *ANESTHESIOLOGY* 1988; 69:959-61
16. Decoene C, Bourzoufi K, Moreau D, Narducci F, Crepin F, Krivosic-Horber R: Use of inhaled nitric oxide for emergency Cesarean section in a woman with unexpected primary pulmonary hypertension. *Can J Anesth* 2001; 48:584-7
17. O'Hare R, McLoughlin C, Milligan K, McNamee D, Sidhu H: Anaesthesia for caesarean section in the presence of severe primary pulmonary hypertension. *Br J Anaesth* 1998; 81:790-2
18. Schulte-Sasse U, Hess W, Tarnow J: Pulmonary vascular responses to nitrous oxide in patients with normal and high pulmonary vascular resistance. *ANESTHESIOLOGY* 1982; 57:9-13
19. Davies MJ, Arsiwala SS, Moore HM, Kerr S, Sosnowski AW, Firmin RK: Extracorporeal membrane oxygenation for the treatment of massive pulmonary embolism. *Ann Thorac Surg* 1995; 60:1801-3
20. Hsieh PC, Wang SS, Ko WJ, Han YY, Chu SH: Successful resuscitation of acute massive pulmonary embolism with extracorporeal membrane oxygenation and open embolectomy. *Ann Thorac Surg* 2001; 72:266-7
21. Sugioka J, Nakajima T, Ohsumi H, Kuro M, Sasako Y: Anesthetic management using percutaneous cardiopulmonary support for cesarean section in a patient with severe pulmonary hypertension. *Masui* 1995; 44:574-8
22. Myles PS, Hall JL, Berry CB, Esmore DS: Primary pulmonary hypertension: Prolonged cardiac arrest and successful resuscitation following induction of anesthesia for heart-lung transplantation. *J Cardiothorac Vasc Anesth* 1994; 8:678-81
23. Hohn L, Schweizer A, Morel DR, Spiliopoulos A, Licker M: Circulatory failure after anesthesia induction in a patient with severe primary pulmonary hypertension. *ANESTHESIOLOGY* 1999; 91:1943-5
24. Robinson JN, Banerjee R, Landberg MJ, Thiet MP: Inhaled nitric oxide therapy in pregnancy complicated by pulmonary hypertension. *Am J Obstet Gynecol* 1999; 180:1045-6