

## Decrease in Bispectral Index Preceding Intraoperative Hemodynamic Crisis: Evidence of Acute Alteration of Propofol Pharmacokinetics

David M. Honan, M.B., F.F.A.R.C.S.I.,\* Patrick J. Breen, M.B., F.F.A.R.C.S.I.,\* John F. Boylan, M.B., F.R.C.P.C.,† Neil J. McDonald, M.B., F.F.A.R.C.S.I.,† Talmage D. Egan, M.D.‡

THE bispectral index (BIS<sup>®</sup>, Aspect Medical Systems Inc., Newton, MA) is a processed electroencephalographic variable which correlates with depth of hypnosis in adult patients during general anesthesia.<sup>1,2</sup> It has also been used clinically to guide anesthetic drug administration,<sup>3</sup> and to quantify the pharmacodynamic action of anesthetic drugs in the laboratory setting.<sup>4</sup> BIS has previously been shown to decrease following hypovolemic cardiac arrest, lagging behind the decrease in blood pressure by approximately 2 min.<sup>5</sup> We report a case of unrecognized venous hemorrhage with a fatal outcome during total intravenous anesthesia (TIVA) for elective abdominal aortic aneurysm repair, where the BIS score began to decrease well before other monitored variables suggested clinical deterioration, and we propose that BIS-derived data may provide early insights into altered drug pharmacokinetics due to hemorrhage.

### Case Report

A 70-yr-old woman was admitted for elective abdominal aortic aneurysm repair. History was unremarkable. Anesthesia was induced with alfentanil and propofol, and maintained with infusions of alfentanil and propofol, the latter being target-controlled and varying at protocol-determined time points. Routine monitoring of vital signs was supplemented with BIS monitoring. The patient had consented to

participate in a clinical investigation of the antioxidant effects of propofol TIVA during major vascular surgery, and blood samples for this purpose were drawn from the arterial line at defined time intervals. A stable level of anesthesia was maintained, with a BIS score of approximately 35 (untargeted). Intraoperatively, the patient was hemodynamically stable. An aortic graft was inserted, with a cross-clamp time of 60 min.

Immediately after unclamping, the patient's BIS level decreased rapidly from its steady state value of 35 to a value of 20. Conferral with surgical colleagues did not reveal any concerns on their part at that time. Heart rate and blood pressure remained stable over the next 10 min, but then decreased from 120/70 to 65/30 mmHg (Fig. 1). Simultaneously, the surgical team reported major venous bleeding. The patient's blood pressure normalized with aggressive volume resuscitation and discontinuation of anesthetic agents, but surgical hemostasis proved unsuccessful. Despite fluid and inotrope therapy, the patient's vital signs deteriorated, and she died of refractory hypotension after 2 h of resuscitation. Although sampling of propofol concentrations was abandoned once the patient began to deteriorate, all three previous samples were retained for analysis. Subsequent assay revealed that the final sample (drawn following declamping) had a propofol concentration significantly in excess of the target level (table 1). The target-controlled infusion pump (Diprifusor, Fresenius Vial S.A., Brezins, France) satisfied subsequent technical examination.

### Discussion

The BIS monitor provides useful information concerning the depth of hypnosis in healthy patients with stable vital signs, and has been validated with the TIVA combination of propofol and alfentanil.<sup>6,7</sup> However, the effect on BIS of hemodynamic instability is unknown, although decreasing BIS values have previously been shown to follow severe hypotension.<sup>5</sup> Our patient's abrupt BIS depression during steady state TIVA occurred well before clinical deterioration. Experimental data indicate that hypovolemia decreases the dose requirement for anesthetics, and that an increased hypnotic effect of propofol may be attributable to changes in both pharmacokinetics and end-organ sensitivity.<sup>8</sup> Other experimental work has shown that hemorrhagic shock alters both the distribution and the clearance of opioids, resulting in higher plasma concentrations.<sup>9,10,11</sup> It is not clear in this case whether the decrease in BIS was related only to altered drug pharmacokinetics (*i.e.*, an increased propofol concentration) or perhaps also to altered pharmacodynamics (*i.e.*, increased sensitivity to propofol). It is also conceivable that the decrease in BIS resulted partly from a profound decrease in cerebral perfusion

Interested readers are also directed to another article on this topic appearing in this issue. See Kazama T, Kurita T, Morita K, Nakata J, Sato S: Influence of hemorrhage on propofol pseudo-steady state concentration. *ANESTHESIOLOGY* 2002; 97:1156-61.

This article is featured in "This Month in Anesthesiology." Please see this issue of *ANESTHESIOLOGY*, page 6A.

\* Clinical Research Fellow, † Consultant Anesthetist (Staff Physician), Department of Anaesthesia, Intensive Care and Pain Medicine, St. Vincent's University Hospital. ‡ Associate Professor, Department of Anesthesiology, University of Utah School of Medicine.

Received from the Department of Anaesthesia, Intensive Care and Pain Medicine, St. Vincent's University Hospital, Dublin, Ireland; and the Department of Anesthesiology, University of Utah School of Medicine, Salt Lake City, Utah. Submitted for publication December 12, 2001. Accepted for publication April 29, 2002. Support was provided by Zeneca Ireland plc, Dublin, Ireland, which paid for the propofol assay of the three blood samples at Dr. Mirakhor's laboratory at Queen's University, Belfast, Northern Ireland. Other support was provided by the St. Vincent's University Hospital, Dublin, Ireland.

Address reprint requests to Dr. Honan: Department of Anaesthesia, Intensive Care and Pain Medicine, St. Vincent's University Hospital, Dublin 4, Ireland. Address electronic mail to: honan@iol.ie. Individual article reprints may be purchased through the Journal Web site, [www.anesthesiology.org](http://www.anesthesiology.org).

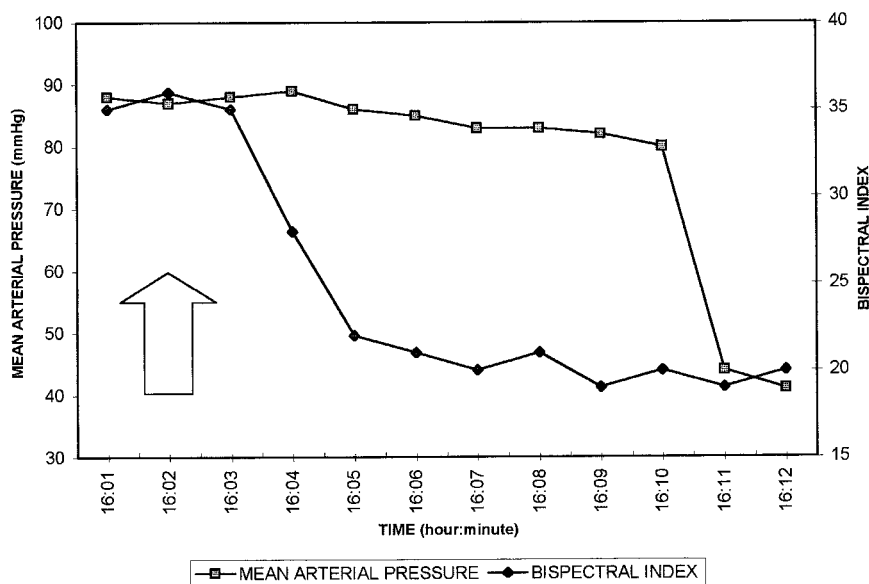


Fig. 1. Changes in bispectral index and mean arterial pressure, after declamping (arrow).

(independent of pharmacologic mechanisms), but no data exist to support or refute this possibility.

In the setting of steady state TIVA *via* an upper limb vein, with uncontrolled venous hemorrhage from veins draining into the inferior vena cava, two potential factors might explain the measured rise in propofol concentration, and the decrease in BIS, prior to clinical deterioration. First, with a reduced venous return and consequent decrease in cardiac output, brain perfusion would tend to be preserved while blood flow to other vascular beds would decrease. The reduced distribution volume associated with shock would result in higher propofol concentrations.<sup>12</sup> Second, because the clearance of propofol is limited by liver blood flow, a decrease in liver blood flow during hypovolemia would be expected to result in higher plasma propofol concentrations, although this mechanism is unlikely to be important within the short time frame involved in this report.

Our experience suggests that BIS-derived data may provide useful insights into altered patient physiology and pharmacology when changes in BIS occur during apparent steady state conditions of anesthesia. In certain circumstances, an altered BIS value may reflect a “prodromal” change in depth of anesthesia arising from unexpected alterations in drug pharmacokinetics. This

change may reflect subtle, regional hemodynamic decompensation before overt clinical deterioration.

We suggest that sudden, unexplained decreases in BIS score during otherwise steady state conditions of anesthetic delivery should prompt consideration not simply of depth of anesthesia, but of factors that may alter anesthetic disposition and effect. New intraoperative circumstances, especially hypovolemia, may result in altered depth as a result of changes in drug disposition; early detection of these changes may have implications for the patient’s clinical well-being. While the BIS is clearly not designed or intended to monitor hemodynamic changes, it may indirectly reflect hemodynamic alterations when such alterations influence the pharmacokinetics or pharmacodynamics of anesthetics.

The authors thank the laboratory staff of Rajinder K. Mirakhur, M.D., Ph.D., F.R.C.A., Department of Anaesthesia, Queen’s University, Belfast, Northern Ireland, and Zeneca Ireland plc, Dublin, Ireland, for their assistance with the propofol assay.

## References

1. Rampil IJ: A primer for EEG signal processing in anesthesia. *ANESTHESIOLOGY* 1998; 89:980-1002
2. Glass PS, Bloom M, Kears L, Rosow C, Sebel P, Manberg P: Bispectral analysis measures sedation and memory effects of propofol, midazolam, isoflurane and alfentanil in healthy volunteers. *ANESTHESIOLOGY* 1997; 86:836-47
3. Song D, Joshi JP, White PF: Titration of volatile anesthetics using bispectral index facilitates recovery after ambulatory anesthesia. *ANESTHESIOLOGY* 1997; 87:842-84
4. Billard V, Gambus PL, Chamoun N, Stanski DR, Shafer SL: A comparison of spectral edge, delta power, and bispectral index as EEG measures of alfentanil, propofol, and midazolam drug effect. *Clin Pharmacol Ther* 1997; 61:45-58
5. England MR: The changes in bispectral index during a hypovolemic cardiac arrest. *ANESTHESIOLOGY* 1999; 91:1947-9
6. Iselin-Chaves IA, Flaishon R, Sebel PS, Howell S, Gan TJ, Sigl J, Ginsberg B, Glass PS: The effect of the interaction of propofol and alfentanil on recall, loss of consciousness, and the bispectral index. *Anesth Analg* 1998; 87:949-55
7. Iselin-Chaves IA, El-Moalem HE, Gan TJ, Ginsberg B, Glass S: Changes in the auditory evoked potentials and the bispectral index following propofol or propofol and alfentanil. *ANESTHESIOLOGY* 2000; 92:1300-10
8. De Paepe P, Belpaire FM, Rosseel MT, Van Hoey G, Boon PA, Buylaert WA: Influence of hypovolemia on the pharmacokinetics and the electroencephalographic effect of propofol in the rat. *ANESTHESIOLOGY* 2000; 93:1482-90

Table 1. Target Versus Measured Blood Concentrations of Propofol at Three Event-related Time Points

	Target Propofol Concentration	Measured Propofol Concentration
Time 1 (preinduction)	0 µg/ml	0 µg/ml
Time 2 (at cross-clamping)	5 µg/ml	4.71 µg/ml
Time 3 (after declamping, at fall of BIS)	3 µg/ml	7.15 µg/ml

BIS = bispectral index

9. Egan TD, Kuramkote S, Gong G, Zhang J, McJames SW, Bailey PL: Fentanyl pharmacokinetics in hemorrhagic shock: A porcine model. *ANESTHESIOLOGY* 1999; 91:156–66

10. De Paep P, Belpaire FM, Rossell MT, Buylaert WA: The influence of hemorrhagic shock on the pharmacokinetics and the analgesic effect of morphine in the rat. *Fundam Clin Pharmacol* 1998; 12:624–30

11. Johnson KB, Kern SE, Hamber EA, McJames SW, Kohnstamm KM, Egan TD: Influence of hemorrhagic shock on remifentanyl: a pharmacokinetic and pharmacodynamic analysis. *ANESTHESIOLOGY* 2001; 94:322–32

12. Johnson KB, Egan TD, Kern SE, Whidden D, James L: The influence of hemorrhagic shock on propofol: A pharmacokinetic analysis (abstract). *ANESTHESIOLOGY* 2001; 95:A649

*Anesthesiology* 2002; 97:1305–8

© 2002 American Society of Anesthesiologists, Inc. Lippincott Williams & Wilkins, Inc.

## Visual Loss after Use of Nitrous Oxide Gas with General Anesthetic in Patients with Intraocular Gas Still Persistent Up to 30 days after Vitrectomy

Brendan J. Vote, M.D.,\* Richard H. Hart, M.D.,† David R. Worsley, M.D.,‡ James H. Borthwick, M.D.,§  
Stephen Laurent, M.D.,|| Archibald J. McGeorge, M.D.#

INTRAOCCULAR gas may enter an eye in a variety of ways: penetrating injury, infection, rapid decompression, gas bubble disease, or from therapeutic interventions by ophthalmologists.<sup>1</sup> Therapeutic use of intraocular gas provides internal retinal tamponade for retinal breaks or detachment, macular hole repair, and complicated diabetic vitrectomy. Unfortunately, gases used in intraocular surgery introduce a variety of potential problems. One problem is posed for patients requiring subsequent surgery (not necessarily ophthalmic) in the postoperative period while intraocular gas may still be present in the eye. We report three cases from three different centers where adverse events occurred after nitrous oxide (N<sub>2</sub>O)-induced general anesthesia in patients following recent vitrectomy with use of intraocular gas. A summary of principles of intraocular gases is provided, including recommendations for prevention and management of N<sub>2</sub>O-induced anesthesia-related intraocular gas complications.

### Case Reports

#### Case 1

A 73-yr-old man underwent vitrectomy and internal drainage of a large subretinal hemorrhage at the right macula (table 1 for summary of patient data). After fluid-air exchange, the eye (vitreous cavity) was filled with 14% perfluoropropane (C<sub>3</sub>F<sub>8</sub>) gas. Twenty-two days postoperatively, the patient underwent elective total hip replacement surgery during general anesthesia, which included N<sub>2</sub>O. The patient awoke from surgery with no perception of light (NPL) vision in the eye with intraocular gas. No visual recovery occurred and optic atrophy developed in the right eye.

\* Vitreoretinal Fellow, † Senior Registrar, || Consultant Anaesthetist, Department of Anaesthesia. # Vitreoretinal Surgeon, Auckland Hospital, Auckland. ‡ Vitreoretinal Surgeon, Waikato Hospital, Hamilton. § Vitreoretinal Surgeon, Christchurch Hospital, Christchurch.

Received from the Department of Ophthalmology, Department of Anaesthesia, Auckland Hospital, Auckland. Department of Ophthalmology, Waikato Hospital, Hamilton. Department of Ophthalmology, Christchurch Hospital, Christchurch; Department of Anaesthesia, Auckland Hospital, Auckland, New Zealand. Submitted for publication December 10, 2001. Accepted for publication May 1, 2002. Supported by Auckland Public Hospital, Auckland, New Zealand.

Address reprint requests to Dr. Laurent: Department of Anaesthesia, Private Bag 92024, Auckland, New Zealand. Address electronic mail to: stevel@adhb.govt.nz. Individual article reprints may be purchased through the Journal Web site, [www.anesthesiology.org](http://www.anesthesiology.org).

#### Case 2

An 80-yr-old man underwent vitrectomy for retinal detachment during general anesthesia. The eye was filled with 20% C<sub>3</sub>F<sub>8</sub> gas at the end of the procedure. The following day, examination showed a flat retina, normal intraocular pressure (IOP), and 70% gas fill (percentage vitreous cavity volume). Unfortunately urinary retention developed in the patient following the operation, requiring catheterization. Nine days postoperatively, the patient was progressing well, with hand movement visual acuity, 60% gas fill, and a flat inferior retina. He remained catheterized and transurethral prostate resection was performed during general anesthesia. N<sub>2</sub>O was used for the complete procedure. Overnight, the patient experienced ocular pain, but no emergent ophthalmic review was sought. When the ophthalmologist asked to see the patient the next day, the patient's IOP was slightly increased at 23 mmHg, and clinical features of total central retinal artery occlusion were present (marked relative afferent pupil defect, cherry red spot). Despite systemic and topical IOP-lowering agents, the patient's vision had deteriorated to NPL, which never recovered. Subsequent review confirmed development of optic atrophy.

#### Case 3

A 75-yr-old man underwent vitrectomy for macula hole and the eye filled with 20% C<sub>3</sub>F<sub>8</sub> gas. He then underwent emergency orthopedic surgery for a fractured neck of femur repair, with N<sub>2</sub>O use in general anesthesia 1 month later. Immediately after the orthopedic procedure, he reported loss of vision in his left eye to the staff in the recovery room. Examination 90 min after surgery revealed light perception visual acuity, a relative afferent pupil defect, and 50–60% gas bubble in the vitreous cavity. Fortunately visual acuity recovered to 6/24, though optic nerve pallor developed.

### Background

#### *Intraocular Gas–Intraocular Pressure Relation*

Whenever intraocular gas is used, the surgeon risks producing increased IOP from excessive volume and/or expansion of the intraocular gas. Gas expansion may cause ocular hypertension (increased IOP) in four circumstances: decreasing barometric pressure (altitude), influx of N<sub>2</sub>O, excessive concentration of an expanding gas, decreased facility of outflow (aqueous drainage) through the trabecular meshwork.<sup>1</sup>

**Table 1. Pertinent Preoperative, Operative, and Postoperative Data from Each Case**

Variable	Case 1	Case 2	Case 3
Second operation	Elective total hip replacement	Semielective transurethral resection of prostate	Emergency neck of femur fracture repair
Time after vitrectomy surgery	22 days	9 days	30 days
Visual acuity before second operation	CF (9 days prior)	HM (1 day prior)	—
IOP before second operation	Normal	Normal (17 mmHg)	Normal (15 mmHg)
Gas fill before second operation	—	60%	—
Other intraoperative factors implicated in visual loss	None	Low blood pressure approximately 5 min intraoperatively	None
Visual acuity after second operation (final acuity)	NPL	NPL	PL (6/24)
Time of postoperative examination	Day 0	Day 1 (14 h postoperative)	Day 0
Postoperative gas fill	—	50%	50–60%
Pain postoperatively	No	Yes	No
Postoperative IOP	Normal	23 mmHg (12 mmHg after treatment)	Digitally normal (no portable IOP measurement available)
Management	Topical and systemic IOP-lowering agents	Topical and systemic IOP-lowering agents	Topical and systemic IOP-lowering agents
Postoperative funduscopy appearance	Optic atrophy	Cherry red spot but perfused central retinal artery; subsequently developed optic atrophy	Temporal disc pallor but perfused retinal vessels; subsequently developed optic atrophy
Presumed lesion	CRAO? Ischemic optic neuropathy?	CRAO	CRAO? Ischemic optic neuropathy?

Preoperative, intraoperative, and postoperative data relate to the second operation, not the initial vitrectomy.

CF = counting fingers; HM = hand movements; NPL = no perception of light; PL = perception of light; IOP = intraocular pressure; CRAO = central retinal artery occlusion.

As the eye is somewhat elastic and contains fluid and solids, the relation between ocular volume and gas pressure is more complex than is predicted by ideal gas laws (Boyle's, Charles', Avagadro's and Dalton's laws). Nonetheless these laws allow an understanding of the behavior of intraocular gases in the clinical setting. Of perhaps greater relevance, Fick's law determines growth or shrinkage of gas bubbles in the eye.<sup>1</sup> Essentially, behavior of an intraocular gas bubble after introduction into the globe depends on its solubility compared with atmospheric gases (room air). Thus, three types of gases may be introduced: room air; a gas that is less soluble or less diffusible than room air (e.g., sulfurhexafluoride [ $\text{SF}_6$ ] and  $\text{C}_3\text{F}_8$ ), which thus persists longer than air; a gas that is more soluble or diffusible than room air (e.g., carbon dioxide and  $\text{N}_2\text{O}$ ) and thus disappears more quickly than air.<sup>1</sup>

#### *Specific Gases Pertinent to the Ophthalmic-Anesthetic Situation*

A variety of gases can be used in an ophthalmic setting. Filtered room air,  $\text{SF}_6$ , and  $\text{C}_3\text{F}_8$  are those most commonly used. The duration of intraocular gas varies with the volume, concentration, and type of gas used. Larger more concentrated volumes of gases less soluble than air last longer.<sup>2</sup> Air typically resorbs within a few days.  $\text{SF}_6$  lasts 7–10 days;  $\text{C}_3\text{F}_8$ , 4–6 weeks; though  $\text{C}_3\text{F}_8$  durations

of more than 70 days have been reported.<sup>3</sup>  $\text{C}_3\text{F}_8$ , with its longer duration in the eye, has been shown to be superior to  $\text{SF}_6$  in the management of complicated retinal detachments in which longer tamponade periods are required.<sup>4</sup> Silicone oil is an alternate intraocular tamponade agent that avoids intraocular gas-related problems, while providing long-term tamponade protection. However, it introduces its own complications, requires an additional removal procedure, and does not provide tamponade protection sufficiently for its use in conditions such as macular hole.<sup>4,5</sup>

Unlike air,  $\text{SF}_6$  and  $\text{C}_3\text{F}_8$  are expansile gases. During the expansion phase, nitrogen and other blood gases enter the bubble more rapidly than  $\text{SF}_6$  or  $\text{C}_3\text{F}_8$  disappears, which leads to exponential expansion of the bubble.  $\text{SF}_6$  and  $\text{C}_3\text{F}_8$  gases can be mixed with air and used in a nonexpansile (isovolumetric) concentrations or used in an expansile fashion depending on surgical factors and desired effects. One hundred percent  $\text{SF}_6$  expands to twice the injected volume over 24 h, while 100%  $\text{C}_3\text{F}_8$  expands to four times the injected volume over 3–7 days. The expansion phase of  $\text{SF}_6$  and  $\text{C}_3\text{F}_8$  gases is such that IOP is able to normalize faster than the rate of expansion of the gas and, by allowing smaller injection volumes, avoids potential problems of injecting larger volumes of nonexpansile gas (e.g., air) into a closed eye.<sup>1</sup>



### *Effect of Intraocular Gas Injection on Intraocular Pressure*

Injection of 0.3 ml gas (~5% vitreal volume) is enough to increase the IOP to greater than 70 mmHg and close the central retinal artery; though usually IOP decreases to normal pressures within 15 min.<sup>6</sup> Injection of larger volumes or expansile mixes can reach a much higher IOP and take longer before normalization of IOP.<sup>16</sup> There is no precise duration of increased IOP greater than central retinal artery perfusion pressure that will lead to permanent visual loss; however, primate models suggest irreversible damage occurs if retinal artery obstruction is present for approximately 90 min.<sup>7</sup> Clinically, increased IOP is known to close the central retinal artery and this can be visualized during the period of increased IOP. On resolution to normal IOP, however, fundal appearance can vary from normal reperfused vessels to the classic cherry red spot, which may take some hours to develop.<sup>8,9</sup> Ultimately, however, an eye damaged by central retinal artery occlusion (CRAO) will typically show evidence of optic disc pallor, attenuated vessels, and nerve fiber layer loss in the months that follow.<sup>8</sup>

### *Influence of Nitrous Oxide on Intraocular Gas Behavior*

Nitrous oxide is much more soluble than other gases and therefore exerts a potent effect on all intraocular gases. If N<sub>2</sub>O is used when gas is present in a closed eye (e.g., after injection or in the postoperative period), then the volume of intraocular gas increases while N<sub>2</sub>O is being used and only stops expanding once N<sub>2</sub>O is discontinued. A more than threefold volume increase may be seen over 1 h of N<sub>2</sub>O use,<sup>10</sup> which is easily sufficient to close the central retinal artery.

## Discussion

Despite numerous studies of the effect of N<sub>2</sub>O on bubble volume, secondary glaucoma is not commonly reported, though most anesthesiologists recognize that N<sub>2</sub>O is contraindicated if intraocular gas is present or planned to be used in a closed eye.<sup>10-15</sup> Although IOP problems and CRAO are well-recognized complications of intraocular gas use,<sup>6, 16-19</sup> our case series represents the first reported cases of permanent visual loss through the postoperative use of N<sub>2</sub>O-induced general anesthesia in eyes with intraocular gas. Although not excluded in these cases, embolic phenomena (e.g., fat emboli) typically occur as a shower and would likely have additional embolic findings, both in the affected eye and elsewhere.<sup>8</sup> Similarly, other anesthetic factors have been implicated in visual loss, especially hemodynamic, such as hypotension, patient posturing, medications, and blood loss.<sup>20-22</sup> These diseases typically would cause

anterior or posterior ischemic optic neuropathy rather than CRAO.<sup>21</sup> Aside from patient 2, who had intraoperative hypotension, no other factors implicated in visual loss were evident in these cases. Case 2 clearly showed CRAO as the mechanism of visual loss, making the hypotension, though possibly contributory, perhaps less significant than the gas-related mechanism. Although only case 2 showed clear evidence of CRAO, increased IOP in itself is not known to cause anterior or posterior ischemic optic neuropathy. However, anterior or posterior ischemic optic neuropathy can ultimately lead to disc pallor, and thus could not be excluded as causes in cases 1 and 3.<sup>23</sup>

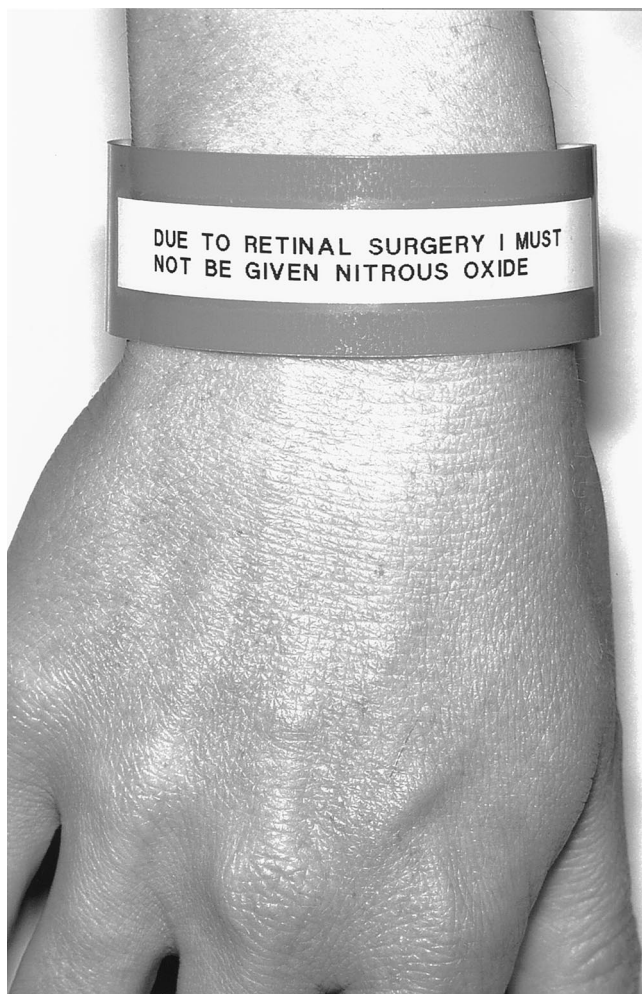
It is important for anesthesiologists to be aware that an intraocular gas bubble can persist in the eye for up to 10 weeks after ocular surgery. Use of highly soluble gases, such as N<sub>2</sub>O, in the presence of intraocular gas can lead to significant visual complications. In the current patients, complications developed associated with N<sub>2</sub>O use 22, 9, and 30 days after eye surgery. This is because N<sub>2</sub>O rapidly enters the gas bubble, inducing an increase in gas volume inside the essentially rigid, closed eye. The rapid and extreme increase in pressure closes the central retinal artery, leading to the observed visual loss. Because the patient is anesthetized at the time this damage is presumably occurring, they do not report pain (as might normally be expected in an awake patient with extreme elevation of IOP). Presumably, IOP rapidly returns to asymptomatic values soon after anesthetic completion, as suggested experimentally.<sup>11</sup>

### *Methods to Reduce Risk of Nitrous Oxide Visual Loss*

**Prevention.** In the ophthalmic setting, communication between surgeon and anesthesiologist usually avoids gas-related complications, though, occasionally, inadvertent N<sub>2</sub>O problems have been detected intraoperatively.<sup>1</sup> Clearly, surgeons have a responsibility to increase patient awareness regarding the risks of further surgery when intraocular gas has been used and to ensure adequate communication between surgeon and anesthesiologist preoperatively. In addition, we propose the use of a simple warning bracelet, for patients to wear in the postoperative period until the gas bubble has dissolved (fig. 1). The importance of such bracelets is even more relevant in the emergency situation when patients may be incapacitated and unable to relay intraocular gas history.

### *Management of Acute Episode if Detected*

If a problem is recognized intraoperatively, then immediate steps should be taken. N<sub>2</sub>O should be ceased immediately; ventilation, commenced with 100% oxygen. One hundred percent oxygen has been shown to lead to faster reversal of bubble expansion than room air alone.<sup>24</sup> In addition, adequate systemic perfusion should



**Fig. 1.** Nitrous oxide warning bracelet placed at the time of intraocular gas injection and removed only after the gas has resorbed.

be ensured. Urgent consultation with an ophthalmologist should be obtained, with ongoing emergency management guided by the ophthalmologist. If ophthalmology consultation is not available and if after 5 min the eye continues to feel hard during palpation (using other eye for comparison), then consideration of pars plana paracentesis should be given to vent excess gas from the eye. Using a short (1/2 in) needle (26–30 gauge), pierce the 1-mm thick sclera of the eye 3.5–4 mm from the limbus (junction between clear cornea and white sclera). The needle should be directed perpendicularly

toward the center of the eye. A few seconds is typically enough to reduce IOP to safe pressures (removal of a precise amount is not essential).

The authors thank Jillian Blakley, R.N., Operating Theatre, Mercy Hospital, Auckland, New Zealand.

## References

1. Whitacre M: Principles and Applications of Intraocular Gas, 1st edition. Edited by Blodi BA, Gottlieb JL. Boston, Butterworth-Heinemann, 1998, pp 3–88
2. Chang S, Lincoff HA, Coleman DJ, Fuchs W, Farber ME: Perfluorocarbon gases in vitreous surgery. *Ophthalmology* 1985; 92:651–6
3. Lincoff H, Coleman J, Kreissig I, Richard G, Chang S, Wilcox LM: The perfluorocarbon gases in the treatment of retinal detachment. *Ophthalmology* 1983; 90:546–51
4. Abrams GW, Azen SP, McCuen BW, 2nd, Flynn HW, Jr, Lai MY, Ryan SJ: Vitrectomy with silicone oil or long-acting gas in eyes with severe proliferative vitreoretinopathy: Results of additional and long-term follow-up. Silicone Study report 11. *Arch Ophthalmol* 1997; 115:335–44
5. Han L, Cairns JD, Campbell WG, McCombe MF, Heriot WJ, Heinze JB: Use of silicone oil in the treatment of complicated retinal detachment: Results from 1981 to 1994. *Aust N Z J Ophthalmol* 1998; 26:299–304
6. Abe T, Nakajima A, Nakamura H, Ishikawa M, Sakuragi S: Intraocular pressure during pneumatic retinopexy. *Ophthalmic Surg Lasers* 1998; 29:391–6
7. Hayreh SS, Kolder HE: Central retinal artery occlusion and retinal tolerance time. *Ophthalmology* 1980; 87:75–8
8. Brown G: Retinal Arterial Obstruction: Focal Points 1994; XII:1–11
9. Malinowski SM, Pesin SR: Visual field loss caused by retinal vascular occlusion after vitrectomy surgery. *Am J Ophthalmol* 1997; 123:707–8
10. Stinson TW III, Donlan JV Jr: Interaction of intraocular air and sulfur hexafluoride with nitrous oxide: A computer simulation. *ANESTHESIOLOGY* 1982; 56:385–8
11. Smith RB, Carl B, Linn JG, Nemoto E: Effect of nitrous oxide on air in vitreous. *Am J Ophthalmol* 1974; 78:314–7
12. Briggs M, Wong D, Groenewald C, McGalliard J, Kelly J, Harper J: The effect of anaesthesia on the intraocular volume of the C3F8 gas bubble: I. Eye 1997; 11:47–52
13. Mostafa S, Wong S, Snowden S, Ansons A, Kelly J, McGalliard J: Nitrous oxide and internal tamponade during vitrectomy. *Br J Ophthalmol* 1991; 75:726–8
14. Wolf GL, Capuano C, Hartung J: Effect of nitrous oxide on gas bubble volume in the anterior chamber. *Arch Ophthalmol* 1985; 103:418–9
15. Wolf GL, Capuano C, Hartung J: Effect of nitrous oxide on gas bubble volume (letter). *Arch Ophthalmol* 1985; 103:1274
16. Chen PP, Thompson JT: Risk factors for elevated intraocular pressure after the use of intraocular gases in vitreoretinal surgery. *Ophthalmic Surg Lasers* 1997; 28:37–42
17. Sabates WI, Abrams GW, Swanson DE, Norton EW: The use of intraocular gases. The results of sulfur hexafluoride gas in retinal detachment surgery. *Ophthalmology* 1981; 88:447–54
18. Sabates NR, Tolentino FI, Arroyo M, Freeman HM: The complications of perfluoropropane gas use in complex retinal detachments. *Retina* 1996; 16:7–12
19. Abrams GW, Sabates WI, Goldman I: The results of sulphur hexafluoride gas in vitreous surgery. *Am J Ophthalmol* 1982; 94:165–71
20. Remigio D, Wertenbaker C: Post-operative bilateral vision loss. *Surv Ophthalmol* 2000; 44:426–32
21. Williams EL, Hart WM Jr, Tempelhoff R: Postoperative ischemic optic neuropathy. *Anesth Analg* 1995; 80:1018–29
22. Jampol LM, Goldbaum M, Rosenberg M, Bahr R: Ischemia of ciliary arterial circulation from ocular compression. *Arch Ophthalmol* 1975; 93:1311–7
23. Hayreh SS: Posterior ischaemic optic neuropathy. *Ophthalmologica* 1981; 182:29–41
24. Hyldegaard O, Madsen J: Effect of air, heliox, and oxygen breathing on air bubbles in aqueous tissues in the rat. *Undersea Hyperb Med* 1994; 21:413–24

## Permanent Postoperative Vision Loss Associated with Expansion of Intraocular Gas in the Presence of a Nitrous Oxide-Containing Anesthetic

Robin R. Seaberg, M.D.,\* William R. Freeman, M.D.,† Michael H. Goldbaum, M.D.,† Gerard R. Manecke, Jr., M.D.‡

INJECTION of an inert gas into the vitreous of the eye is commonly performed as a treatment for retinal detachment, either as an office procedure (pneumatic retinopexy) or as part of a surgical repair.<sup>1,2</sup> Nitrous oxide ( $N_2O$ ) has the potential to diffuse into closed gas-containing spaces, resulting in dramatic increases in pressure and/or volume. We report two cases of permanent postoperative blindness resulting from expansion of an intraocular gas bubble during administration of an  $N_2O$ -containing anesthetic.

### Case Report

#### Case 1

A 37-yr-old man underwent a femoral-to-distal bypass graft of the left leg for a gangrenous left toe. Medical history included type 1 diabetes mellitus, hypertension, peripheral vascular disease, and end-stage renal disease. He had poor vision in both eyes, resulting from proliferative diabetic retinopathy and vitreous hemorrhage, and he had previously undergone laser treatment of both eyes, as well as two vitrectomies of the left eye (OS) and one vitrectomy of the right eye (OD), without placement of a gas bubble. Six weeks before vascular surgery, a limited superior retinal detachment developed in the patient and he underwent an office procedure in which perfluoropropane gas was exchanged for the fluid in the vitreous cavity OD, followed by laser treatment to the causative retinal tear. The patient had "hand motion" vision through the gas bubble, and an intraocular pressure (IOP) of 17 mmHg (normal, 8–22 mmHg) 2 weeks after placement. The gas bubble occupied approximately 60% of the vitreous volume and the retina was attached. During the preoperative evaluation, the anesthesiologist became aware of the patient's surgery history, but not the office visit or the gas placement. The vascular procedure was performed during general anesthesia with the patient in the supine position. Anesthesia was induced with propofol and maintained with 60%  $N_2O$  in oxygen, isoflurane, and opioid. There were no periods of hypoxia or hypotension. The procedure lasted approximately 5 h. The patient had no complaints while awakening from anesthesia. Later that night, he reported tearing and loss of vision OD. An ophthalmology consultation was obtained. Fundoscopic examination revealed a pale, opaque retina with extreme narrowing of the arteries, an appearance

typical of central retinal artery occlusion. There has been no recovery of light perception OD. Vision in OS is 20/50.

#### Case 2

A 19-yr-old woman underwent cadaveric pancreas and kidney transplantation. Medical history was significant for type 1 diabetes mellitus with retinopathy, hypertension, and hemodialysis-dependent end-stage renal disease. She underwent left eye surgery to treat proliferative diabetic retinopathy and a retinal tear at another institution 25 days prior to the transplant. No information about this procedure was available at the time of the transplantation surgery. Visual acuity was "hand motion" OS and "finger count" OD. She underwent the transplantation surgery during general anesthesia while in the supine position. Propofol was given for induction and anesthesia was maintained with isoflurane,  $N_2O$  60% in oxygen, and fentanyl. Total surgery time was 5 h. Systolic blood pressure was maintained around 140 mmHg throughout the procedure. Postoperatively, on the day of surgery, the patient reported pain OS. As she became more alert she noted no light perception OS. The ophthalmology service was consulted. The IOP OS was measured at 40 mmHg and the vitreous cavity was described as 100% filled with gas. The diagnosis of arterial occlusion to the retina resulting in loss of light perception was made. On postoperative day 1, IOP OS was 12 mmHg with 70% gas fill and the retina was gray. By postoperative day 4, the IOP OS was 5 mmHg and the vitreous cavity was 45% filled with gas. The optic nerve was erythematous and the retina was white. Discussion with the surgeon who performed the eye surgery revealed that sulfur hexafluoride gas had been injected into the vitreous cavity. Four months after the transplantation operation, visual acuity was "no light perception" OS and 20/400 OD. The patient continues to have progressive proliferative diabetic retinopathy in the remaining functional (right) eye.

### Discussion

The use of intraocular gas for the repair of retinal detachment has become common.<sup>1,2</sup> Inert gases, such as perfluoropropane ( $C_3F_8$ ) or sulfur hexafluoride ( $SF_6$ ), are mixed with air typically at concentrations that are non-expansile and used to replace the fluid in the vitreous cavity to provide intravitreal tamponade. In addition to their use in the operating room, smaller amounts of expansile concentrations of gas (*i.e.*, 100% perfluoropropane) are introduced to repair simple retinal detachments in the clinic setting. Diffusion of  $N_2O$  into intraocular gas or air has been demonstrated to dramatically increase IOP within 15–24 min of administration.<sup>3–5</sup> Therefore, it is commonly avoided during retina surgery involving the placement of an intraocular gas bubble.

The loss of vision in both of these cases is believed to be the result of sustained high IOP from the expanding gas bubble, causing occlusion of the blood supply to the retina

\* Assistant Clinical Professor of Anesthesiology, Department of Anesthesiology. † Professor of Ophthalmology, Department of Ophthalmology. ‡ Clinical Professor of Anesthesiology, Department of Anesthesiology.

Received from the Departments of Anesthesiology and Ophthalmology, University of California, San Diego, California. Submitted for publication July 8, 2002. Accepted for publication July 18, 2002. Supported by institutional and/or department resources (solely for R.R.S., M.H.G., and G.R.M.). Additional support for W.R.F. from Research to Prevent Blindness, Inc., Rockville, Maryland.

Address correspondence and reprint requests to Dr. Seaberg: Department of Anesthesiology, UCSD Medical Center, 200 West Arbor Drive, San Diego, California 92103-8770. Address electronic mail to: rseaberg@ucsd.edu. Individual article reprints may be purchased through the Journal Web site, [www.anesthesiology.org](http://www.anesthesiology.org).



and optic nerve. Irreversible retinal damage has been shown after occlusion of the central retinal artery in numerous experimental models.<sup>6-8</sup> Interruption of the retinal blood supply typically occurs when the IOP exceeds the systolic pressure in the retinal arterial vessels.<sup>9,10</sup> The pressure in these vessels varies and is lower in patients with diabetes, older patients, and patients with atherosclerosis.<sup>11-15</sup> The presence of type 1 diabetes mellitus and peripheral vascular disease probably placed these patients at a higher risk for this complication.

With the growing popularity of vitreous surgery and pneumatic retinopathy, these slowly reabsorbing gases reside in the vitreous cavity of many individuals. This underscores the need for careful history taking and a high index of suspicion in a patient with a history of retinal detachment or other medical condition (e.g., diabetic retinopathy) that may have involved eye procedures. Even when the history of gas bubble placement is known, reabsorption time is not uniform or always predictable. Indeed, current published guidelines recommend avoidance of N<sub>2</sub>O for 10 days after sulfur hexafluoride injection,<sup>5</sup> but the patient in case 2 experienced this complication 25 days after injection. Published reports show that perfluoropropane gas has a dwell time of 28 days,<sup>16</sup> yet in patient 1 it occurred 41 days after injection. The gas bubble cannot be detected during physical examination, as it is not visible to the naked eye or with direct ophthalmoscopy. The presence of an intraocular bubble can only be reliably detected by indirect ophthalmoscopy.

For these reasons, we suggested to the manufacturers and distributors of these gases that a warning system be implemented. As a result of these discussions, Scott Specialty Gases, Inc. (Philadelphia, PA), the international distributor of medical-grade gases, in cooperation with USA distributors Alcon Laboratories, Inc. (Fort Worth, TX) and Infinites, Inc. (St. Louis, MO), and the US Food and Drug Administration, has begun to provide hospital band-type warning bracelets to all facilities using these

gases. The bracelets are placed on each patient who receives intraocular gas injection to alert other health professionals to the presence of the bubble and the need to avoid N<sub>2</sub>O administration. The bracelet is left on until the gas bubble reabsorbs. Also, we have added a "bubble in eye?" check box to our anesthesia preoperative evaluation forms as a reminder to seek this information before formulating the anesthetic plan for a patient.

Understanding the risk, as well as vigilance in history taking, will be necessary to avoid this devastating complication.

## References

1. Benson WE, Chan P, Sharma S, Snyder WB, Bloome MA, Birch DG: Current popularity of pneumatic retinopathy. *Retina* 1999; 19:238-41
2. Ai E, Gardner TW: Current patterns of intraocular gas use in North America. *Arch Ophthalmol* 1993; 111:331-2
3. Smith RB, Carl B, Linn JG Jr, Nemoto E: Effect of nitrous oxide on air in vitreous. *Am J Ophthalmol* 1974; 78:314-7
4. Stinson TW III, Donlon JV Jr: Interaction of intraocular air and sulfur hexafluoride with nitrous oxide, a computer simulation. *ANESTHESIOLOGY* 1982; 56:385-8
5. Wolf GL, Capuano C, Hartung J: Nitrous oxide increases intraocular pressure after intravitreal sulfur hexafluoride injection. *ANESTHESIOLOGY* 1983; 59:547-8
6. Hayreh SS, Kolder HE, Weingeist TA: Central retinal artery occlusion and retinal tolerance time. *Ophthalmology* 1980; 87:75-8
7. Hayreh SS, Jonas JB: Optic disk and retinal nerve fiber layer damage after transient central retinal artery occlusion: An experimental study in rhesus monkeys. *Am J Ophthalmol* 2000; 129:786-95
8. Zhu Y, Ohlemiller KK, McMahan BK, Gidday JM: Mouse models of retinal ischemic tolerance. *Invest Ophthalmol Vis Sci* 2002; 43:1903-11
9. Attariwala R, Giebs CP, Glucksberg MR: The influence of elevated intraocular pressure on vascular pressures in the cat retina. *Invest Ophthalmol Vis Sci* 1994; 35:1019-25
10. Kiel JW, van Heuven WA: Ocular perfusion pressure and choroidal blood flow in the rabbit. *Invest Ophthalmol Vis Sci* 1995; 36:579-85
11. Dallinger S, Findl O, Strenn K, Eichler HG, Wolzt M, Schmetterer L: Age dependence of choroidal blood flow. *J Am Geriatr Soc* 1998; 46:484-7
12. Langham ME, Grebe R, Hopkins S, Marcus S, Sebag M: Choroidal blood flow in diabetic retinopathy. *Exp Eye Res* 1991; 52:167-73
13. Groh MJ, Michelson G, Langhans MJ, Harazny J: Influence of age on retinal and optic nerve head blood circulation. *Ophthalmology* 1996; 103:529-34
14. Recchia FM, Brown GC: Systemic disorders associated with retinal vascular occlusion. *Curr Opin Ophthalmol* 2000; 11:462-7
15. Hayreh SS: Retinal and optic nerve head ischemic disorders and atherosclerosis: role of serotonin. *Prog Retin Eye Res* 1999; 18:191-221
16. Lincoff H, Mardirossian J, Lincoff A, Liggett P, Iwamoto T, Jakobiec F: Intravitreal longevity of three perfluorocarbon gases. *Arch Ophthalmol* 1980; 98:1610-11



## Cardiopulmonary Bypass following Severe Transfusion-related Acute Lung Injury

Harish S. Lecamwasam, M.D.,\* David Katz, M.D.,† Gus J. Vlahakes, M.D.,‡ Walter Dzik, M.D.,‡  
Scott C. Streckenbach, M.D.,§

TRANSFUSION-RELATED acute lung injury (TRALI) can cause profound hypoxemia abruptly after the administration of blood products. It classically occurs within 1 to 2 h of a transfusion.<sup>1</sup>

Transfusion-related acute lung injury occurs in 1:2,500 patients receiving a transfusion during anesthesia and is fatal in 5% of cases.<sup>2,3</sup> TRALI has occurred following surgical procedures requiring cardiopulmonary bypass (CPB).<sup>4-6</sup> However, there has been no description of a patient undergoing CPB immediately following the onset of TRALI. In this report, we describe a patient who, despite development of severe TRALI during the prebypass period, underwent redo-coronary revascularization and mitral valve replacement and proceeded to complete recovery.

### Case Report

A 66-yr-old man came to the operating room for redocoronary artery bypass grafting and mitral valve replacement. He had undergone coronary bypass grafting and mitral valve repair 14 yr previously. His medications included warfarin, which was discontinued 5 days prior to surgery. Preoperative laboratory values were normal except for a mildly increased prothrombin time of 14.8 s. A chest radiograph showed cardiomegaly and clear lungs. An electrocardiogram showed atrial fibrillation with a ventricular rate of 82 beats/min. Cardiac catheterization revealed native coronary disease, moderate mitral regurgitation, and a left ventricular ejection fraction of 30%.

Anesthesia was induced with midazolam, fentanyl, and pancuronium. The airway was secured without difficulty. The lungs were ventilated with 100% oxygen and a tidal volume of 600 ml with peak inspiratory pressures (PIP) of 18–20 cm H<sub>2</sub>O. Postintubation arterial blood gas assessment showed a Pao<sub>2</sub> of 427 mmHg, a Paco<sub>2</sub> of 38 mmHg, and a pH of 7.41. Blood pressure was 140/64 mmHg, heart rate was 64 beats/min (atrial fibrillation), pulmonary artery pressure was 40/20 mmHg (mean, 25 mmHg), central venous pressure was 8 mmHg, and thermodilution cardiac output was 3.2 l/min.

During mediastinal dissection, the surgical team encountered excessive bleeding. In view of the incompletely reversed warfarin, two units of fresh frozen plasma (FFP) were administered. Approximately 45 min later, the patient's respiratory status began to deteriorate. Pulse oximeter saturation (SpO<sub>2</sub>) decreased to the low 90s, and PIP increased.

Auscultation, inspection of the surgical field, and bronchoscopy did not define a cause. Within 10 min, as PIP continued to increase and the SpO<sub>2</sub> continued to decrease, yellow fluid filled the endotracheal tube and persisted despite aggressive suctioning. Arterial blood gas assessment at this point showed a Pao<sub>2</sub> of 41 mmHg, a Paco<sub>2</sub> of 61 mmHg, and a pH of 7.19 on 100% oxygen. Concurrently, the patient's blood pressure decreased to 90/50 mmHg without a significant change in the central venous or pulmonary artery pressures. There was no electrocardiographic or echocardiographic evidence of myocardial ischemia, and the degree of mitral insufficiency was unchanged. Crystalloid and norepinephrine were used to support the patient's blood pressure; ranitidine, diphenhydramine, and hydrocortisone were given for a possible allergic reaction. Donor and patient blood samples were collected for a transfusion reaction-TRALI work up.

Given worsening hypoxemia and ongoing hemodynamic instability, the surgeons rapidly instituted CPB. As expected, oxygenation immediately improved. The first Pao<sub>2</sub> during CPB (100% oxygen) was 451 mmHg. After single-vessel coronary artery bypass graft and mitral valve replacement, the first attempt to wean the patient from CPB failed because of hypotension, hypoxemia and, eventually, left ventricular failure. An intraaortic balloon was inserted, and a second attempt at weaning from CPB was successful, with 1:1 balloon counterpulsation and increased inotropic and vasopressor support. At weaning, the patient's mean arterial pressure was 90 mmHg, mean pulmonary artery pressure was 26 mmHg, central venous pressure was 8 mmHg, and cardiac output was 3.2 l/min. Hypoxemia, however, persisted with post-CPB Pao<sub>2</sub> values of 30–50 mmHg. Prostaglandin E<sub>1</sub> and inhaled nitric oxide, up to 80 ppm, were given sequentially without apparent benefit. After hemostasis was achieved, the patient was transferred to the intensive care unit with an open sternum due to edematous lungs.

Chest radiography performed at admission to the intensive care unit showed diffuse bilateral air space disease. Arterial blood gas assessment on 100% oxygen showed a Pao<sub>2</sub> of 35 mmHg, a Paco<sub>2</sub> of 36 mmHg, and a pH of 7.39. As part of a TRALI work up, the patient was typed for human leukocyte antigen (HLA), and the donor plasma was tested for antibodies to HLAs. Plasma from one donor was found to contain antibodies against HLA B<sub>44</sub>, an antigen that was present in the patient. A positive lymphocytotoxicity assay result confirmed incompatibility between the donor plasma and the patient lymphocytes.

On postoperative day 3, patient respiratory function improved enough (Pao<sub>2</sub>: 106 mmHg, Paco<sub>2</sub>: 38 mmHg, and pH: 7.49 on 60% oxygen) to permit sternal closure. The intraaortic balloon pump was removed on postoperative day 4. The patient was extubated on day 12 and discharged home on day 16 following full recovery.

### Discussion

Transfusion-related lung injury is characterized by non-cardiogenic pulmonary edema following plasma-containing blood product transfusion. The characteristic chest radiograph shows diffuse, bilateral air space disease. TRALI is frequently associated with hypotension.<sup>1,2,5</sup> Hypotension typically occurs in conjunction with a decrease in left ventricular filling pressure and cardiac output.

\* Chief Resident, Fellow in Cardiac Anesthesia. † Resident. ‡ Associate Professor. § Instructor.

Received from the Department of Anesthesia and Critical Care, Division of Cardiac Surgery, and the Blood Transfusion Service, Massachusetts General Hospital and Harvard Medical School, Boston, Massachusetts. Submitted for publication February 14, 2002. Accepted for publication May 30, 2002. Support was provided solely from institutional and/or departmental sources.

Address reprint requests to Dr. Streckenbach: Department of Anesthesia and Critical Care, Massachusetts General Hospital, 55 Fruit Street, Boston, Massachusetts 02114. Address electronic mail to: sstreckenbach@partners.org. Individual article reprints may be purchased through the Journal Web site, www.anesthesiology.org.

It is thought that the majority of TRALI episodes result from reactions of donor leukocyte agglutinating antibodies (anti-HLA class I, anti-HLA class II, and antigranulocyte) with recipient leukocytes and endothelial cells.<sup>7</sup> Antibody-coated leukocytes are believed to adhere to activated pulmonary endothelium, which leads to increased capillary permeability and pulmonary edema. TRALI is typically associated with whole blood, fresh frozen plasma, and platelets, because these blood products contain large volumes of antibody-rich plasma. TRALI is also more frequently associated with blood from multiparous women because pregnancy is associated with sensitization to non-self-HLA antigens.<sup>2,8</sup> There is substantial clinical and laboratory evidence supporting the diagnosis of TRALI in the current patient. First, pulmonary edema and hypoxia occurred in the patient within 1 h of receiving fresh frozen plasma. Second, no other precipitant of pulmonary edema was identified. Finally, the plasma from one of the donors (who was multiparous) contained anti-HLA B<sub>44</sub> antibodies that cross-reacted with the patient's lymphocytes.

The treatment of TRALI is primarily supportive. In a case series of 36 patients, all required supplemental oxygen for a mean of 40 h, while 72% required mechanical ventilation.<sup>1</sup> As would be expected with noncardiogenic pulmonary edema, patients with TRALI respond poorly to diuretic therapy. In fact, fatalities associated with TRALI have been primarily attributed to hemodynamic collapse in the setting of hypovolemia rather than to respiratory failure.<sup>5</sup> Indeed, the available data suggest that patients with TRALI who are hypotensive with a diminished cardiac output respond favorably to crystalloid or colloid infusions.<sup>5,9,10</sup> Despite the paucity of data regarding the use of inhaled nitric oxide and prostaglandin E<sub>1</sub> in the treatment of TRALI, we attempted a trial of these agents, which may have some benefit in adult respiratory distress syndrome. We were unable to document any benefit in this patient.

Given that CPB alone can be associated with systemic inflammation and pulmonary dysfunction,<sup>11,12</sup> it could be argued that a patient with evolving TRALI should not undergo CPB. However, in this case, given the severity of the hypoxemia, coupled with the patient's uncorrected coronary artery and mitral valvular disease, undergoing bypass seemed prudent. We hoped that extracorporeal support using CPB might provide a window within which the TRALI-mediated inflammatory cascade might subside. This notion is supported by Yokota *et al.*<sup>13</sup> who recently used venoarterial extracorporeal life

support to manage the acute phase of TRALI that occurred following repair of a type A aortic dissection. Worsley *et al.*<sup>14</sup> have similarly used extracorporeal membrane oxygenation to support a patient with TRALI that occurred following coronary artery bypass grafting.

In summary, we report a patient who survived CPB despite the onset of severe TRALI in the prebypass period. The case highlights the clinical and current laboratory diagnosis of TRALI. Since anesthesiologists administer plasma-containing blood products routinely, it is paramount that we remain familiar with the diagnosis and management of this condition. Such familiarity is especially important since pulmonary dysfunction (with TRALI as its worst manifestation) might be a grossly underreported and underrecognized complication of transfusion and since TRALI is the second most common cause of transfusion-related death.<sup>15</sup>

## References

1. Popovsky MA, Moore SB: Diagnostic and pathogenetic considerations in transfusion-related acute lung injury. *Transfusion* 1985; 25:573-7
2. Popovsky MA, Chaplin HC, Moore SB: Transfusion-related acute lung injury: A neglected serious complication of hemotherapy. *Transfusion* 1992; 32:589-92
3. Ausley MB Jr: Fatal transfusion reactions caused by donor antibodies to recipient leukocytes. *Am J Forensic Med Pathol* 1987; 8:287-90
4. Culliford AT, Thomas S, Spencer FC: Fulminating noncardiogenic pulmonary edema: A newly recognized hazard during cardiac operations. *J Thorac Cardiovasc Surg* 1980; 80:868-75
5. Hashim SW, Kay HR, Hammond GL, Kopf GS, Geha AS: Noncardiogenic pulmonary edema after cardiopulmonary bypass: An anaphylactic reaction to fresh frozen plasma. *Am J Surg* 1984; 147:560-4
6. Latson TW, Kickler TS, Baumgartner WA: Pulmonary hypertension and noncardiogenic pulmonary edema following cardiopulmonary bypass associated with an antigranulocyte antibody. *ANESTHESIOLOGY* 1986; 64:106-11
7. Kopko PM, Holland PV: Transfusion-related acute lung injury. *Br J Haematol* 1999; 105:322-9
8. Palfi, M Berg S, Ernerudh J, Berlin G: A randomized controlled trial of transfusion-related acute lung injury: Is plasma from multiparous donors dangerous? *Transfusion* 2001; 41:317-22
9. Levy GJ, Shabot MM, Hart ME, Mya WW, Goldfinger D: Transfusion-associated noncardiogenic pulmonary edema. Report of a case and a warning regarding treatment. *Transfusion* 1986; 26:278-81
10. Fitzgerald J, Chatwani A, Oyer R: Noncardiogenic pulmonary edema as a rare complication of blood transfusions: A case report. *J Reprod Med* 1988; 33:243-5
11. Kotani N, Hashimoto H, Sessler DI, Muraoka M, Wang JS, O'Connor MF, Matsuki A: Neutrophil number and interleukin-8 and elastase concentrations in bronchoalveolar lavage fluid correlate with decreased arterial oxygenation after cardiopulmonary bypass. *Anesth Analg* 2000; 90:1046-51
12. Hensel M, Volk T, Docke WD, Kern F, Tschirna D, Egerer K, Konert W, Kox WJ: Hyperprocalcitonemia in patients with noninfectious SIRS and pulmonary dysfunction associated with cardiopulmonary bypass. *ANESTHESIOLOGY* 1998; 89:93-104
13. Yokota K, Fujii T, Kimura K, Toriumi T, Sari A: Life-threatening hypoxemic respiratory failure after repair of acute type a aortic dissection: Successful treatment with venoarterial extracorporeal life support using a prosthetic graft attached to the right axillary artery. *Anesth Analg*, 2001; 92:872-6
14. Worsley MH, Sinclair CJ, Campanella C, Kilpatrick DC, Yap PL: Noncardiogenic pulmonary oedema after transfusion with granulocyte antibody containing blood: Treatment with extracorporeal membrane oxygenation. *Br J Anesth* 1991; 67:116-9
15. Szama K: Reports of 355 transfusion-associated deaths: 1976 through 1985. *Transfusion* 1990; 30:583-90

## Successful Management of Severe Life-threatening Hypoxemia Due to Pulmonary Arteriovenous Malformation

Anna Hofer, M.D.,\* Michael Pusch, M.D.,\* Bettina Haizinger, M.D.,\* Rudolf Mair, M.D.,†  
Roland Gitter, M.D.,‡ Hans Gombotz, M.D.§

AFTER cavopulmonary anastomosis, pulmonary arteriovenous malformations (PAVMs) may develop in nearly all pre-Fontan patients, but only about 20% are clinically important.<sup>1</sup> They are thought to be the persistence of arteriovenous communications of the fetal and neonatal pulmonary circulation. It is speculated that the lack of hepatic venous blood flowing through the lungs and, hence, the absence of some stimulating or suppressive factor, may contribute to this condition.<sup>2</sup> The PAVMs may lead to progressive desaturation (>5%) in the years after undergoing Glenn anastomosis. However, normal arterial oxygenation does not exclude the presence of persisting PAVMs.<sup>1</sup> The diagnosis is made by the detection of a rapid appearance of contrast dye in the pulmonary veins after injection into the pulmonary arteries or by contrast echocardiography.

This is a report of successful administration of nitric oxide (NO) in a patient after Fontan repair with severe life-threatening hypoxemia due to preoperatively undetected PAVMs, thus avoiding extracorporeal membrane oxygenation (ECMO) support.

### Case Report

A 4-yr-old boy (body weight, 13 kg; height, 103 cm) was scheduled for a fenestrated extracardiac Fontan procedure. In the neonatal period, he had undergone a Damus-Kaye-Stansel operation with right-sided Blalock-Taussig (BT) shunt and coarctation repair because of a single ventricle with a subaortic chamber, restrictive bulboventricular foramen, transposition of the great arteries, hypoplastic aorta, and coarctation of the aorta. At age 8 months, the boy underwent bidirectional Glenn anastomosis. The preoperative angiogram revealed an unobstructed flow through the Glenn anastomosis and the pulmonary vascular tree, as well as a mean pulmonary pressure of 13 mmHg. The superior vena cava pressure was 14 mmHg, oxygen saturation 65%. Selective catheterization of the pulmonary veins was not performed. Arterial oxygen saturation (Sao<sub>2</sub>) in room air was 75%, blood pressure was 110/55 mmHg, and heart rate was 100 beats/min.

Anesthesia was induced and maintained as a total intravenous anesthetic with midazolam (total dosage, 13 mg) and sufentanil (375 µg); muscle relaxation was performed with pancuronium (5 mg). Prebypass

Sao<sub>2</sub> was 80% with an Fio<sub>2</sub> of 0.5, central venous pressure (femoral vein) 10 mmHg, arterial blood pressure 100/50 mmHg. The operation took 4.5 h and was performed using moderate hypothermic extracorporeal circulation (bypass time, 113 min; esophagus temperature, 32°C). Following anastomosis of the inferior vena cava and pulmonary artery and fenestration of the right atrium, the surgeon inserted a left atrial indwelling catheter and pacing wires. At that time, the child was normothermic (37°C esophagus) and the hematocrit concentration was 32%. We were ready to stop the extracorporeal circulation (ECC) with inotropic support of 5 µg · kg<sup>-1</sup> · min<sup>-1</sup> dopamine, 10 µg · kg<sup>-1</sup> · min<sup>-1</sup> amrinone, and 5 µg · kg<sup>-1</sup> · min<sup>-1</sup> nitroglycerin. However, weaning from ECC failed because of severe hypoxemia (Sao<sub>2</sub> decreased to 30%), whereas hemodynamic parameters remained stable (arterial blood pressure, 120/60 mmHg; central venous pressure, 17 mmHg; left atrial pressure, 10 mmHg; transpulmonary pressure gradient, 7 mmHg). The transpulmonary pressure gradient did not change during the following events. Both lungs could easily be ventilated without signs of increased airway resistance or reduced lung compliance. Blood drawn from the left atrial catheter showed a Pao<sub>2</sub> of 30 mmHg. Since ventilation with 100% oxygen failed to improve oxygenation, the decision to use ECMO was made. While awaiting the equipment, we decided to start NO-inhalation at 25 ppm. The Sao<sub>2</sub> increased to 80–87% and, finally, 4 h after the first attempt, the child could be weaned from ECC without using ECMO.

In the intensive care unit, oxygenation continued to be highly dependent on NO inhalation. Accidental discontinuation resulted in severe hypoxemia (Sao<sub>2</sub> <50%). Selective angiography of the left pulmonary artery performed 3 days later revealed a pulmonary arteriovenous malformation of the left lower lobe (fig. 1). The rapid appearance of contrast dye in the pulmonary veins during the first angiography had been underestimated by the cardiologist. Balloon occlusion of the left lower lobe artery resulted in a marked increase in Sao<sub>2</sub> from 81 to 86% in radial artery blood and from 86 to 92% in left atrial blood. In contrast, occlusion of the fenestration (conduit to right atrium) only resulted in a slight increase of Sao<sub>2</sub> from 81 to 82%. During angiography, the inspired oxygen concentration still was 80% and NO was administered into the breathing circuit at a concentration of 25 ppm. It took 8 days to wean the patient from mechanical ventilation. Thereafter, NO inhalation was continued *via* face mask until the tenth postoperative day. The boy was discharged from the intensive care unit with an Sao<sub>2</sub> between 86 and 92%.

### Discussion

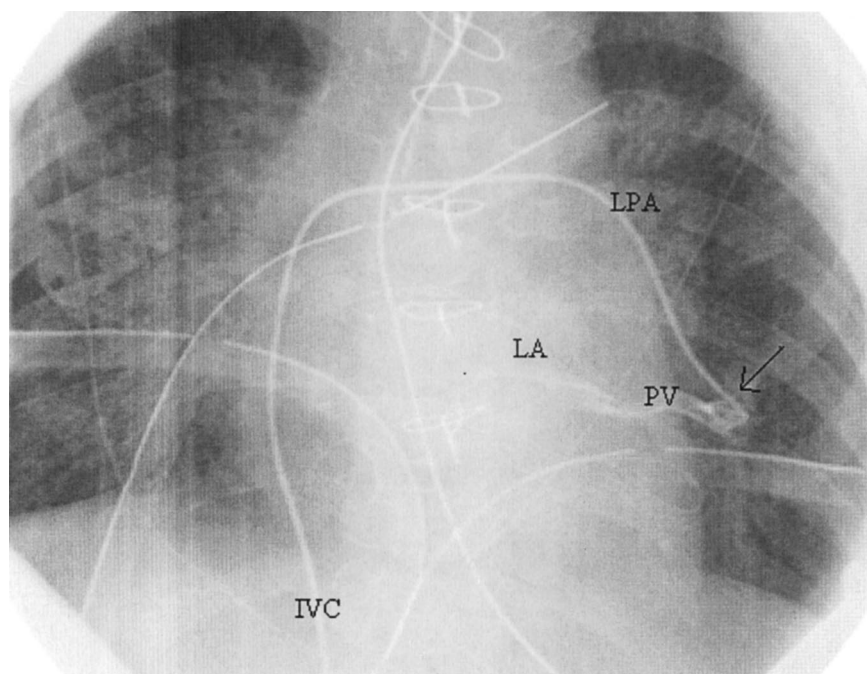
Because of the unpredictable development of PAVMs, there has been concern about the timing of the Fontan procedure in children after bidirectional Glenn anastomosis. PAVMs are likely to occur in the time period between early Glenn operation (in the first 6 months of life) and the final Fontan procedure.<sup>3</sup> As the fenestrated extracardiac Fontan operation<sup>4</sup> is favored by our pediatric surgeon, the children get their “final step” at the age of 4 yr or with a body weight of at least 15 kg.<sup>5</sup> Then, the 20-mm extracardiac conduit can be placed easily by the surgeon. This size of conduit is preferred because it

\* Specialist, Department of Anesthesiology and Intensive Care. † Department of Thoracic and Cardiovascular Surgery. ‡ Department of Pediatric Cardiology. § Professor, Department of Anesthesiology and Intensive Care, General Hospital, Linz

Received from the Department of Anesthesiology and Intensive Care, General Hospital Linz, Linz, Austria. Submitted for publication January 22, 2002. Accepted for publication June 7, 2002. Support was provided solely by institutional and/or departmental sources.

Address reprint requests to Dr. Anna Hofer: AKH Linz, Krankenhausstraße 9, A-4020 Linz, Austria. Address electronic mail to: anna.hofer@akh.linz.at. Individual article reprints may be purchased through the Journal Web site, www.anesthesiology.org.





**Fig. 1.** The catheter has been introduced through the vena cava inferior (IVC) into the left pulmonary artery (LPA) and advanced to the left lower lobe artery. After injection of contrast dye into the artery (arrow), it appeared immediately in a pulmonary vein (PV) running back to the left atrium (LA).

meets the patient's flow requirements later during adulthood, and therefore a reoperation is also unlikely.

Extracorporeal circulation may reduce lung compliance and increase intrapulmonary shunting, interstitial lung water, and pulmonary vascular resistance.<sup>6</sup> In this case, however, a marked decrease of lung compliance or increase in airway pressure could not be observed. In addition, the transpulmonary gradient, as an indicator of a functioning Fontan circulation, was low (7 mmHg) and remained stable even in presence of severe hypoxemia, giving an erroneous impression of low pulmonary vascular resistance. The increased pulmonary resistance after extracorporeal circulation was masked by blood flow being predominantly directed through the PAVMs and bypassing gas exchange.

After reducing pulmonary vascular resistance by NO inhalation, blood flow was redistributed to the normal vascular bed, enabling adequate gas exchange. The shunt flow across the 4-mm fenestration as a possible cause of desaturation was excluded by balloon occlusion during angiography. After balloon occlusion of the fenestration  $\text{Sao}_2$  changed only slightly from 81 to 82%.

Inhaled NO dilates pulmonary blood vessels in ventilated lung areas, thus facilitating gas exchange by improvement of perfusion in ventilated areas. Previous studies have shown that the reduction of pulmonary vascular resistance after cardiopulmonary bypass (CPB) by NO administration is even more prominent than before. Wessel *et al.*<sup>7</sup> showed a twofold stronger decrease of pulmonary vascular resistance after CPB than before CPB. In a randomized trial, Russell *et al.*<sup>8</sup> demonstrated that NO reduces the increased pulmonary artery pres-

sure ( $>50\%$  mean systemic arterial pressure) that developed after pediatric cardiopulmonary bypass.

The ECMO may be an ideal method to restore oxygenation, but it does not reverse the right-to-left shunt across the PAVMs and is associated with significant adverse side effects.<sup>9</sup> Bacha *et al.*<sup>9</sup> describe three patients with PAVMs after bidirectional cavopulmonary anastomosis. In one patient, they used ECMO and balloon occlusion, the second patient died after development of severe coagulopathy, which made balloon occlusion and ECMO impossible, and the third patient was treated with ECMO, but could not be weaned from mechanical support before NO inhalation over 14 days. Balloon occlusion of PAVMs is not always possible because of the diffuse nature of the malformations. In our case, a coil embolization of the malformation was postponed after the oxygenation had improved with NO because of our knowledge that these malformations usually resolve after Fontan procedure. In our patient, the collateral was indeed no longer detectable in angiography performed 3 months later.

The perioperative course of this case demonstrates that inhaled NO may be successful in the treatment of severe hypoxemia due to PAVMs after Fontan repair, and it may even avoid the use of ECMO and its associated adverse side effects, such as hemorrhage, neurologic injury, or infections.

## References

1. Bernstein HS, Brook MM, Silverman NH, Bristow J: Development of pulmonary arteriovenous fistulae in children after cavopulmonary shunt. *Circulation* 1995; 92:II309-14
2. Justino H, Benson LN, Freedom RM: Development of unilateral pulmonary arteriovenous malformations due to unequal distribution of hepatic venous flow. *Circulation* 2001; 103:e39-43

3. Jonas RA: Indications and timing for the bidirectional Glenn shunt versus the fenestrated Fontan circulation. *J Thorac Cardiovasc Surg* 1994; 108:522-4
4. Lemler MS, Scott WA, Leonard SR, Stromberg D, Ramaciotti C: Fenestration improves clinical outcome of the Fontan procedure. *Circulation* 2002; 105: 207-16
5. Petrossian E, Reddy VM, McElhinney DB, Akkersdijk GP, Moore P, Parry AJ, Thompson LD, Hanley FL: Early results of the extracardiac conduit Fontan operation. *J Thorac Cardiovasc Surg* 1999; 117:688-96
6. Gamillscheg A, Zobel G, Urlesberger B, Berger J, Dacar D, Stein JI, Rigler B, Metzler H, Beitzke A: Inhaled nitric oxide in patients with critical pulmonary

perfusion after fontan-type procedures and bidirectional Glenn anastomosis. *J Thorac Cardiovasc Surg* 1997; 113:435-42

7. Wessel DL: Inhaled nitric oxide for the treatment of pulmonary hypertension before and after cardiopulmonary bypass. *Crit Care Med* 1993; 21:S344-5
8. Russell IA, Zwass MS, Fineman JR, Balea M, Rouine-Rapp K, Brook M, Hanley FL, Silverman NH, Cahalan MK: The effects of inhaled nitric oxide on postoperative pulmonary hypertension in infants and children undergoing surgical repair of congenital heart disease. *Anesth Analg* 1998; 87:46-51
9. Bacha EA, Jonas RA, Mayer JE Jr, Perry S, del Nido PJ: Management of pulmonary arteriovenous malformations after surgery for complex congenital heart disease. *J Thorac Cardiovasc Surg* 2000; 119:175-6

Anesthesiology 2002; 97:1315-7

© 2002 American Society of Anesthesiologists, Inc. Lippincott Williams & Wilkins, Inc.

## Hyperinflation Resulting in Hemodynamic Collapse following Living Donor Lobar Transplantation

Steven M. Haddy, M.D.,\* Ross M. Bremner, M.D., Ph.D.,† Earl W. Moore-Jefferies, M.D.,\* Durai Thangathurai, M.D.,‡ Felicia A. Schenkel, R.N.,§ Mark L. Barr, M.D.,|| Vaughn A. Starnes, M.D.#

BILATERAL living lobar transplantation has become an established strategy to deal with the long-term shortage of suitable donor tissue for patients with end-stage lung disease; this technique has been in use at the Keck School of Medicine at the University of Southern California since 1993. We present a case in which the disparity in size between the donated lobes and the recipient's thorax led to life-threatening ventilatory and hemodynamic compromise in the immediate postoperative period.

### Case Report

A 30-yr-old woman was admitted with end-stage cystic fibrosis for scheduled bilateral living lobar transplant. She was oxygen dependent at home and had been hospitalized several times in the preceding weeks for decompensation of her disease.

At the time of admission, arterial blood gas measurements on 2 l/min oxygen were as follows: pH, 7.43; PaCO<sub>2</sub>, 55 mmHg; PaO<sub>2</sub>, 44 mmHg. Forced vital capacity was 47% of the predicted value. The patient's weight was 46 kg and her height was 153 cm. Physical examination was remarkable for an increased S<sub>2</sub>, and examination of the bony thorax showed increased anterior-posterior diameter typical of patients with cystic fibrosis.

Because of the patient's progressive deterioration, the decision was made to proceed with lobar lung transplantation using living donors. The indications for and technique of performing this procedure have been previously described.<sup>1-3</sup> In brief, the lower right lobe is harvested from a healthy donor at the same time that the lower left lobe is harvested from a second donor, and the donated lobes are then implanted into the recipient patient.

The patient was taken to the operating room without premedication. Following venous access and radial artery catheter placement, anesthesia was induced with etomidate and maintained with isoflurane, vecuronium, and fentanyl. A pulmonary artery catheter was placed following induction of anesthesia; the initial blood pressures were 60/30 mmHg with a pulmonary artery occlusion pressure of 20 mmHg. Cardiopulmonary bypass is instituted because the severe pleural adhesions in these patients increase the duration and technical difficulty of performing the native pneumonectomies.

The chest was opened using a bilateral thoracosternotomy or "clam shell" incision. Dynamic hyperinflation was observed and treated by decreasing the inspiratory to expiratory ratio, with use of bronchodilators and vigorous tracheal toilet, and by initiating brief periods of apnea. Permissive hypercapnia (PaCO<sub>2</sub>, 80-90 mmHg) allowed unhurried dissection of the lungs and hilar structures without significant arterial desaturation. Cardiopulmonary bypass was instituted and bilateral pneumonectomies were performed. The lobes were subsequently transplanted as described elsewhere.<sup>1</sup>

Following implantation of the lobes, the patient was weaned from bypass using 5  $\mu\text{g} \cdot \text{kg}^{-1} \cdot \text{min}^{-1}$  of dopamine. The pulmonary artery catheter which had been advanced into the newly implanted lobes showed pressures of 40/20-45/25 mmHg. Protamine, methylprednisolone, and furosemide were also administered. Hemostasis was induced, and the chest was closed. Arterial blood gases on FiO<sub>2</sub> of 0.5 and 5 cm H<sub>2</sub>O positive end expiratory pressure (PEEP) using tidal volumes of 500 ml at 12 breaths/min volume-controlled mechanical ventilation were pH: 7.32; PaCO<sub>2</sub>: 45; and PaO<sub>2</sub>: 375.

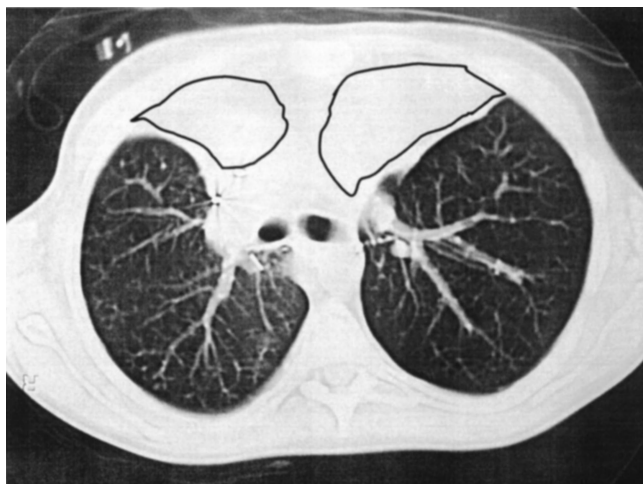
Prior to transport to the cardiac intensive care unit, the thoracostomy tubes were set on -20 cm H<sub>2</sub>O suction. Almost immediately the patient's hemodynamic status deteriorated, with the blood pressure dropping from 100 mmHg systolic to 50-60 mmHg systolic with corresponding decreases in the pulmonary artery pressures. This responded minimally to increased fluid administration and inotropic support, including dopamine, phenylephrine, and epinephrine. Although the chest tubes did not show significant drainage of blood, the surgical team decided to reopen the incision. During the preparation for reexploration of the chest, the thoracostomy tubes were disconnected from the water-seal drainage devices. Almost immediately, the patient's blood pressure returned to its prior value.

After a period of observation, the decision was made not to reopen the chest and the tubes were again connected to suction. Hemodynamic deterioration recurred, and this time the peak inspiratory pressure increased from the mid 30s to 50-60 cm H<sub>2</sub>O. Suspecting some interaction between the negative pleural pressure and the change in hemodynamics, we elected to discontinue suction on the thoracostomy tubes. The nurse disconnected the water-seal pleural drainage canisters from suction, but there was no improvement in the hemo-

\* Assistant Professor, ‡ Professor, Department of Anesthesiology. † Assistant Professor, || Associate Professor, # Professor and Chair, Department of Cardiac Surgery. § Senior Coordinator, Cardiothoracic Transplantation.

Received from the Departments of Anesthesiology and Cardiac Surgery, University of Southern California University Hospital and the Keck School of Medicine, Los Angeles, California. Submitted for publication February 1, 2002. Accepted for publication June 12, 2002. Support was provided solely from institutional and/or department sources.

Address reprint requests to Dr. Steven Haddy: Department of Anesthesiology, University of Southern California University Hospital, Keck School of Medicine, 1500 San Pablo Street, 4th Floor, Los Angeles, California 90033. Address electronic mail to: stevenhaddy@hotmail.com. Individual article reprints may be purchased through the Journal Web site, www.anesthesiology.org.



**Fig. 1.** Computerized tomogram from a lobar recipient several weeks following transplantation. The outlined areas have filled with fluid. In the immediate postoperative setting these spaces are empty and may allow hyperinflation of the implanted lobes, causing the hemodynamic changes described.

dynamic profile. On realizing that the water seal was maintaining a negative intrapleural pressure, we disconnected the chest tubes from the canister to allow pleural pressure to return to atmospheric level. Improvement was immediate, with restoration of blood pressure and a decrease in peak inspiratory pressure. After a period of observation, the patient was transported uneventfully to the intensive care unit, with the chest tubes to water seal at atmospheric pressure.

## Discussion

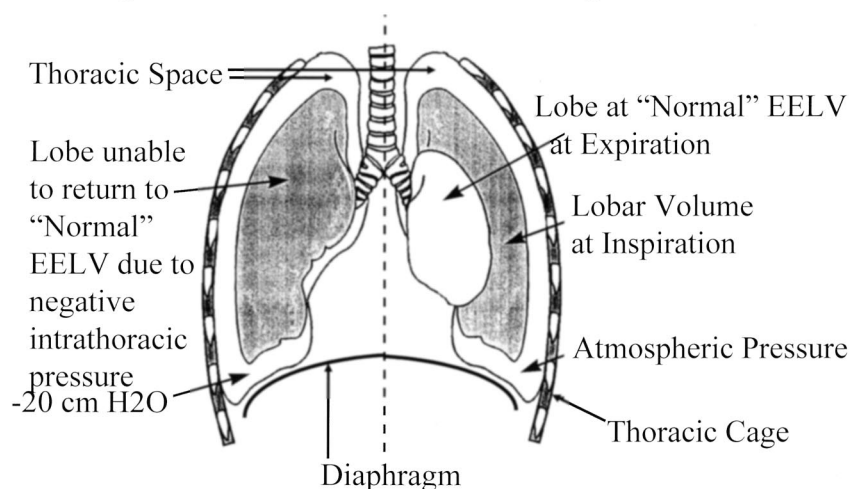
Physicians caring for patients with severe obstructive pulmonary disease are familiar with the phenomenon of dynamic hyperinflation also known as “auto-PEEP,” “intrinsic-PEEP,” or “occult-PEEP.” This is usually defined as an increase of the end-expiratory lung volume greater than the elastic equilibrium volume (volume of relax-

ation).<sup>4,5</sup> The management of this condition in patients with chronic obstructive pulmonary disease has been well described. Dynamic hyperinflation can have profound effects on the hemodynamic status of patients experiencing ventilatory failure.<sup>6</sup> The etiologies of these hemodynamic difficulties include mechanical pressure on the right heart from the hyperinflated lungs, causing decreased venous return, and impedance to right-sided heart ejection caused by distended alveoli compressing the pulmonary microvasculature, leading to right-sided heart failure. The interaction becomes even more complicated when spontaneous (or assisted), rather than controlled, ventilation is used.<sup>7,8</sup>

This patient did not meet the criteria for dynamic hyperinflation. The donor lungs showed no signs of flow limitation and no bronchospasm was evident. The patient’s skeletal muscles were well relaxed after administration of vecuronium, and her lungs underwent mechanical ventilation using conventional rates. In spite of this, hemodynamic changes were similar to those seen in dynamic hyperinflation. We believe that the negative intrapleural pressure, resulting from the suction placed on the chest tubes, created a situation in which the lungs were kept hyperinflated and thus on the flat portion of the compliance curve. Negative intrathoracic pressure, combined with positive intrapulmonary pressure, leads to hyperinflation with decreased venous return and impedance to right-sided heart outflow. This was caused by the size discrepancy between the single pulmonary lobes and the larger hemithoraces into which they were implanted. In subsequent cases, we have observed that these hemodynamic changes are more severe as size discrepancy increases.<sup>9</sup> The size discrepancy may be even greater than predicted on the basis of donor and recipient height, since an increased anterior-posterior diameter develops in cystic fibrosis patients as an adap-

## Abnormal Mechanics in Transplanted Lobe

## Normal Mechanics in Transplanted Lobe



**Fig. 2.** Comparison of the pulmonary mechanics in a hemithorax at atmospheric pressure, with one under negative intrathoracic pressure, following lobar transplantation. Failure of the lungs to empty due to the negative intrathoracic pressure causes hyperinflation and subsequent hemodynamic deterioration.



tive change resulting from long-term lung hyperinflation during the period of rib cage development.<sup>10</sup>

While the hemodynamic and pulmonary mechanical effects of dynamic hyperinflation are similar to those found in our case, the cause is quite different. Return of the lobes to their end expiratory volume was probably limited because the chest tube suction mechanically produced continuous negative end-expiratory pleural pressure. Since the bony thorax is not collapsible, the negative intrapleural pressure is transmitted directly to the transplanted lobe. Physiologically, the negative end-expiratory pleural pressure places the healthy lobes near the maximum flat portion of their pressure-volume relation, even though normal intrinsic elastic recoil may be present. With the lungs held in this inflated configuration, successive breaths rapidly "stack" to produce dangerous levels of inspiratory pressure. Hyperinflation from either excessive positive intrapulmonary pressures (as might be seen with high levels of PEEP) or constant negative intrapleural pressures (as in our patient) has similar hemodynamic effects.

At the University of Southern California, we have chosen to deal with the shortage of donors for our cystic fibrosis patients, in part, by using living donors. Since the first living-donor lobar transplant in 1993, we have performed more than 120 of these procedures. The small stature of these patients makes the use of a single lobe adequate for implantation into a hemithorax; however, there is still usually a residual space as the lobe does not conform completely to the shape of the chest. Figure 1 shows a computerized tomographic scan from one of our recipient lobar transplant patients, several weeks after transplantation, demonstrating the space remaining in the chest after lobe insertion. This ultimately fills with fluid in a similar fashion to that seen after lobectomy or pneumonectomy. The complication described previously, while not unique to lobar transplantation, may be expected to occur more frequently when a significant donor-to-recipient size discrepancy exists. A large size discrepancy would result in a larger potential space into which the lobes may expand to the point of severe hyperinflation when suction is applied to the chest tubes. Figure 2 shows a diagram illustrating the pathophysiology we believe to be operating in these patients. As noted previously, our clinical impression is that the degree of physiologic influence is directly related to the degree of discrepancy between the size of the implanted lobes and that of the recipient's thorax.

This and subsequent cases have provided us with a better understanding of the physiology involved in lobar

transplantation and has led us to modify the postoperative treatment of these patients in the following ways:

1. Chest tubes are placed next to water-seal drain, but no negative pressure is applied for the first several hours postoperatively.
2. PEEP (5–10 cm H<sub>2</sub>O) is applied progressively in the cardiac surgery intensive unit, as tolerated.
3. Negative pressure is applied to the chest tubes (two in each hemithorax) in sequence: 5–10 cm H<sub>2</sub>O to each tube, for 1 h intervals, rotating for the first 24 h. Later, continuous suction is applied to each tube and gradually increased to –20 cm H<sub>2</sub>O over the next 48 h.

Using this procedure on all patients, we have minimized the hemodynamic consequences of the donor-to-recipient size discrepancies inherent in lobar transplantation and have not seen similar acute deterioration in the last 90–100 patients examined.

In summary, we describe a case of hemodynamic deterioration following bilateral living-donor lobar transplantation. The hemodynamic changes are similar to those seen in dynamic hyperinflation.<sup>5</sup> However, the etiology is negative intrapleural pressure rather than positive intrapulmonary pressure. As a result of this experience, we have modified our treatment of these patients to include small but gradually increasing application of negative pressure to the chest tubes.

## References

1. Starnes VA, Barr ML, Cohen RG: Lobar transplantation. Indications, technique, and outcome. *J Thorac Cardiovasc Surg* 1994; 108: 403–10; discussion 410–1
2. Starnes VA, Barr ML, Schenkel FA, Horn MV, Cohen RG, Hagen JA, Wells WJ: Experience with living-donor lobar transplantation for indications other than cystic fibrosis. *J Thorac Cardiovasc Surg* 1997; 114: 917–21; discussion 921–2
3. Barr ML, Schenkel FA, Cohen RG, Chan KM, Marboe CC, Hagen JA, Barbers RG, Starnes VA: Bilateral lobar transplantation utilizing living related donors. *Artif Organs* 1996; 20:1110–1
4. Gibson GJ: Pulmonary hyperinflation a clinical overview. *Eur Respir J* 1996; 9:2640–9
5. Leith DE, Brown R: Human lung volumes and the mechanisms that set them. *Eur Respir J* 1999; 13:468–72
6. Ranieri VM, Dambrosio M, Brienza N: Intrinsic PEEP and cardiopulmonary interaction in patients with COPD and acute ventilatory failure. *Eur Respir J* 1996; 9:1283–92
7. Dambrosio M, Fiore G, Brienza N, Cinnella G, Marucci M, Ranieri VM, Greco M, Brienza A: Right ventricular myocardial function in ARF patients. PEEP as a challenge for the right heart. *Intensive Care Med* 1996; 22:772–80
8. Dambrosio M, Cinnella G, Brienza N, Ranieri VM, Giuliani R, Bruno F, Fiore T, Brienza A: Effects of positive end-expiratory pressure on right ventricular function in COPD patients during acute ventilatory failure. *Intensive Care Med* 1996; 22:923–32
9. Starnes VA, Barr ML, Cohen RG, Hagen JA, Wells WJ, Horn MV, Schenkel FA: Living-donor lobar lung transplantation experience: Intermediate results. *J Thorac Cardiovasc Surg* 1996; 112: 1284–90; discussion 1290–1
10. Guignon I, Cassart M, Gevenois PA, Knoop C, Antoine M, Yernault JC, Estenne M: Persistent hyperinflation after heart-lung transplantation for cystic fibrosis. *Am J Respir Crit Care Med* 1995; 151:534–40