

Current Techniques for Perioperative Lung Isolation in Adults

Javier H. Campos, M.D.*

LUNG isolation techniques are used in thoracic, esophageal, vascular, and nonthoracic surgical settings in the perioperative period. The purpose of this review is to provide an update on the current use of (1) double-lumen tube (DLT) technology (left- and right-sided double-lumen endotracheal tubes) and (2) bronchial blocking technology, including Fogarty occlusion catheters, the Univent[®] bronchial blocker (Vitaaid, Lewiston, NY), and a wire-guided endobronchial blocker (WEB[®]; Cook, Bloomington, IN) to achieve lung isolation.

More than 50 yr ago, Björk and Carlens¹ introduced a practical method of lung isolation to facilitate lung surgery or to prevent contamination of the contralateral lung while maintaining one-lung ventilation (OLV) with a DLT. Today, rubber DLTs continue to be used extensively throughout the world, while in the United States most DLTs are plastic and disposable. Ginsberg² reported the use of a Fogarty catheter as an endobronchial blocker to achieve OLV. Inoue *et al.*³ introduced a new device for OLV, using a single-lumen endotracheal tube with an incorporated bronchial blocker (Univent[®]) so that when OLV is no longer needed the tube can be left *in situ* (*i.e.*, for postoperative mechanical ventilation). Arndt *et al.*⁴ introduced the wire-guided endobronchial blocker (WEB), which consists of a single bronchial blocker that is advanced through a standard single-lumen endotracheal tube. Although these different devices are designed to achieve OLV, there is no randomized trial demonstrating one to be superior over the others during elective thoracic cases.

There are widely accepted indications for lung isolation, including

1. to facilitate surgical exposure in thoracic surgery, thoracoscopy, lobectomy, pneumonectomy, lung transplantation, and cardiac surgery (*i.e.*, in minimally invasive surgery); surgery of the descending thoracic

aorta; esophageal surgery; and other surgical procedures, such as thoracic approach to the spine;

2. surgery on the bronchus to facilitate gas exchange to the other bronchus (*i.e.*, bronchopleural fistula and intraluminal tumors);
3. to facilitate procedures that require lung isolation to prevent contamination to the contralateral lung (*i.e.*, abscess, hemorrhage due to trauma, rupture of the pulmonary artery, or bronchopulmonary lavage);
4. during the use of differential lung ventilation and positive end-expiratory pressure ventilation.

Double-lumen Technology

Double-lumen tubes are the most commonly used tubes for lung isolation.⁵ These are designed to isolate, selectively ventilate, and/or collapse either lung. Mallinckrodt (Argyle, NY) recently reincorporated a bevel in the left-sided Broncho-Cath[®] tube. Perhaps this change was prompted by a perceived difficulty in intubating the left mainstem bronchus with the Broncho-Cath[®] tubes without a bevel at the bronchial tip.⁶ Newer 26-, 28- and 32-French sizes have been introduced by Rüsch, Sheridan, and Mallinckrodt.

A common problem with the left-sided DLT is the lack of objective guidelines to choose a properly sized DLT. In practice, a left-sided DLT that is too small requires a large endobronchial cuff volume, which might increase malposition (herniation). Also, the small DLT does not readily allow fiberoptic bronchoscope placement and can make suction difficult. A properly sized DLT is one in which the main body of the tube passes atraumatically through the glottis and advances easily within the trachea, and in which the bronchial component passes into the intended bronchus without difficulty. There are increasing reports of complications related to the use of an undersized DLT. Sivalingam and Tio⁷ described a tension pneumothorax and pneumomediastinum that occurred after the endobronchial tip of a smaller-than-predicted DLT had migrated too far into the left lower bronchus, and the whole tidal volume was delivered into a single lobe.

Various methods have been proposed for determining proper left-sided DLT size. Brodsky *et al.*⁸ showed that direct measurement of the diameter of the tracheal width at the interclavicular plane from the preoperative posterior-anterior chest radiograph can be used as a

*Professor of Anesthesiology and Director of Cardiothoracic Anesthesiology.

Received from the Department of Anesthesia, College of Medicine, University of Iowa Health Care, Iowa City, Iowa. Submitted for publication September 21, 2001. Accepted for publication June 24, 2002. Support was provided solely from institutional and/or departmental sources.

Address reprint requests to Dr. Campos: Department of Anesthesia, University of Iowa Health Care, 200 Hawkins Drive, Iowa City, Iowa 52242-1079. Address electronic mail to: javier-campos@uiowa.edu.

The illustrations for this section are prepared by Dimitri Karetnikov, 7 Tenyson Drive, Plainsboro, New Jersey 08536.

Table 1. Conversion Measurements of Tracheal Widths Based on Chest Radiograph and Bronchial Diameter Measurements Based on Computed Tomography Scan of the Chest and the Predicted Left-sided Double-lumen Endotracheal Tube Size

| Measured Tracheal Width (mm) | Measured Bronchial Diameter (mm) | Left-sided DLT (French) |
|---------------------------------|-------------------------------------|----------------------------|
| ≥18 | ≥12 | 41 |
| ≥16 | 12 | 39 |
| ≥15 | 11 | 37 |
| ≥14 | 10 | 35 |
| ≥12.5 | <10 | 32 |
| ≥11 | NA | 28 |
| NA | NA | 26 |

DLT = double-lumen tube; NA = not applicable; has not been investigated.
Data from Brodsky et al.,⁸ Hannallah et al.,¹⁰ and Fitzmaurice and Brodsky²⁰

guide to predict which left-sided DLT size to select. However, Chow *et al.*,⁹ using the same method as Brodsky *et al.*,⁸ found it to be less reliable in their patient population, which was comprised mostly of Asians. In the study conducted by Chow *et al.*,⁹ an oversized DLT was placed in the female patients; the overall positive predictive values for male and female patients were 77 and 45%, respectively, in selecting the proper size DLT. This implies that the tracheal width method of determining tube size is of limited utility for populations with smaller stature. A possible alternative is to measure the diameter of the left mainstem bronchus by computed tomography (table 1); however, this method is not practical, as it requires a radiologist experienced in airway sizes.¹⁰ Taken together, these studies suggest that chest radiographs and computed tomography scans are valuable tools for the selection of proper DLT size, in addition to their proven value in the assessment of abnormal tracheobronchial anatomy, and should be reviewed prior to the placement of a DLT.

Placement, Positioning, and Confirmation of the Left-sided Double-lumen Endotracheal Tube

The two most commonly used techniques for placement of a left-sided DLT are the *blind technique*, in which the tube is passed after direct laryngoscopy and then turned 90° counterclockwise to the left and advanced until slight resistance is felt, which usually indicates that the endobronchial lumen of the DLT had entered the bronchus, and the *fiberoptic-directed technique*, which is used after the endobronchial tip of the

DLT has passed the vocal cords. The fiberoptic is passed down the endobronchial lumen, and the tip of the DLT is then guided over the fiberoptic into the left mainstem bronchus.

Boucek *et al.*¹¹ compared the methods for DLT placement, finding that the insertion of a DLT using the blind technique required an average of 88 s, whereas the directed bronchoscope technique required an average of 181 s. Both methods resulted in successful left mainstem bronchus placement in most patients. The recommended OD of the flexible fiberoptic bronchoscope to be used with a 35- to 41-French DLT is 3.5 mm or 4.2 mm. For smaller sized DLTs (*i.e.*, 26–32 French), a bronchoscope with an OD of 2.4 mm must be used.

Auscultation and/or fiberoptic bronchoscopy are the current methods used to confirm DLT placement. Both techniques require the endotracheal and endobronchial cuffs to be fully inflated to provide a good seal. Because the purpose of the endobronchial cuff is to allow ventilation or to protect against contamination, the optimal seal in the endobronchial cuff is airtight, with no leaks when the cuff is inflated with a maximum of 3 ml air. On auscultation and observation, breath sounds should be absent on the left side of the chest during ventilation when the endobronchial lumen adapter is clamped. Following clamping of the endotracheal lumen adapter, breath sounds should be absent from the right side of the chest during ventilation of the (unclamped) bronchial lumen.

Evidence strongly suggests that auscultation alone is unreliable for confirmation of proper DLT placement. When fiberoptic bronchoscopy was used after position-

ing using auscultation alone, 78% of left-sided DLTs and 83% of right-sided DLTs had to be repositioned because of initial malposition.¹² In a second study, involving 200 patients who were intubated using the blind method followed by confirmation with a fiberoptic bronchoscope, the investigators found that more than one third of the DLTs required repositioning by at least 0.5 cm.¹³ The advantages of fiberoptic bronchoscopy are the ability to correct intraoperative malpositions, the ability to determine the margin of safety for a left-sided DLT, the ability to aspirate secretions in the conducting airways, and the use of the suction port to blow oxygen through the fiberoptic bronchoscope to improve visualization of anatomic structures if hemoptysis or pus is present.

It follows, then, that the most accurate method for confirmation of left-sided DLT placement is fiberoptic bronchoscopy. A visual demonstration of fiberoptic bronchoscopy and DLT placement is available on CD-ROM.¹⁴ Broncho-Cath[®] tubes have a radiopaque line encircling the tube. This line is proximal to the bronchial cuff and can be useful while positioning a left-sided DLT. The line is 4 cm from the distal tip of the bronchial lumen. This marker reflects white during fiberoptic visualization and, when positioned slightly above the carina, should provide the necessary margin of safety for positioning into the left mainstem bronchus, along with the view of the blue endobronchial cuff seen 2–5 mm below the tracheal carina on the left bronchus.

The left-sided DLT remains the most suitable device for lung isolation for the majority of elective thoracic procedures because of the ease in placement and versatility that it affords. Benumof *et al.*¹⁵ demonstrated that the left-sided DLT has a greater margin of safety and should be the tube of choice in the majority of cases in which OLV is needed. However, in many instances, if a left-sided DLT cannot be placed, then a right-sided DLT can be the alternative.

Right-sided Double-lumen Endotracheal Tubes

The principal argument against the right-sided DLT is the relative low margin of safety: specifically, a higher incidence of right upper lobe collapse and obstruction.¹⁶ Theoretically, right-sided DLTs will be more likely to dislodge than left-sided DLTs, requiring repositioning. This is, in part, because of the shorter right mainstem bronchus and the earlier origin of the right upper bronchus from below the tracheal bifurcation, which can emerge from a distance of between 1.5 and 2.0 cm in female or male adults, respectively. Also, the occurrence of an anomalous right upper bronchus that emerges above the tracheal carina contraindicates the use of a right-sided DLT. The relative indications for a right-sided DLT include distorted anatomy of the left mainstem

bronchus by a tumor or a descending thoracic aortic aneurysm, left-sided pneumonectomy, left-sided tracheo-bronchial disruption, and left lung transplantation. For instance, the advantage of using a right-sided DLT for a left-sided pneumonectomy is that it obviates the need for withdrawal of the endobronchial tube from the left mainstem bronchus, with the attendant risk of blood and secretions moving from the operative (left) bronchus to the nonoperative bronchus. Also, exposure of the left mainstem bronchial stump to positive airway pressure is avoided with the use of a right-sided DLT. The right-sided DLT design varies among manufacturers; all right-sided DLTs have an extra slot in the endobronchial lumen that varies in size to allow ventilation through the right upper bronchus and, if well aligned, prevents unnecessary obstruction. Recent studies using improved placement techniques have shown no increased incidence of obstruction of the right upper lobe bronchus orifice with a right-sided DLT when compared to a left-sided DLT.^{17,18}

Placement, Positioning, and Confirmation of the Right-sided Double-lumen Endotracheal Tube

A major cause of unsuccessful placement of a right-sided DLT is failure to confirm correct placement. The reduced success of the right-sided DLT was attributed to the lack of confirmation of the DLT after the patients were turned into the lateral decubitus position.¹⁶ Based on two recent studies that demonstrated no complications with the placement of a right-sided DLT,^{17,18} the following modified technique is suggested. After the endotracheal lumen tube has passed the vocal cords, the stylet is removed, and the tube is advanced slightly and rotated 90° toward the right. The anatomy of the tracheal carina and the origins of the right upper bronchus and bronchus intermedius are identified when the fiberscope is passed through the bronchial lumen. The fiberscope is used to guide the tube into the right mainstem bronchus. Then, the white line marker on the inner surface of the endobronchial lumen is identified distal to the right upper lobe ventilation slot (fig. 1A). In order to align the slot of the tube with the upper lobe bronchus, a rotational movement of the DLT may be necessary. The fiberscope is passed through the slot so that proper alignment between the slot and the right upper bronchus occurs (fig. 1B); then, distal to the endobronchial lumen, one would confirm a clear view showing the bronchus intermedius (fig. 1C). Once the endobronchial observation is made, the fiberscope is advanced through the endotracheal lumen, where the blue endobronchial cuff can be visualized (fig. 1D).

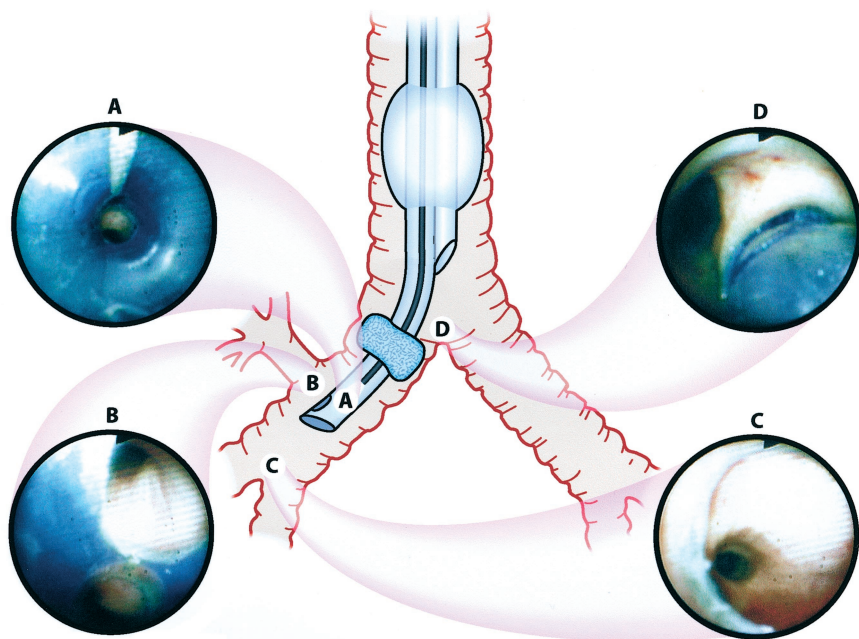


Fig. 1. Fiberoptic bronchoscopic examination for a right-sided double-lumen tube. (A) White line marker when the bronchoscope is passed through the endobronchial lumen. (B) Slot of the endobronchial lumen properly aligned within the entrance of the right upper bronchus. (C) Part of the bronchus intermedius when the bronchoscope is advanced through the distal portion of the endobronchial lumen. (D) Edge of the endobronchial cuff around the entrance of the right mainstem bronchus when the bronchoscope is passed through the tracheal lumen.

Complications of Double-lumen Endotracheal Tubes

Common complications of DLTs are malposition and airway trauma. Frequent causes of malposition include dislodgment of the endobronchial cuff due to an overinflated cuff, which would move the tube into its proximal position; surgical manipulation of the bronchus; or extension of the head and neck when the patient is in the lateral decubitus position. To prevent the latter, the patient's head should be resting on folded blankets so that no flexion or extension occurs.¹⁹ In a review conducted over the last 25 yr on DLTs and airway injuries, bronchial rupture was reported with both rubber and plastic DLTs. It was found that no ruptures had been reported with 41-French DLTs. Whether the complications associated with smaller tubes occurred because they were undersized for the individual patients could not be determined.²⁰

Bronchial Blocking Technology for Lung Isolation

The bronchial blocking technique involves blockade of a mainstem bronchus to allow lung collapse distal to the occlusion. Fogarty catheters,² the Univent[®],³ and WEBs⁴ are the devices used as bronchial blockers.

Fogarty Occlusion Catheter as a Bronchial Blocker

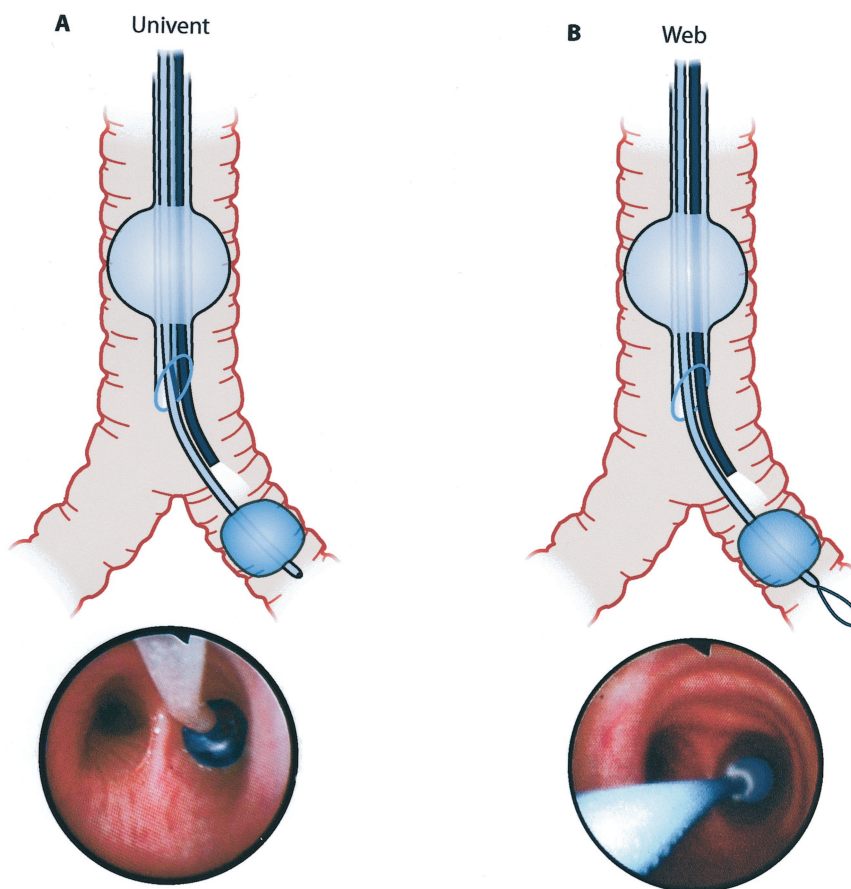
The Fogarty catheter² can be used as a bronchial blocker to achieve lung isolation. An advantage of the Fogarty catheter is that it can be passed through a single-

lumen endotracheal tube in an already intubated patient, without the need for tube exchange, or during nasotracheal intubation and OLV. It may be passed through smaller sized single-lumen endotracheal tubes (*i.e.*, 6.0-mm ID). The most commonly used Fogarty catheter is the 8-French size. The occlusion balloons range in size from 0.5 to 3.0 ml of air. The Fogarty catheter comes with a wire stylet that can be curved at the distal end to facilitate guidance to the target bronchus. The Fogarty catheter is passed through the endotracheal tube, and its guidance is oriented with the aid of a fiberscope. After the Fogarty catheter is introduced into the bronchus, the balloon is inflated under direct vision, and the fiberscope is withdrawn. The optimal position of the Fogarty balloon catheter allows complete blockade of the bronchus without any detectable air leak, usually 4 mm below the tracheal carina into the target bronchus. A disadvantage of the Fogarty catheter is its lack of a hollow center; thus, suction or oxygen insufflation is not possible, and lung collapse takes longer because it occurs by absorption atelectasis.

Univent[®] Tubes

A single-lumen tube with an incorporated channel for the bronchial blocker (Univent[®]) is another alternative to isolate the lungs. The Univent[®] has a shape similar to that of a standard endotracheal tube. In the Univent[®] unit, there is a channel housing a moveable bronchial blocker that can be used to block the left or the right bronchus. An advantage of the Univent[®] is its utility in patients in whom the airway is considered difficult for direct laryngoscopy.²¹ Easy passage during an awake oral intubation has also been reported.²² Other features of

Fig. 2. (A) Univent[®] bronchial blocker; the optimal position of the Univent[®] in the left mainstem bronchus. (B) Wire-guided endobronchial blocker (WEB); the optimal position of the WEB blocker in the left mainstem bronchus.



the Univent[®] tube are its efficiency as a selective lobar blocker to improve oxygenation²³ and its ability to convert to a regular endotracheal tube without the need to exchange the tube if postoperative mechanical ventilation is contemplated.

The ID of the Univent[®] for use in adults ranges from 6.0–9.0 mm, the enclosed channel of the bronchial blocker makes the OD larger than that of a regular tube of the same internal size, and the oval shape of the tube requires two different measurements of the OD. The inner lumen is reduced by allowing a space for the blocker. The Univent[®] should be highly considered in patients who present a difficult airway and because of its easy passage during awake oral intubation, similar to a standard endotracheal tube.

Placement, Positioning, and Confirmation of Univent[®] Tubes

Prior to use, the bronchial blocker is lubricated with jelly or spray silicone to facilitate passage. After the bronchial cuff is tested, the blocker is retracted, and standard endotracheal tube placement is performed. Once the tube is in the trachea, the bronchial blocker is advanced to the right or left mainstem bronchus under direct view with the fiberoptic.

bronchoscope. The optimal position of the bronchial blocker when fully inflated (6–8 ml of air) into the left main bronchus is when the inflated bronchial cuff is seen with the fiberoptic 5 mm down the left mainstem bronchus without any detectable air leak (fig. 2A). For a right-sided bronchial blocker, the optimal position is when the cuff is seen above the origin of the right upper bronchus, with no leaks detectable when the cuff is fully inflated. In my experience, the right upper bronchus can occasionally be occluded by the cuff. To facilitate lung collapse, the fiberoptic is connected to the suction device and is advanced to the right upper bronchus. Then, the air that remains in the upper bronchus is evacuated, and, after withdrawal of the fiberoptic, the bronchial blocker cuff is inflated. The bronchial blocker cuff requires approximately 3 ml of air to achieve lobar blockade. Because of reports of the potential for perforation of the trachea or bronchus when the Univent[®] is placed blindly, this tube should be guided and its position should be confirmed with the fiberoptic bronchoscope rather than by auscultation.

Complications of the Univent[®]

Two serious complications may occur with improper use of the Univent[®]: inclusion of the bronchial blocker into the stapling line during right upper lobectomy and

Table 2. Summary of Lung Isolation Devices and Recommendations for Placement

| Device | Indication | Tube Size |
|----------------------------|---|---|
| Left-sided DLT | Majority of elective left or right thoracic surgical procedures | Can be determined by measurements of the tracheal width from chest radiograph |
| Right-sided DLT | Left bronchus-distorted anatomy Left pneumonectomy | |
| Univent® blockers | Selective lobar blockade Difficult airways | |
| WEB® blockers | Critically ill intubated patient who requires lung isolation Selective lobar blockade Nasotracheal intubation | Standard endotracheal tube at least 8.0 mm ID |
| Fogarty occlusion catheter | Critically ill intubated patient who requires lung isolation Small bronchus Nasotracheal intubation | Standard endotracheal tube at least 6.0 mm ID |

DLT = double-lumen tube; WEB = wire-guided endobronchial blocker; ID = inside diameter.

obstruction of the tracheal lumen after the bronchial blocker is mistakenly inflated into the tracheal lumen.²⁴ Another complication reported with the Univent® involved blind insertion of the blocker, passing it distally beyond the left bronchial carina, causing lung rupture and pneumothorax.²⁵

Wire-guided Endobronchial Blocker during Lung Isolation

Yet another alternative for lung isolation is the wire-guided endobronchial blocker (WEB).⁴ The WEB has some advantages over the DLT and the Univent®. For instance, it has been reported to be effective in patients with endotracheal tubes in place or in patients who present with a difficult airway. A major advantage is that it can be passed through a nasotracheal tube in patients who require nasal intubation and OLV but cannot open their mouth sufficiently. It can be used as a lobar blocker in patients with previous pneumonectomy who require one-lobe ventilation during surgery (J.H.C., personal communication, April 2001). The WEB is a 9-French catheter that is available in 65 and 78 cm lengths with an internal lumen measuring 1.4 mm in diameter, which

contains a flexible wire that passes through the proximal end of the catheter, where it exits as a flexible wire loop. The wire allows the fibroscope and catheter to be coupled while they are guided into position. This blocker has a high-volume, low-pressure cuff with either an elliptical or spherical shape. In addition, the WEB comes with a three-way multiport airway adapter, where the WEB, the fibroscope, and the anesthesia breathing circuit can be connected.

Placement, Positioning, and Confirmation of the Wire-guided Endobronchial Blocker

The WEB is a single unit that is passed through a standard endotracheal tube. Prior to placement, the WEB shaft and the fibroscope are lubricated with jelly or silicone spray. This technique involves placing the endobronchial blocker through the endotracheal tube and utilizes the fibroscope and wire loop to guide the blocker into the mainstem bronchus. The fibroscope has to be advanced far enough so that the WEB will enter the bronchus while it is being advanced. Once the deflated cuff is below the entrance of the bronchus, the fibroscope is withdrawn, and then the cuff is fully inflated

with 5–8 ml of air to obtain proper sealing of the targeted bronchus (fig. 2B).

After the patient is turned to the lateral decubitus position, bronchoscopic confirmation is necessary to ensure that the cuff of the WEB is still properly positioned. Then, the wire loop can be withdrawn to convert the 1.4-mm channel into a suction port to expedite lung collapse. It is important to remove the wire loop to avoid inclusion during the stapling line. The optimal position of the WEB in the left or in the right bronchus is achieved when the blocker balloon outer surface is seen with the fiberscope at least 2–5 mm below the tracheal carina on the targeted bronchus, and the proper seal is obtained.

One of the advantages of the WEB is its relatively easy placement when an 8.0-mm ID standard endotracheal tube is used. Also, once lung isolation is complete, and there is a need for postoperative mechanical ventilation, the WEB can be withdrawn without the need for reintubation. Some disadvantages of the WEB include the constant need of a fiberscope for its guidance and difficulties in advancing the WEB and the fiberscope when smaller standard endotracheal tubes are used (*i.e.*, 7.0-mm ID). Also, once the wire loop is removed, it cannot be reinserted through the channel to allow repositioning of the blocker. The small diameter of the suction channel increases the time required for the lung to collapse. However, lung collapse can be expedited by attaching a barrel from a 3-ml syringe to a device providing low suction.

Conclusions

The left-sided DLT, Fogarty catheter, Univent[®], and WEB devices have performed well over the years. However, in my opinion, there is still room for improvement in the design of right-sided DLTs. Misalignment between the lumen of the right upper lobe bronchus and the tube's lobar slot (*i.e.*, the slot intended to provide ventilation to the right upper lobe) might be a problem for the anesthesiologist who is not accustomed to the right-sided DLT. This problem would be less frequent if the lobar slot was much longer (*i.e.*, more than 20 mm) and wider. Potentially, both the lobar slot and the distal endobronchial lumen could be combined, resulting in a single, long and wide distal opening, allowing ventilation of both the right upper lobe and the bronchus intermedius *via* a single channel.

Table 2 summarizes a logical approach to the use of these devices for lung isolation. Because of the greater margin of safety, the left-sided DLT should be the tube of choice for the majority of cases. A right-sided DLT should be an alternative when a contraindication to the placement of a left-sided DLT exists. The Univent[®] or WEB is a better choice for patients with a difficult airway

or whenever a lobar blockade is needed. The WEB or the Fogarty catheter is suitable when nasotracheal intubation is required during OLV. For confirmation of DLTs, the Univent[®], Fogarty catheters, and WEBs, I recommend the use of fiberoptic bronchoscopy to confirm tube placement when the patient is in the supine position, after the patient is moved to the lateral decubitus position, and whenever a malposition of these devices occurs.

References

1. Björk VO, Carlens E: The prevention of spread during pulmonary resection by the use of a double lumen catheter. *J Thorac Surg* 1950; 20:151–7
2. Ginsberg RJ: New technique for one-lung anesthesia using an endobronchial blocker. *J Thorac Cardiovasc Surg* 1981; 82:542–6
3. Inoue H, Shohtsu A, Ogawa J, Kawada S, Koide S: New device for one-lung anesthesia: Endotracheal tube with movable blocker. *J Thorac Cardiovasc Surg* 1982; 83:940–1
4. Arndt GA, Kranner PW, Rusy DA, Love R: Single-lung ventilation in a critically ill patient using a fiberoptically directed wire-guided endobronchial blocker. *ANESTHESIOLOGY* 1999; 90:1484–6
5. Lewis JW, Serwin JP, Gabriel FS, Bastanfar M, Jacobsen G: The utility of a double-lumen tube for one-lung ventilation in a variety of noncardiac thoracic surgical procedures. *J Cardiothorac Vasc Surg* 1992; 6:705–10
6. Brodsky JB, Macario A: Modified Bronchocath double-lumen tube. *J Cardiothorac Vasc Anesth* 1995; 9:784–5
7. Sivalingam P, Tio R: Tension pneumothorax, pneumomediastinum, pneumoperitoneum, and subcutaneous emphysema in a 15-year-old Chinese girl after a double-lumen tube intubation and one-lung ventilation. *J Cardiothorac Vasc Anesth* 1999; 13:312–5
8. Brodsky JB, Macario A, Mark JBD: Tracheal diameter predicts double-lumen tube size: A method for selecting left double-lumen tubes. *Anesth Analg* 1996; 82:861–4
9. Chow MYH, Liam BL, Lew TWK, Chelliah RY, Ong BC: Predicting the size of a double-lumen endobronchial tube based on tracheal diameter. *Anesth Analg* 1998; 87:158–60
10. Hannallah M, Benumof JL, Silverman PM, Kelly LC, Lea D: Evaluation of an approach to choosing a left double-lumen tube size based on chest computed tomographic scan measurement of left mainstem bronchial diameter. *J Cardiothorac Vasc Anesth* 1997; 11:168–71
11. Boucek CD, Landreneau R, Freeman JA, Strollo D, Bircher NG: A comparison of techniques for placement of double-lumen endobronchial tubes. *J Clin Anesth* 1998; 10:557–60
12. Alliaume BA, Coddens J, Deloof T: Reliability of auscultation in positioning of double-lumen endobronchial tubes. *Can J Anaesth* 1992; 39:687–90
13. Klein U, Karzai W, Bloos F, Wohlfarth M, Gottschall R, Fritz H, Gugel M, Seifert A: Role of fiberoptic bronchoscopy in conjunction with the use of double-lumen tubes for thoracic anesthesia. *ANESTHESIOLOGY* 1998; 88:346–50
14. Katz JA: Double-lumen endobronchial intubation and fiberoptic technology for separation of the lungs, Anesthesia, 5th edition [companion CD-ROM]. Edited by Miller RD. Philadelphia, WB Saunders, 2000
15. Benumof JL, Partridge BL, Salvatierra C, Keating J: Margin of safety in positioning modern double-lumen endotracheal tubes. *ANESTHESIOLOGY* 1987; 67:729–38
16. McKenna MJ, Wilson RS, Botelho RJ: Right upper lobe obstruction with right-sided double-lumen endobronchial tubes: A comparison of two tube types. *J Cardiothorac Anesth* 1988; 2:734–40
17. Campos JH, Massa CF: Is there a better right-sided tube for one-lung ventilation? A comparison of the right-sided double-lumen tube with the single-lumen tube with right-sided enclosed bronchial blocker. *Anesth Analg* 1998; 86:696–700
18. Campos JH, Massa CF, Kernstine KH: The incidence of right upper-lobe collapse when comparing a right-sided double-lumen tube versus a modified left double-lumen tube for left-sided thoracic surgery. *Anesth Analg* 2000; 90:535–40
19. Saito S, Dohi S, Naito H: Alteration of double lumen endobronchial tube position by flexion and extension of the neck. *ANESTHESIOLOGY* 1985; 52:696–7
20. Fitzmaurice BG, Brodsky JB: Airway rupture from double-lumen tubes. *J Cardiothorac Vasc Anesth* 1999; 13:322–9
21. Hagihira S, Takashima M, Mori T, Yoshiya I: One-lung ventilation in patients with difficult airways. *J Cardiothorac Vasc Anesth* 1998; 12:186–8
22. Ransom ES, Carter LS, Mund GD: Univent tube: A useful device in patients with difficult airways. *J Cardiothorac Vasc Anesth* 1995; 9:725–7
23. Campos JH: Effects on oxygenation during selective lobar versus total lung collapse with or without continuous positive airway pressure. *Anesth Analg* 1997; 85:583–6
24. Dougherty P, Hannallah M: A potentially serious complication that resulted from improper use of the Univent[®] tube. *ANESTHESIOLOGY* 1992; 77:835–6
25. Schwartz DE, Spencer YC, Larson MD: Pneumothorax complicating the use of a Univent[®] endotracheal tube. *Anesth Analg* 1993; 76:443–5