

Conservative Treatment of Paraplegia after Removal of an Epidural Catheter during Low-molecular-weight Heparin Treatment

Frank Herbstreit, M.D.,* Peter Kienbaum, M.D.,† Peter Merguet, M.D.,‡ Jürgen Peters, M.D.‡

EPIDURAL catheters are commonly used in today's anesthetic practice, and complications are rare. However, hematomas within the spinal canal leading to compression of the spinal cord remain a major concern. In particular, anticoagulation and bleeding disorders are considered to be risk factors for hematoma formation after neuroaxial blockade. We report a case of paraplegia that developed after removal of a thoracic epidural catheter during low-molecular-weight heparin (LMWH) treatment. The patient's symptoms improved spontaneously, and restitution was complete after conservative treatment.

Case Report

A 73-yr-old woman (height, 149 cm; weight, 61 kg) was scheduled to undergo left nephrectomy because of a kidney tumor. Her past medical history was unremarkable except for a previous hysterectomy and possible asbestosis. Preoperative coagulation studies and platelet count were within the normal range. Following admission, the patient had been treated with a LMWH (enoxaparin, 40 mg subcutaneously every morning). Since a combined general and epidural anesthesia was planned, no enoxaparin was administered on the day of surgery, *i.e.*, the last dose was given approximately 24 h before anesthesia.

An epidural catheter (20 gauge) was inserted uneventfully at the T12-L1 interspace *via* an 18-gauge Tuohy needle in the awake patient using the loss-of-resistance technique with normal saline. Neither blood nor cerebrospinal fluid could be aspirated *via* the catheter, and a test dose of 3 ml bupivacaine, 0.5%, did not evoke sensory deficits. General anesthesia was induced with fentanyl (5 µg/kg), etomidate (20 mg), and rocuronium (0.5 mg/kg); the trachea was intubated; and anesthesia was maintained with nitrous oxide (60% end tidal) and sevoflurane (0.7% expired). Another 8 ml bupivacaine, 0.5%, was administered epidurally, and anesthesia and nephrectomy proceeded uneventfully except for a splenectomy due to surgical injury to the spleen. The patient was extubated after surgery and transferred to a general ward. For analgesia, a continuous epidural infusion of 0.25% bupivacaine (4-8 ml/h) was administered. This yielded sufficient analgesia without gross sensory or motor deficits. When the patient was visited by an anesthesiologist on the first postoperative day, analgesia was satisfactory and gross neurologic examination was normal. Treatment with LMWH was continued, and no other drugs impairing coagulation or platelet function were given postoperatively.

On the morning of the third postoperative day, a surgeon removed

the epidural catheter without consulting an anesthesiologist. Unfortunately, enoxaparin (40 mg subcutaneously) had been administered approximately 2 h earlier. Immediately after catheter removal, the patient complained of severe back pain, and over the next 2 h, paraplegia of both legs developed. The attending anesthesiologist on call was informed. Examination revealed a complete palsy of the left leg and impossible flexion of the right hip. The left patellar reflex and the anal sphincter reflex were absent. Other muscular reflexes were normal, and a Babinski sign was not observed. Sensory deficits did not occur at any time.

An urgent magnetic resonance image (MRI) was obtained and revealed an inhomogeneous epidural mass compressing the dural sac from T11-T12 to T12-L1, consistent with an epidural hematoma (fig. 1). A neurosurgical consultation was requested immediately. At the time of the neurosurgical examination, a slight improvement of the motor impairment was observed. Thus, immediate surgical intervention was not considered by the neurosurgeon to be indicated, and a decision toward a conservative trial was made. Treatment with corticosteroids (dexamethasone, 40 mg intravenously initially and 4 mg orally four times daily for 1 week) and physical therapy were initiated. The motor deficits gradually disappeared completely over the next 4 days. The epidural mass was still present in a MRI obtained after 3 days but was smaller in size and did not compress the dural sac (fig. 2).

Discussion

Epidural hematoma is a very rare but typical complication of epidural anesthesia. In a large retrospective and prospective study, no signs suggesting epidural hematoma were recognized in 4,185 patients receiving a thoracic epidural catheter.¹ However, several cases of spinal or epidural hematoma after neuraxial blockade in patients receiving LMWH have been published,^{2,3} and investigators expressed their concern about patients receiving LMWH being at an increased risk for those particular complications.⁴ In 1997, the Food and Drug Administration issued a public health advisory regarding reports of epidural or spinal hematomas with the concurrent use of LMWH and spinal-epidural anesthesia or spinal puncture. Similar recommendations were issued by the German Society of Anesthesiology and Intensive Care Medicine in the same year.⁵ There is consensus that when LMWH is used perioperatively, neuroaxial block should be delayed for 10 to 12 h after the last dose.^{6,7} The same time interval has been recommended between LMWH administration and removal of a spinal or epidural catheter.⁶

Enoxaparin has an elimination half-life of 2.3-3.0 h, and its antithrombotic effect lasts for about 24 h.⁸ LMWHs also undergo renal elimination and do accumulate in patients with renal failure.⁸ Whether nephrectomy in our patient altered LMWH elimination can only be speculated.

* Resident in Anesthesiology, † Staff Anesthesiologist, ‡ Professor of Anesthesiology and Intensive Care Therapy and Chairman.

Received from the Abteilung für Anästhesiologie und Intensivmedizin, Universitätsklinikum Essen, Hufelandstrasse 55, D-45122 Essen, Germany. Submitted for publication August 2, 2001. Accepted for publication January 15, 2002. Support was provided solely from institutional and/or departmental sources.

Address reprint requests to Dr. Herbstreit: Abteilung für Anästhesiologie und Intensivmedizin, Universitätsklinikum Essen, Hufelandstrasse 55, D-45122 Essen, Germany. Address electronic mail to: frank.herbstreit@uni-essen.de. Individual article reprints may be purchased through the Journal Web site, www.anesthesiology.org.

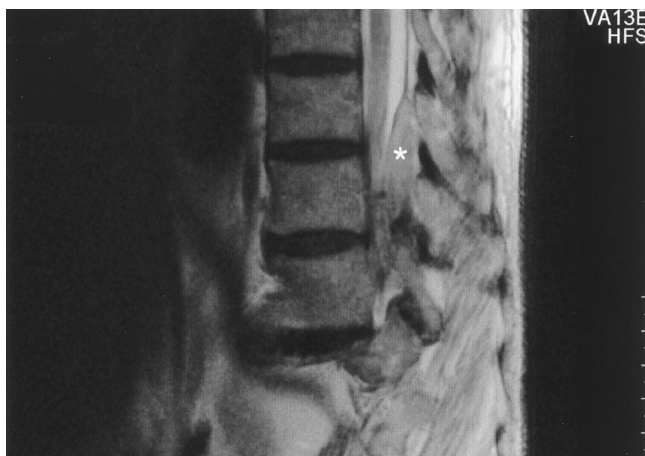


Fig. 1. Sagittal magnetic resonance imaging section at the T12–L1 level after removal of an epidural catheter revealing an epidural mass (*) extending from T12 to L1 compressing the dural sac.

Reversing the effects of LMWH is difficult. Protamine neutralizes the antithrombin activity of LMWH, normalizing the activated partial thromboplastin time; however, its antagonizing effect on antifactor Xa activity is incomplete.⁹ If LMWH effects are to be reversed, protamine seems to have a lesser effect compared to its antagonizing abilities after unfractionated heparin treatment.

Cases of epidural hematoma developing after catheter removal have been reported.^{10,11} The treatment of choice is laminectomy and surgical evacuation of the hematoma. The rapidity of surgical intervention correlates with the outcome.¹² There are, however, also reports of patients that have been managed successfully

without surgical intervention following epidural hematomas of either posttraumatic or spontaneous origin.^{13,14} In most of those cases, improving clinical condition led to the decision for conservative management. Novel in our case is the conservative management of an epidural hematoma developing as a complication after epidural anesthesia with complete resolution of the neurologic symptoms. Initial regression of symptoms during diagnostic workup led to the conservative approach.

An epidural hematoma occurred after removal of an epidural catheter. The physician removing the catheter was not trained in anesthesiology and was unaware of the risk when an epidural catheter is removed shortly after LMWH administration. This supports the view that postoperative neuroaxial blockade should be supervised by anesthesia personnel and that manipulations of epidural catheters should only be made by educated physicians. Particular caution is warranted when anticoagulants or platelet aggregation inhibitors are administered. Following administration of LMWHs, removal of epidural catheters should be delayed for 10–12 h.

The management of suspected epidural hematoma should include a thorough neurologic examination, an urgent MRI or computed tomography scan, and immediate consultation with a neurosurgeon. Surgical intervention remains the treatment of choice in patients with neurologic deficits; however, a conservative approach may be indicated in patients showing early clinical improvement.

References

- Giebler RM, Scherer RU, Peters J: Incidence of neurologic complications related to thoracic epidural catheterizations. *ANESTHESIOLOGY* 1997; 86:55–63
- Sandhu H, Morley-Forster P, Spadafora S: Epidural hematoma following epidural anesthesia in a patient receiving unfractionated heparin for thromboprophylaxis. *Reg Anesth Pain Med* 2000; 25:72–5
- Stroud CC, Markel D, Sidhu K: Complete paraplegia as a result of regional anesthesia. *Arthroplasty* 2000; 15:1064–7
- Horlocker TT, Wedel DJ: Spinal and epidural blockade and perioperative low molecular weight heparin: Smooth sailing on the titanic. *Anesth Analg* 1998; 86:1153–6
- Gogarten W, Van Aken H, Wulf H, Klose R, Vandermeulen E, Harenberg J: Para-spinal regional anesthesia and prevention of thromboembolism/anticoagulation: Recommendations of the German Society of Anesthesiology and Intensive Care Medicine. *Anesthesiol Intensivmed Notfallmed Schmerzther* 1997; 38:623–8
- Liu SS, McDonald SB: Current issues in spinal anesthesia. *ANESTHESIOLOGY* 2001; 94:888–906
- Vandermeulen EP, Van Aken H, Vermeylen J: Anticoagulants and spinal-epidural anesthesia. *Anesth Analg* 1994; 79:1165–77
- Hirsh J, Warkentin TE, Shaughnessy SG, Anand SS, Halperin JL, Rascke R, Granger C, Ohman EM, Dalen JE: Heparin and low-molecular-weight heparin: Mechanisms of action, pharmacokinetics, dosing, monitoring, efficacy, and safety. *Chest* 2001; 119:S64–94
- Harenberg J, Gnasso A, De Vries JX, Zimmermann R, Augustin J: Inhibition of low molecular weight heparin by protamine chloride in vivo. *Thromb Res* 1985; 38:11–20
- Yin B, Barratt SM, Power I, Percy J: Epidural haematoma after removal of an epidural catheter in a patient receiving high-dose enoxaparin. *Br J Anaesth* 1999; 82:288–90
- Ousmane ML, Fleyfel M, Vallet B: Epidural hematoma after catheter removal. *Anesth Analg* 2000; 90:1246–51
- Lawton MT, Porter RW, Heisermann JE, Jacobowitz R, Sonntag VKH, Dickmann CA: Surgical management of spinal epidural hematoma: Relationship between surgical timing and neurological outcome. *J Neurosurg* 1995; 83:1–7
- La Rosa G, d'Avella D, Conti A, Cardali S, La Torre D, Cacciola F, Longo M, Tomasello F: Magnetic resonance imaging-monitored conservative management of traumatic spinal epidural hematomas. *J Neurosurg* 1999; 91(suppl):128–32
- Duffill J, Sparrow OC, Millar J, Barker CS: Can spontaneous spinal epidural hematoma be managed safely without operation? A report of four cases. *J Neurol Neurosurg Psychiatry* 2000; 69:816–9

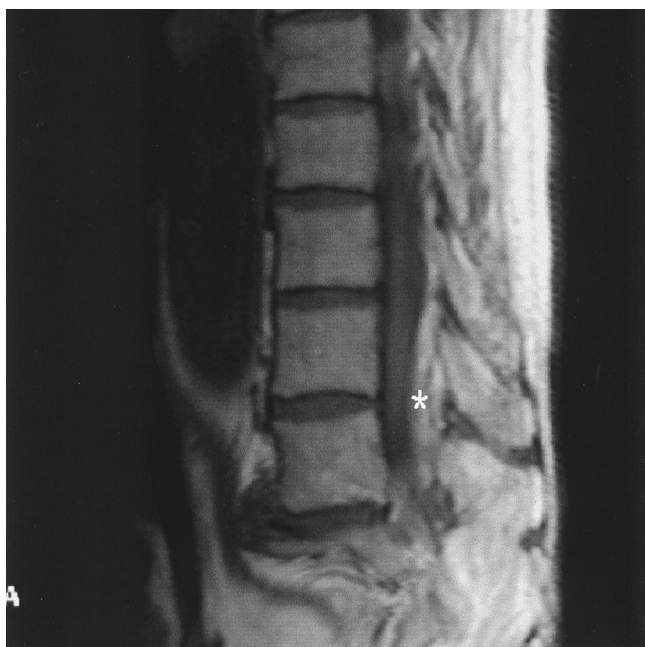

Fig. 2. Magnetic resonance imaging study of the lumbar spine 3 days after removal of an epidural catheter. The epidural mass (*) is smaller but still present.

Spontaneous Resolution of Epidural Hematoma after Continuous Epidural Analgesia in a Patient without Bleeding Tendency

Kazuyoshi Inoue, M.D.,* Masataka Yokoyama, M.D.,† Hideki Nakatsuka, M.D.,* Keiji Goto, M.D.‡

SPINAL epidural hematoma (SEH) after epidural analgesia is a rare but serious complication. Most cases of SEH after epidural block are attributed to the patient having a bleeding tendency or receiving anticoagulation therapy.¹⁻³ Surgical decompression of the spinal cord is mandatory for prevention of permanent neurologic deficits.^{1,2} Only a few cases of spontaneous recovery from SEH have been reported.⁴⁻⁶ We report a case of SEH accompanied by paraplegia after continuous epidural analgesia in a patient without a known bleeding disorder and not receiving anticoagulation therapy. This patient recovered spontaneously.

Case Report

A 72-yr-old woman (weight, 42 kg) with stenosis of the bile duct associated with cholelithiasis was admitted for choledochoduodenotomy and cholecystectomy. The patient had no relevant medical history and was on no medication. Except for elevations in aspartate aminotransferase (109 U/l [normal range, 11-32 U/l]), alanine aminotransferase (112 [11-32] U/l), alkaline phosphatase (230 [6-39] U/l), and total bilirubin (8.9 mg/dl; normal range, 0.3-1.2 U/l), she showed no abnormal findings in preoperative laboratory examinations, including coagulation tests.

The patient received an epidural block combined with general anesthesia. Epidural puncture was performed with an 18-gauge Tuohy needle at the T7-T8 interspace, and the epidural space was easily confirmed on the first attempt without bleeding. An epidural catheter was advanced smoothly 5 cm in the cephalad direction without accompanying paresthesia or pain. During surgery, epidural analgesia was achieved with a mixture of 0.125% bupivacaine and 5 μ g/ml fentanyl. The patient received 8 ml of the mixture as an initial dose, and this was followed by continuous administration at a rate of 6 ml/h. The operation was performed without difficulty, and total blood loss during the 3-h surgery was 420 ml.

In the recovery room, the patient had no pain and was able to dorsiflex both feet on request. We reduced the epidural infusion of the 0.125% bupivacaine and 5 μ g/ml fentanyl to 4 ml/h for postoperative pain control. On the first postoperative day, the patient had no pain or motor weakness when postoperative evaluation was made by the anesthesiologist. On the second postoperative day, both lower extremities gradually became weak, but the patient did not report her condition to anyone because she considered that this weakness was due to epidural analgesia. On the third postoperative day, the patient informed the nursing staff of her condition, and the anesthesiologist was consulted.

When the patient first complained of lower extremity weakness, she was alert and had no pain. Her vital signs were normal, but she was unable to hold her knees flexed. We immediately discontinued the epidural infusion and consulted a neurosurgeon. The neurologic examination showed hypoesthesia and hypalgesia below the T6 dermatome distribution in the right side and below the T8 in the left side. Both the patellar and the Achilles tendon reflexes were absent. Manual muscle testing revealed that the muscle strength of the iliopsoas and the quadriceps femoris were zero (0/5), and the muscle strength of the tibialis anterior and extensor hallucis longus were trace (1/5) in both lower extremities. Cranial nerve and upper extremity examination results were normal. No bleeding or sign of infection was present at the epidural catheter insertion site. Although the postoperative coagulation profile was normal, we suspected an SEH. Emergency magnetic resonance (MR) imaging was ordered, and the epidural catheter was removed before the study. The MR images revealed a hematoma extending from Th6 to Th9 (fig. 1). When the MR imaging was finished, however, the patient began to show signs of recovery from the paraplegia. She could dorsiflex both lower extremities on request. One hour after the MR imaging, she could hold the right knee flexed. Judging from the signs of spontaneous resolution, the neurosurgeon recommended conservative therapy with 8 mg intravenous dexamethasone every 8 h. Several hours after the conservative therapy, the muscle strength and sensory function improved gradually in both lower extremities.

By the fourth postoperative day, the patient had regained the ability to dorsiflex both feet and to hold both knees flexed. On the eighth postoperative day, she was able to stand by herself without assistance, and she was able to walk with a cane by the 14th postoperative day. An MR image obtained on the 14th postoperative day showed that the hematoma remained at the same level but was reduced in size (fig. 2). The patient was discharged from the hospital on the 40th postoperative day without neurologic deficits.

Discussion

Placement of an epidural catheter may cause SEH more often than expected, but most SEHs remain asymptomatic.^{7,8} In some patients, however, SEH becomes symptomatic, especially if the patient has a bleeding tendency or is receiving anticoagulation therapy.¹⁻³ Our patient did not have a bleeding tendency and was not receiving anticoagulants. She was also not taking nonsteroidal antiinflammatory drugs, which are known to impair platelet function. Traumatic or difficult epidural puncture can also cause symptomatic SEH even in patients without coagulation-related disorders or treatment. However, in our patient, the epidural block was performed easily and atraumatically by a well-trained anesthesiologist. The epidural congestion related to the compromised hepatic function in our patient may have been a contributing factor in the development of SEH. Hepatic dysfunction accompanied by increased portal pressure can divert blood into the epidural circulation and cause the veins to dilate and bleed easily.^{8,9} This could have

* Staff Anesthesiologist, † Associate Professor, ‡ Assistant Professor.

Received from the Department of Anesthesiology and Resuscitology, Okayama University Medical School, Okayama City, Okayama, Japan. Submitted for publication December 28, 2001. Accepted for publication April 4, 2002. Support was provided solely from departmental sources.

Address reprint requests to Dr. Yokoyama: Department of Anesthesiology and Resuscitology, Okayama University Medical School, 2-5-1, Shikata-cho, Okayama City, Okayama 700-8558, Japan. Address electronic mail to: masayoko@cc.okayama-u.ac.jp. Individual article reprints may be purchased through the Journal Web site, www.anesthesiology.org.

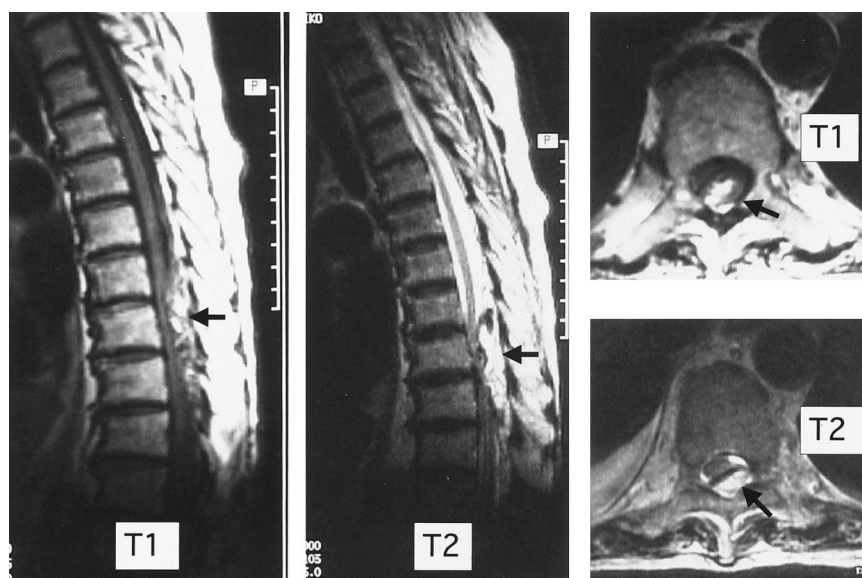


Fig. 1. Magnetic resonance images (MRI) on postoperative day 3. Sagittal T1- and T2-weighted MRIs show a posterior hematoma extending from the Th6 to the Th9 level and compression of the spinal cord. Arrows indicate the hematoma at the Th7 level in axial and sagittal MRIs.

led to the symptomatic change in this case. Spontaneous SEH has been reported in a few cases.^{4,10} MR study in our case, however, revealed that the SEH was located where the epidural block had been performed; therefore, spontaneous SEH was unlikely, although the cause of this SEH was not clear.

Irrespective of the cause, emergency decompressive laminectomy should be performed for SEH in patients presenting with progressive signs of spinal cord compression.^{1,2} Lawton *et al.*¹¹ reviewed that rapid diagnosis of SEH and emergency surgical treatment maximize neurologic recovery, but patients with complete neurologic lesions or long-standing compression can improve substantially with surgery. However, surgical treatment may be unnecessary when the clinical symptoms are not progressive or when early recovery is observed.⁵ Wagner *et al.*⁶ reported that for

patients with a stable or improving neurologic status, conservative management monitored by MR imaging might be the treatment of choice. Because our patient began to show signs of recovery from the paraplegia early after we were informed of symptoms, we chose conservative therapy. Our patient's neurologic function improved shortly after removal of the catheter, suggesting that a pressure effect from the epidural infusion may have worsened her functional deficit. This implies that epidural infusion may aggravate the symptoms of SEH, and that removal of the epidural catheter may improve the paraplegia, as occurred in our patient.

The delay in recognizing the SEH in this case should be addressed. As mentioned above, early diagnosis of SEH is key to preventing permanent neurologic deficit. In our hospital, nursing staff and surgeons check the patient's

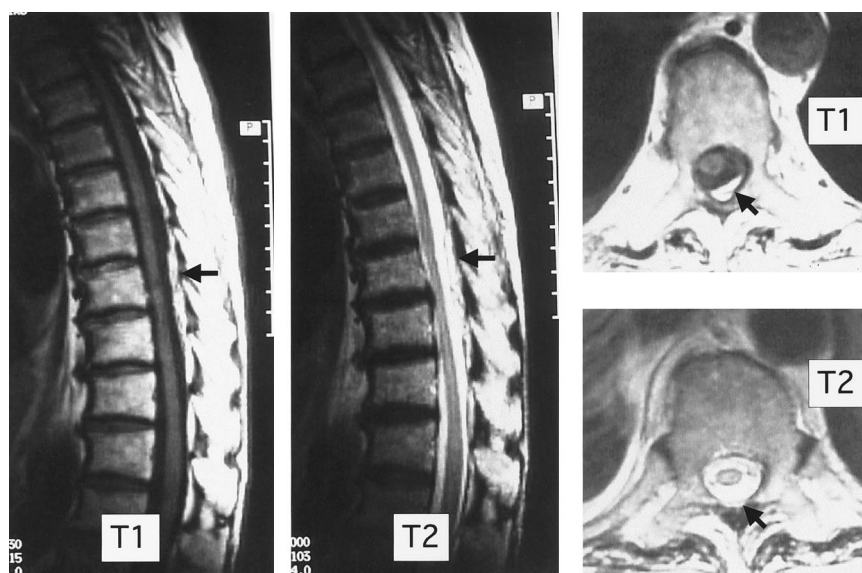


Fig. 2. Magnetic resonance images (MRIs) on postoperative day 14. Sagittal T1- and T2-weighted MRIs show that the hematoma still exists from the Th6 to the Th9 level, but it is smaller than it was on postoperative day 3, and compression of the spinal cord has disappeared. Arrows indicate the hematoma at the Th7 level in axial and sagittal MRIs.

condition often during the postoperative period, and the anesthesiologist makes postoperative rounds on the first postoperative day as a rule. After the postoperative round by the anesthesiologist on the first postoperative day, however, our patient was not given a thorough examination for signs of neurologic dysfunction. Furthermore, our patient did not report her condition because she thought her symptoms were due to the epidural analgesia. Postoperative pain control by epidural analgesia has become popular. Thus, it is important to carefully explain the side effects of epidural block not only to patients but also to nursing staff and surgeons. In addition, patients who have undergone epidural block should be monitored carefully for potential neurologic deficit after surgery, and the postoperative round by the anesthesiologist should be made while patients receive continuous epidural infusion.

The authors thank Wasa Ueda, M.D. (Department of Perioperative Science, Kochi Medical School, Kohasu, Okoh-cho, Nankoku City, Kochi, Japan), for reviewing the manuscript.

Anesthesiology 2002; 97:737-9

References

1. Foo D, Rossier AB: Preoperative neurological status in predicting surgical outcome of spinal epidural hematoma. *Surg Neurol* 1981; 15:389-401
2. Onishchuk JL, Carlsson C: Epidural hematoma associated with epidural anesthesia: Complications of anticoagulant therapy. *ANESTHESIOLOGY* 1992; 77: 1221-3
3. Vandermeulen EP, Van Aken H, Vermeylen J: Anticoagulants and spinal-epidural anesthesia. *Anesth Analg* 1994; 79:1165-77
4. Clarke BD, Bertrand G, Tampieri D: Spontaneous spinal epidural hematoma causing paraplegia: Resolution and recovery without surgical decompression. *Neurosurgery* 1992; 30:108-11
5. Boukobza M, Guichard JP, Boissonet M, George B, Reizine D, Gelbert F, Merland JJ: Spinal epidural haematoma: Report of 11 cases and review of literature. *Neuroradiology* 1994; 36:456-9
6. Wagner S, Forsting M, Hache W: Spontaneous resolution of a large spinal epidural hematoma: Case report. *Neurosurgery* 1996; 38:816-8
7. Harvey SC, Roland PJ, Curé JK, Cuddy BG, O'Neil MG: Spinal epidural hematoma detected by lumbar epidural puncture. *Anesth Analg* 1997; 84:1136-9
8. Morisaki H, Doi J, Ochiai R, Takeda J, Fukushima K: Epidural hematoma after epidural anesthesia in a patient with hepatic cirrhosis. *Anesth Analg* 1995; 80:1033-5
9. Dunn D, Dhopes V, Mobini J: Spinal subdural hematoma: A possible hazard of lumbar puncture in an alcoholic. *JAMA* 1979; 241:1712-3
10. McQuarrie IG: Recovery from paraplegia caused by spontaneous spinal epidural hematoma. *Neurology* 1978; 28:224-48
11. Lawton MT, Porter RW, Heiserman JE, Jacobowitz R, Sonntag VKH, Dickman CA: Surgical management of spinal epidural hematoma: Relationship between surgical timing and neurological outcome. *J Neurosurg* 1995; 83:1-7

© 2002 American Society of Anesthesiologists, Inc. Lippincott Williams & Wilkins, Inc.

Lidocaine-induced Seizures in Patients with History of Epilepsy: Effect of Antiepileptic Drugs

John C. DeToledo, M.D.,* Alireza Minagar, M.D.,† Merredith R. Lowe, M.D.‡

LIDOCAINE has a concentration-dependent effect on seizures. Serum concentrations of lidocaine below 5 mg/ml decrease neuronal excitability and have been used to treat status epilepticus. At higher level concentrations, lidocaine is a proconvulsant, lowering seizure threshold in the cerebral cortex, amygdala, and hippocampus, usually causing a generalized convulsion.¹⁻³ While the effects of anticonvulsants on lidocaine-induced convulsions have been recently investigated in rats,⁴ the effects of lidocaine in the precipitation of partial seizures in patients with a previous history of epilepsy and the role of antiepileptic drugs in these cases have not been reported.

Case Reports

Case 1

A 36-yr-old diabetic woman was admitted to the hospital because of chest pain and ventricular tachycardia. She had a 14-yr history of focal motor seizures involving the right side of the body. Previous electroencephalograms showed left hemispheric spikes. Seizures had been

well controlled on 400 mg/day phenytoin. After she was given 100 mg lidocaine intravenously for the ventricular tachycardia (1.3 mg/kg), the patient developed a typical focal seizure involving the right side of her face and the right arm. She was given a loading dose of 1,500 mg phenytoin intravenously, which increased the serum concentration of phenytoin from 6.8 to 22.3 µg/ml. She recovered uneventfully from the seizure. As the ventricular tachycardia persisted, she was given an additional lidocaine bolus of 50 mg (0.65 mg/kg) followed by a continuous infusion of 2 g lidocaine in 500 ml D5%, at a rate of 3.3 mg/min. Approximately 6 h after the beginning of the infusion, she had a witnessed generalized seizure. Her electroencephalogram, which had previously shown complete cessation of the previous seizure pattern, now showed the abrupt onset of generalized spike and polyspike and waves (fig. 1). The concentration of lidocaine in venous blood was 21 µg/ml. Lidocaine infusion was stopped, and she was given 10 mg intravenous diazepam, which suppressed the spike and wave discharges.

Case 2

A 41-yr-old woman had a history of focal and secondarily generalized seizures since the age of 23. Previous ictal and interictal electroencephalograms showed a right frontal focus. The patient had finished an electroencephalographic telemetry evaluation for epilepsy surgery and was restarted on carbamazepine, 200 mg. During a cerebral arteriogram and Wada test performed that same day, she was mistakenly given a 20-mg lidocaine bolus (which had been used to anesthetize the groin) *via* the intraarterial catheter into the right internal carotid artery. She developed a focal seizure originating in the right hemisphere within 20 s of the injection (fig. 2). The seizure was clinically and electrographically identical to her usual focal seizures. The seizure did not generalize. The serum concentration of carbamazepine was 1.6 µg/ml at the time of the seizure.

* Associate Professor of Neurology, † Neurology Instructor, ‡ Assistant Professor of Clinical Neurology.

Received from the Department of Neurology, University of Miami School of Medicine, Miami, Florida. Submitted for publication October 15, 2001. Accepted for publication March 14, 2002. Support was provided solely from institutional and/or departmental sources.

Address reprint requests to Dr. DeToledo: EEG Laboratory, University of Miami School of Medicine, 1150 Northwest 14th Street, Suite 400, Miami, Florida 33136. Address electronic mail to: jdetoled@mednet.med.miami.edu. Individual article reprints may be purchased through the Journal Web site, www.anesthesiology.org.

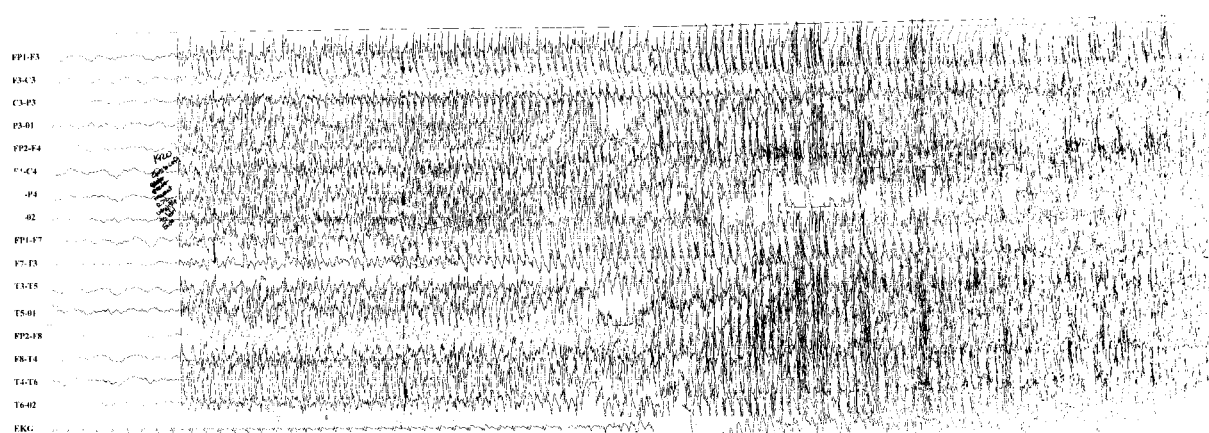


Fig. 1. Abrupt onset of generalized spike and wave discharges in patient 2. The record shows no evidence of a focal onset for this seizure.

Discussion

These two cases illustrate two distinct presentations of lidocaine-induced seizures in patients with a previous history of epilepsy: precipitation of a patient's typical partial seizure when concentrations of anticonvulsant medications were low and precipitation of a generalized tonic clonic when the patient had therapeutic concentrations of phenytoin. Lidocaine is known to have a concentration-dependent effect on seizures. At concentrations between 0.5 and 5 $\mu\text{g/ml}$, lidocaine can suppress the clinical and electroencephalographic manifestations of seizures, whereas at higher concentrations, lidocaine can cause seizures.^{3,5,6} This bimodal response has been demonstrated in cats with penicillin-induced epileptogenic foci in which concentrations between 2 and 3 $\mu\text{g/ml}$ cause suppression of epileptiform electroencephalographic discharges. This suppression persists

until the lidocaine concentration drops below 1 $\mu\text{g/ml}$. Concentrations between 4.5 and 7 $\mu\text{g/ml}$, however, increase cortical irritability, culminating in status epilepticus at concentrations above 7.5 $\mu\text{g/ml}$.⁶ In epileptic cats, the presence of epileptiform EEG discharges indicates that serum concentrations of lidocaine are either below 1 $\mu\text{g/ml}$ or above 7 $\mu\text{g/ml}$.

At serum concentrations below 5 $\mu\text{g/ml}$, lidocaine abolishes cortically induced facilitation of motoneurons,⁷ which may account for its anticonvulsant action. The mechanisms governing the anticonvulsant actions of the drug are not completely understood.⁸ Intravenous administration of lidocaine inhibits L-glutamate-induced transcallosal inhibition of contralateral neurons in cats,⁹ which is independent of γ -aminobutyric acid or its receptor sites.¹⁰ The mechanisms mediating the proconvulsant properties of lidocaine are not completely understood, either. Supratherapeutic concentrations of lidocaine

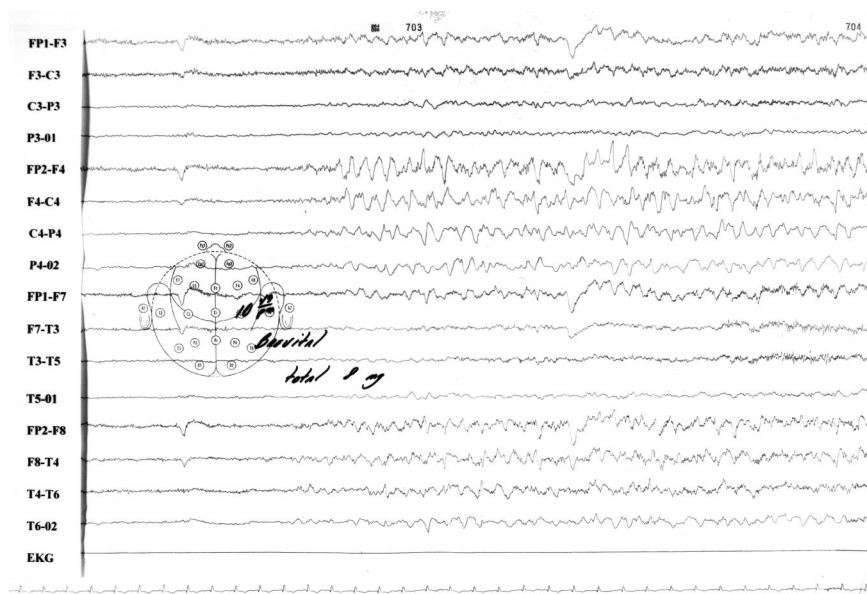


Fig. 2. Electroencephalographic recording during the inadvertent administration of lidocaine into the right internal carotid artery (note electroencephalographic technician's notation of "brevital 8 mg" in the record). Approximately 2 s after the injection, there is irregular, semirhythmic 4-Hz sharp and slow waves over the right hemisphere that are maximal over the right frontal and parasagittal areas.

produce a selective blockade of inhibitory cortical neurons,^{5,11} which ultimately lead to convulsions.

In humans, slow intravenous infusions of lidocaine have been successfully used to treat convulsive status epilepticus and *epilepsia partialis continua*.³ Lidocaine concentrations above 8 to 9 $\mu\text{g/ml}$,^{2,5} however, are associated with increased risk of generalized tonic-clonic convulsions.¹⁻³ Continuous intravenous infusions of lidocaine given to 11 healthy volunteers at rates ranging from 1.5 to 3 $\text{mg} \cdot \text{kg}^{-1} \cdot \text{min}^{-1}$ resulted in generalized convulsions in all after an average total dose of 6–8 mg/kg .² Convulsions occurred abruptly and without prodrome in 15 of the 17 volunteers. Several of the volunteers had recurrence of seizures over the 20–30 min following the end of the infusion. One of them had seven seizures following the infusion. All volunteers had postictal confusion after the lidocaine-induced seizures, and the average time for neurologic recovery was 37 min.² Although slower rates of infusion, 0.5 $\text{mg} \cdot \text{kg}^{-1} \cdot \text{min}^{-1}$ given over 25 min, are usually considered safe, another study showed that 1 out of 12 healthy volunteers developed a generalized convulsion with this rate of infusion.¹²

Lidocaine is converted to monoethylglycinexylidide by oxidative *N*-deethylation, part of which is then hydrolyzed to 2,6-glycine xylidide.¹³ Both monoethylglycinexylidide and, to a lesser extent, 2,6-glycine xylidide can lower seizure threshold¹⁴ and potentiate lidocaine-induced seizures. The role played by lidocaine *versus* its metabolites in the causation of seizures is not always clear. Circumstantial evidence suggests that the rapid metabolism of lidocaine and the potentiating effects of monoethylglycinexylidide and 2,6-glycine xylidide on seizures are of clinical relevance for some patients.^{8,13,15} Patients with lidocaine-induced central nervous system toxicity usually have concentrations above 5 $\mu\text{g/ml}$ and low concentrations of its metabolites.¹⁵ Conversely, there are individuals with signs and symptoms of toxicity who have low lidocaine concentrations but high concentrations of monoethylglycinexylidide. This seems to be more common after extended infusions of lidocaine.¹⁵

Results from animal studies suggest that different anticonvulsants confer different degrees of protection against lidocaine-induced seizures.⁴ However, the effects of anticonvulsants on lidocaine-induced seizures in patients with a previous history of epilepsy have not been reported. These two patients had their typical partial seizure triggered by the administration of high doses of lidocaine. In both instances, the serum concentration of anticonvulsants was low at the time of the focal seizure. After she had a partial seizure, the first patient received a loading dose of phenytoin. She was given a second

bolus of lidocaine and kept on a continuous lidocaine infusion, and she had a second seizure. This seizure, however, was generalized. This patient had been monitored with electroencephalography, and there was no evidence that this generalized seizure evolved from the left frontal seizure focus. In this instance, the therapeutic concentration of phenytoin did not protect against the diffuse lowering of seizure threshold produced by the high concentration of lidocaine but may have prevented the activation of her frontal focus by the lidocaine.

Our findings have to be viewed with reservation as they are based on two cases. Nevertheless, these cases show that lidocaine can activate the seizure focus in patients with a previous history of partial seizures.¹⁶ These cases also suggest that the activation of a preexisting seizure focus is more likely if the serum concentration of anticonvulsants is low. Conversely, therapeutic concentrations of antiepileptic drugs may not prevent generalized seizures, which derive from the widespread lowering of seizure threshold caused by the high concentration of lidocaine.¹⁷

References

1. Pfeifer H, Greenblat DJ, Koch-Weser J: Clinical use and toxicity of intravenous lidocaine. *Am Heart J* 1976; 92:168–73
2. Usubiaga JE, Wikinski J, Ferrero R, Usubiaga IE, Wikinski R: Local anesthetic-induced convulsions in man: An electroencephalographic study. *Anesth Analg* 1966; 45:611–21
3. DeToledo JC: Lidocaine and seizures. *Ther Drug Monit* 2000; 22:320–2
4. Sawaki K, Ohno K, Miyamoto K, Hirai S, Yazaki K, Kawaguchi M: Effects of anticonvulsants on local anaesthetic-induced neurotoxicity in rats. *Pharmacol Toxicol* 2000; 86:59–62
5. De Jong RH, Walts LF: Lidocaine-induced psychomotor seizures in man. *Acta Anaesthesiol Scand Suppl* 1966; 23:598–604
6. Julien RM: Lidocaine in experimental epilepsy: Correlations of anticonvulsant effect with blood concentration. *Electroencephalogr Clin Neurophysiol* 1973; 34:639–45
7. Bernhard CG, Bohm E: The action of local anaesthetics on experimental epilepsy in cats and monkeys. *Br J Pharmacol* 1955; 10:288–95
8. Momota Y, Artru AA, Powers KM, Mautz DS, Ueda Y: Concentrations of lidocaine and monoethylglycine xylidide in brain, cerebrospinal fluid, and plasma during lidocaine-induced epileptiform electroencephalogram activity in rabbits: The effects of epinephrine and hypocapnia. *Anesth Analg* 2000; 91:362–8
9. Warnick JE, Kee RD, Yim GKW: The effects of lidocaine on inhibition in the cerebral cortex. *ANESTHESIOLOGY* 1971; 34:327–30
10. Ciarlone AE: Alteration of lidocaine- or procaine-induced convulsions by manipulation of brain amines. *J Dent Res* 1981; 60:182–6
11. Tanaka K, Yamasaki M: Blocking action of cortical inhibitory synapses by intravenous lidocaine. *Nature* 1966; 209:207–8
12. Hollunger G: On the metabolism of lidocaine: II. The biotransformation of lidocaine. *Acta Pharmacol* 1960; 17:365–71
13. Blumer J, Strong JM, Atkinson AJ: The convulsant potency of lidocaine and its *N*-dealkylated metabolites. *J Pharmacol Exp Ther* 1973; 186:31–6
14. Foldes FF, Molloy R, McNall PG, Koukal LR: Comparison of toxicity of intravenously given local anesthetic agents in man. *JAMA* 1960; 172:1493–7
15. Strong JM, Parker M, Atkinson AJ Jr: Identification of glycinexylidide in patients treated with intravenous lidocaine. *Clin Pharmacol Ther* 1972; 14:67–72
16. Fujita H, Maru E, Shimada M, Suzuki H, Ogiuchi H: A decrease in seizure susceptibility to lidocaine in kindled epileptic rats. *Anesth Analg* 2000; 90:1129–34
17. Murao K, Shingu K, Tsushima K, Takahira K, Ikeda S, Nakao S: The anticonvulsant effects of volatile anesthetics on lidocaine-induced seizures in cats. *Anesth Analg* 2000; 90:148–55

Severe Bleeding following Lumbar Sympathetic Blockade in Two Patients under Medication with Irreversible Platelet Aggregation Inhibitors

Christoph Maier, M.D., Ph.D.,* Martin Gleim, M.D.,† Thomas Weiss, M.D.,‡ Ulf Stachetzki, M.D.,§ Volkmar Nicolas, M.D., Ph.D.,|| Michael Zenz, M.D., Ph.D.#

TICLOPIDINE and clopidogrel are irreversible platelet aggregation inhibitors known to be more effective than aspirin in the prevention of cardiovascular events.¹⁻³ Consequently, an increasing number of patients on these medications are seen in pain clinics.⁴ Although the new platelet inhibitors have demonstrated a lower incidence of spontaneous bleeding than aspirin, the risk of hemorrhage after regional analgesic techniques like neuraxial or sympathetic block may still be increased.^{3,5} This has recently encouraged the American Society of Regional Anesthesia to mention the possible risk of spinal hematomas in patients on ticlopidine and clopidogrel in their guidelines for epidural and spinal anesthesia.**

The blockade of the lumbar sympathetic chain is a commonly used technique in pain management of patients suffering from peripheral arterial disease (PAD), with a very low incidence of severe complications.^{6,7} Although puncture of arterial or venous vessels may be more frequent than reported, large hematomas are obviously uncommon.⁸ However, since irreversible platelet inhibitors like ticlopidine and clopidogrel have been introduced as therapy in Germany, two of our patients have sustained serious bleedings following sympathetic block, and one had a fatal outcome. We present these two cases, propose recommendations for their prevention, and suggest extended monitoring following lumbar sympathetic block (LSB) in patients with an increased risk of bleeding.

* Professor, Department of Pain Management, ‡ Consultant, # Professor, Department of Anaesthesiology, Intensive Care, and Pain Management, § Consultant, Department of Pathology, || Professor, Department of Radiology, Berufsgenossenschaftliche Kliniken Bergmannsheil, Ruhr Universität Bochum. † Consultant, Department of Anaesthesiology and Intensive Care, University of Kiel.

Received from the Berufsgenossenschaftliche Kliniken Bergmannsheil, Ruhr Universität Bochum, Bochum, Germany, and the Department of Anaesthesiology and Intensive Care, University of Kiel, Kiel, Germany. Submitted for publication November 5, 2001. Accepted for publication March 15, 2002. Support was provided solely from institutional and/or departmental sources.

Address reprint requests to Dr. Maier: Department of Pain Management, Berufsgenossenschaftliche Kliniken Bergmannsheil, Bürkle-de-la-Camp Platz 1, D-44789 Bochum, Germany. Address electronic mail to: christoph.maier@ruhr-uni-bochum.de. Individual article reprints may be purchased through the Journal Web site, www.anesthesiology.org.

** Recommendations for neuraxial anesthesia and anticoagulation: Antiplatelet drugs and neuraxial block. Addendum (May 2001). American Society of Regional Anesthesia Web site. Available at: http://www.asra.com/items_of_interest/consensus_statements/page2.iphtml.

Case Reports

Case 1

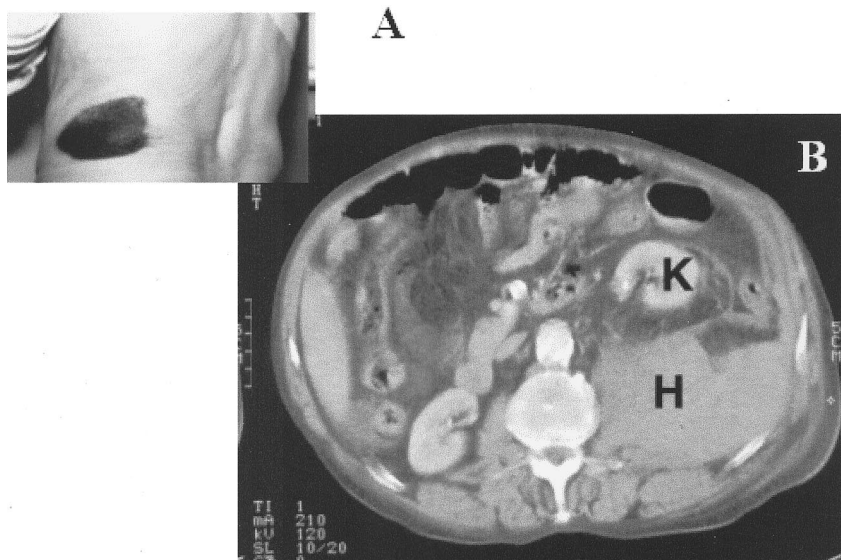
A 71-yr-old male patient was admitted to our pain clinic for LSB. He presented with intermittent claudication (left leg) and a trophic leg ulcer on the right foot due to a progressive PAD as shown by angiography. He reported a pain-free walking distance of 70 m. His medication included 500 mg/day ticlopidine (Tiklyd®; Sanofi-Synthelabo, Berlin, Germany) for stroke prevention in the presence of carotid artery stenosis. History and physical examination revealed no signs of an increased bleeding disposition, and, thus, no coagulation parameters were obtained. Left-sided LSB was performed (5 ml bupivacaine, 0.5%) using radiographic control. No vascular puncture was noted. Within the next 12 h, his pain-free walking distance increased to 113 m. However, he complained of numbness at the medial side of his left thigh as well as groin pain. Two days later, a widespread skin hematoma was recognized (fig. 1A). Hemoglobin decreased from 13.5 g/dl to 10.3 g/dl. Ticlopidine was stopped; however, no bleeding time or other anticoagulation test was performed. Four days later (6 days after the first block), a second block was performed. Direct radiographic control using contrast medium confirmed an intravascular needle position. Redirecting the cannula resulted in the correct spread of solution, and 1.5 ml ethanol, 95%, was then administered. The following night, the patient complained of severe pain in the left groin with a simultaneous decrease in blood pressure and hemoglobin (8.9 g/dl) due to a large retroperitoneal hematoma (fig. 1B). Transfusion stabilized the patient's hemodynamic condition. He was discharged 5 days later without major complaints and with an improved walking distance.

Case 2

A 79-yr-old female patient with generalized PAD, severe pain in her lower extremities, polyneuropathy, coronary artery sclerosis, and a history of stroke some years ago presented with symptoms of an acute obstruction of the left femoral arteries. Angiography demonstrated multiple occlusions predominately on the left side but did not reveal an indication for angioplasty or surgical reconstruction. After failure of prostaglandin E1 treatment, the patient was referred for diagnostic LSB 2 weeks later, since her foot pain was unbearable despite morphine medication. In the following 24 h, she complained of an increasing numbness of the entire left leg. Even in the absence of a history of any bleeding disorder, 75 mg/day clopidogrel (Plavix®; Sanofi-Synthelabo, Berlin, Germany) was discontinued 3 days prior to LSB. Seventy-two hours later, the coagulation parameters, including the bleeding time (160 s), were within normal limits. LSB was performed at the L3 level using a 26-gauge needle and checking for any blood aspiration. The first injection of contrast medium revealed a paravertebral displacement. After redirecting the needle position, the typical spread of the solution was demonstrated. Intravascular injection had not been recognized. The application of 5 ml bupivacaine, 0.5%, led to a minor increase in skin temperature (1.5°C) without significant pain relief.

The patient spent her first 9 h on the ward uneventfully and then suddenly complained of burning groin and medial thigh pain. There

Fig. 1. Case 1: (A) Skin hematoma 72 h after sympathetic lumbar blockade. (B) Computed tomography scan (48 h after lumbar sympathetic neurolytic block) showing a large retroperitoneal hematoma (H) with ventromedial displacement of the left kidney (K). Reprinted with permission of the Department of Radiology, CAU Kiel.



were no other pathologic hints (soft abdominal wall; normal peristaltic sounds; blood pressure, 120–130/75 mmHg through 1 h; heart rate, 70–80 beats/min). Administration of a low-dose opiate decreased her pain remarkably, and 2 h later she was walking on the ward without complaints. However, another hour later (*i.e.*, 12 h after LSB), she was found pulseless. Resuscitation attempts were unsuccessful.

The autopsy revealed a massive coagulated hematoma (about 2.3–3 l) beneath the left psoas muscle with enlarged retroperitoneal hemorrhage (fig. 2). There were no visible puncture lesions in larger vessels. Severe atherosclerosis was detected in the aorta and in most arteries of the left leg. Due to a recent thrombosis of the left iliac artery, collateral vessels were enlarged.

Discussion

The blockade of the lumbar sympathetic chain *versus* a surgical lumbar sympathectomy has proven to be a safe technique. It has reduced mortality when using radiographic control or computed tomography (CT) guidance combined with application of contrast medium for evaluation of the spread of the solution. However, there are a few reports of serious complications of LSB due to failed puncture or application of the neurolytic agent too close to the spinal cord or the ureter.⁸ Out of more than 2,100 patients with LSB, 5 deaths have been reported, 2 of which were due to severe bleeding under anticoagulation.^{8–11} Although puncture of arterial or venous vessels may be more frequent than reported, large hematomas are obviously uncommon and of minor consequence in the absence of other risk factors.⁸

We have performed more than 2,000 LSBs since 1985, performing the conventional dorsal-lateral approach on one or two levels under plain radiographic control or CT guidance. All injections but the two reported cases were without any clinically relevant bleedings. Although we did not specifically look for these complications, all patients were monitored on a ward for 24–48 h. In addition, an internal quality assurance was performed,

including the routine measurement of blood hemoglobin and urine screening for erythrocytes. No cases of injury to the ureter were revealed, as determined by urine screening for erythrocytes. The incidence of other side effects was also minimal. Genitofemoral neuralgia after neurolytic LSB was less than 0.8% *versus* 1–30%




Fig. 2. Case 2. Large retroperitoneal hematoma revealed by autopsy. MP = iliopsoas muscle.

reported elsewhere.^{9,12} Therefore, the dramatic course of these two patients taking antiplatelet agents suffering from severe bleeding after LSB was unexpected and alarming, more so since a clear cause-and-effect relationship could not be established.

Ticlopidine and clopidogrel are irreversible inhibitors of adenosine diphosphate-induced platelet aggregation. As a consequence, coagulation will gradually return to its normal function only after the affected platelets are being replaced within 5–7 days of discontinuation of treatment. These drugs have been reported to be more effective than aspirin in the prevention of atherosclerotic events in patients with a history of a recent stroke, myocardial infarction, severe PAD, or vascular stent implantation.^{1,2} Although purpura or epistaxis was observed in 2.9–5.3% of patients receiving clopidogrel, there was a significant reduction in the total number of bleeding events compared to aspirin.³ The new irreversible platelet aggregation inhibitors are therefore considered to be the gold standard for patients with manifested symptoms of atherosclerotic disease.

It remains unclear, however, in which way platelet function is affected in patients taking these new drugs undergoing surgery or other invasive therapeutic approaches. There are still no reliable tests available, including testing for bleeding time, to address this problem, to guide antiplatelet therapy, to calculate the individual risk of bleeding, and, especially, to determine if the coagulation has returned to normal after cessation of the platelet inhibitors.^{3,**} Drug companies therefore recommend stopping ticlopidine and clopidogrel 7 days prior to elective surgery. There are no studies regarding the safety of epidural or spinal anesthesia in patients during or immediately after discontinuation of antiplatelet drug treatment.^{**} Only one case report describes a subarachnoid hematoma following a very difficult lumbar puncture in a patient receiving ticlopidine.⁵

In the presented cases, it remains uncertain whether the platelet inhibitors were the direct cause of the retroperitoneal bleeding. An intravascular positioning of the needle was noted in the first patient, although puncturing a vessel with a 25-gauge needle is usually of little clinical consequence. Lumbar arteriography used to be performed with 16- to 20-gauge cannulas but with low rates of bleeding complications.

In the second patient, autopsy revealed no vascular lesions. The prolonged interval of 9 h between LSB and the onset of early signs (*e.g.*, groin and femoral pain) and the patient's general good health until then are strong arguments against the assumption of a needle-induced vessel lesion with consecutive bleeding of more than 2.5 l. The hemorrhagia could have been a consequence of increased pressure in the paraaortal collateral vessels due to the progressive as well as recent thrombotic occlusion of the left femoral artery revealed on autopsy. Although clopidogrel had been discontinued 4 days pre-

viously, it still may have exerted some effects and, as such, may have been a synergistic factor in this scenario.

Since LSB is a common pain clinic procedure, it is important for other clinicians to be aware of the potential for severe hematomas following nerve blocks in patients taking platelet aggregation inhibitors. Still, LSB is considered to be a very safe technique with great benefits for high-risk patients with otherwise untreatable pain due to PAD. Therefore, the presented cases have led us to make the following recommendations:

1. Since there is a lack of reliable and sensitive tests to monitor coagulation,^{4,**} irreversible platelet inhibitors should be discontinued for at least 7 days prior to any invasive technique, in case any hemorrhage is not controllable by external compression. Following the recent addendum of the American Society of Regional Anesthesia for epidural and spinal injection, this precaution should be extended to LSB and celiac block.^{**} In case of a high thrombotic risk, patients should be switched to a different therapeutic regimen with heparin up to 6 h prior to the blockade.
2. Patients with an increased risk of bleeding, *i.e.*, taking any platelet inhibitor or with a history of recent progression of PAD, should be closely monitored as inpatients for 24 h after LSB.⁴
3. Groin pain and, particularly, pain at the medial side of the thigh seem to be early signs of a bleeding complication after LSB. The side of the thigh pain indicates which side is affected in cases of bleeding into the iliopsoas muscle, as explained by the distribution area of the genitofemoral nerve. If the patient experiences a painful sensation such as that described in this report, an ultrasound examination or a more sensitive CT scan of the retroperitoneum should be performed immediately.

References

1. Taniuchi M, Kurz HI, Lasala JM: Randomized comparison of ticlopidine and clopidogrel after intracoronary stent implantation in a broad patient population. *Circulation* 2001; 104:539–43
2. Bogousslavsky J: Benefit of ADP receptor antagonists in atherothrombotic patients: New evidence. *Cerebrovasc Dis* 2001; 11(suppl 2):5–10
3. Bhatt DL, Hirsch AT, Ringleb PA, Hacke W, Topol EJ: Reduction in the need for hospitalization for recurrent ischemic events and bleeding with clopidogrel instead of aspirin. CAPRIE investigators. *Am Heart J* 2000; 140:67–73
4. Cobos E, Cruz JC, Day M: Etiology and management of coagulation abnormalities in the pain management patient. *Curr Rev Pain* 2000; 4:413–9
5. Urmey WF, Rowlingson JC: Do antiplatelet agents contribute to the development of perioperative spinal hematoma? *Reg Anesth Pain Med* 1998; 23(suppl 2):146–51
6. Gleim M, Maier C, Melchert U: Lumbar neurolytic sympathetic blockades provide immediate and long-lasting improvement of painless walking distance and muscle metabolism in patients with severe peripheral vascular disease. *J Pain Symptom Manage* 1995; 10:98–104
7. Alexander JP: Chemical lumbar sympathectomy in patients with severe lower limb ischaemia. *Ulster Med J* 1994; 63:137–43
8. Ernst S, Heindel W, Fischbach R, Gawenda M, Langen HJ, Neubauer S, Krahe T: Komplikationen der CT-gesteuerten lumbalen Sympathikolyse: Eigene Erfahrungen und Literaturübersicht. *Rofo Fortschr Geb Röntgenstr Neuen Bildgeb Verfahr* 1998; 168:77–83

9. Reid W, Watt JK, Gray TG: Phenol injection of the sympathetic chain. *Br J Surg* 1970; 57:45-50
10. Coubret PH, Lermusiaux P, Becquemin JP, Etienne G, Mellièrre D: La sympatholyse au phénol a-t-elle des indications? *J Mal Vasc* 1985; 10:357-61
11. Dreyfus A, Fondras JC, Loubrieu G, Ntarundenga U: Expérience de la

sympatholyse chimique lombaire dans les artériopathies des membres inférieurs. *Agressologie* 1990; 31:207-9

12. Sayson SC, Ramamurthy S, Hoffman J: Incidence of genitofemoral nerve block during lumbar sympathetic block: Comparison of two lumbar injection sites. *Regional Anesth* 1997; 22:569-74

Anesthesiology 2002; 97:743-5

© 2002 American Society of Anesthesiologists, Inc. Lippincott Williams & Wilkins, Inc.

Asynchronous Independent Intermittent Positive Pressure Ventilation as a Solution to Refractory Hypoxemia during Chest Surgery

Micha Shamir, M.D.,* Yaacov Gozal, M.D.,† Yuval Weiss M.D.,‡ Lev Ronin, M.D.,§ Jacob Raphael, M.D.¶

IMPROVING surgical exposure during thoracic operations in the lateral decubitus position is one of the indications for one-lung ventilation (OLV).¹ OLV provides satisfactory oxygenation in the majority of patients. However, hypoxemia may develop secondary to the obligatory right-to-left transpulmonary shunt through the nonventilated, nondependent lung.^{2,3} Continuous positive airway pressure (CPAP),⁴ high-frequency jet ventilation,⁵ intermittent manual inflations,⁶ and partial ventilation^{7,8} to the nondependent lung have been used to improve oxygenation during OLV. Positive end-expiratory pressure (PEEP)¹ and nitric oxide⁹ application to the dependent lung were used for the same objective. We report a case of severe hypoxemia related to OLV during anterior thoracic spine fusion that resolved only with the use of differential intermittent positive pressure ventilation.

Case Report

A 63-yr-old man was diagnosed as suffering from T5-T6 vertebrae osteomyelitis and paravertebral abscess. His past medical history included chronic renal failure, non-insulin-dependent diabetes mellitus, hypertension, hypothyroidism, and epilepsy. The patient underwent an uneventful emergent abscess drainage and posterior spine fusion in the prone position. On the third postoperative day, the patient required a second emergent operation due to worsening of paraparesis. Anterior thoracic spine fusion *via* right thoracotomy was indicated. Blood tests were significant for abnormal results of renal function tests. Arterial blood gases on the day before were as follows (fraction of inspired oxygen [FIO₂], 0.21): pH, 7.37; partial pressure of carbon dioxide (Pco₂), 39 mmHg; and partial pressure of oxygen (Po₂), 84 mmHg. A chest radiograph prior to surgery showed atelectasis of the left lower lobe (fig. 1). Anesthesia was induced with midazolam, etomidate, and fentanyl intravenously. Vecuronium bromide was administered to facilitate tracheal intubation. The trachea was intubated

with a 41-French, left-sided, double-lumen tube (Broncho-cath™; Mallinckrodt Medical, Athlone, Ireland). Tube positioning was confirmed by auscultation and fiberoptic bronchoscopy in the supine as well as in the left lateral decubitus position. Patient monitoring included (in addition to standard monitoring) radial artery catheter for invasive blood pressure measurement and a left internal jugular vein catheter. Anesthesia was maintained with isoflurane and 50% nitrous oxide in oxygen supplemented by intermittent boluses of fentanyl and vecuronium. The lungs were ventilated with a tidal volume of 10 ml/kg; respiratory rate was adjusted to maintain normocapnia and PEEP of 4 cm H₂O. Arterial blood gas values and ventilation parameters are shown in table 1.

Several minutes before nondependent right lung deflation, oxygen concentration was raised to 100%. Once the chest was opened and the right lung deflated, a significant decrease in the arterial saturation (from 98% to 63%) was noted. Oxygenation did not improve significantly either by 10 cm H₂O CPAP applied to the nondependent lung initially or by 10 cm H₂O PEEP application to the dependent lung later. Fiberoptic bronchoscopy confirmed proper positioning of the double-lumen tube without mucous plugging or increased secretions. Restoration of two-lung ventilation improved oxygen saturation, but surgery could not continue because the right lung obstructed the surgical field. High-frequency jet ventilation was considered, but the ventilator was unavailable.

At this stage, differential lung ventilation was initiated as follows (table 1): the dependent lung was ventilated by the anesthesia machine with a tidal volume of 6 ml/kg, a respiratory rate of 14 breaths/min, a PEEP of 10 cm H₂O, and an FIO₂ of 1.0. The nondependent lung was ventilated by a volume control, battery-powered, servo controlled, transport ventilator (Flight III; Flight Medical, Lod, Israel) with a tidal volume of 1 ml/kg, a respiratory rate of 20 breaths/min, a PEEP of 0 cm H₂O, and an FIO₂ of 1.0. Peak inspiratory pressures were 35 and 25 cm H₂O, respectively. Under this ventilation mode, oxygenation increased dramatically to 100% oxygen saturation (table 1). The right, nondependent lung volume was similar to that seen without ventilation; respiratory inflations resulted in small volume changes that did not interfere with the surgical exposure. The operation continued uneventfully, and the patient was extubated in the operating room at the end of surgery. The patient was discharged from the intensive care unit 24 h later and transferred back to the ward.

Discussion

One-lung ventilation is routinely used during thoracic surgery. It provides good exposure and adequate surgical conditions. However, OLV creates an obligatory right-to-left transpulmonary shunt through the nondependent, nonventilated lung and increases alveolar-to-arterial oxygen tension difference, so hypoxemia may develop. Blood flow to the nondependent lung is usually reduced by gravity, lung collapse, surgeon manipulation,

* Staff Anesthesiologist, † Senior Lecturer in Anesthesia, § Resident in Anesthesia, Department of Anesthesiology and Critical Care Medicine, ‡ Senior in Anesthesia and Assistant to Hospital Director, Administration.

Received from Hadassah University Hospital, Jerusalem, Israel. Submitted for publication December 10, 2001. Accepted for publication March 15, 2002. Support was provided solely from institutional and/or departmental sources.

Address reprint requests to Dr. Shamir: Department of Anesthesiology and Critical Care Medicine, Hadassah University Hospital, PO Box 12000, Jerusalem 91120, Israel. Address electronic mail to: shamir61@bezeqint.net. Individual article reprints may be purchased through the Journal Web site, www.anesthesiology.org.

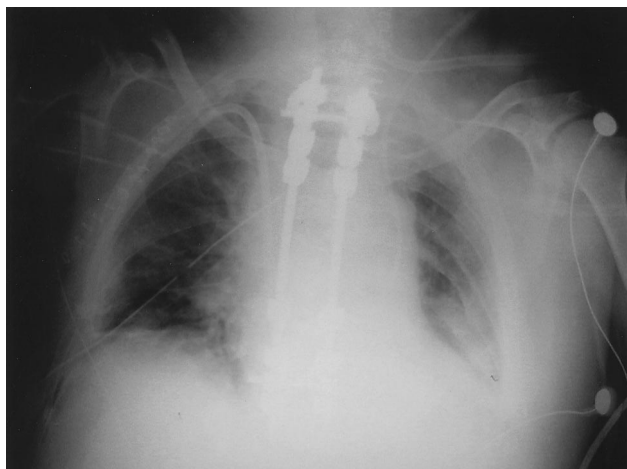


Fig. 1. Preoperative chest radiograph.

and by active hypoxic pulmonary vasoconstriction, thus decreasing the shunt.³ Hence, conventional ventilation of the dependent lung with 100% oxygen is usually associated with acceptable arterial oxygen tension (P_{aO_2}) values. If hypoxemia does occur, optimization of oxygenation can be obtained in several ways.^{4,5} CPAP with 100% oxygen to the collapsed lung is the most effective means for correction of hypoxemia during OLV.¹⁰ PEEP applied to the ventilated lung can recruit collapsed alveoli and improve oxygenation. However, PEEP increases the dependent lung alveolar pressure and pulmonary vascular resistance, thus diverting blood to the nondependent, nonventilated lung and, in turn, worsening the shunt and hypoxemia.¹ The result of PEEP application to the dependent lung is therefore unpredictable, usually favorable only if the dependent lung is basically ill.¹¹

Baraka⁷ described a method of differential intermittent positive pressure ventilation by partial occlusion of the adapter limb to the nondependent lung while maintaining unrestricted ventilation of the dependent lung. Yamamura *et al.*⁸ invented a complicated, large, and heavy device, which enables the diversion of different

proportions of the tidal volume to the nondependent lung, thus ventilating it differentially. Both methods lack the ability to monitor and control precisely volumes and pressures.

In our patient, hypoxemia developed shortly after instituting OLV. The common practices of treating hypoxemia during OLV were taken (100% oxygen, reconfirmation of tube patency and proper position, CPAP to the nondependent lung and then PEEP to the dependent lung) but failed to improve oxygenation. In this report, we describe a simple technique for differential lung ventilation that improved severe hypoxemia related to OLV. Our technique has three major advantages. First is the use of simple equipment, which is highly accessible. Second is the ability to determine and monitor precisely ventilation parameters. The third advantage is that using the anesthesia machine to ventilate the dependent lung keeps the ability to maintain inhaled anesthesia (considering the negative effect on the hypoxic pulmonary vasoconstriction). The small tidal volume applied to the nondependent lung yielded small changes in the lung volume, which did not interfere with the surgical exposure. Peak inspiratory pressure of the nondependent lung was high relative to the small tidal volume (25 cm H_2O). This high peak inspiratory pressure can be attributed to low compliance of a lung that was deflated for a while, small diameter of the tracheal lumen, direct surgical pressure, or any combination of these three explanations. It seems that gas trapping was not evident since lung volume was small and did not increase with time. In addition, a slightly increased respiratory rate (20 breaths/min) should allow sufficient time for small tidal volume expiration (auto PEEP could not be measured with our equipment). Blood pressure did not change while the lungs were ventilated differentially; therefore, there was no need for synchronization between the ventilators.¹¹

In conclusion, this case demonstrates the use of asynchronous differential intermittent positive pressure ven-

Table 1. Ventilation Parameters and Blood Gases during Two-lungs Ventilation, One-lung Ventilation, and Differential Intermittent Positive-pressure Ventilation

	Two-lung Ventilation	One-lung Ventilation		Differential IPPV		Two-lung Ventilation
		Dependent Lung	Nondependent Lung	Dependent Lung	Nondependent Lung	
FiO_2	0.5	1.0	1.0	1.0	1.0	1.0
PEEP (cm H_2O)	4	10	10	10	0	0
Tidal volume (ml)	500	300	0	300	50	700
Respiratory rate (breaths/min)	14	16	0	14	20	14
PIP (cm H_2O)	25	35	—	35	25	28
pH	7.27		7.27		7.32	7.31
P_{CO_2} (mmHg)	44		51		38	34
PO_2 (mmHg)	158		37		276	336
O_2Sat	99		63		100	100

IPPV = intermittent positive-pressure ventilation; FiO_2 = fraction of inspired oxygen; PEEP = positive end-expiratory pressure; PIP = peak inspiratory pressure; P_{CO_2} = partial pressure of carbon dioxide; PO_2 = partial pressure of oxygen; O_2Sat = oxygen saturation.

tilation as a simple and useful way to improve oxygenation during OLV.

References

1. Brodsky JB, Fitzmaurice B: Modern anesthetic techniques for thoracic operations. *World J Surg* 2001; 25:162-6
2. Torda TA, McCulloch CH, O'Brien HD, Wright JS, Horton DA: Pulmonary venous admixture during one-lung anaesthesia. *Anaesthesia* 1974; 29:272-9
3. Benumof JL: Conventional and differential lung management of one-lung ventilation. *Anesthesia for Thoracic Surgery*. Edited by Benumof JL. Philadelphia, WB Saunders, 1987, pp 271-87
4. Capan LM, Turndorf H, Patel C, Ramanathan S, Acinapura A., Chalon J: Optimization of arterial oxygenation during one-lung anesthesia. *Anesth Analg* 1980; 59:847-51
5. El-Baz NM, Kittle CF, Faber LP, Welshe W: High frequency ventilation with an uncuffed endobronchial tube: A new technique for one-lung anesthesia. *J Thorac Cardiovasc Surg* 1982; 84:823-8
6. Jedeikin R, Olsfanger D, Shachor D: Intraoperative anaesthetic management of hypoxaemia during transthoracic endoscopic sympathectomy. *Eur J Surg Suppl* 1994; 572:23-5
7. Baraka A: Differential lung ventilation as an alternative to one-lung ventilation during thoracotomy. *Anaesthesia* 1994; 49:881-2
8. Yamamura T, Furumido H, Saito Y: A single unit device for differential lung ventilation with only one anesthesia machine. *Anesth Analg* 1985; 64:1017-20
9. Wilson WC, Kapelanski DP, Benumof JL, Newhart JW, Johnson FW, Chanick RN: Inhaled nitric oxide (40 ppm) during one-lung ventilation, in the lateral decubitus position, does not decrease pulmonary vascular resistance or improve oxygenation in normal patients. *J Cardiothorac Vasc Surg* 1997; 22:172-7
10. Cohen E, Eisenkraft JB: Positive end-expiratory pressure during one-lung ventilation improves oxygenation in patients with low arterial oxygen tensions. *J Cardiothorac Vasc Anesth* 1996; 10:578-82
11. Thomas AR, Bryce TL: Ventilation in the patient with unilateral lung disease. *Crit Care Clin* 1998; 14:743-73

Anesthesiology 2002; 97:745-9

© 2002 American Society of Anesthesiologists, Inc. Lippincott Williams & Wilkins, Inc.

Cardiac Arrest on Induction of Anesthesia Due to Triple Vessel Coronary Artery Disease despite a "Negative" Angiogram

Rashmi N. Mueller, M.D.,* Barry F. Uretsky, M.D.,† Lei Hao, M.D.,‡ David H. Walker, M.D.,§ Gregory E. Panomitos, M.D.,* Mark H. Zornow, M.D.||

CORONARY angiography is considered to be the clinical gold standard for the characterization of coronary artery atherosclerosis. We describe a case of a patient with a history of angina whose coronary angiogram identified only minimal lesions. Six months later, the patient had a cardiac arrest during induction of anesthesia. Postmortem evaluation revealed severe (70-90%) stenoses of all three major coronary arteries. The failure of the preoperative angiogram to detect the severity of this patient's disease is discussed.

Case Report

A 47-yr-old, 61-kg man was scheduled to undergo revision of a left femoral to popliteal bypass graft. In addition to his chief complaint of claudication, the patient had chest pain typical of angina. He had several risk factors for coronary artery disease, including hypertension, hyperlipidemia, a 20 pack-year smoking history, and a positive family history. Serial electrocardiograms had shown no specific ischemic changes. Cardiac enzymes, measured during a recent hospital admission for angina, were normal.

An exercise stress echocardiogram was nondiagnostic, secondary to the patient's decreased ability to exercise. His ejection fraction was estimated to be 50%. No other test of functional capacity was performed. In September 2000, he underwent a left heart catheterization and coronary angiography. The angiogram showed diffuse luminal

irregularities in both the left and right coronary arteries; however, the maximal lesion was interpreted as a 40% stenosis of the right coronary artery (figs. 1A-C).

The patient's daily medications included isosorbide (10 mg three times daily), metoprolol (25 mg twice daily), aspirin (325 mg daily), and sublingual nitroglycerin (as needed). He underwent uneventful general anesthesia in October 2000 for a left femoral-popliteal bypass. This attempt at revascularization was unsuccessful, and the patient was scheduled for a revision.

In January 2001, cardiologists again noted that the recent angiogram (obtained in September 2000) had shown noncritical disease of the right coronary artery, with maximal stenosis of 40%. The patient was characterized as being "low risk" for surgery. Vasospasm and esophageal spasm were mentioned as possible etiologies for the stable chest pain. Close perioperative monitoring and treatment with nitroglycerin were recommended. Diltiazem, instead of metoprolol, was prescribed; however, the patient did not implement this change.

The patient presented for surgery in March 2001. Preoperatively, his blood pressure was 166/87 mmHg, with a pulse of 80 beats/min. That morning, he had taken metoprolol, isosorbide, and aspirin. As premedication, he received midazolam (2 mg) intravenously. Routine monitors were applied. After preoxygenation, anesthesia was induced with sodium thiopental (375 mg), lidocaine (60 mg), and fentanyl (100 µg). Succinylcholine (100 mg) was used to facilitate tracheal intubation. The first blood pressure after intubation was 176/105 mmHg, with a pulse of 101 beats/min. Isoflurane (1%) and esmolol (22 mg) were administered. Minutes later, the anesthesiologist was unable to obtain a blood pressure. The patient had no palpable pulse, although the electrocardiogram showed a rate of 95 beats/min. This rhythm quickly deteriorated to a wide-complex tachycardia and then either ventricular fibrillation or asystole. Isoflurane was discontinued, and cardiopulmonary resuscitation was initiated. Defibrillation was attempted three times in rapid succession with 360 J. Ventilation continued with 100% oxygen. Epinephrine, lidocaine, magnesium, hydrocortisone, amiodarone, atropine, glucagon, and calcium chloride were administered. Arterial and central venous cannulation were established during the resuscitation. Initial arterial blood gas measurements were pH, 7.44; arterial carbon dioxide tension (Paco₂), 14 mmHg; and arterial oxygen tension (PaO₂), 544 mmHg, with a serum potassium of 3.7 mEq/L.

* Assistant Professor, || Professor and Vice-Chairman for Clinical Affairs, Department of Anesthesiology, † Professor, Division of Cardiology, Department of Internal Medicine, ‡ Resident Physician, § Professor and Chairman, Department of Pathology.

Received from the Department of Anesthesiology, The University of Texas Medical Branch, Galveston, Texas. Submitted for publication December 4, 2001. Accepted for publication March 19, 2002. Support was provided solely from institutional and/or departmental sources.

Address reprint requests to Dr. Mueller: Department of Anesthesiology, University of Texas Medical Branch, 301 University Boulevard, Galveston, Texas 77555-0591. Address electronic mail to: ramuelle@utmb.edu. Individual article reprints may be purchased through the Journal Web site, www.anesthesiology.org.

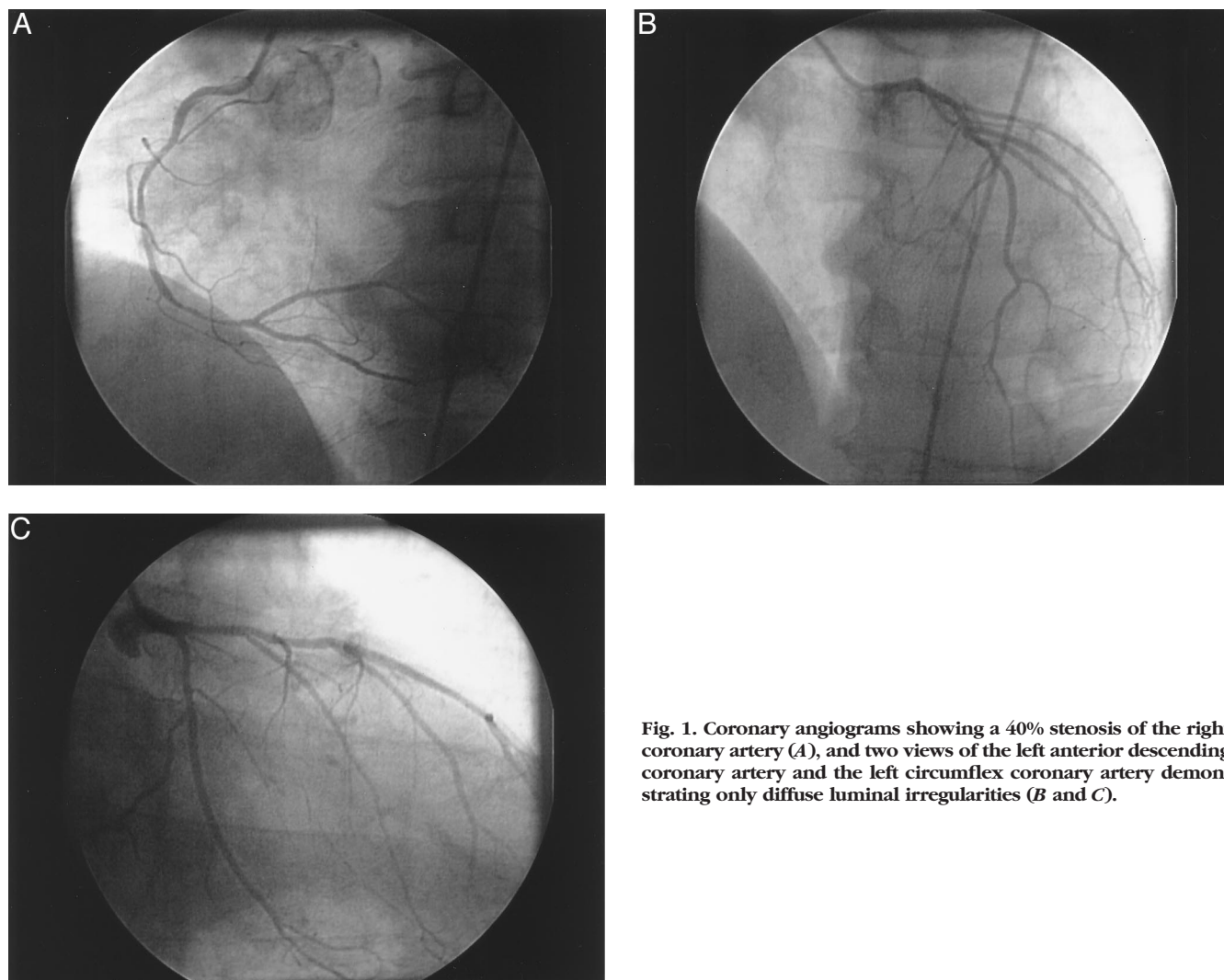


Fig. 1. Coronary angiograms showing a 40% stenosis of the right coronary artery (A), and two views of the left anterior descending coronary artery and the left circumflex coronary artery demonstrating only diffuse luminal irregularities (B and C).

Additional attempts at defibrillation were made. A chest radiograph showed no pneumothorax. After approximately 40 min of chest compressions, the electrocardiogram showed a wide-complex rhythm followed by sinus tachycardia, with a systolic blood pressure greater than 200 mmHg. The patient was transported to the intensive care unit on lidocaine, nitroglycerin, and epinephrine infusions.

Later that day, the patient suffered two additional episodes of ventricular fibrillation, which were terminated with electrical defibrillation. Cardiac enzymes, electrocardiography, and echocardiography were all consistent with an anteroapical myocardial infarction. The next morning, he was awake and able to follow verbal commands. Two days after the initial cardiac arrest, he developed a ventricular tachycardia, which evolved into ventricular fibrillation. Resuscitation was attempted for 30 min without success.

An autopsy showed the left ventricle of the heart to be mildly hypertrophied. The myocardium of the anterior portion of the left ventricle was acutely infarcted. There was also a small, well-healed scar in the anterior left ventricular wall. The coronary arteries had severe concentric atherosclerotic plaques throughout their lengths. There was 90% luminal narrowing of the left anterior descending coronary artery, 80% of the left circumflex artery, and 70% of the right coronary artery at 1.5 cm, 1.8 cm, and 1.5 cm, respectively, from the arterial origins (figs. 2A-C). There was no evidence of hemorrhage, thrombosis, or rupture within the plaques.

Discussion

Coronary artery angiography is considered the definitive study in the evaluation of coronary atherosclerosis, impacting medical and surgical management. Our patient had physical symptoms strongly suggestive of myocardial ischemia and multiple risk factors for coronary artery disease. However, an angiogram performed 6 months prior to planned surgery falsely reassured clinicians involved in his perioperative care about the extent of coronary atherosclerosis. The maximal lesion noted by angiography was 40% stenosis in the right coronary artery, with mild irregularity of the left coronary artery. Postmortem examination, surprisingly, revealed severe diffuse three-vessel disease.

The limitations of coronary artery angiography have been discussed in the cardiology literature.¹⁻³ The percentage of stenosis is calculated by comparing the lumen of the stenotic area to that of an adjacent, presumably healthy, arterial segment. Coronary intravascular ultra-

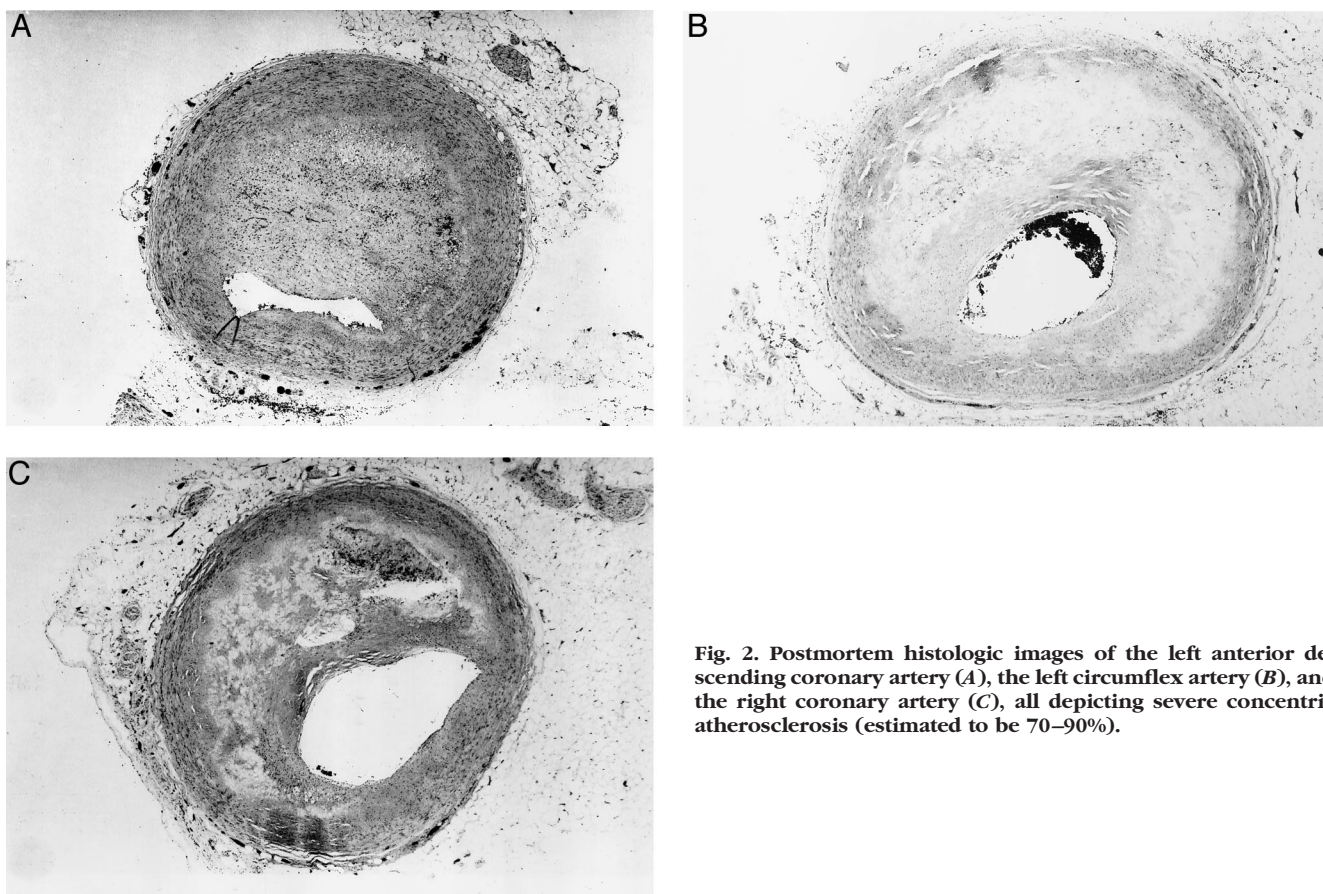


Fig. 2. Postmortem histologic images of the left anterior descending coronary artery (A), the left circumflex artery (B), and the right coronary artery (C), all depicting severe concentric atherosclerosis (estimated to be 70–90%).

sound, which depicts cross-sectional tomographic views of the vascular wall and lumen, has shown that only 6.8% of 884 angiographically normal reference segments were actually normal.⁴ Therefore, in patients with diffuse disease, angiographers often compare severely atherosclerotic areas to less diseased ones. This contributes to underestimation of the actual stenosis. Diffuse, concentric, and symmetric involvement of the vessel may also present the illusion of a smaller artery, without focal constriction, in the two-dimensional angiogram.^{1,3}

There are other conditions that may confound the angiographic impression. The Glagov phenomenon is compensatory dilatation of atherosclerotic arterial wall, which is thought to be due to rearrangement of medial smooth muscle cells.^{5,6} This arterial remodeling increases the cross-sectional area and prevents functional narrowing until 40–50% of the cross-section is occupied by plaque. Despite the presence of mild to moderate disease, the lumen will appear almost normal on angiography.^{5,7} Further plaque enlargement will decrease the arterial lumen.

Numerous other factors associated with unreliable angiographic data include complexity of lesions (eccentric or slit-like lesions are troublesome), distension of vessels at systemic pressures, dye distension, intraobserver or interobserver variability, overlapping of branches, foreshortening, disease at bifurcations, flush occlusions, in-

adequate dye filling, vasospasm (overestimates), blurring due to motion during the cardiac cycle, and resolution of angiographic equipment.^{1–3,8} Lesions in the left main coronary artery are especially difficult to detect.⁹ Coronary angiography is even less reliable after mechanical intervention associated with angioplasty or stent deployment.^{1,2} Quantitative computerized angiography has most of the same shortcomings.^{1,10} The two-dimensional nature of conventional angiography contributes to many of these problems. Physiologic coronary flow reserve, as measured by reactive hyperemia, does not correlate with measurement of percent stenosis on angiography.¹¹ This may be partially explained by underestimated stenosis.

At least 11 studies have described discrepancies between premortem angiographic and postmortem histologic estimations (performed 1 day to 3 yr apart) of the severity of coronary artery disease.^{9,12–22} Angiography generally underestimates lesion severity. Conversely, postmortem pathology tends to overestimate it. Pathologists assess the percentage of stenosis by dividing luminal area by the total area occupied by plaque.^{6,8} When arterial remodeling occurs, the cross-sectional area occupied by the plaque may initially increase, without luminal encroachment. This may lead to overestimation of the percentage of arterial stenosis, compared to the actual decrease in the luminal area. Other factors, such as lack of systemic distending pressure, postmortem

arterial shrinkage, and changes with fixation, may lead to errors. If there has been a sufficiently long interval of time between the two studies, the lesion could have truly progressed. Generally, however, histologic estimates of stenoses are reliable for lesions over 75% in diameter.⁶

In our patient, diffuse concentric atherosclerotic disease had narrowed the entire length of all three coronary arteries. We believe that the degree of stenosis was angiographically underassessed due to the lack of a normal reference segment. The patient presumably had similar coronary artery lesions during his previous surgery. A review of his records revealed that his heart rate was better controlled during the previous anesthetic induction (a resting pulse of 50–60 beats/min, with no increase during induction and laryngoscopy). When he presented for the surgical procedure discussed in this case report, his pulse was 80 beats/min, and it increased to 101 beats/min following tracheal intubation. There were no other significant differences between the conduct of the two anesthetic inductions. It is possible that given his severe degree of coronary vascular compromise, this patient was unable to tolerate even a mild elevation in heart rate.

Since the patient underwent prolonged cardiopulmonary resuscitation, he was not considered a candidate for thrombolytic therapy. He may have benefited from urgent percutaneous transluminal coronary angioplasty. Although it is difficult to reconstruct the decision-making processes involved, it is our suspicion that the cardiologists reviewed his recent angiogram and concluded that there was no lesion that would be amenable to stent placement or dilatation.

This case is a reminder that it is vital to look at the entire clinical picture: the history, signs and symptoms of the patient, as well as his or her functional status, along with the results of an angiogram, if one has been obtained. This is particularly important before a cardiac cause of chest pain is excluded. In retrospect, the extent of compromise of our patient's coronary vessels probably would have been discovered by further testing of his functional capacity, *e.g.*, by a dobutamine stress echocardiogram or an adenosine-thallium scan.

In this instance, coronary intravascular ultrasound may have been a superior diagnostic test since it provides images not only of the lumen, but also of the vessel wall, including the plaque.^{1,4,23} The American College of Cardiology/American Heart Association guidelines for coronary angiography recommend coronary intravascular ultrasound as an alternative imaging modality for the evaluation of patients with characteristic anginal symptoms and positive results of a functional study, with no focal stenosis, or with only mild coronary artery disease on angiography.²⁴ Another advantage of intravascular ultrasound over angiography is that it has the potential to detect soft, eccentric, lipid-rich plaques that may not

be causing significant stenoses.²⁵ These lesions may be more likely to be implicated in acute coronary syndromes as a result of acute plaque rupture and vessel occlusion.^{8,26} However, expense and availability may limit widespread use of this diagnostic tool at present. Furthermore, intravascular ultrasound requires instrumentation of the coronary artery and carries with it the associated risk of arterial damage or spasm. This report emphasizes that although coronary angiography is considered the best clinical tool to detect coronary atherosclerosis, it has limitations and must be used in conjunction with all other pertinent data.

The authors wish to thank Marjorie R. Grafe, M.D., Ph.D. (Professor and Vice-Chair, Department of Pathology, The University of Texas Medical Branch, Galveston, Texas), for her valuable assistance in providing the photomicrographs in this article.

References

1. Topol EJ, Nissen SE: Our preoccupation with coronary luminology: The dissociation between clinical and angiographic findings in ischemic heart disease. *Circulation* 1995; 92:2333–42
2. Nissen SE: Shortcomings of coronary angiography and their implications in clinical practice. *Cleve Clin J Med* 1999; 66:479–85
3. Schwartz L, Bourassa MG: Evaluation of patients with chest pain and normal coronary angiograms. *Arch Intern Med* 2001; 161:1825–33
4. Mintz GS, Painter JA, Pichard AD, Kent KM, Satler LF, Popma JJ, Chuang YC, Bucher TA, Sokolowicz LE, Leon MB: Atherosclerosis in angiographically "normal" coronary artery reference segments: An intravascular ultrasound study with clinical correlations. *J Am Coll Cardiol* 1995; 25:1479–85
5. Glagov S, Weisenberg E, Zarins CK, Stankunavicius R, Koletts GJ: Compensatory enlargement of human atherosclerotic coronary arteries. *N Engl J Med* 1987; 316:1371–5
6. Davies MJ: Coronary artery remodelling and the assessment of stenosis by pathologists. *Histopathology* 1998; 33:497–500
7. Stiel GM, Stiel LS, Schofer J, Donath K, Mathey DG: Impact of compensatory enlargement of atherosclerotic coronary arteries on angiographic assessment of coronary artery disease. *Circulation* 1989; 80:1603–9
8. Fishbein MC, Siegel RJ: How big are coronary atherosclerotic plaques that rupture? *Circulation* 1996; 94:2662–6
9. Isner JM, Kishel J, Kent KM, Ronan JA, Ross AM, Roberts WC: Accuracy of angiographic determination of left main coronary arterial narrowing. *Circulation* 1981; 63:1056–64
10. Escaned J, Baptista J, Di Mario C, Haase J, Ozaki Y, Linker DT, de Feyter PJ, Roelandt JR, Serruys PW: Coronary heart disease/atherosclerosis/myocardial infarction: Significance of automated stenosis detection during quantitative angiography: Insights gained from intracoronary ultrasound imaging. *Circulation* 1996; 94:966–72
11. White CW, Wright CB, Doty DB, Hiratzka LF, Eastham CL, Harrison DG, Marcus ML: Does visual interpretation of the coronary angiogram predict the physiologic importance of a coronary stenosis? *N Engl J Med* 1984; 310:819–24
12. Blankenhorn DH, Curry PJ: The accuracy of arteriography and ultrasound imaging for atherosclerosis measurement. *Arch Pathol Lab Med* 1982; 106:483–9
13. Hale G, Jefferson K: Technique and interpretation of selective coronary arteriography in man. *Br Heart J* 1963; 25:644–54
14. Kemp HG, Evans H, Elliott WC, Gorlin R: Diagnostic accuracy of selective coronary cineangiography. *Circulation* 1967; 36:526–33
15. Vlodaver Z, Frech R, Van Tassel RA, Edwards JE: Correlation of the antemortem coronary arteriography and the postmortem specimen. *Circulation* 1973; 47:162–9
16. Grondin CM, Dyrda I, Pasternak A, Campeau L, Bourassa MG, Lesperance J: Discrepancies between cineangiographic and postmortem findings in patients with coronary artery disease and recent myocardial revascularization. *Circulation* 1974; 49:703–8
17. Schwartz JN, Kong Y, Hackel DB, Bartel AG: Comparison of angiographic and postmortem findings in patients with coronary artery disease. *Am J Cardiol* 1975; 36:174–8
18. Hutchins GM, Bulkley BH, Ridolfi RL, Griffith LS, Lohr FT, Piasio MA: Correlation of coronary arteriograms and left ventriculograms with postmortem studies. *Circulation* 1977; 56:32–7
19. Galbraith JE, Murphy ML, De Soyza N: Coronary angiogram interpretation: Interobserver variability. *JAMA* 1978; 240:2053–9
20. Arnett EN, Isner JM, Redwood DR, Kent KM, Baker WP, Ackerstein H,

Roberts WC: Coronary artery narrowing in coronary heart disease: Comparison of cineangiographic and necropsy findings. *Ann Intern Med* 1979; 91:350-6

21. Waller BF, Roberts WC: Amount of narrowing by atherosclerotic plaque in 44 nonbypassed and 52 bypassed major epicardial coronary arteries in 32 necropsy patients who died within 1 month of aortocoronary bypass grafting. *Am J Cardiol* 1980; 46:956-62

22. Dietz WA, Tobis JM, Isner JM: Failure of angiography to accurately depict the extent of coronary artery narrowing in three fatal cases of percutaneous transluminal coronary angioplasty. *J Am Coll Cardiol* 1992; 19:1261-70

23. Nissen SE, Gurley JC, Grines CL, Booth DC, McClure Rick, Berk M, Fischer C, DeMaria AN: Intravascular ultrasound assessment of lumen size and wall morphology in normal subjects and patients with coronary artery disease. *Circulation* 1991; 84:1087-99

24. Scanlon PJ, Faxon DP, Audet A, Carabello B, Dehmer GJ, Eagle KA, Legako

RD, Leon DF, Murray JA, Nissen SE, Pepine CJ, Watson RM, Ritchie JL, Gibbons RJ, Chaitlin MD, Eagle KA, Gardner TJ, Garson A, Russell RO, Ryan TJ, Smith SC: ACC/AHA guidelines for coronary angiography: Executive summary and recommendations: A report of the American College of Cardiology/American Heart Association Task Force on practice guidelines (Committee on Coronary Angiography). *Circulation* 1999; 99:2345-57

25. Yamagishi M, Terashima M, Awano K, Kijima M, Nakatani S, Daikoku S, Ito K, Yasumura Y, Miyatake K: Morphology of vulnerable coronary plaque: Insights from follow-up of patients examined by intravascular ultrasound before an acute coronary syndrome. *J Am Coll Cardiol* 2000; 35:106-11

26. Ambrose JA, Tannenbaum MA, Alexopoulos D, Hjemdahl-Monsen CE, Leavy J, Weiss M, Borrico S, Gorlin R, Fuster V: Angiographic progression of coronary artery disease and the development of myocardial infarction. *J Am Coll Cardiol* 1988; 12:56-62