

Nerve Root Inflammation Demonstrated by Magnetic Resonance Imaging in a Patient with Transient Neurologic Symptoms after Intrathecal Injection of Lidocaine

Alexander Avidan, M.D.,* Moshe Gomori, M.D.,† Elyad Davidson, M.D.‡

TRANSIENT neurologic symptoms after intrathecal injection of lidocaine are common. The main symptoms are severe pain and dysesthesia in the buttocks and legs after recovery from spinal anesthesia. The symptoms typically resolve within 1 week. No definitive etiology has been established until now. We report findings on magnetic resonance imaging (MRI) of a patient with transient neurologic symptoms after spinal anesthesia with lidocaine that indicated a local inflammatory process as the possible etiology for this symptom.

Case Report

A 60-yr-old healthy male patient (American Society of Anesthesiologists physical status class I) underwent excision of a perineal condylomata under spinal anesthesia. Anesthesia was performed with the patient in the sitting position with a 27-gauge pencil-point spinal needle (te me na SARL, Bondy, France) and 50 mg hyperbaric lidocaine (AstraZeneca, London, United Kingdom). Dural puncture was achieved in the first attempt, and no paresthesias were elicited. The hyperbaric lidocaine was diluted with cerebrospinal fluid. The patient remained seated for 5 min and then was placed in the prone jackknife position. Intraoperatively, the patient was hemodynamically stable, and the postoperative course was uneventful. The patient was released home pain-free within several hours following the procedure.

The next morning, the patient began to feel pain in his lower back radiating to his buttocks and legs. During the next few hours, the pain became severe, and the patient returned to the hospital.

On admission, the patient was in extreme discomfort and complained of intractable pain in his buttocks and thighs. There was no tenderness or signs of inflammation at the site of the spinal injection. Neurologic examination revealed no motor, sensory, or muscle-tendon reflex abnormalities. The patient denied having severe back pain or a similar episode in the past. Due to the severe pain and the radicular findings, we performed an MRI (with and without Gd-DTPA contrast material [Magnetol, Soreq, Israel]), which ruled out an epidural or spinal hematoma, direct nerve injury, or an infectious process. There were no signs of pressure to the cord or the spinal roots due to

bulging discs or degenerative changes. The only abnormal finding was enhancement of the mildly thickened cauda equina and the lumbosacral nerve roots on the postcontrast study (post Gd-DTPA), which are consistent with nonspecific inflammatory or infiltrative processes (figs. 1 and 2).

Due to the severe pain, the patient was treated with intravenous morphine (patient-controlled analgesia), and the pain decreased gradually within several hours. The patient was released the next day with mild pain, which fully resolved the following day.

Discussion

The use of intrathecal lidocaine came under scrutiny in the past decade after an increasing number of reports of severe neurologic symptoms (transient neurologic symptoms, cauda equina syndrome) after spinal anesthesia with lidocaine.¹ There is a lower incidence of these symptoms when other local anesthetics are used for spinal anesthesia.²⁻⁴ This supports the hypothesis that lidocaine has a neurotoxic effect, although other mechanisms, such as local anesthetics maldistribution, myofascial pain, and surgical positioning, have been proposed.⁵⁻⁹ The mechanism of this postulated lidocaine toxicity is unknown. An ischemic effect of lidocaine on the spinal cord was ruled out.¹⁰ The result of the MRI in this case showing enhancement of the cauda equina and the lumbosacral nerve roots may support the theory of a direct toxic effect of lidocaine. The MRI findings are suggestive of pial hyperemia or breakdown of the nerve root-blood barrier by a noninfectious inflammatory process. A similar picture can be found in patients with Guillain-Barré and Krabbe (demyelinating disorder) syndromes.¹¹⁻¹³ In Guillain-Barré syndrome, the degree of enhancement correlates well with the severity of the disease.¹⁴

The enhancement of the cauda equine roots indicates breakdown of the blood-nerve barrier. In the present case, it suggests a chemical irritation due to intrathecal anesthetic. This breakdown may be the cause of the neurologic deficit or just another effect of the intrathecal anesthetic. Until now, no studies were performed to investigate findings in MRI in patients after spinal anesthesia with and without neurologic symptoms. It is therefore impossible to conclude definitely from this case that the findings in the MRI prove direct toxic effect of lidocaine. However, in regard to similar MRI findings in other neurologic disorders, it is suggestive that toxic effects of lidocaine are the cause of the transient neurologic syndrome.

* Tutor in Anesthesiology, Hebrew University Hadassah Medical School, Staff Anesthesiologist, Department of Anesthesiology and Critical Care Medicine. † Professor in Radiology, Hebrew University Hadassah Medical School, Head MRI, Department of Radiology. ‡ Lecturer in Anesthesiology, Hebrew University Hadassah Medical School, Staff Anesthesiologist, Department of Anesthesiology and Critical Care Medicine.

Received from the Department of Anesthesiology and Critical Care Medicine, Hebrew University Hadassah Medical School, Hadassah University Hospital, Jerusalem, Israel. Submitted for publication August 10, 2001. Accepted for publication January 3, 2002. Support was provided solely from institutional and/or departmental sources.

Address correspondence to Dr. Avidan: Department of Anesthesiology and Critical Care Medicine, Hebrew University Hadassah Medical School, Hadassah University Hospital, Ein Kerem, P.O. Box 12000, Jerusalem 91120, Israel. Address electronic mail to: avidan3@netvision.net.il. Reprints will not be available from the authors. Individual article reprints may be purchased through the Journal Web site, www.anesthesiology.org.

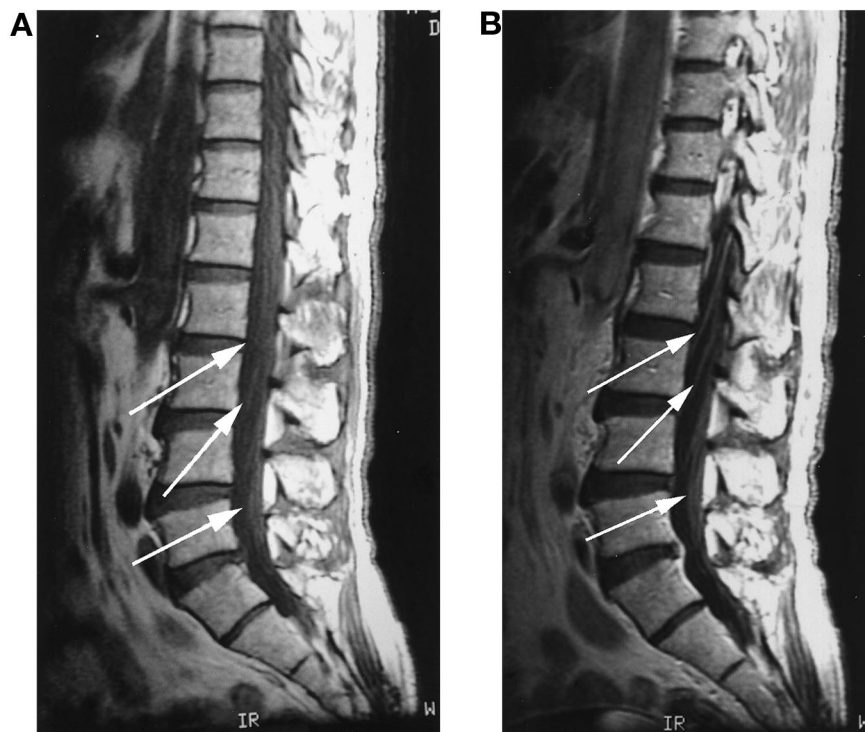


Fig. 1. Enhancement on the post-Gd-DTPA study of the mildly swollen cauda equine and spinal roots in the sagittal plane T9 sacrum (A, before Gd-DTPA; B, after Gd-DTPA).

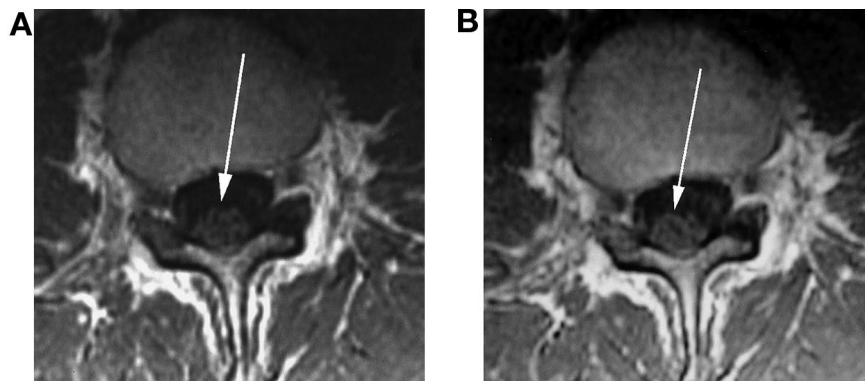


Fig. 2. Enhancement on the post-Gd-DTPA study of the mildly swollen cauda equine at level of L3 (A, before Gd-DTPA; B, after Gd-DTPA).

References

- Gaiser RR: Should intrathecal lidocaine be used in the 21st century? *J Clin Anesth* 2000; 12:476-81
- Salmela L, Aromaa U: Transient radicular irritation after spinal anesthesia induced with hyperbaric solutions of cerebrospinal fluid-diluted lidocaine 50 mg/ml or mepivacaine 40 mg/ml or bupivacaine 5 mg/ml. *Acta Anaesthesiol Scand* 1998; 42:765-9
- De Weert K, Traksel M, Gielen M, Slappendel R, Weber E, Dirksen R: The incidence of transient neurological symptoms after spinal anaesthesia with lidocaine compared to prilocaine. *Anaesthesia* 2000; 55:1020-4
- Liguori GA, Zayas VM, Chisholm MF: Transient neurologic symptoms after spinal anesthesia with mepivacaine and lidocaine. *ANESTHESIOLOGY* 1998; 88:619-23
- Johnson ME: Potential neurotoxicity of spinal anesthesia with lidocaine. *Mayo Clin Proc* 2000; 75:921-32
- Hiller A, Karjalainen K, Balk M, Rosenberg PH: Transient neurological symptoms after spinal anaesthesia with hyperbaric 5% lidocaine or general anaesthesia. *Br J Anaesth* 1999; 82:575-9
- Morisaki H, Masuda J, Kaneko S, Matsushima M, Takeda J: Transient neurologic syndrome in one thousand forty-five patients after 3% lidocaine spinal anesthesia. *Anesth Analg* 1998; 86:1023-6
- Freedman JM, Li DK, Drasner K, Jaskela MC, Larsen B, Wi S: Transient neurologic symptoms after spinal anesthesia: An epidemiologic study of 1,863 patients [erratum appears in *ANESTHESIOLOGY* 1998; 89:1614]. *ANESTHESIOLOGY* 1998; 89:633-41
- Pollock JE, Neal JM, Stephenson CA, Wiley CE: Prospective study of the incidence of transient radicular irritation in patients undergoing spinal anesthesia. *ANESTHESIOLOGY* 1996; 84:1361-7
- Benveniste H, Qui H, Hedlund LW, Huttemeier PC, Steele SM, Johnson GA: In vivo diffusion-weighted magnetic resonance microscopy of rat spinal cord: Effect of ischemia and intrathecal hyperbaric 5% lidocaine. *Reg Anesth Pain Med* 1999; 24:311-8
- Patel H, Garg BP, Edwards MK: MRI of Guillain-Barre syndrome. *J Comput Assist Tomogr* 1993; 17:651-2
- Iwata F, Utsumi Y: MR imaging in Guillain-Barre syndrome. *Pediatr Radiol* 1997; 27:36-8
- Vasconcellos E, Smith M: MRI nerve root enhancement in Krabbe disease. *Pediatr Neurol* 1998; 19:151-2
- Gorson KC, Ropper AH, Muriello MA, Blair R: Prospective evaluation of MRI lumbosacral nerve root enhancement in acute Guillain-Barre syndrome. *Neurology* 1996; 47:813-7

Spinal Anesthesia for a Patient with Familial Hyperkalemic Periodic Paralysis

James F. Weller, M.D.,* Richard A. Elliott, M.D.,* Peter J. Pronovost, M.D., Ph.D.†

THE *periodic paralyses* are a group of familial abnormalities in membrane electrolyte conductance that cause patients to have episodes of flaccid weakness associated with alterations in serum potassium. Based upon potassium concentrations during the episodes of weakness, three distinct subgroups of this disorder have been described: hypokalemic, normokalemic, and hyperkalemic.

Numerous cases of patients with the hypokalemic and normokalemic forms of familial periodic paralysis undergoing both general and regional anesthesia have been reported, many of them complicated by exacerbations of weakness. Unfortunately, there is little data to guide the perioperative care of patients with the less-common hyperkalemic disorder. We believe that the case discussed below is the first detailed report of a regional anesthetic successfully performed for a patient with familial hyperkalemic periodic paralysis.

Case Report

The patient was a 53-yr-old man who was seen at our Preoperative Evaluation Center the day prior to undergoing radical retropubic prostatectomy and right inguinal hernia repair. He described episodes of muscle weakness in association with upper respiratory infections beginning at age 6. Because his father carried the diagnosis of hyperkalemic periodic paralysis, the patient states that his symptoms were attributed to the same syndrome. At age 32, while in dental school, the patient underwent formal evaluation including electromyography but declined provocative and genetic testing. Since then, he has been followed at another institution by a neurologist familiar with his disorder. His past medical history was otherwise remarkable except for smoking, and his only medications were 250 mg acetazolamide orally per day and 5 g creatine orally per day. His father, brother, niece, and grandnephew also carried the diagnosis.

In 1999, the patient experienced his most severe and prolonged episode of weakness following a general anesthetic, which included succinylcholine for bilateral partial nasal turbinectomy. This episode lasted 4 days and was complicated by development of a deep venous thrombosis, requiring 6 months of warfarin therapy.

The patient fasted for 8 h prior to surgery. Resting electrocardiogram and admission laboratory values were within normal limits, including a QT interval of 0.40 s, serum potassium of 3.5 mEq/L, and serum glucose

of 107 mg/dl. In the preoperative area, an 18-gauge peripheral IV was placed, and an infusion of 5% dextrose in normal saline was begun. The patient was taken to the operating room, where standard monitors, including continuous pulse oximetry, continuous electrocardiography, and noninvasive blood pressure cuff, were applied. The patient was sedated lightly with 2 mg intravenous midazolam. A subarachnoid block was performed at the level of L3-L4, with the patient in the sitting position, using 22.5 mg hyperbaric bupivacaine, 0.75% (3 ml), which produced a T4 sensory level bilaterally. The patient received an additional 2 mg midazolam during the case. He breathed spontaneously through a face mask. To prevent hypothermia, ambient temperature in the operating room was maintained at 72°F, an upper body forced-air warming blanket was applied, and all fluids were run through a blood-warming device; minimum rectal temperature was 35.8° centigrade. During the first 90 min of the case, 2,400 ml dextrose, 5%, in normal saline was administered, causing the patient's serum glucose to rise to 454 mg/dl. After receiving an additional 1,750 ml 9% normal saline, 0.9%, his serum glucose returned to 119 mg/dl within 2 h in the postanesthesia care unit. Serum potassium concentrations were measured hourly during the case and ranged from 3.3 to 3.6 mEq/L. The surgical procedure was completed 130 min after placement of the spinal. The patient was transferred to the postanesthesia care unit, where his subarachnoid block resolved completely. Postoperative pain management was provided by intravenous hydromorphone patient-controlled analgesia. He was discharged from the hospital on postoperative day 3, at which time he continued to show no evidence of muscle weakness.

Discussion

The hyperkalemic form of familial periodic paralysis was first described by Gamstorp in 1956. The rarest of the dyskalemic periodic paralyses, the incidence of the hyperkalemic variety has been estimated at 1:500,000.¹ It is inherited in an autosomal dominant fashion with a high degree of penetrance in both males and females. Attacks tend to be shorter in duration, but onset of the disease is earlier than in the hypokalemic variety, frequently in the first decade of life. Weakness is usually more pronounced in the proximal muscles of the extremities and trunk but may progress to affect facial and bulbar muscles. Muscles of respiration are generally spared. Electrocardiographic abnormalities frequently accompany episodes of paresis; T-wave peaking may precede the onset of clinical weakness. Dysrhythmias have been reported but are uncommon. Myotonia is a frequent symptom, leading some investigators to suggest that hyperkalemic periodic paralysis may be a part of the disease spectrum that includes paramyotonia congenita. Cold, infection, anesthesia, rest following exercise, and hunger have all been reported to precipitate attacks. Nonetheless, the paucity of literature and correlation among precipitating factors (cold and anesthesia) creates difficulty in evaluating the relative importance of individual factors. Acetazolamide and thiazide diuretics

* Resident, Department of Anesthesiology and Critical Care Medicine, † Associate Professor, Departments of Anesthesiology and Critical Care Medicine, Surgery, and Health Policy and Management.

Received from the Departments of Anesthesiology and Critical Care Medicine, Surgery, and Health Policy and Management, The Johns Hopkins Hospital, Baltimore, Maryland. Submitted for publication August 3, 2001. Accepted for publication January 15, 2002. Support was provided solely from institutional and/or departmental sources.

Address reprint requests to Dr. Pronovost: The Johns Hopkins Hospital, Department of Anesthesiology and Critical Care Medicine, Meyer 295, 600 North Wolfe Street, Baltimore, Maryland 21287-7294. Address electronic mail to: ppronovo@jhmi.edu. Individual article reprints may be purchased through the Journal Web site, www.anesthesiology.org.

Table 1. Recommendations for Anesthetic Care of Patients with Hyperkalemic Periodic Paralysis

-
- A. Preoperative evaluation
1. Consider consultation with colleagues from other specialties, such as Neurology, who may have more experience with the disorder.
 2. Laboratory evaluation should include electrolytes and a resting electrocardiogram, in addition to any other studies indicated by the patient's comorbidities or surgical procedure.
 3. While an ICU bed may not be required postoperatively, one should be available.
- B. Avoid known precipitants.
1. Prevent carbohydrate depletion by loading the night before surgery and avoiding excessive fasting (e.g., schedule as first case when possible).
 2. Consider preoperative administration of kaluretics (e.g., thiazides, acetazolamide) to lower serum potassium.
 3. Provide dextrose-containing, potassium-free intravenous fluids perioperatively.
 4. Monitor temperature closely and maintain normothermia.
 5. Avoid succinylcholine.
 6. Avoid etomidate.
 7. Avoid acidemia.
 8. Consider requesting fresh packed erythrocytes that have been washed prior to administration.
 9. Consider measuring potassium concentrations in packed erythrocytes and discarding units with high concentrations.
- C. Monitor closely for signs and symptoms of an attack.
1. Use serial monitoring of electrolytes throughout the perioperative period, at least every hour intraoperatively.
 2. Observe the electrocardiogram for evidence of hyperkalemia, including T-wave peaking.
 3. When a nerve stimulator is used to monitor response to a nondepolarizing muscle relaxant, recall that even facial muscles can be paralyzed by an episode of hyperkalemia.
- D. Be prepared to treat early signs of an attack with abortive measures.
1. Insulin and glucose
 2. Sodium bicarbonate
 3. Calcium
 4. Furosemide
 5. Inhaled β -adrenergic agonists
 6. Epinephrine
-

ICU = intensive care unit.

have been used chronically to decrease the frequency and severity of attacks, presumably *via* kaluresis.²

The underlying defect in hyperkalemic periodic paralysis is a mutation of the α subunit of the skeletal muscle sodium channel located on chromosome 17.³ This mutation results in hypopolarization of the muscle membrane. During an attack, potassium moves out of muscle cells, causing serum potassium to rise. The average increase in serum potassium is just 20% and may even remain within normal limits; however, this relative hyperkalemia depolarizes the muscle membrane sufficiently to prevent activation of sodium channels and thus propagation of the action potential.²

Just 2 yr after the syndrome was first described, Egan cited anesthesia as a precipitant of severe attacks of familial hyperkalemic periodic paralysis. He studied 41 affected members of three different families, each of which had at least one member who had received general anesthesia. Following each anesthetic, the patient experienced an attack of transient paralysis lasting from 2 to 5 h. Egan also commented that one of these patients later received a spinal anesthetic for childbirth without developing paralysis. Unfortunately, no further details regarding the anesthetic techniques, such as whether succinylcholine was used, are reported.⁴ In 1980, Flewelling reported the first safe use of general anesthesia without muscle relaxants in the management of a 10-yr-old girl with familial hyperkalemic periodic paralysis.⁵ Subsequent reports document the safe use of nondepolarizing muscle relaxants^{6,7} and propofol.⁸

Despite finding only one prior allusion to regional anesthesia for a patient with hyperkalemic periodic paralysis, we could find no pathophysiologic reason why the use of a neuraxial technique should be contraindicated. In fact, there is some evidence that the inclusion of epinephrine in neuraxial local anesthesia causes moderate hypokalemia, a potential benefit in this patient population.⁹ In table 1, we outline some recommendations for anesthetic care of patients with hyperkalemic periodic paralysis.

In conclusion, we have provided a detailed report of a successful spinal anesthetic for the management of a patient with familial hyperkalemic periodic paralysis. We believe that neuraxial anesthesia is safe and in some cases may be the preferred option for this patient population.

References

1. Ellis FR: Inherited Muscle Disease. *Br J Anaesth* 1980; 52:153-64
2. Miller J, Katz RL: Muscle diseases, *Anesthesia and Uncommon Disease: Pathophysiologic and Clinical Correlations*, 2nd edition. Edited by Katz J, Benumof J, Kadis LB. Philadelphia, Saunders, 1981, pp 330-5
3. Adams DC, Heyer EJ: Anesthesia for the patient with neurologic disease. *Anesthesiol Clin North Am* 1997; 15:673-89
4. Egan TJ, Klein R: Hyperkalemic familial periodic paralysis. *Pediatrics* 1959; 24:761-73
5. Flewelling EH, Bodenstainer JB: Anesthetic experience in a patient with hyperkalemic periodic paralysis. *Anesth Rev* 1980; 7:44-6
6. Aarons JJ, Moon RE, Camporeis EM: General anesthesia and hyperkalemic periodic paralysis. *ANESTHESIOLOGY* 1989; 71:303-4
7. Ashwood EM, Russel WJ, Burrow DD: Hyperkalemic periodic paralysis and anaesthesia. *Anaesthesia* 1992; 47:579-84
8. Cone SM, Sansome AJ: Propofol in hyperkalemic periodic paralysis (letter). *Anaesthesia* 1992; 44:1012
9. Lefgren A, Hahn RG: Serum potassium levels after induction of epidural anaesthesia using mepivacaine with and without adrenaline. *Acta Anaesthesiol Scand* 1991; 35:170-4

Prolonged Desflurane Administration for Refractory Status Epilepticus

Michael D. Sharpe, M.D., F.R.C.P.C.,* G. Bryan Young, M.D., F.R.C.P.C.,† Seyed Mirsattari, M.D., F.R.C.P.C.,‡
Chris Harris, R.R.T.§

REFRACTORY status epilepticus (RSE) has been defined as continuous seizures for 60–90 min despite the administration of two to three anticonvulsant medications.¹ Several case reports have recommended isoflurane anesthesia for RSE due to its efficacy and tolerable side effects.^{2–5} We report a case of desflurane administration to a patient with RSE and discuss its potential application for this disorder.

Case Report

A 71-yr-old man was transferred to our hospital with generalized myoclonic status epilepticus. He was normal neurologically 1 month prior to admission when focal myoclonic seizures occurred in the right upper limb, which proceeded to be generalized. There were no prodromal signs or symptoms of infection. At his local hospital, initial treatment of the seizures with phenytoin, phenobarbital, and midazolam was ineffective. He was intubated, mechanically ventilated, and transported to our institution in status epilepticus. A propofol infusion was initiated upon admission, and an electroencephalogram at that time demonstrated very active bursts of epileptiform activity in the anterior head (fig. 1). Over the next 24 h, the patient continued to have seizures despite propofol, clonazepam, phenytoin, and valproate, and he subsequently required continuous paralysis with cisatracurium to facilitate ventilatory compliance. Desflurane anesthesia was initiated (1% end-tidal), which immediately suppressed epileptiform activity, and the propofol and cisatracurium infusions were discontinued. Adequate burst suppression was subsequently achieved with an end-tidal concentration of 2% (fig. 2). However, the patient exhibited significant central nervous system (CNS) irritability since whenever he was physically stimulated (e.g., oral suctioning or changing of position), this caused short bursts of myoclonic seizure activity. During the next 24 h, the frequency of seizures increased, which necessitated desflurane to be increased to an end-tidal concentration of 4%. During the next 13 days, adequate burst suppression was achieved with desflurane with end-tidal concentrations ranging between 3 and 4%. Breakthrough seizures were treated with lorazepam or midazolam boluses. For comparison of effectiveness, desflurane was discontinued on day 13, and isoflurane anesthesia was initiated for an additional 13 days. Isoflurane also provided adequate burst suppression with end-tidal concentrations ranging from 0.10% to 0.66%.

During the initial propofol infusion, dopamine was required (up to $10 \mu\text{g} \cdot \text{kg}^{-1} \cdot \text{min}^{-1}$) to maintain a mean blood pressure greater than

60 mmHg. However, during inhalational anesthesia administration, with both desflurane and isoflurane, a phenylephrine infusion (up to $720 \mu\text{g}/\text{min}$) was also required to maintain adequate blood pressure. The patient was weaned off both medications following discontinuation of inhalational anesthesia.

The patient was earlier diagnosed with adenocarcinoma of the prostate and was treated with radiotherapy and surgery. He also had been taking colloidal silver and was using higher-than-recommended doses for approximately 1 month prior to his onset of seizures.

Laboratory investigations, including international normalized ratio, hepatic enzymes, blood urea nitrogen, and creatinine did not indicate any significant abnormalities throughout the patient's hospital course (fig. 3). Computerized axial tomography and MRI scans of the head demonstrated no structural abnormalities. Several cerebrospinal fluid samples revealed no organisms or an elevated leukocyte count, no neoplastic cells, a normal glucose concentration, and mildly to moderately elevated protein; all subsequent cultures were negative. All other laboratory investigations to exclude CNS infection, Hashimoto thyroiditis, vasculitis, porphyria, or paraneoplastic syndrome were negative. Since all diagnostic tests were negative, CNS silver toxicity was considered due to the patient's recent ingestion of large amounts of colloidal silver. Silver concentrations were found to be elevated in plasma (41.7; normal, 1.0–2.3 nM), erythrocytes (48.2; normal, 4.3–10 nM), cerebrospinal fluid (2.1 nM), and urine (47.28; normal, 0–0.46 nM). Plasmapheresis was therefore initiated; however, despite a significant reduction in serum silver, the patient's neurologic condition did not improve.

In total, during 26 days of inhalational anesthesia, 238 and 39 MAC hours of desflurane and isoflurane, respectively, were administered to this patient, during which time several parenteral anticonvulsive therapies were administered and dosages were adjusted according to serum drug concentrations and control of the patient's seizure activity. On a daily basis, the dose of inhalational anesthetic was reduced to determine whether seizure activity resumed. Figure 4 is a qualitative summary of the patient's anticonvulsant therapy during his hospital stay. Eventually, seizures were controlled with clonazepam and valproate, allowing isoflurane to be gradually withdrawn. However, the patient remained in a persistent vegetative state, presumably from a toxic encephalopathy, the etiology of which was not yet determined. A tracheostomy was performed, and the patient was eventually weaned from the ventilator. His discharge electroencephalogram demonstrated α -theta coma patterns but no epileptiform discharges and no definite electrographic reactivity (fig. 5). The patient remained in the intensive care unit for 50 days and was eventually transferred to his home hospital 76 days following his admission. The patient expired on day 153. An autopsy examination of the brain did not reveal any definitive cause of this patient's encephalopathy, and there was no cerebral edema.

Discussion

Isoflurane anesthesia has become our agent of choice for refractory status epilepticus⁶ and has also been recommended by several practitioners.^{2–5} Although halothane was initially recommended for this disorder, the potential organ toxicity associated with its toxic metab-

* Associate Professor, Department of Anesthesia, † Professor, ‡ Epilepsy Fellow, Department of Clinical Neurological Sciences, § Respiratory Therapist, Department of Respiratory Therapy, London Health Sciences Centre—University Campus, University of Western Ontario.

Received from the Department of Anesthesia, London Health Sciences Centre—University Campus, London, Ontario, Canada. Submitted for publication August 13, 2001. Accepted for publication January 15, 2002. Support was provided solely from institutional and departmental sources.

Address reprint requests to Dr. Sharpe: Department of Anesthesia, London Health Sciences Centre—University Campus, 339 Windermere Road, London, Ontario, Canada N6A 5A5. Address electronic mail to: michael.sharpe@lhsc.on.ca. Individual article reprints may be purchased through the Journal Web site, www.anesthesiology.org.

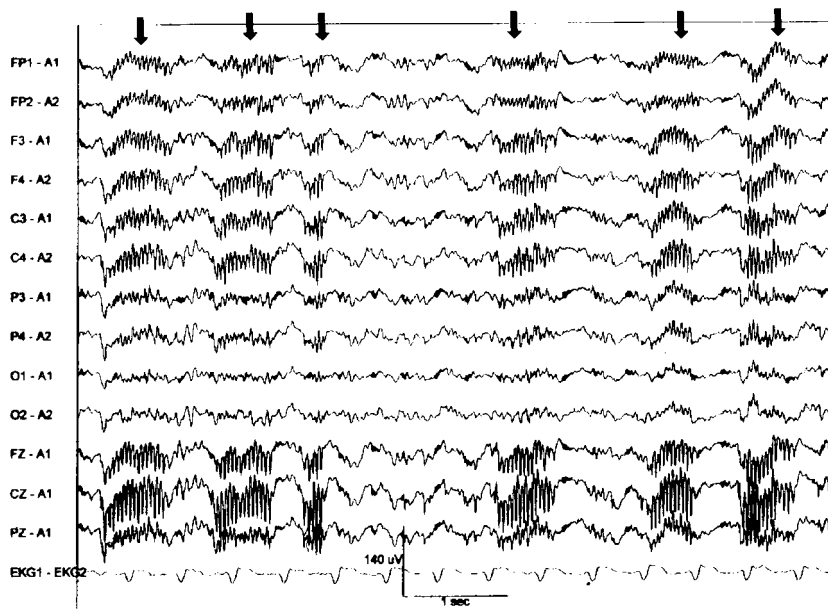


Fig. 1. Sixteen-lead electroencephalographic recording during propofol infusion. The patient received a single bolus of cisatracurium to block muscle artifact just before this recording. Prior to the cisatracurium administration, the patient had bursts of muscle activity occurring at the same time intervals as the bursts of spikes on the electroencephalogram. Shown are bursts of positive polyspikes in the anterior head (arrows) separated by rhythmic background electroencephalographic activity.

olites is concerning, particularly during prolonged administration.⁷ Isoflurane, on the other hand, undergoes significantly less metabolism, and its potential to produce organ toxicity is substantially reduced. Although significant increases in plasma organic fluoride have been demonstrated in patients receiving isoflurane for prolonged periods, there was no renal toxicity associated with this observation.⁸ As well, the published experience with isoflurane anesthesia for refractory status epilepticus and our own experience in seven patients over the past 5 yr have indicated no organ toxicity associated with prolonged exposure to isoflurane.²⁻⁶

Desflurane is a third-generation inhalational anesthetic agent with physiochemical properties comparable to isoflurane. Desflurane undergoes biotransformation by

cytochrome P-450, similar to isoflurane; however, the formation of its toxic metabolites was shown to be even less than isoflurane.⁹ This apparent resistance to biotransformation may be an advantage of desflurane over isoflurane, particularly during prolonged administration. As well, this patient also received a course of phenobarbital, which is a known inducer of cytochrome P-450 activity. However, despite receiving a combined total dose of 277 MAC hours of desflurane and isoflurane, there was no indication of renal, hepatic, or other organ toxicity (fig. 5).

The effects of desflurane on depression of electroencephalographic activity, including burst suppression, is dose related and comparable to the effects seen with equipotent doses of isoflurane. The effects of desflurane

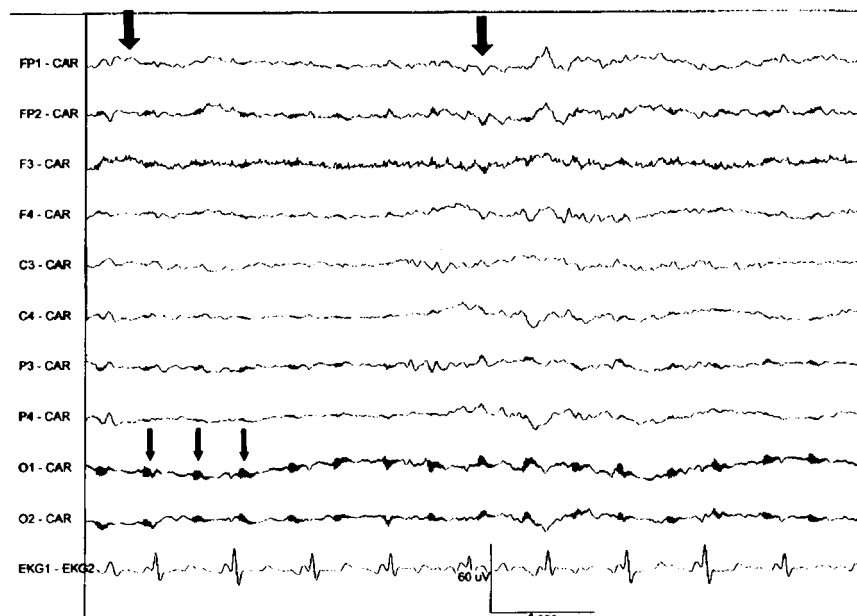


Fig. 2. Electroencephalographic recording during desflurane anesthesia demonstrating an incomplete burst-suppression pattern (bursts at large arrows) without epileptiform activity or myoclonic jerks. The low-amplitude, high-frequency, periodic, dark complexes (small arrows) that occur every 400-450 ms are electronic artifacts from a transformer.

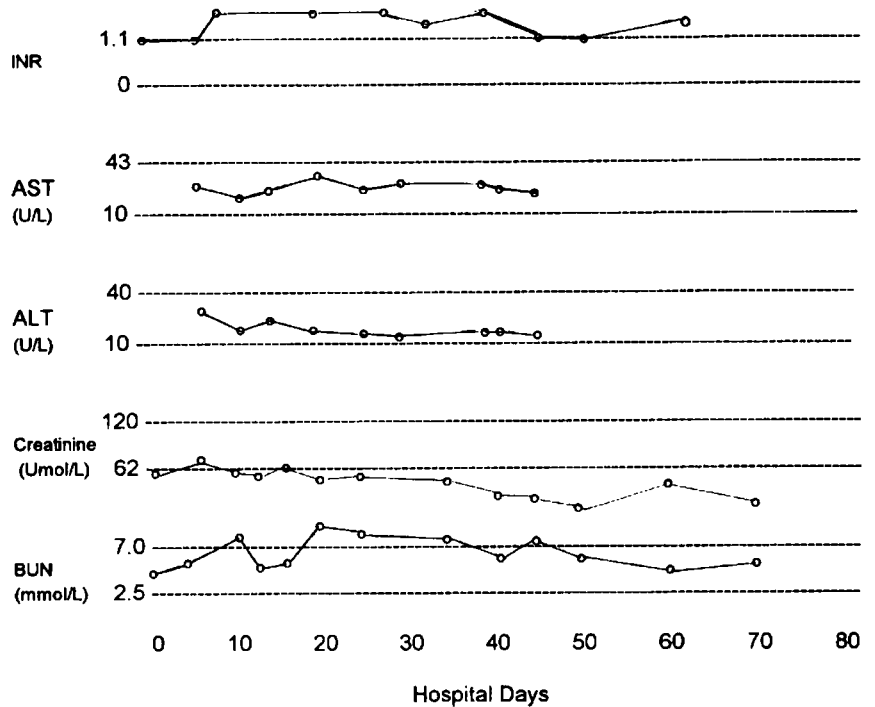


Fig. 3. Summary of international normalized ratio (INR), hepatic enzymes, and renal function for hospital course. AST = aspartate aminotransferase; ALT = alanine aminotransferase; BUN = blood urea nitrogen. The normal range of values is indicated on the chart for each parameter.

and isoflurane on cerebral blood flow, intracranial pressure, and cerebral metabolic rate are also comparable.¹⁰ Although the possibility exists that the toxic metabolites of these agents contributed to the underlying encephalopathy, there is no published evidence of CNS toxicity with either desflurane or isoflurane.⁷

During isoflurane administration, there is a dose-dependent reduction in systemic vascular resistance due to peripheral vasodilation. Indeed, all of our seven patients

with refractory status epilepticus treated with isoflurane or desflurane required an inotrope and/or a vasopressor during its administration, despite adequate fluid resuscitation.⁶ Desflurane also has similar effects to isoflurane on systemic coronary, renal, hepatic, and cerebral hemodynamics. However, its ability to cause systemic vasodilation is less than isoflurane and therefore should theoretically be less prone to cause hypotension negating the need for vasopressor therapy.¹⁰ Despite this, dopamine

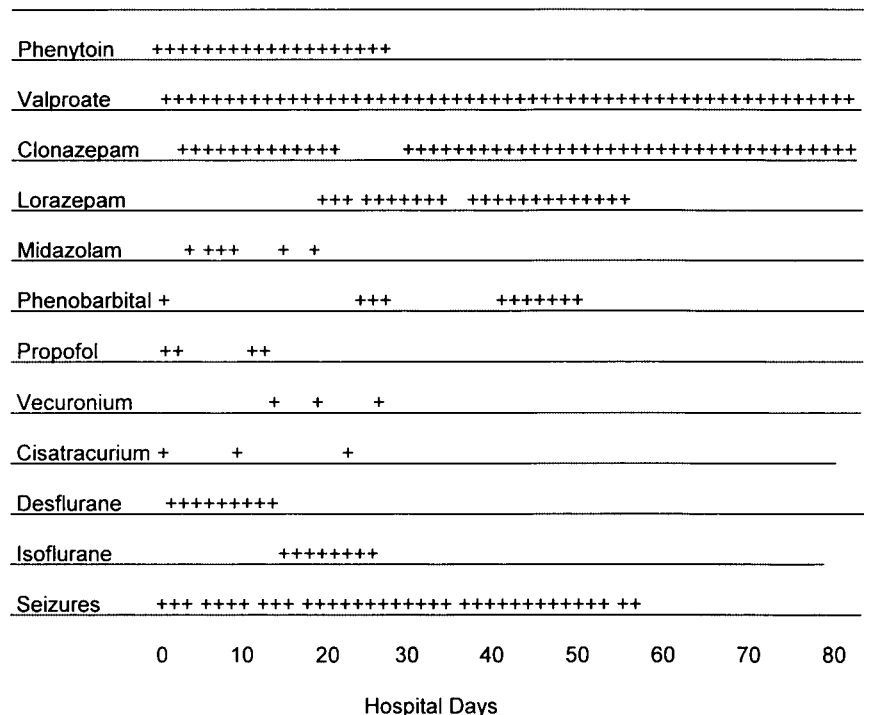


Fig. 4. Qualitative summary of drug therapy and seizure activity for hospital course.

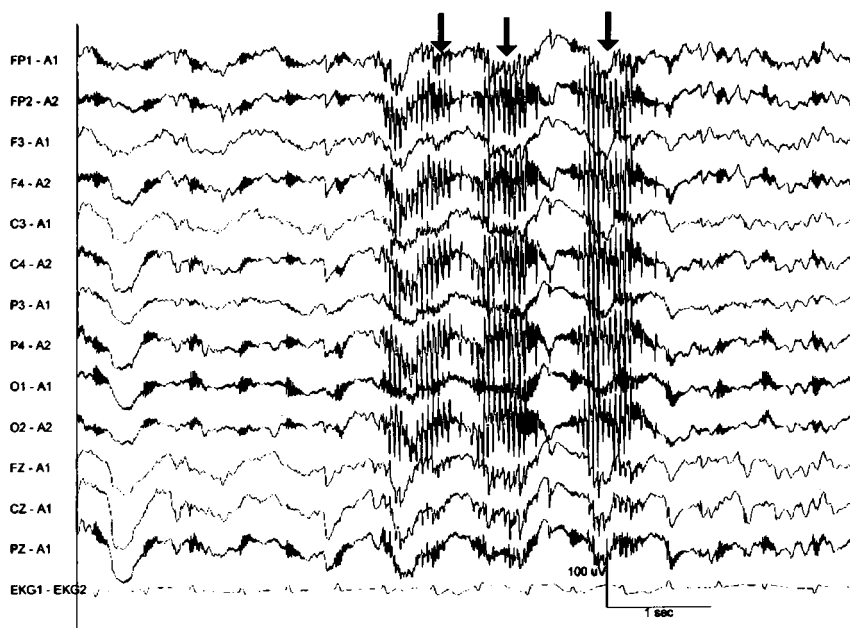


Fig. 5. Thirteen-lead electroencephalographic recording after discontinuation of anesthesia; no more spikes are evident with occasional brief bursts of myoclonic muscle artifact (arrows).

and phenylephrine were required during both desflurane and isoflurane administration.

The blood-gas partition coefficient of desflurane is lower than isoflurane and implies a more rapid onset of action and elimination once discontinued.¹⁰ However, this theoretical advantage will likely not be appreciated in the treatment of refractory status epilepticus since experience has demonstrated administration of isoflurane results in a prompt burst-suppression response on the electroencephalogram. Therefore, a quicker response to desflurane would likely not be appreciated clinically. In terms of recovery, however, the elimination of isoflurane can be rather prolonged, particularly when it has been administered for many days in the intensive care unit. Whether long-term administration of desflurane would translate into a more rapid recovery and whether this would result in any clinical benefit (*e.g.*, an earlier extubation time) are unknown.

In summary, desflurane is a newer inhalational agent with pharmacokinetic and pharmacodynamic properties comparable to isoflurane. As demonstrated in this case report, it was as effective as isoflurane in producing burst suppression and was easily titratable over a prolonged period of time in response to the electroencephalogram. Although the theoretical advantages of desflurane over isoflurane include a more rapid onset of action and elimination, as well as perhaps fewer requirements

for inotropic and/or vasopressor therapy for hypotension and reduced potential for organ toxicity due to its relative resistance to biotransformation, these potential advantages need to be evaluated in future studies. Inhalational anesthesia with either isoflurane or desflurane is a suitable therapy and is recommended for patients with refractory status epilepticus.

References

1. Shorvon S. Status epilepticus: Its clinical features and treatment in children and adults. Cambridge, Cambridge University Press, 1994, pp 201
2. Ropper AH, Kofke WA, Bromfield EB, Kennedy SK: Comparison of isoflurane, halothane and nitrous oxide in status epilepticus. *Ann Neurol* 1986; 19: 98-9
3. Sakaki T, Abe K, Hoshida T, Morimoto T, Tsunoda S, Okuchi K, Miyamoto S, Furuya H: Isoflurane in the management of status epilepticus after surgery for lesion around the motor area. *Acta Neurochir (Wien)* 1992; 116:38-43
4. Kofke WA, Young RSK, Davis P, Woelfel SK, Gray L, Johnson D, Gelb A, Meeke R, Warner DS, Pearson KS, Gibson JR Jr, Koncelik J, Wessel HB: Isoflurane for refractory status epilepticus: A clinical series. *ANESTHESIOLOGY* 1989; 71:653-9
5. Kofke WA, Bloom MJ, Van Cott A, Brenner RP: Electrographic tachyphylaxis to etomidate and ketamine used for refractory status epilepticus controlled with isoflurane. *J Neurosurg Anesth* 1997; 9:269-72
6. Mirsattari S, Young B, Sharpe M: Isoflurane inhalational anesthesia for refractory status epilepticus. *Epilepsia* 2001; 42(suppl 7):146
7. Kenna JG, Jones RM: The organ toxicity of inhaled anesthetics. *Anesth Analg* 1995; 81:S51-66
8. Spencer EM, Willatts SM, Prys-Roberts C: Plasma inorganic fluoride concentrations during and after prolonged (>24 hrs) isoflurane sedation: Effects on renal function. *Anesth Analg* 1991; 73:731-7
9. Koblin DD: Characteristics and implications of desflurane metabolism and toxicity. *Anesth Analg* 1992; 75:S10-6
10. Wartler DC, Pagel PS: Cardiovascular and respiratory actions of desflurane: Is desflurane different from isoflurane? *Anesth Analg* 1992; 75:S17-31

Propofol Induced Marked Prolongation of QT Interval in a Patient with Acute Myocardial Infarction

Masao Sakabe, M.D.,* Akira Fujiki, M.D.,† Hiroshi Inoue, M.D.‡

PROPOFOL is a widely used anesthetic drug and does not prolong corrected QT interval as much as other anesthetic agents, including midazolam.¹ Propofol is also used for induction and maintenance of general anesthesia, even in patients with either congenital or acquired long QT syndrome.² However, we experienced marked prolongation of the QT interval during anesthesia with propofol to allow mechanical ventilation in a patient with acute myocardial infarction.

Case Report

A 71-yr-old woman was admitted to our hospital because of acute anterior myocardial infarction. On admission, her pulse rate was 129 beats/min, and her blood pressure was 204/120 mmHg. An electrocardiogram showed QS pattern and ST elevation in V1-V3 and normal QRS duration (80 ms). QT interval corrected by heart rate (QTc) according to Bazett's formula³ was 440 ms (fig. 1A). Serum potassium was 3.2 mEq/l, calcium was 8.9 mg/dl, and magnesium was 2.0 mg/dl. Blood gas analysis revealed pH 6.96, Pao₂ 75.9 mmHg, Paco₂ 106.2 mmHg, base excess -11.3, and HCO₃⁻ 23.4 mEq/l. The patient was intubated for ventilatory support. Propofol was given intravenously for induction (100 mg or 1.7 mg/kg) and maintenance (1.7 mg · kg⁻¹ · h⁻¹) of sedation to allow mechanical ventilation. Four hours later, the QT interval was markedly prolonged as compared with the baseline value, and the QTc interval was prolonged to 690 ms (fig. 1B). QRS duration was not affected. At that time, serum concentrations of electrolytes still remained within the physiologic range; potassium was 3.9 mEq/l, calcium was 8.9 mg/dl, and magnesium was 2.0 mg/dl. Drugs concomitantly used were heparin (8,000 U/day), nitroglycerin (0.15 mg/h), dopamine (2.0 μg · kg⁻¹ · min⁻¹), and piperacillin (4 g/day). Fortunately, lethal ventricular tachyarrhythmias, such as torsade de pointes, were not induced. The QTc interval was shortened to 490 ms after withdrawal of propofol (fig. 1C). Serum potassium was 3.9 mEq/l and calcium was 9.8 mg/dl, but magnesium was not measured at this point. Administration of propofol was repeated for challenge, and the QTc interval was prolonged again (fig. 1D). The QRS duration was 100 ms, and serum concentrations of electrolytes remained unchanged (potassium was 3.9 mEq/l and calcium was 10.0 mg/dl). Instead of propofol, midazolam (0.15 mg · kg⁻¹ · h⁻¹) was given without prolongation of the QT interval. The patient has been free from any arrhythmic events for 1 yr after discharge. QT prolongation has not been documented at each visit of our outpatient clinic.

* Fellow, † Assistant Professor, ‡ Professor.

Received from the Second Department of Internal Medicine, Toyama Medical and Pharmaceutical University, Toyama, Japan. Submitted for publication September 7, 2001. Accepted for publication January 15, 2002. Support was provided solely from departmental sources.

Address reprint requests to Dr. Inoue: The Second Department of Internal Medicine, Toyama Medical and Pharmaceutical University, 2630 Sugitani, Toyama 930-0194, Japan. Address electronic mail to: hiroshi@ms.toyama-mpu.ac.jp. Individual article reprints may be purchased through the Journal Web site, www.anesthesiology.org.

Discussion

Many causes are known to induce prolongation of QT interval: antiarrhythmic drugs, psychotropic drugs, changes in electrolyte concentrations, lesions of the central nervous system, and changes in sympathetic tone.⁴ Several investigators described unexpected, life-threatening ventricular tachyarrhythmias, sudden cardiac arrest, and death during general anesthesia in patients suffering from undiagnosed long QT syndrome.⁵ The effect of anesthetic agents on QT interval has been studied. McConachie *et al.*³ reported that propofol prolonged the QT interval significantly, but the prolongation was small as compared with thiopentone. During induction of anesthesia with propofol, the QTc interval remained below the upper limit (440 ms) of the normal range in patients with normal QT intervals. In contrast, methohexital and midazolam did prolong the QT interval to exceed the upper limit.² Other investigators reported both propofol and midazolam did not change the QTc interval significantly.⁶ Furthermore, sevoflurane prolonged the QTc interval significantly, and that was fully reversible when propofol was substituted for sevoflurane.^{7,8}

The mechanism of QT prolongation during anesthesia might be due to a reduction in sympathoadrenergic activity with a concomitant increase in vagal tone. Sympathetic nerve activity was inhibited and sensitivity of baroreflex was decreased during anesthesia with propofol.⁹

Propofol inhibits L-type calcium channel directly and shortens the duration of action potential in isolated cardiac myocytes.¹⁰ This effect is significantly greater than that on K⁺ currents.¹¹ Both thiopentone and midazolam also have similar effects on inward Ca²⁺ current.¹¹ The mean open time of single sodium channels was significantly reduced with propofol.¹² Taken together, the effects of propofol on the QT interval are quite complicated.

In the present case, the mechanism for QT prolongation remains unclear. There were no apparent causes for QT prolongation except the administration of propofol. QT prolongation disappeared after withdrawal of propofol and was reproduced with challenge test with propofol. In patients with coronary artery disease, prolongation of the QT interval could be associated with polymorphic ventricular tachycardia, known as torsade de pointes, and sudden death.¹³ This was, however, not supported by other investigators.^{14,15} Although ventricular tachyarrhythmias were not induced in our patient, propofol should be given cautiously in patients with acute myocardial infarction.

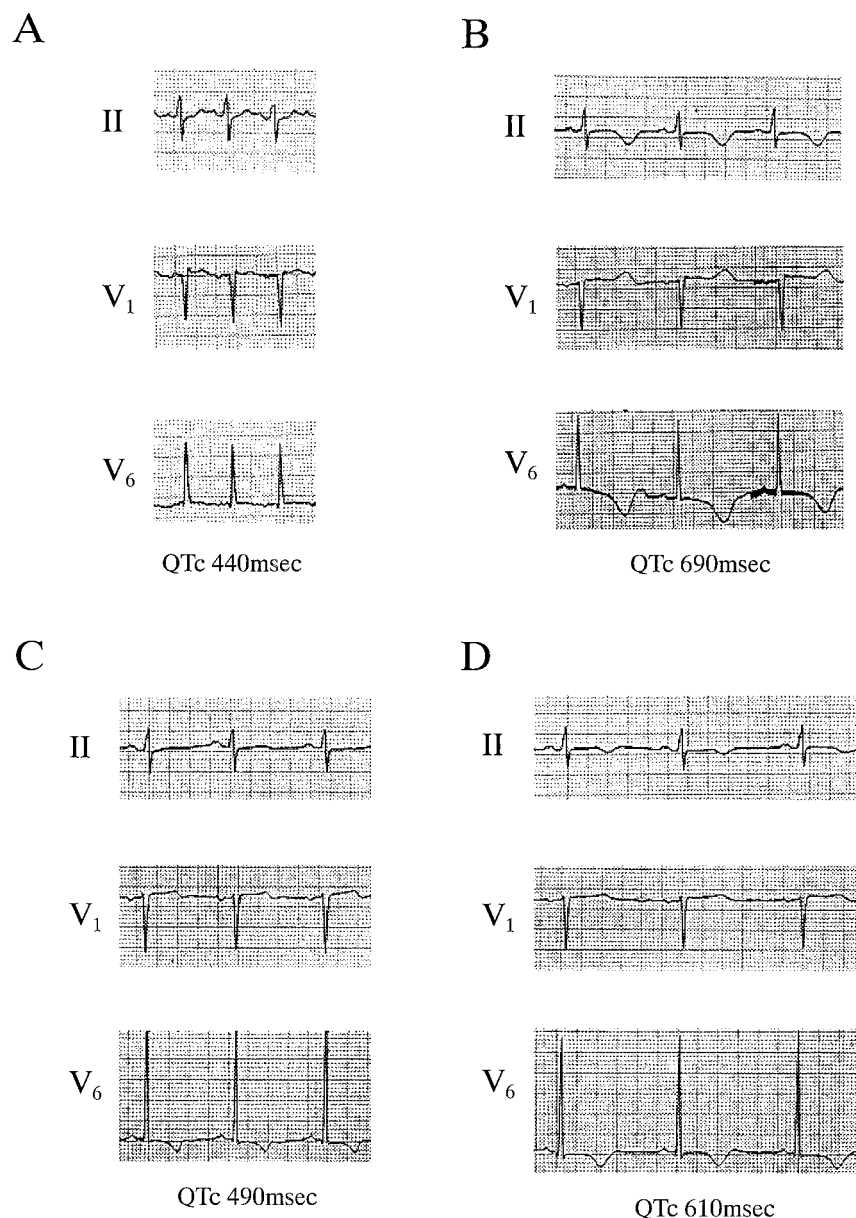


Fig. 1. Effects of propofol on QT interval. Electrocardiogram on admission (A) and after the administration of propofol (B). QTc interval was prolonged from 440 to 690 ms. QTc prolongation disappeared after withdrawal (C) and was reproduced with readministration (D) of propofol. Although R-R interval was also shortened after withdrawal of propofol (C), QTc was shortened disproportionately with shortening of R-R interval. All electrocardiograms were recorded at a standard gain (1 mV/10 mm) and paper speed (25 mm/s). On admission, echocardiography showed the presence of pericardial effusion (550 ml). The R-wave amplitude increased in accordance with reduction of the pericardial effusion.

The authors thank Akira Masuda, M.D. (Associate Professor, Department of Anesthesiology, Toyama Medical and Pharmaceutical University, Toyama, Japan), for critical review of the manuscript.

References

- Saarnivaara L, Klemola UM, Lindgren L, Rautiainen P, Suvanto A: QT interval of the ECG, heart rate and arterial pressure using propofol, methohexital or midazolam for induction of anaesthesia. *Acta Anaesthesiol Scand* 1990; 34: 276-81
- McConachie I, Keaveny JP, Healy TE, Vohra S, Million L: Effect of anaesthesia on the QT interval. *Br J Anaesth* 1989; 63:558-60
- Bazett HC: An analysis of the time-relations of electrocardiograms. *Heart* 1920; 7:353-70
- Yanowitz F, Preston JB, Abildskov JA: Functional distribution of right and left stellate innervation to the ventricles: Production of neurogenic electrocardiographic changes by unilateral alteration of sympathetic tone. *Circ Res* 1966; 18:416-28
- Medak R, Benumof JL: Perioperative management of the prolonged Q-T interval syndrome. *Br J Anaesth* 1983; 55:361-4
- Galloway PA, Glass PSA: Anesthetic implications of prolonged QT interval syndromes. *Anesth Analg* 1985; 64:612-20
- Kuenszberg E, Loeckinger A, Kleinsasser A, Lindner KH, Puehringer F, Hoermann C: Sevoflurane progressively prolongs the QT interval in unpremedicated female adults. *Eur J Anaesthesiol* 2000; 17:662-4
- Kleinsasser A, Loeckinger A, Lindner KH, Keller C, Boehler M, Puehringer F: Reversing sevoflurane-associated Q-Tc prolongation by changing to propofol. *Anaesthesia* 2001; 56:248-71
- Sellgren J, Ejnell H, Elam M, Ponten J, Wallin BG: Sympathetic muscle nerve activity, peripheral blood flows, and baroreceptor reflexes in humans during propofol anesthesia and surgery. *ANESTHESIOLOGY* 1994; 80:534-44
- Zhou W, Fontenot HJ, Liu S, Kennedy RH: Modulation of cardiac calcium channels by propofol. *ANESTHESIOLOGY* 1997; 86:670-5
- Buljubasic N, Marijic J, Bercezi V, Supan DF, Kampine JP, Bosnjak ZJ: Differential effects of etomidate, propofol, and midazolam on calcium and potassium channel currents in canine myocardial cells. *ANESTHESIOLOGY* 1996; 85: 1092-9
- Saint DA: The effects of propofol on macroscopic and single channel sodium currents in rat ventricular myocytes. *Br J Pharmacol* 1998; 124:655-62
- Schwartz PJ, Wolf S: QT interval prolongation as predictor of sudden death in patients with myocardial infarction. *Circulation* 1978; 55:1074-7
- Forsell G, Orinius E: QT prolongation and ventricular fibrillation in acute myocardial infarction. *Acta Med Scand* 1981; 210:309-11
- Wolfe CL, Nibley C, Bhandari A, Chatterjee K, Scheinman M: Polymorphous ventricular tachycardia associated with acute myocardial infarction. *Circulation* 1991; 84:1543-51

EXIT to ECMO

Theresa C. Michel, M.D.,* Andrew L. Rosenberg, M.D.,† Linda S. Polley, M.D.‡

ADVANCES in prenatal ultrasonography have improved the ability to detect fetal anomalies of the airway and respiratory system that would be incompatible with life outside the uterus. Extracorporeal membrane oxygenation (ECMO) is increasingly used to care for the neonate with severe pulmonary pathology and respiratory distress.¹ Some disorders of the neonatal airway are so severe, however, that techniques have been developed to provide oxygenated blood to the neonate by maintaining fetal-placental circulation until the infant's airway is secured. The *ex utero* intrapartum technique (EXIT) procedure was initially developed to allow uteroplacental circulation to continue while an artificial airway could be established in cases in which congenital abnormalities of the fetal head and neck could impair spontaneous respiration after delivery.² This procedure has been predominately used for managing giant fetal neck masses, such as teratomas and lymphangiomas, as well as for neonates with *in utero*-applied tracheal clips to induce lung growth stunted by congenital diaphragmatic hernia.³⁻⁶ However, some neonates with a significantly compromised airway may also require ECMO due to concomitant severe lung pathology. The time required to initiate ECMO may lead to unacceptable hypoxia if an airway cannot be immediately established. We present a case report describing the anesthetic management involved when an EXIT procedure was used to facilitate initiation of ECMO in a neonate with a large pulmonary arteriovenous malformation.

Case Report

A 26-yr-old gravida 2 para 1 woman with an uncomplicated pregnancy and no significant medical history was referred to our institution after an ultrasonographic examination at 21 weeks gestation revealed a fetus with a large pulmonary arteriovenous malformation, severe cardiomegaly, and a large-diameter pulmonary artery that may have been obstructing the fetal airway. The fetus had no other malformations or obvious pathology. Because further diagnostic studies would be required to evaluate the cardiopulmonary anomaly before attempting definitive surgical correction, a multidisciplinary team decided that

ECMO should be instituted immediately upon delivery. Cannulation could take several minutes, however, and it would be necessary to provide some method of oxygenation. In anticipation of severe respiratory distress and the potential difficulty securing an airway immediately after birth, the decision was made to perform an EXIT procedure before establishing ECMO. General anesthesia was planned to permit control of uterine tone.

The patient was admitted at 38 1/2 weeks for elective cesarean section. A preoperative physical exam revealed a 64-in, 60-kg healthy parturient with a Mallampati I airway. Preoperatively, the patient received routine aspiration prophylaxis and was prehydrated with a liter of normal saline. Following rapid sequence induction, anesthesia was maintained with a 50/50 mix of nitrous oxide and oxygen with 1% end-tidal isoflurane. Fentanyl, 300 µg, was given within the first 10 min. Muscle relaxation was maintained with atracurium.

At the point of uterine incision, FiO₂ was increased to 100%, and isoflurane was increased from 1.8% to 2.6% end-tidal to provide uterine relaxation for delivery of the fetal head and neck. Ephedrine boluses, totaling 95 mg over the course of the case, were necessary to maintain maternal systolic blood pressure greater than 100 mmHg.

Fetal membrane rupture occurred 5 min after uterine incision; the neonate's head, shoulders, and right arm were delivered a minute later. A 24-gauge peripheral intravenous catheter was placed in the right hand of the infant while he was orally intubated with a 3.5 endotracheal tube, using a Miller O laryngoscope blade. Because of fetal lung hypoplasia, we did not plan to mechanically ventilate the child. The goal was to protect the airway and to have the means to ventilate if ECMO cannulation was prolonged or fetal distress occurred. The infant was monitored with continuous pulse oximetry on the right hand to measure preductal oxygen saturation and echocardiography. Fentanyl (10 µg) and pancuronium (1 mg) were administered intravenously to the infant just prior to ECMO cannulation. The neonatal SpO₂ ranged from 26% to 65%, and 0.2 mg intravenous atropine was given for a heart rate of 90 beats/min. After successful cannulation of the internal jugular vein, the child was delivered, and ECMO was initiated 6 min later. The total elapsed time from delivery of the head to ECMO was 44 min. Umbilical blood gas measurements immediately after initiation of ECMO revealed an arterial pH of 7.26, a PaCO₂ of 52, a PaO₂ of 36, an HCO₃ of 23, and an SaO₂ of 76%; a venous pH of 7.33, a PvcO₂ of 42, a Pvo₂ of 51, an HCO₃ of 21.9, and an SpO₂ of 91%.

After ECMO was established, isoflurane was decreased to 1.1% end-tidal, and nitrous oxide was restarted at 70% with 30% O₂. The placenta was delivered spontaneously 5 min after the child was delivered. Though uterine tone was firm, 30 U oxytocin in 1,000 ml lactated Ringer's solution were administered to the mother intravenously. Total estimated blood loss was 600 ml. The mother's postpartum course was uncomplicated, and she was discharged to home on the second postoperative day.

The approximately 3,000-g baby was taken to the Neonatal Intensive Care Unit, where he remained on ECMO. On the second day of life, repair of the pulmonary arteriovenous fistula, patent ductus arteriosus, and atrial septal defect were performed. The child's postoperative course was complicated by bleeding and hemodynamic instability. Ultimately, the severity of pulmonary hypoplasia was deemed non-survivable. On the fourth postpartum day, ECMO was withdrawn, and the child expired secondary to respiratory failure.

* Resident, † Robert Wood Johnson Clinical Scholar, ‡ Director, Obstetric Anesthesiology Research.

Received from the Department of Anesthesiology, Division of Obstetric Anesthesiology, Women's Hospital, University of Michigan Health System, Ann Arbor, Michigan. Submitted for publication September 26, 2001. Accepted for publication January 15, 2002. Dr. Rosenberg is supported in part by the Robert Wood Johnson Clinical Scholars Program, Princeton, New Jersey.

Address reprint requests to Dr. Rosenberg: 1500 East Medical Center Drive, 1G323 UH, Ann Arbor, Michigan 48109-0048. Address electronic mail to: arosen@umich.edu. Individual article reprints may be purchased through the Journal Web site, www.anesthesiology.org.

Discussion

Increasingly sophisticated techniques used in perinatal medicine, such as the EXIT procedure, may change how an anesthesiologist balances the risks and benefits of interventions and therapeutics that affect the mother and those that may affect the neonate. For example, frequently, medications with the potential to blunt neonatal ventilation, such as opioids, are used sparingly or not at all. In this case, anticipation of the use of ECMO and the subsequent need for neonatal sedation allowed use of narcotic prior to delivery. Fentanyl was selected for its rapid onset, ability to cross the placental membrane, and relative lack of effect on uterine tone, uterine blood flow, and maternal and fetal hemodynamics.⁷

Optimal uterine relaxation was essential to prevent premature placental separation prior to the establishment of ECMO and to allow for fetal oxygenation. We used 2 to 3 minimum alveolar concentration (MAC) isoflurane to achieve adequate uterine relaxation while not compromising both maternal systolic blood pressure and fetal perfusion. Although higher MACs of 3 to 4 have been shown to produce significant tocolysis,⁸ isoflurane administered at an end-tidal concentration of greater than 2.0% for greater than 30 min has been shown in animal studies to result in fetal acidosis due to decreased fetal heart rate, oxygen saturation, cardiac output, and blood pressure.⁹ We were prepared to provide additional uterine relaxation if indicated with bolus doses of 50–100 μg intravenous nitroglycerine.

The rapid establishment of neonatal intravenous access permitted administration of additional opioid and neuromuscular blocker prior to ECMO cannulation and provided a route for emergency drugs. The presence of several anesthesiologists allowed for multiple interventions to be accomplished at the same time while assuring proper care to the anesthetized mother.

Following the successful tracheal intubation, the neonate demonstrated relatively low oxygen saturations of 26–65%. Previous investigations of fetal arterial oxygen saturation during labor have identified SpaO_2 values of 30% as the threshold value for fetal compromise. Initially, we were concerned that these values reflected inadequate uteroplacental perfusion.¹⁰ One explanation is that with uterine incision and decompression, partial placental separation may have occurred, leading to inadequate uteroplacental blood flow.¹¹ Also, the large pulmonary arteriovenous malformation may have been a

cause of this apparent hypoxia and underscored the urgency for establishing ECMO. The low SpO_2 values may also have been attributed to unique aspects of the EXIT to ECMO period. We have observed in all previous EXIT procedures that initial fetal SpO_2 values are in the low 30% range. Finally, movement artifact¹² from the difficulty maintaining good oximetry probe contact may have contributed to the observed oxygen saturation readings. Obtaining a cord blood sample was entertained but rejected because it would not alter our management and could delay ECMO. However, the near-normal cord gases soon after ECMO was initiated suggest that fetal perfusion was adequate during the time of the EXIT procedure.

In summary, in the setting of neonatal pulmonary and airway abnormalities, the combination of two very technically challenging procedures, such as EXIT and ECMO, may be attempted. Familiarity with intrauterine neonatal physiology and maternal uterine response to anesthetics is critical to successfully manage an EXIT to ECMO procedure.

References

1. Extracorporeal Life support Organization (ELSO) Registry. Ann Arbor, Michigan, ELSO, 1997
2. Langer JC, Tabb T, Thompson P, Paes BA, Caco CC: Management of prenatally diagnosed tracheal obstruction: Access to the airway in utero prior to delivery. *Fetal Diagn Ther* 1992; 7:12–6
3. Schulman SR, Jones BR, Slotnick N, Schwartz MZ: Fetal tracheal intubation with intact uteroplacental circulation. *Anesth Analg* 1993; 76:197–9
4. Liechty W, Crombleholme T, Flake A, Morgan MA, Durth D, Hubbard A, Adzick NS: Intrapartum airway management for giant fetal neck masses: The EXIT (ex-utero intrapartum treatment) procedure. *Am J Obstet Gynecol* 1997; 177: 870–4
5. Mychalishka GB, Bealer JF, Graf JL, Adzick NS, Harrison MR: Operating on placental support: The EX Utero Intrapartum procedure. *J Pediatr Surg* 1997; 32:227–31
6. Shih GH, Boyd GL, Vincent RD, Long FW, Hauth JC, Georgeson, KE: The EXIT procedure facilitates delivery of an infant with a pretracheal teratoma. *ANESTHESIOLOGY* 1998; 89:1573–5
7. Craft JB, Coaldrake LA, Bolan JC, Mondino M, Mazel P, Gilman RM, Shokes LK, Woolf WA: Placental passage and uterine effects of fentanyl. *Anesth Analg* 1982; 62:894–8
8. Harrison MR, Anderson J, Rosen MA, Ross NA, Hendrickx AG: Fetal surgery in the primate: I. Anesthetic, surgical and tocolytic management to maximize fetal-neonatal survival. *J Pediatr Surg* 1982; 17:115–23
9. Palahniuk RJ, Shnyder SM: Maternal and fetal cardiovascular and acid-base changes during halothane and isoflurane anesthesia in the pregnant ewe. *ANESTHESIOLOGY* 1974; 41:462–72
10. Seelbach-Gobel B, Heupel M, Kuhnert M, Butterweggem: The prediction of fetal acidosis by means of intrapartum fetal pulse oximetry. *Am J Obstet Gynecol* 1999; 180:73–81
11. Morishima HO, Hyman AI, Adamsons K, James LS: Anesthetic management for fetal operation in the subhuman primate. *Am J Obstet Gynecol* 1971; 110: 926–33
12. Bloom SI, Swindle RG, McIntire DD, Leveno KJ: Fetal pulse oximetry: Duration of desaturation and intrapartum outcome. *Obstet Gynecol* 1999; 93: 1036–40

Anaphylactic Shock Due to Suxamethonium Complicated by a Coronary Thrombus

Vincent Joly, M.D.,* Antoine Ceddaha, M.D.,† Marie-Thérèse Guinnepain, M.D.,‡ Serge Makowski, M.D.,§
Patrick Henry, M.D.,§ Marc Fischler, M.D.¶

MYOCARDIAL infarction following anaphylactic shock is uncommon.¹ Suggested causes of myocardial infarction are severe hypotension, coronary spasm, and release of vasoactive substances or of procoagulating molecules. Myocardial infarction with normal coronary arteries is exceptional.² We report a case of anaphylactic shock and myocardial ischemia following exposure to succinylcholine in which early coronary angiography showed the presence of a coronary thrombus.

Case Report

A 62-yr-old man (American Society of Anesthesiologists physical status II) presented with an epidermoid carcinoma infiltrating the right vocal cord and was scheduled for a diagnostic direct laryngoscopy. Nicardipine for hypertension was his only medication. His medical history was unremarkable, and there was no history of atopy or allergic reaction to drugs.

Atropine, 0.01 mg/kg, and 5 mg midazolam were administered intramuscularly 30 min before the patient arrived in the operating room. Conventional monitoring included pulse oximetry, electrocardiography, and noninvasive pressure monitoring. Anesthesia was induced with 2 mg/kg propofol and 15 µg/kg alfentanil followed by 1 mg/kg succinylcholine. A catheter (Seldicath; Plastimed, France) was introduced into the trachea through the cricothyroid membrane, and jet ventilation (GR300; Laboratoire Lejeune-Seitz-Ameline, Paris, France) was begun approximately 2 min after the end of anesthetic induction. In the seconds that followed, it was observed that the pulse oximeter ceased to function, although the electrical activity of the heart continued. No femoral or carotid pulse could be felt. Cardiopulmonary resuscitation was started with tracheal intubation, cardiac massage, and administration of several boluses of epinephrine (1-mg bolus followed by three 1-mg boluses injected every minute and then by a 2-mg/h infusion). A pneumothorax was ruled out by chest radiography. The patient recovered a spontaneous cardiac rhythm after 10 min of resuscitation but quickly developed ventricular fibrillation. Cardiopulmonary resuscitation was restarted and required nine consecutive electric shocks (300 joules for the first four and 400 for the next five) and administration of 1 mg/kg lidocaine and continuation of epinephrine infusion. After 30 min of resuscitation, hemodynamic parameters were satisfactory (heart rate, 120 beats/min; blood pressure, 90/40). The patient presented diffuse papular erythema. Blood samples were obtained for later measurement of histamine and tryptase concentrations and complement fractions. An electrocardi-

ogram revealed significant ST-segment elevation in DII-DIII derivations; a transthoracic echocardiogram showed diffuse left ventricular wall motion abnormalities and a major right ventricle dilatation with an akinetic free wall. A coronary angiography was performed because of the electrocardiographic and echocardiographic abnormalities.

The left main coronary was normal, and the left anterior descending artery had no stenosis in its three segments. There were two diagonal branches without stenosis. The circumflex artery was large, irregular, and calcified without significant stenosis, with two marginal branches without abnormalities. The right coronary system was dominant, with a large, calcified right coronary artery. The proximal segment of the right coronary artery was the site of a single thrombus surrounded by contrast medium (fig. 1A); the thrombus disappeared after the first intracoronary injection of contrast medium ("washing effect"; fig. 1B).

The patient's course was rapidly favorable. Epinephrine was gradually stopped within 6 h. The patient was tracheally extubated 9 h after the onset of shock.

Angiography, performed on day 8, showed the right coronary artery free from stenosis along its three segments.

A subsequent patient interview did not reveal latex, egg, or soy allergies. Blood samples drawn during the shock showed plasma histamine and serum tryptase concentrations of 716 nmol/l ($N < 6$) and 233 µg/l ($N < 13.5$), respectively. Drug hypersensitivity was investigated by skin testing a few weeks later. Skin-prick test results were negative for latex, egg, and soy. Intradermal tests were performed with 0.02 ml, using serial dilutions in saline physiologic solution (9 mg/ml NaCl) of commercially available drugs. The first dilution was 1/1,000 for all drugs except for muscle relaxants (1/100,000). A skin-prick test with 10 mg/ml histamine (positive control) was done to ensure a normal skin reactivity. Tests were read after 15 min. Intradermal test results were regarded as positive if the mean wheal (W) diameter was equal or higher than 5 mm and a larger flare (F), without reaction to negative control (0.02 ml saline). In the case of a negative test result, a higher concentration was tested after a 20-min interval. Intradermal test results were positive for succinylcholine (W/F = 7/20 at 0.0001 mg/ml) and rocuronium (W/F = 8/30 at 0.01 mg/ml), negative for vecuronium (maximum studied concentration of 0.4 mg/ml), and pancuronium (maximum studied concentration of 0.2 mg/ml) and were doubtful (W/F = 4/10) for atracurium (maximum studied concentration of 0.01 mg/ml). Mivacurium was not tested. Propofol (maximum studied concentration of 1 mg/ml), sufentanil (maximum studied concentration of 0.5 µg/ml), alfentanil (maximum studied concentration of 0.05 mg/ml), and thiopental (maximum studied concentration of 2.5 mg/ml) were also tested, and the results were negative.

The patient was scheduled for a frontolateral laryngectomy 2 months later. Anesthesia was administered with thiopental, sufentanil, pancuronium, and isoflurane. One day after surgery, cervicofacial emphysema required a tracheotomy under local anesthesia. The postoperative course was uneventful.

Discussion

Injection of anesthetic agents may promote anaphylactoid (nonimmunologic mechanism) or anaphylactic shock (immunologic mechanism). Basophils are implicated during anaphylactoid reaction with histamine re-

* Resident in Anesthesiology, † Staff Anesthesiologist, ‡ Staff Allergist, § Staff Cardiologist, ¶ Professor of Anesthesiology and Chairman, Department of Anesthesiology.

Received from the Departments of Anesthesiology and Allergology and Cardiology, Hôpital Foch, Université Paris-Ouest, Suresnes, France. Submitted for publication July 16, 2001. Accepted for publication February 14, 2002. Support was provided solely from institutional and/or departmental sources.

Address reprint requests to Dr. Fischler: Service d'Anesthésie, Hôpital Foch, 40 rue Worth, 92151 Suresnes, France. Address electronic mail to: fischler@hopital-foch.org. Individual article reprints may be purchased through the Journal Web site, www.anesthesiology.org.

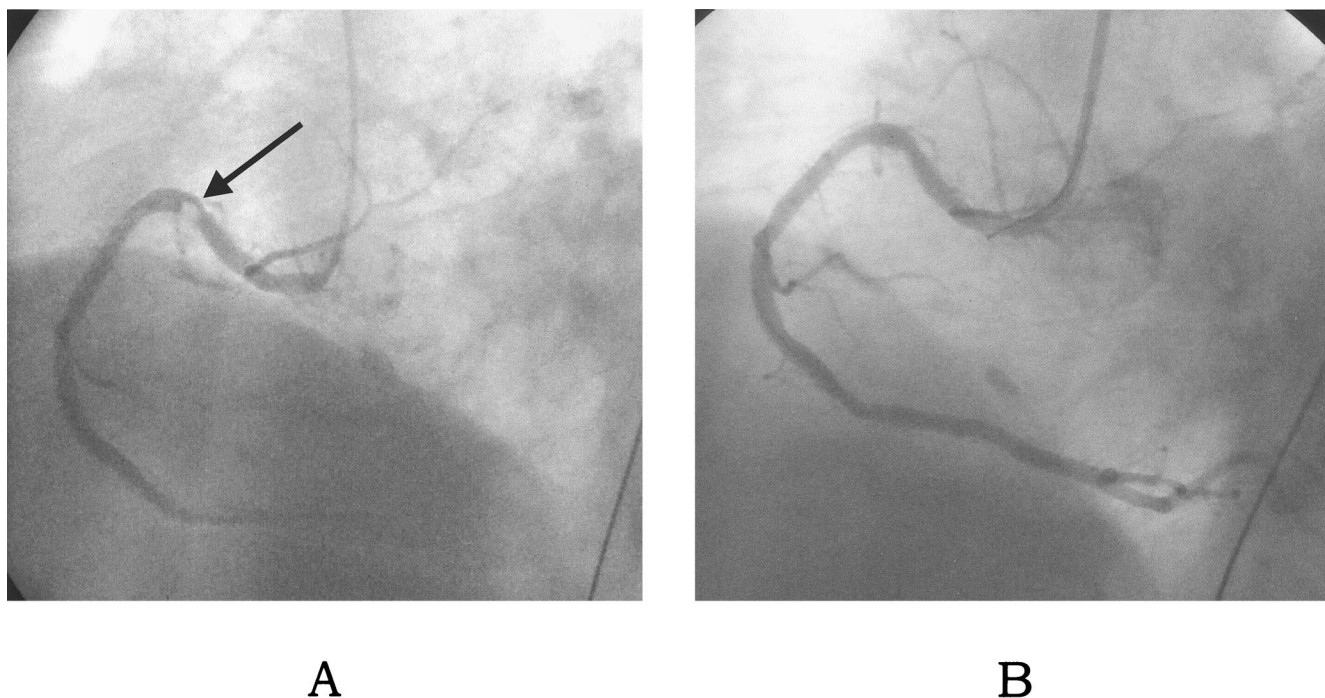


Fig. 1. (A) Thrombus surrounded by contrast medium in the proximal segment of the right coronary artery. (B) Disappearance of the thrombus after intracoronary injection of contrast medium.

lease. Anaphylactoid shock promotes the release of preformed (histamine, tryptase) or neoformed (prostaglandins, leukotrienes, platelet-activating factor) mediators by tissue mast cells and basophils. The reported case was a true anaphylactic shock following administration of succinylcholine because the intradermal test results were positive at a very high dilution and because the tryptase concentration was very high, confirming the immunologic origin of mast cell degranulation.^{3,4}

Our case was rated grade IV according to the Ring and Messmer classification of severe anaphylactoid reactions.⁵ It was peculiar in the sudden onset and severity of the cardiovascular symptoms (electromechanical dissociation) and the lag between the shock and the generalized erythema, which was probably due to the prolonged period of low cutaneous perfusion. The most striking feature was the seriousness of cardiovascular symptomatology. Various mechanisms may explain heart failure in anaphylactic or anaphylactoid reaction: sudden and massive cardiac release of histamine (immunoglobulin E-dependent specific immunologic reaction or nonspecific reaction), complement activation with production of anaphylatoxins C_{3a} and C_{5a} (cardiac anaphylaxis),⁶ myocardial ischemia or myocardial infarction, sudden and major decrease of venous return, or anoxia following an airway edema or severe bronchospasm.

Cases of myocardial ischemia or myocardial infarction following an anaphylactic or anaphylactoid shock are

rare. Mechanisms involved may be low coronary blood flow,¹ vasoconstriction or coronary spasm,⁷ high concentrations of catecholamines,⁸ histamine release,⁹ serotonin release,¹⁰ or thromboxane and leukotriene releases.¹¹ Coronary vasospasm due to inflammation mediators can be worsened by therapeutic epinephrine injection. Wasp stings have been reported as responsible for coronary spasm in a patient with normal coronary arteries.²

A different mechanism was possibly responsible for our case of acute myocardial ischemia. The coronary angiography performed 1 h after the beginning of the shock showed a thrombus in the proximal segment of the right coronary artery. Since the thrombus disappeared after injection with the contrast medium, we believe that it was recent and related to several possible mechanisms, which were perhaps associated: the hypotension and shock event causing potential low flow in the coronary circulation; the prothrombotic effects of epinephrine; a systemic coagulopathy due to the release of mediators, histamine, tryptase, kallikrein, and other potential mediators released during anaphylactic reaction.¹²

To our knowledge, this is the first reported case that shows the formation of a coronary thrombus following anaphylactic shock. The early coronary angiography, performed to investigate electrocardiographic and echocardiographic abnormalities, permitted detection of the thrombus in the right coronary artery.

References

1. Massing JL, Bentz MH, Schlessner P, Dumitru C, Louis JP: Myocardial infarction following a bee sting: A propos of a case and review of the literature. *Ann Cardiol Angeiol (Paris)* 1997; 46:311-5
2. Wagdi P, Mehan VK, Burgi H, Salzmann C: Acute myocardial infarction after wasp stings in a patient with normal coronary arteries. *Am Heart J* 1994; 128:820-3
3. Laroche D, Vergnaud MC, Sillard B, Soufarapis H, Bricard H: Biochemical markers of anaphylactoid reactions to drugs: Comparison of plasma histamine and tryptase. *ANESTHESIOLOGY* 1991; 75:945-9
4. Fisher MM, Baldo BA: Mast cell tryptase in anaesthetic anaphylactoid reactions. *Br J Anaesth* 1998; 80:26-9
5. Ring J, Messmer K: Incidence and severity of anaphylactoid reactions to colloid volume substitutes. *Lancet* 1977; 1:466-9
6. del Balzo U, Polley MJ, Levi R: Cardiac anaphylaxis: Complement activation as an amplification system. *Circ Res* 1989; 65:847-57
7. Ahmad S: Allopurinol and enalapril: Drug induced anaphylactic coronary spasm and acute myocardial infarction (letter). *Chest* 1995; 108:586
8. Berne RM: The effect of epinephrine and norepinephrine on coronary circulation. *Circ Res* 1958; 6:644-55
9. Laine P, Kaartinen M, Penttila A, Panula P, Paavonen T, Kovanen PT: Association between myocardial infarction and the mast cells in the adventitia of the infarct-related coronary artery. *Circulation* 1999; 99:361-9
10. Yildiz O, Smith JR, Purdy RE: Serotonin and vasoconstrictor synergism. *Life Sci* 1998; 62:1723-32
11. Shepherd JT, Vanhoutte PM: Mechanisms responsible for coronary vasospasm. *J Am Coll Cardiol* 1986; 8:50A-54A
12. Choi IH, Ha TY, Lee DG, Park JS, Lee JH, Park YM, Lee HK: Occurrence of disseminated intravascular coagulation (DIC) in active systemic anaphylaxis: Role of platelet-activating factor. *Clin Exp Immunol* 1995; 100:390-4