

Permanent Paraparesis and Cauda Equina Syndrome after Epidural Blood Patch for Postdural Puncture Headache

James H. Diaz, M.D., Dr.P.H.

EPIDURAL blood patch (EBP) is now recommended as the treatment of choice for managing postdural puncture headache (PDPH).¹⁻³ Choi² noted an initial success rate of 91% and a long-term success rate of 61% in managing PDPH with EBP. In a prospective study of 504 patients undergoing EBP for PDPH, however, Safa-Tisseront *et al.*³ observed less initial success in managing PDPH with EBP and reported complete relief of symptoms in 75% of patients, incomplete relief in 18%, and failure in 7%. The currently recommended volume of autologous blood for EBP is 10–20 ml^{1,2}; however, repeated EBPs for refractory PDPH have used larger volumes of autologous blood.^{4,5} We report a case of permanent spastic paraparesis with cauda equina syndrome after EBP with 30 ml of autologous blood for the successful management of PDPH.

Case Report

A 52-yr-old woman with a past history of hypothyroidism, L5-S1 discectomy in 1986, and prolonged cervical pain and facial numbness from an automobile accident in 1998, underwent outpatient lumbar puncture (LP) in 1999 to rule out multiple sclerosis (table 1). The LP was performed atraumatically with a 22-gauge, noncutting spinal needle, at the L2-L3 interspace and the upper pole of the earlier laminectomy scar. Cerebrospinal fluid (CSF) analysis, clotting studies, serum chemistries, and hematologic indices were within normal limits. Postural, bilateral, frontoparietal headache with occipital radiation, photophobia, and nausea began the morning after the LP, and worsened over the next 2 days. On the third day after LP, the patient, who remained afebrile, underwent outpatient EBP for PDPH, performed by an anesthesiologist in the emergency department. The EBP was performed atraumatically in the left lateral decubitus position with a 17-gauge Tuohy needle inserted in the midline at the L2-L3 previous LP site through a 1% lidocaine skin wheal. A loss-of-resistance technique with preservative-free normal saline and no air was used to detect epidural space entry. On epidural space entry, no paresthesias, blood, or CSF were noted. No air or local anesthetics were administered into the epidural space. During slow epidural injection of 30 ml of autologous blood, the patient reported no low back, buttock, or

lateralizing leg pain. The patient was then placed at supine bedrest, reported 90–95% improvement in her postural headache and associated symptoms, and was discharged from the emergency department 30 min after the EBP.

Although her postural headache improved, the patient experienced low back pain after returning home. Over the next 48 h (days 1–2), the low back pain worsened and was associated with lumbar and left leg muscle spasms and radiating radicular pain in the left leg and foot. On the third day after EBP, the patient was believed to have routine, resolving sequelae from successful EBP on examination by her personal physician, who detected no neurologic signs and prescribed oral gabapentin for pain. On the fourth day after EBP, the patient was again believed to exhibit sequelae of successful EBP on examination by a consultant anesthesiologist, who did not perform the EBP. The patient continued to experience low back and left leg radicular pain, which limited ambulation. The patient continued taking gabapentin for pain and avoided anticoagulants, nonsteroidal antiinflammatory drugs, and herbal supplements. On post-EBP day 12, urinary incontinence and paraparesis of the left leg developed in the patient. An immediate magnetic resonance imaging (MRI) study of the lumbar spine showed a sausage-shaped mass in the posterior lumbar spinal canal, extending from L2-L4, and causing extrinsic spinal cord compression at L2-L3. Despite improvement in back pain and leg weakness after 24 h of intravenous dexamethasone, as recommended by the neurosurgical consultant, the patient continued to have back pain and left foot weakness. On post-EBP day 13, the neurosurgeon recommended lumbar laminectomy with evacuation of lumbar epidural hematoma.

Extending the earlier lumbar laminectomy incision, the neurosurgeon performed a laminectomy from L2-L4 and observed an organized subdural hematoma, sandwiched between the dura and arachnoid mater. Although the MRI had suggested a posterior epidural hematoma, laminectomy uncovered a subdural hematoma that extended from L2-L4, and compressed the arachnoid mater against the exiting spinal nerves bilaterally. The subdural hematoma was evacuated, and the dura and other soft tissues were closed in layers. Postoperatively, the low back pain and muscle spasms improved, but severe left hip and leg pain continued. A spinocutaneous fistula with a CSF leak developed during ambulation on the fourth postoperative day, and was managed medically with antibiotics and fluid restriction. Lumbar MRI on the seventh postoperative day revealed a cystic CSF collection from L2-L5. The recent laminectomy incision was reexplored by another neurosurgical consultant; several dural leaks were identified, oversewn, and resealed with fibrin glue.

Over the next year, bilateral leg weakness, opisthotonic muscular spasms in the lower back and left leg, urinary incontinence, and sexual dysfunction, consistent with spastic paraparesis and cauda equina syndrome developed in the patient. The muscular spasms were associated with painful accentuated lumbar lordosis and spastic inversion of the left foot. The diagnosis of multiple sclerosis was excluded from the current illness by normal CSF analysis, absence of cerebral and spinal sclerotic plaques on multiple neuraxial MRIs, and absence of ophthalmoplegia or other cranial nerve findings.

On referral to our pain clinic in November 2000, the patient was taking several oral medications for anxiety and pain (citalopram, alprazolam, propoxyphene), and for painful spasticity (diazepam, baclofen, tizanidine). A physical examination revealed a wobbly, cane-supported gait with left foot drop, bilateral sacroiliac tenderness, well-healed lumbar laminectomy scars, patellar hyporeflexia, and Achilles areflexia.

Professor of Anesthesiology (Pain Management) and Public Health and Preventive Medicine (Occupational and Environmental Medicine), Departments of Anesthesiology, and Public Health and Preventive Medicine.

Received from the Louisiana State University Health Sciences Center (LSUHSC), The LSUHSC Multidisciplinary Pain Mastery Center, New Orleans, Louisiana. Submitted for publication September 20, 2001. Accepted for publication January 2, 2002. Support was provided from institutional and/or departmental sources and by a State Grant from the Health Education Fund (HEF) of the Board of Regents, State of Louisiana, entitled "The Center for Occupational Medicine Research" (HEF grant No. 2000-05 07).

Address reprint requests to Dr. Diaz: Department of Public Health and Preventive Medicine, Louisiana State University School of Medicine, 1600 Canal Street, Suite 800, New Orleans, Louisiana 70112. Address electronic mail to: jdiaz@lsuhsc.edu. Individual article reprints may be purchased through the Journal Web site, www.anesthesiology.org.

Table 1. Chronology and Outcome of Treatments

Date	Procedure or Treatment	Neurologic Outcome
August 25, 1999	Lumbar puncture	Postdural puncture headache
August 28, 1999	Epidural blood patch	Headache resolved; low back and radicular pain
September 11, 1999	L2–L4 lumbar laminectomy	Spinal decompression and subdural hematoma evacuation
September 18, 1999	Reexploration of lumbar laminectomy	Repair of multiple dural leaking sites
September 1999–present	Medical management and physical therapy	Spastic paraparesis and cauda equina syndrome

The patient began taking a new combination of oral medications for anxiety and chronic pain (zolpidem, tramadol, gabapentin, rofecoxib) and for painful myospasticity (baclofen, tizanidine), and was gradually weaned from the propoxyphene and benzodiazepines. With the addition of aggressive physical therapy and plantar left foot support, the patient's pain and mobility improved over the next 6 months with fewer myospastic attacks.

Discussion

Epidural blood patch (EBP) is the currently accepted treatment of choice for postdural puncture headache (PDPH) because of its high initial success rates (over 70%), low failure rates (less than 10%), and infrequent complications.^{1–3} The ideal volume of blood to be injected during EBP is between 10 and 20 ml, although some investigators have recommended larger volumes as directed by the onset of backache, neckache, or radicular pain.^{1,3–5} Bart and Wheeler⁶ compared treatment with EBP using 10 ml of autologous blood with epidural saline patch (ESP) of 30 ml in patients with PDPH after spinal anesthetics with 25-gauge needles and epidural anesthetics with 17-gauge needles. In the PDPH populations compared, EBP was significantly superior to ESP in resolving PDPH.⁶ Taivainen *et al.*⁵ compared EBP for PDPH using 10 ml of autologous blood to EBP for PDPH with 11 to 15 ml of blood and found no difference between the 2 groups.

The most common complication associated with EBP is low back pain.⁷ Other rare, transient complications have included aseptic meningitis,⁸ lumbovertebral syndrome,⁹ radicular pain,¹⁰ bradycardia,¹¹ fever,¹² and seizures.¹³ Spinal hematoma is a known complication of dural puncture. It may occur spontaneously, and can cause transient or permanent paraparesis.^{14,15} Spinal hematoma has also occurred after dural puncture in anticoagulated patients,^{15,16} and in patients with renal failure,¹⁷ liver failure,¹⁸ and thrombocytopenia.¹⁸ Tekkok *et al.*¹⁹ reported the surgical evacuation of a spinal epidural hematoma in a woman without coagulopathy, who underwent a series of six EBPs to manage PDPH after repeated epidural phenol injections for chronic pain.

In this case, EBP was successful in relieving PDPH, was associated with common side effects, and was not associated with excessive bleeding, paresthesias, or recognized dural puncture. The delayed presentation of severe neurologic findings in this case was inconsistent

with pioneering animal investigations conducted by Di-Giovanni *et al.*²⁰ that demonstrated disappearance within days of 2 ml of autologous blood injected epidurally in goats. The 30-ml EBP clotted, initially relieving PDPH; defibrinated over time; and reorganized into a dense mass, possibly more seroma than hematoma, by post-EBP day 12. In addition, the contribution of leaking CSF to the mass effect may have expanded the remaining elements of the EBP and the phagocytic process, contributing progressively to the compression of the terminal spinal cord and cauda equina. The initial MRI study demonstrated a lumbar mass effect that caused extrinsic cord compression from L2–L4, consistent with a posterior spinal epidural hematoma. However, spinal decompression showed the hematoma to be sandwiched between the dura and arachnoid mater, tamponading any possible CSF leakage. Aldrete and Brown²¹ also reported subdural hematoma after EBP without observed dural puncture, but the EBP was injected through an epidural catheter presumed to have migrated intrathecally. Spinal reexploration for CSF fistula revealed multiple CSF leaks at previous LP and laminectomy sites. These dural rents may have opened subdural tunnels for the EBP to follow. Postlaminectomy fibrosis with obliteration of the epidural space may also have compromised epidural space identification, predisposing to dural puncture, as occurred in the case of subdural hematoma after repeated epidural phenol injections with presumed fibrosis.¹⁹

In conclusion, we have reported a case of permanent spastic paraparesis with the cauda equina syndrome after EBP for PDPH. The only steps in the EBP process in this case that were unconventional included an EBP volume of 30 ml and a short post-EBP supine observation period of 30 min, instead of the recommended 1–2 h.⁵ These steps were not, however, inconsistent with the experiences of other investigators, managing similar patients with PDPH by EBP.^{5,6} The low back and radicular pain reported by the patient during the week after EBP were assessed by two physical examinations and considered consistent with typical post-EBP sequelae. The dramatic onset of left leg weakness and urinary incontinence 12 days after EBP precipitated immediate radiographic and neurosurgical evaluation for spinal compression.

Epidural blood patch for PDPH should be limited to 10–20 ml of autologous blood, injected as close to the

initial dural puncture site as possible, with injection halted by patient reports of significant low back or leg pain. Epidural blood patch should be followed by a 1 to 2 h period of supine bedrest to allow the EBP to clot and adhere locally.⁵ Anesthesiologists must remain vigilant for spinal compression after EBP for PDPH, especially in postoperative laminectomy and postphenol neurolysis patients at greater risk of dural puncture.¹⁹ Surgical decompression of the terminal cord and cauda equina must be immediate, and complete recovery or transient neurologic outcomes cannot be assured.

References

1. Neal JM: Update on postdural puncture headache. *Techniques in Regional Anesthesia and Pain Management* 1998; 2:202-10
2. Choi PTL: Management of postdural puncture headache. *Techniques in Regional Anesthesia and Pain Management* 2001; 5:41-5
3. Safa-Tisseront V, Thormann F, Malassine P, Henry M, Riou B, Coriat P, Seebacher J: Effectiveness of epidural blood patch in the management of postdural puncture headache. *ANESTHESIOLOGY* 2001; 95:334-9
4. Szeinfeld M, Ilmeidan IH, Moser MM, Machado R, Klose KJ, Serafini AN: Epidural blood patch: Evaluation of the volume and spread of blood injected into the epidural space. *ANESTHESIOLOGY* 1986; 64:820-2
5. Taivainen T, Pitkenen M, Tuominen M, Rosenberg PH: Efficacy of epidural blood patch for postdural puncture headache. *Acta Anaesthesiol Scand* 1993; 37:702-5
6. Bart AJ, Wheeler AS: Comparison of epidural saline placement and epidural blood placement in the treatment of post-lumbar-puncture headache. *ANESTHESIOLOGY* 1978; 48:221-3
7. Abouleish E, De la Vega S, Blandinger I, Tio T: Long-term follow-up of epidural blood patch. *Anesth Analg* 1975; 54:459-63
8. Oh J, Camann W: Severe, acute meningeal irritative reaction after epidural blood patch. *Anesth Analg* 1998; 87:1139-40
9. Palmer JH, Wilson DW, Brown CM: Lumbovertebral syndrome after repeat epidural blood patch. *Br J Anaesth* 1997; 78:334-6
10. Cornwall RD, Dolan WM: Radicular back pain after lumbar epidural blood patch. *ANESTHESIOLOGY* 1975; 43:692-3
11. Andrews P, Ackerman W, Juneja M, Cases-Cristobal V, Rigor BM: Transient bradycardia associated with extradural blood patch after inadvertent dural puncture in patients. *Br J Anaesth* 1992; 69:401-3
12. Crawford JS: Experiences with epidural blood patch. *Anaesthesia* 1980; 35:13-5
13. Bolton V, Leight C, Scanlon T: Postpartum seizure after epidural blood patch and intravenous caffeine sodium benzoate. *ANESTHESIOLOGY* 1989; 70:146-9
14. Edleson R, Chernik N, Posner J: Spinal subdural hematomas complicating lumbar puncture. *Arch Neurol* 1974; 31:134-7
15. Owens E, Kasten G, Hessel E: Spinal subarachnoid hematoma after lumbar puncture and heparinization: A case report, review of the literature, and discussion of anesthetic implications. *Anesth Analg* 1986; 65:1201-7
16. DeAngelis J: Hazards of subdural and epidural anesthesia during anticoagulant therapy: A case report and review of the literature. *Anesth Analg* 1972; 51:676-9
17. Grejda S, Ellis K, Arino P: Paraplegia following spinal anesthesia in a patient with chronic renal failure. *Reg Anesth* 1989; 14:155-7
18. Laglia A, Eisenberg R, Weinstein P, Mani R: Spinal epidural hematoma after lumbar puncture in liver disease. *Ann Intern Med* 1978; 88:515-6
19. Tekkok IH, Carter DA, Brinker R: Spinal subdural haematoma as a complication of immediate epidural blood patch. *Can J Anaesth* 1996; 43:306-9
20. DiGiovanni AJ, Galbert MW, Wahle WM: Epidural injection of autologous blood for postlumbar-puncture headache. II. Additional clinical experiences and laboratory investigation. *Anesth Analg* 1972; 51:226-32
21. Aldrete JA, Brown TL: Intrathecal hematoma and arachnoiditis after prophylactic blood patch through a catheter. *Anesth Analg* 1997; 84:233-4

Anesthesiology 2002; 96:1517-8

© 2002 American Society of Anesthesiologists, Inc. Lippincott Williams & Wilkins, Inc.

Facilitation of Passing the Endotracheal Tube over the Flexible Fiberoptic Bronchoscope Using a Cook® Airway Exchange Catheter

Chakib M. Ayoub, M.D.,* Antoine M. Lteif, M.D.,* Marwan S. Rizk, M.D.,† Najj M. Abu Jalad, M.D.,† Usamah Hadi, M.D. ‡, Anis S. Baraka, M.D., F.R.C.A.§

THE advancement of the endotracheal tube (ETT) over a flexible fiberoptic bronchoscope (FOB) is often impeded by obstruction at the epiglottis or the arytenoids.¹⁻³ This is usually attributed to the creation of a cleft along the ETT bevel by the difference in the outer diameter (OD) of the FOB and the internal diameter of the ETT. Inability to pass the tube into the trachea leaves the airway unprotected and may also result in injuries to the larynx.

Various maneuvers and endotracheal tube designs have been described to overcome this problem. The current report was designed to assess the feasibility and ease of passing the ETT over the FOB by using a Cook® airway exchange catheter.²⁻⁴

* Assistant Professor, † Resident, § Professor and Chairman, Department of Anesthesiology; ‡ Clinical Associate Professor Department of Otolaryngology.

Received from the American University of Beirut Medical Center, Beirut, Lebanon. Submitted for publication August 8, 2001. Accepted for publication January 2, 2002. Support was provided solely from institutional and/or departmental sources.

Address reprint requests to Dr. Ayoub: Department of Anesthesiology, American University of Beirut, P.O. Box 11 0236, Beirut, Lebanon. Address electronic mail to: chakib.ayoub@aub.edu.lb. Individual article reprints may be purchased through the Journal Web site, www.anesthesiology.org.

Case Report

With institutional review board approval and patients' consent, 50 patients aged 20-76 yr, scheduled to undergo elective general anesthesia with tracheal intubation, were enrolled in the study. Patients included 23 women and 27 men, with ASA physical status I-III. Patients weighting more than 90 kg, patients having a history or signs of difficult airway, diabetics, and patients at risk for aspiration of gastric content were excluded from the study.

Anesthesia was induced with intravenous fentanyl 1 µg/kg, midazolam 1-2 mg, propofol 1-2 mg/kg, and vecuronium 0.1 mg/kg. After complete neuromuscular block was achieved as monitored by a peripheral nerve stimulator, a Berman intubating airway was inserted. One investigating anesthesiologist performed all of the tracheal intubations by advancing the FOB (3.8 mm Olympus LF2) through the oral airway, pharynx, larynx, and trachea until the carina was visualized. Mallinkrodt 7.5 and an 8.0 mm inner diameter (ID) endotracheal tube (ETT) were used for women and men respectively.

The lubricated ETT was then advanced into the oral airway with the preformed concavity oriented anteriorly (12 o'clock). If insertion was impeded, a lubricated 2.3 mm Cook® airway exchange catheter was inserted *via* the ETT beside the FOB until the tip of the catheter was visualized near the carina; the ETT was then advanced over the bronchoscope and the Cook® exchange catheter. If this maneuver failed to pass the tube into the trachea after two or three attempts, both the FOB and ETT were removed and tracheal intubation was performed by direct rigid laryngoscopy. In each case, the ease of ETT

Table 1. Ease of Advancing the Endotracheal Tube over the Cook® Airway Exchange Catheter into the Trachea

Successful advancement	No. of patients
Accomplished in one attempt	9
Accomplished in two to three attempts	6
Unsuccessful	1

The number of attempts required to achieve successful tracheal intubation using the Cook® airway exchange catheter.

advancement was graded as follows: grade I indicates successful advancement of the ETT over the FOB; grade II indicates successful advancement of the ETT over the FOB by using a Cook® airway exchange catheter; and grade III indicates that ETT passage was unsuccessful despite the use of the Cook® airway exchange catheter, and intubation was performed by direct laryngoscopy. Also, the incidence of successful advancement of the tube over the FOB and the Cook® airway exchange catheter passage into the trachea was compared with the incidence of failure to pass the tube. Each patient served as her or his own control.

Chi-square was used to compare the incidence of successful passage of the ETT over the FOB with the incidence of success after the use of the Cook® exchange catheter. $P < 0.05$ was considered statistically significant.

Fifty patients were enrolled in the study. There was no significant difference in age, sex, height, and score between grade I patients^{3,4} and grade II and grade III patients.^{1,6} The ETT was successfully advanced over the FOB in 68% of the patients (34 out of 50). The Cook® airway exchange catheter was used to treat the remaining 32% of patients (16 of 50 patients). Out of the 16 patients who used a Cook® catheter, successful intubation was 94% (15 of 16 patients). The incidence of success after the two techniques, *i.e.*, 68% versus 94%, was statistically significant ($P < 0.05$).

The resistance to passage of the 7.5 mm and the 8.0 mm ETT using the Cook® exchange catheter and the FOB was not different. Passing the tube was accomplished at the first attempt in 9 out of the 16 patients, after two to three attempts in 6 patients, and was unsuccessful in the last patient (table 1).

Discussion

The value of the flexible bronchoscope in the management of difficult tracheal intubation is well established. However, successful advancement of the FOB and visualization of the carina does not ensure successful advancement of the ETT over the FOB into the trachea. This was attributed to the “hanging up” of the tip of the conventional preformed plastic tubes (Murphy’s tip) on the epiglottis during nasal fiberoptic intubation, or the arytenoids during oral fiberoptic intubation.^{1,2} The cause of this hanging up is the creation of a cleft along the ETT bevel by the difference in the OD of the FOB and the internal diameter of the ETT. This situation may leave the airway unprotected, and may also result in airway bleeding, damage to the arytenoid cartilages or epiglottis, or swelling of the airway, making subsequent tracheal intubation attempts more difficult.

To overcome this obstruction, rotating the ETT 90° counterclockwise has been advocated.² This will allow the Murphy’s tip to realign from the horizontal to the vertical plane, making it less likely to encounter any

laryngeal structures.⁵ Brull recommended using a spiral-wound wire reinforced ETT.⁴ The greater side-to-side flexibility and the more obtuse angle at the distal end makes it less likely to impinge on pharyngeal structures, epiglottis, or the arytenoid cartilages during its advancement into the trachea. Marsh⁶ and Rosenblatt⁷ proposed the double setup tubes; they have shown that when the tip of an uncuffed lubricated pediatric ETT protrudes beyond the tip of the ETT to be used during fiberoptic intubation, it will fill the space that otherwise exists between the latter tube and the FOB. This minimizes the difference in diameters and allows the tube to be easily threaded into the trachea.

In the current report, we have found that inserting a Cook® airway exchange catheter beside the FOB facilitates the advancement of the ETT into the trachea, without the need for external laryngeal manipulation of the neck or 90° counterclockwise rotation of the tube, or both. This may be explained by the fact that the presence of the FOB and the Cook® airway exchange catheter together within the lumen of the ETT may decrease the size of the cleft and consequently centralize the ETT in front of the glottis. As a result, the likelihood of impingement on the arytenoid cartilages will decrease, and the chances of passing the ETT into the trachea without resistance will increase.

The presence of the FOB in the trachea allows the visualization of the tip of the Cook® airway exchange catheter, which will confirm its proper positioning and prevents its overinsertion, and hence will minimize the possible risks associated with the use of these catheters.⁸

In conclusion, the current report shows that advancing the endotracheal tube into the trachea over the FOB may fail in almost one-third of patients. In these patients, successful tracheal intubation can be achieved by introducing a Cook® airway exchange catheter beside the FOB. The successful passage may result from centralizing the tube by both the FOB and the Cook® catheter in front of the glottis, which decreases the likelihood of impingement on the arytenoids.

References

1. Ovassapian A, Yelich SJ, Dykes MHM, Brunner EE: Fiberoptic nasotracheal intubation—incidence and causes of failure. *Anesth Analg* 1983; 62:692–5
2. Schwartz D, Johnson C, Roberts J: A maneuver to facilitate flexible fiberoptic intubation. *ANESTHESIOLOGY* 1989; 71:470–1
3. Katsnelson T, Frost EA, Farcon E, Goldinger PL: When the endotracheal tube will not pass over the flexible fiberoptic bronchoscope. *ANESTHESIOLOGY* 1992; 76:151–2
4. Brull SJ, Wiklund R, Ferris C, Conelly NR, Ehrenwerth J, Silverman DG: Facilitation of fiberoptic orotracheal intubation with a flexible tracheal tube. *Anesth Analg* 1994; 78:746–8
5. Rogers S, Benumof J: New and easy techniques for fiberoptic endoscopy-aided tracheal intubation. *ANESTHESIOLOGY* 1983; 59:569–72
6. Marsh NJ: Easier fiberoptic intubations. *ANESTHESIOLOGY* 1992; 76:860–1
7. Rosenblatt WH: Overcoming obstruction during bronchoscope-guided intubation of the trachea with the double setup endotracheal tube. *Anesth Analg* 1996; 83(1):175–7
8. Baraka A: Tension pneumothorax complicating jet ventilation via a Cook® airway exchange catheter. *ANESTHESIOLOGY* 1999; 91(2):557–8

Failed Intubation Managed with Subcricoid Transtracheal Jet Ventilation followed by Percutaneous Tracheostomy

Jigeeshu V. Divatia, M.D.,* Nilu Bhadra, M.D.,† Atul P. Kulkarni, M.D.,‡ Sanjay M. Upadhye, M.D.,*

FAILED intubation, coupled with the inability to ventilate the lungs of an apneic patient by use of facemask, is a life-threatening emergency. Transtracheal jet ventilation (TTJV) is an established technique of providing emergency airway access and maintaining gas exchange in a cannot-intubate, cannot-ventilate situation.^{1,2} This is, however, a temporary measure, and it may be necessary to establish a definitive airway. The authors report a case in which emergency ventilation in a cannot-intubate, cannot-ventilate situation in the intensive care unit (ICU) was initiated with TTJV through an endotracheal cannula inserted below the cricoid cartilage. Airway access was secured by percutaneous tracheostomy performed over a guide wire inserted through the transtracheal cannula.

Case Report

A 66-yr-old, 59-kg woman was brought to the ICU with severe airway obstruction from a large 8 × 10 cm, stony hard, lobulated tumor on both sides of the neck and crossing the midline. She was unresponsive and cyanotic, with slow, gasping respirations. Her heart rate was 70 beats/min and SpO₂ was 70%. Urgent tracheal intubation was performed by the consultant intensivist. Laryngoscopy allowed us to easily visualize the larynx; however there was considerable resistance to passage of the endotracheal tube beyond the vocal cords. The airway was secured with a 6.0-mm cuffed endotracheal tube and mechanical ventilation was initiated. After 1 h, the patient was conscious and responsive, her SpO₂ had increased to 98%, and she was hemodynamically stable. She received chemotherapy for a presumptive diagnosis of lymphoma. The plan was to extubate the trachea, if the tumor proved to be responsive to chemotherapy. The patient also received enteral feeds *via* a nasogastric tube.

Five days later, there was minimal reduction in the size of the tumor. That afternoon, the patient self-extubated. There was considerable bleeding from the oral cavity. At the same time, she vomited. Oral suction was performed, and 100% oxygen was given by facemask and a self-inflating bag with a reservoir. Her saturation concentration decreased to 85%. Direct laryngoscopy failed to visualize the larynx because of profuse bleeding, the presence of vomitus, and distorted anatomy. The patient then became apneic, and bag and mask ventilation proved to be impossible, despite insertion of an oropharyngeal airway. Her SpO₂ decreased to 65%. We then decided to perform TTJV.

On extension of the neck, the cricoid cartilage could be identified with some difficulty. The cricothyroid membrane was covered by the

tumor and could not be identified; however, the tumor mass was not as prominent about a finger's breadth below the cricoid cartilage. By this time SpO₂ had decreased to 40%. A 14-gauge needle was inserted at the first attempt into the trachea, below the cricoid cartilage. Jet ventilation was delivered by a manual jet injector connected to the wall oxygen outlet, with the pressure reduced to 40 psi. There was effective expansion of the chest; simultaneously, air was noticed blowing out from the pharynx and mouth. Manual jet ventilation was continued to produce adequate chest expansion, at a rate of 10-12 breaths/min. The patient's SpO₂ increased to 95%.

We then proceeded with a percutaneous tracheostomy using the Griggs technique³ and the SIMS Portex (SIMS Portex Limited, Hythe, Kent, UK) kit.⁴ A guide wire was passed through the tracheal cannula, into the trachea, and the cannula was removed. A skin incision was made around the guidewire. A short tapered dilator was smoothly introduced into the trachea over the guide wire. The guide wire was removed, the jet injector was then connected to the hub of this dilator, and jet ventilation was given for 2 min more. SpO₂ was steady at 96-97%. The guide wire was reintroduced through the dilator. The dilator was removed and the skin and subcutaneous tissues, including the tumor, were dilated with the guide wire dilating forceps. The dilating forceps were introduced one more time to dilate the opening in the trachea. The tracheostomy tube was then passed into the trachea over the guide wire. There was no bleeding or difficulty in stretching the tumor tissue, and the procedure, from the time of needle entry into the trachea, took less than 5 min. After confirming the position of the tracheostomy tube, the patient underwent mechanical ventilation and FiO₂ was 1.0. Her SpO₂ increased to 99%, heart rate was 110 beats/min, and blood pressure was 150/90 mmHg. The next morning she was fully awake, responsive, and could be weaned from mechanical ventilation.

Discussion

Several techniques, including TTJV, ventilation *via* a laryngeal mask airway, or percutaneous tracheostomy has been used to manage difficult or failed intubation.^{1,5-7} Needle or surgical cricothyroidotomy have also been advocated to obtain rapid and safe access to the airway in an emergency because the cricothyroid membrane has no major anatomic structures closely related to it, is relatively avascular, and is easy to locate by palpation of the neck. However, in our patient, palpation of the thyroid cartilage was impossible; the cricoid cartilage was located with difficulty, and the cricothyroid membrane was obscured by the tumor. It was possible to puncture the trachea below the cricoid cartilage. Having obtained airway access and established adequate ventilation by TTJV, it was now possible to proceed with percutaneous tracheostomy by introducing the guide wire through the same cannula.

The SIMS Portex PT kit contains a short, hollow, tapered dilator to calibrate the hole made by the needle in the trachea to the size of the guide wire dilating forceps.

* Professor, † Senior Registrar, ‡ Lecturer, Department of Anaesthesia, Critical Care, and Pain.

Received from the Tata Memorial Hospital, Parel, Mumbai, India. Submitted for publication August 14, 2001. Accepted for publication January 3, 2002. Support was provided solely from institutional and/or departmental sources.

Address correspondence to Dr. Divatia: Department of Anaesthesia, Critical Care, and Pain, Tata Memorial Hospital, Dr. E. Borges Road, Parel, Mumbai, 400012, India. Address electronic mail to: jdivatia@vsnl.com. Reprints will not be available from the authors. Individual article reprints may be purchased through the Journal Web site, www.anesthesiology.org.

The ability to attach the jet injector to the hub of the dilator and perform TTJV through it increased the safety of the procedure. It enabled us to ventilate the lungs again, after the initial period of TTJV given through the cannula, before dilatation of the trachea with the guide wire dilating forceps.

In this patient, the use of TTJV was potentially hazardous, and the risk of barotrauma was extremely high because of upper airway obstruction by the tumor.⁸ However, during the unsuccessful attempts at intubation, some air bubbles expelled from the larynx could be seen with every expiration, indicating that the airway was at least partially patent. During spontaneous respiration, tumors in the neck produce dynamic airway obstruction that is more pronounced during inspiration than during expiration. An added advantage of TTJV is that blood and secretions are blown away from the laryngeal inlet during inspiration by upward flow of gas through the larynx as the pressure increases in the chest, and during expiration, when all the gas flow is upward through the larynx.⁹

In this patient, other potential problems included bleeding during tracheal puncture and malplacement of the guide wire and tracheostomy tube. Problems related to malplacement can be avoided by fiberoptic bronchoscopic guidance during percutaneous tracheostomy.^{10,11} While this was clearly impossible in this patient, it can increase the safety of the procedure in other situations where the airway is not obstructed and the oropharynx is not contaminated.

We believe this is the first report on the combined use

of TTJV and percutaneous tracheostomy in a cannot-intubate, cannot-ventilate situation. This concept is useful and should be considered in the management of failed intubation, especially when neck anatomy is better preserved and there is no upper airway obstruction. Percutaneous tracheostomy should be included in every failed intubation drill or difficult airway algorithm, and anesthesiologists must acquire the necessary training and skills to be able to perform percutaneous tracheostomy.

References

1. Caplan R, Benumof JL, Berry FA, Blitt CA, Bode RH, Cheney FW, Connis RT, Guidry DR, Ovassapian A: Practice guidelines for management of the difficult airway: A report of the ASA Task Force on Management of the Difficult Airway. *ANESTHESIOLOGY* 1993; 78:597-602
2. Benumof JL: The importance of transtracheal jet ventilation in the management of the difficult airway. *ANESTHESIOLOGY* 1989; 71:769-78
3. Griggs WM, Worthley LIG, Gilligan JE, Thomas PD, Myburg JA: A simple percutaneous tracheostomy technique. *Surgery, Gynecology and Obstetrics* 1990; 170:543-5
4. Caldicott LD, Oldroyd GJ, Bodenham AR: An evaluation of a new percutaneous tracheostomy kit. *Anaesthesia* 1995; 50:49-51
5. Benumof JL: Laryngeal mask airway and the ASA difficult airway algorithm. *ANESTHESIOLOGY* 1996; 84:686-99
6. Griggs WM, Myburg JA, Worthley LIG: Urgent airway accesses: An indication for percutaneous tracheostomy? *Anaesth Intens Care* 1991; 19:586-7
7. Dob DP, McLure HA, Soni N: Failed intubation and emergency percutaneous tracheostomy. *Anaesthesia* 1998; 53:72-4
8. Smith RB, Schaer WB, Pfaeffle H: Percutaneous transtracheal ventilation for anaesthesia and resuscitation: A review and report of complications. *Can Anaesth Soc J* 1975; 22:607-12
9. Layman PR: Transtracheal ventilation in oral surgery. *Ann Royal Coll Surg Engl* 1983; 65:318-20
10. Paul A, Marelli D, Chiu RCJ, Vestweber KH, Mulder DS: Percutaneous endoscopic tracheostomy. *Ann Thorac Surg* 1989; 47:314-5
11. Berrouschot J, Oeken J, Steiniger L, Schneider D: Perioperative complications of percutaneous tracheostomy. *Laryngoscope* 1997; 107:1538-44

Anesthesiology 2002; 96:1520-2

© 2002 American Society of Anesthesiologists, Inc. Lippincott Williams & Wilkins, Inc.

Aortic Injury and Cardiac Tamponade as a Complication of Subclavian Venous Catheterization

Pascal Fangio, M.D.,* Eric Mourgeon, M.D.,† Antoinette Romelaer, M.D.,‡ Jean-Pierre Goarin, M.D.,† Pierre Coriat, M.D.,§ Jean-Jacques Rouby, M.D., Ph.D.¶

DURING routine placement of a subclavian venous catheter for parenteral nutrition, aortic puncture occurred, resulting in cardiac tamponade. The authors describe a rare but dramatic complication of subclavian venous catheterization. Guidelines to prevent and manage this unusual adverse event are proposed.

* Resident, † Assistant Professor, ‡ Medical Student, ¶ Professor of Anesthesiology and Director, Surgical Intensive Care Unit Pierre Viars; § Professor of Anesthesiology and Chairman, Department of Anesthesiology and Intensive Care.

Received from the University-Hospital Pitié-Salpêtrière, University of Paris VI, Paris, France. Submitted for publication August 8, 2001. Accepted for publication January 15, 2002. Support was provided solely from institutional and/or departmental sources.

Address reprint requests to Dr. Mourgeon: Réanimation Chirurgicale "Pierre Viars," Département d'Anesthésie et de Réanimation Chirurgicale, Hôpital de la Pitié-Salpêtrière, 47-83 boulevard de l'Hôpital, 75013 Paris, France. Address electronic mail to: eric.mourgeon@psl.ap-hop-paris.fr. Individual article reprints may be purchased through the Journal Web site, www.anesthesiology.org.

Case Report

A 46-yr-old woman was admitted to our surgical intensive care unit for a peritonitis-induced septic shock after multiple knife injuries to the bowel. On day 10 of the patient's hospitalization, a central venous catheter was to be placed for additional parenteral nutrition. An experienced physician (more than 50 subclavian venous catheterizations) performed the procedure. After two attempts using the right infraclavicular approach, arterial puncture with an 18-gauge needle, attested by pulsatile red blood return, occurred. After needle removal and manual compression, the right subclavian vein was successfully cannulated. Several minutes later, a sinus tachycardia followed by hemodynamic instability appeared, requiring fluid resuscitation with 1000 ml of hydroxyethylstarch, which resulted in a marked increase in central venous pressure (from 4 to 22 mmHg). A hemopneumothorax was ruled out by bedside chest radiography. Despite fluid infusion, hemodynamic instability increased, leading to paradoxical bradycardia and circulatory arrest. After tracheal intubation, cardiac massage, and intravenous injection of 5 mg of epinephrine, an adequate circulatory

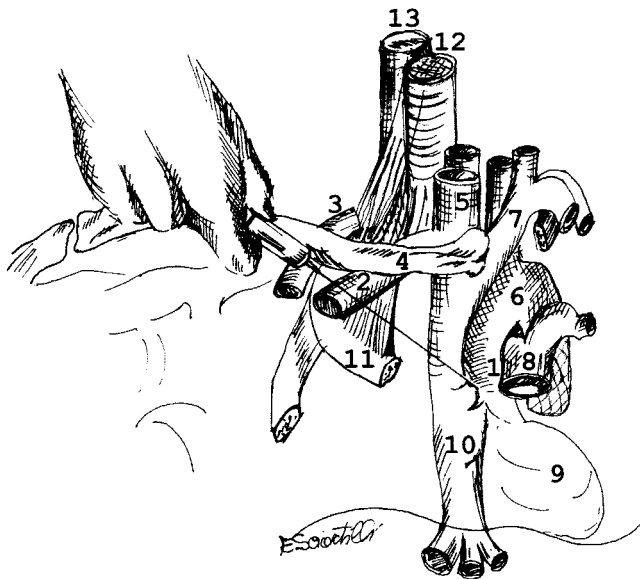


Fig. 1. Suspected needle direction that led to aortic perforation. (1) Ascending aorta; (2) right subclavian vein; (3) right subclavian artery; (4) clavicle; (5) right internal jugular vein; (6) aortic arch; (7) innominate brachiocephalic vein; (8) pulmonary artery; (9) left ventricle; (10) inferior vena cava; (11) first rib; (12) trachea; (13) esophagus.

state was restored in less than 5 min. Transthoracic echocardiography demonstrated a large amount of intrapericardial fluid compressing right cardiac chambers, allowing the diagnosis of cardiac tamponade. The patient was immediately transported to the operating room with an epinephrine infusion for urgent sternotomy. Three hundred milliliters of fresh blood were removed from the pericardium through the pericardiotomy. A punctiform perforation of the right anterolateral side of the intrapericardial ascending aorta was identified with active bleeding, and sutured by a single stitch of polypropylene. Neither pericardium nor cardiac cavity injuries were found. No related complications occurred in the first 2 weeks after sternotomy. Nevertheless, 3 weeks after thoracic surgery, the patient died of multiple organ failure, after ventilator-associated pneumonia developed.

Discussion

Complications after subclavian vein catheterization are not rare, especially immediate complications during the procedure. In a prospective study, 821 patients were randomly assigned to subclavian vein catheterization with or without ultrasound-guided location of the vein. Acute complications occurred in eighty patients (9.7%), including misplacement (6%), subclavian arterial puncture (3.7%), pneumothorax (1.5%), and mediastinal hematoma (0.6%).¹ These complications occurred in over one-quarter of the patients in whom catheterization was unsuccessful. Cardiac tamponade after the placement of central venous catheter by direct perforation of the right ventricle,^{2,3} superior vena cava, or right atrium has also been described.⁴

We report a case of injury to the intrapericardial-ascending aorta complicated by cardiac tamponade during attempted subclavian vein catheterization. Five cases have been reported in the literature.⁵⁻⁸ Reviewing these

case reports, together with ours, some common characteristics can be identified. The accidental puncture of the right lateral side of the ascending aorta is always reported in the context of multiple and unsuccessful puncture attempts of the right subclavian vein. Bleeding from the perforation of the intrapericardial ascending aorta results in rapid filling of the pericardium, which induces cardiac tamponade and cardiac arrest. In three cases, the diagnosis of hemothorax and aortic injury was only autopsy-proven. In the other two, a pericardiocentesis was done, followed rapidly by a sternotomy and an anterolateral thoracotomy that allowed identification of the aortic injury.^{6,7}

Injury of the ascending intrapericardial aorta by needle puncture during a right subclavian vein catheterization attempt is a rare but potentially lethal acute complication that must be acknowledged and recognized by all physicians involved in the placement of central venous catheterization. In all of the cases reported, including ours, aortic injury occurred exclusively after an infraclavicular approach of the right subclavian vein. Nevertheless, injury of the aortic arch through the left lung has also been reported once, during routine placement of a left subclavian venous catheter.⁹ This could be explained by the relatively close anatomic links between the right brachiocephalic venous trunk, and down and backward, the right lateral side of the ascending aorta. Incorrect technique, evidenced by improper direction of the needle toward the down and backward direction, predisposes the patient to aortic injury (fig. 1).

Several practical recommendations can be proposed to avoid and manage this particular complication. It is important to weigh the potential benefit of a subclavian vein catheterization against the risk of immediate complications. Because of possible arterial puncture, bleeding disorders should lead us to prefer a different venous access. The procedure should be discontinued after attempts are repeatedly unsuccessful, and if another site is considered, the contralateral subclavian one should be ruled out. In a prospective trial evaluating the complications and failures of subclavian vein catheterization,¹ the strongest predictor of complication using an univariate analysis was failed catheterization attempt. The complication rate was 4.3% for one needle pass, 10.9% for two needle passes, and 24% for three or more passes. Complications and failures were also found to occur twice as frequently in patients who were especially thin or obese or who had previously undergone major surgery, radiotherapy, or catheterization in the region; this was not the case of our patient. Moreover, an initial failed attempt of subclavian vein catheterization by an operator does not seem predictive of a failed procedure at the same site by another operator, and the risk of complications does not increase.¹ Ultrasound guidance for subclavian venous access can be used with success to locate vascular structures, decreasing the number of failed catheter place-

ments and complications.¹⁰ Nevertheless, in the study by Mansfield *et al.*, this approach had no effect on the incidence of complications and failures.¹ Moreover, these guided techniques are not cost-effective, and require training. Their use in treating patients with predicting factors of immediate complications must be studied. When arterial puncture is observed during attempted venous cannulation, especially if it was difficult, the patient should be carefully examined and monitored to detect early symptoms of cardiac tamponade. Continuous measurement of central venous pressure can be helpful. If hemodynamic instability occurs, a chest radiograph should first exclude tension pneumothorax or hemothorax. Urgent transthoracic echocardiography should then be performed. Once cardiac tamponade is diagnosed, single pericardiocentesis is not an adequate treatment and thoracotomy should be undertaken without delay. Pericardiocentesis alone is always unsuccessful because of uncontrolled bleeding from the aortic perforation, which has to be repaired surgically. In case of inadvertent placement of the catheter in the aorta, suspected on chest radiograph, the catheter should not be removed, but its

location precisely established by angiography or chest computed tomography. Surgical removal is mandatory to prevent uncontrolled bleeding or cardiac tamponade.⁷

References

1. Mansfield PF, Hohn DC, Fornage BD, Gregurich MA, Ota DM: Complications and failures of subclavian-vein catheterization. *N Engl J Med* 1994; 331:1735-8
2. Porter JM, Page R, Wood AE, Phelan D: Ventricular perforation associated with central venous introducer-dilator systems. *Can J Anaesth* 1997; 44:317-20
3. Dane TE, King EG: Fatal cardiac tamponade and other mechanical complications of central venous catheters. *Br J Surg* 1975; 62:6-10
4. Barton BR, Hermann G, Weil R III: Cardiothoracic emergencies associated with subclavian hemodialysis catheters. *JAMA* 1983; 250:2660-2
5. Simstein NL, Poole GV Jr, Nelson LH: Perforation of the intrapericardial aorta during subclavian catheterization (case report). *South Med J* 1984; 77:1605
6. Horowitz MD, Alkire MJ, Lickstein DA, Bauerlein EJ: Aortic injury as a complication of central venous catheterization. *Am Heart J* 1991; 122:595-7
7. Pan D, Moore HG, Angood P, Rabinovici R: Aortic injury resulting from attempted subclavian central venous catheter placement. *J Trauma* 1999; 47:403-5
8. Hamilton DL, Jackson RM: Haemopericardium: A rare fatal complication of attempted subclavian vein cannulation. A report of two cases. *Eur J Anaesthesiol* 1998; 15:501-4
9. Walser EM, Crow WN, Zwischenberger JB, Conti VR: Percutaneous tamponade of inadvertent transthoracic catheterization of the aorta. *Ann Thorac Surg* 1996; 62:895-6
10. Randolph AG, Cook DJ, Gonzales CA, Pribble CG: Ultrasound guidance for placement of central venous catheters: A meta-analysis of the literature. *Crit Care Med* 1996; 24:2053-8

Anesthesiology 2002; 96:1522-5

© 2002 American Society of Anesthesiologists, Inc. Lippincott Williams & Wilkins, Inc.

Synthetic Factor VIIa to Treat Dilutional Coagulopathy during Posterior Spinal Fusion in Two Children

Joseph D. Tobias, M.D.

COAGULATION disturbances and excessive surgical bleeding are major risks associated with any surgical procedure in which blood loss is common. In pediatric-aged patients, one of the more common surgical procedures associated with significant blood loss is posterior spinal fusion. During such procedures, blood loss may equal or exceed a blood volume.¹ When blood component therapy, including packed red blood cells, are used to replace blood loss, a dilutional coagulopathy can oc-

cur related either to thrombocytopenia or the dilution of coagulation factors. When abnormal coagulation function is demonstrated by prolongation of the prothrombin time (PT) and partial thromboplastin time (PTT), treatment generally includes the administration of fresh frozen plasma (FFP) and cryoprecipitate if the fibrinogen level is low. Although this therapy is generally effective, repeated doses of FFP may be required, and occasionally, coagulation disturbances persist. The author presents two children who developed dilutional coagulopathy during posterior spinal fusion for neuromuscular scoliosis. When FFP failed to correct the coagulopathy, synthetic factor VIIa (NovoSeven®, Novo Nordisk Pharmaceuticals, Princeton, NJ) was successfully used. The current status of synthetic factor VIIa and its potential role in the treatment of dilutional coagulopathy are discussed.

This article is accompanied by an Editorial View. Please see: Weiskopf RB: Intraoperative use of recombinant activated coagulation factor VII. *ANESTHESIOLOGY* 2002; 96:1285-6.

Professor, Departments of Child Health and Anesthesiology, The Division of Pediatric Critical Care/Pediatric Anesthesiology.

Received from the Department of Anesthesiology and Child Health, The University of Missouri, Columbia, Missouri. Submitted for publication July 2, 2001. Accepted for publication September 11, 2001. Support was provided solely from institutional and/or departmental sources.

Address reprint requests to Dr. Tobias: Director, Pediatric Critical Care/Pediatric Anesthesiology, Professor of Anesthesiology and Child Health, The University of Missouri, Department of Anesthesiology, 3W40H, One Hospital Drive, Columbia, Missouri 65212. Address electronic mail to Tobiasj@health.missouri.edu. Individual article reprints may be purchased through the Journal Web site, www.anesthesiology.org.

Case Report

Patient 1

An 8-yr-old, 26-kg girl with neuromuscular scoliosis presented for posterior spinal fusion. Anesthetic care included controlled hypotension with remifentanyl-isoflurane to maintain a mean arterial pressure of 55-65 mmHg. Aprotinin was administered in a dose of 30,000 units·kg⁻¹·h⁻¹. The coagulation parameters and treatments are

Table 1. Coagulation Parameters and Treatment Provided for Patient 1

Time	PT/INR/PTT (s), fibrinogen (mg/dl)		Treatment
Preoperative	14.1/1.1/33.2	384	None
Intraoperative (time, blood loss):			
2.0 h, 1,400 ml	16.4/1.4/38.1	278	1 Unit FFP
3.5 h, 2,100 ml	17.8/1.7/47.3	164	1 Unit FFP
4.5 h, 2,400 ml	16.8/1.6/44.2	168	90 µg/kg factor VIIa
Immediately postoperative	10.6/0.8/34.3	128	None
18 h postoperative	19.4/2.0/39.8	144	1 Unit FFP
After FFP	18.7/1.8/39.6	No value obtained	90 µg/kg factor VIIa
After factor VIIa	9.6/0.8/31.7	No value obtained	No additional therapy

PT = prothrombin time; PTT = partial thromboplastin time; INR = international normalized ratio; FFP = fresh frozen plasma.

listed in table 1. The normal ranges are: prothrombin time (PT) 12.0–15.2 s, International Normalized Ratio (INR) 0.8–1.2, partial thromboplastin time (PTT) 23.2–36.0 s, and fibrinogen 187–419 mg/dl. Throughout the hospital course, the patient’s platelet count remained above 100,000/mm³. Eighteen hours postoperatively, when the coagulation function was abnormal again and failed to correct with a unit of FFP (280 ml), the decision was made to use synthetic factor VII, since the patient’s hematocrit had decreased from 30% to 23% and there was 590 ml of output into the surgical drain. After the infusion of synthetic factor VII, there was less than 50 ml of sanguinous drainage from the wound and the drain was removed the next morning. Coagulation studies 24 h later remained within normal limits.

Patient 2

A 13-yr-old, 38-kg boy with neuromuscular scoliosis presented for posterior spinal fusion. Anesthetic care included controlled hypotension with remifentanyl-isoflurane-labetolol to maintain a mean arterial pressure of 55–65 mmHg. Aprotinin was administered in a dose of 30,000 units·kg⁻¹·h⁻¹. The coagulation profiles and treatments are listed in table 2. Postoperatively, the patient’s platelet count remained above 100,000/mm³. Eighteen hours postoperatively, when the coagulation function was abnormal again, based on the previous inability of FFP to correct the abnormal coagulation function, the decision was made to use synthetic factor VIIa. Output over the 12 h from the surgical drains was 692 ml. After the infusion of synthetic factor VII, there was less than 50 ml of sanguinous drainage from the wound and the drain was removed the next morning. Coagulation studies 24 h later remained within normal limits.

Discussion

Normal coagulation requires the interaction and normal function of various components of the coagulation

cascade including platelets, vascular endothelium, and plasma glycoproteins (clotting factors). The clotting cascade has been divided into intrinsic and extrinsic pathways. The extrinsic pathway is initiated by damage to blood vessels and the subsequent release of a transmembrane protein known as tissue factor (TF). TF interacts with and activates factor VII, resulting in the formation of active factor X. Activated factor X with activated factor V results in the conversion of prothrombin to thrombin, which subsequently converts fibrinogen to fibrin (common pathway).²

Before the availability of isolated synthetic factors, FFP and cryoprecipitate were used to treat patients with congenital or acquired coagulation defects. Although generally effective, the obvious health hazards of infectious disease transmission, including the hepatitis and acquired immune deficiency viruses, make this a less than optimal approach to such problems. This problem was alleviated by the production of synthetic factor VIII and IX *via* recombinant DNA technology. However, 15–25% of patients with factor VIII deficiency (hemophilia A) develop antibodies against factor VIII, making future infusions of factor VIII ineffective during bleeding episodes.³ Although activated vitamin K dependent factor concentrates can be used in these patients, their efficacy is low and they are associated with thromboembolic effects.^{4,5} Since factor VIIa must interact with TF to become active, it was postulated that it would be the perfect alternative in hemophiliacs with inhibitors be-

Table 2. Coagulation Parameters and Treatment Provided for Patient 2

Time	PT/INR/PTT (s), fibrinogen (mg/dl)		Treatment
Preoperative	13.8/1.0/34.1	298	None
Intraoperative (time, blood loss):			
1.5 h, 1,900 ml	17.3/1.7/41.1	261	2 Units FFP
2.5 h, 2,700 ml	17.1/1.7/44.3	101	2 Units FFP
3.5 h, 3,300	16.9/1.5/42.2	301	8 Units cryoprecipitate
4.0 h, 3,900	12.6/0.9/34.3	288	90 µg/kg factor VIIa
Immediately postoperative	14.1/1.2/36.1	256	None
12 h postoperative	18.1/1.9/42.2	202	90 µg/kg factor VIIa
After factor VIIa	11.1/1.0/32.7	212	None

PT = prothrombin time; PTT = partial thromboplastin time; INR = international normalized ratio; FFP = fresh frozen plasma.

cause it would bypass the extrinsic system (factors VIII and IX), activating the extrinsic pathway, and would not be associated with thromboembolic risks. In 1988, the first patient was treated with synthetic factor VIIa at the Karolinska Hospital in Stockholm, Sweden. Factor VIIa was successfully used as the sole hemostatic agent during synovectomy in a patient with hemophilia and inhibitors.⁶

Experience using factor VIIa outside of the hemophilia population is somewhat limited. White *et al.* reported the successful use of factor VIIa in two surgical patients who developed coagulopathy and bleeding after massive transfusion.⁷ Despite correction of coagulation function as demonstrated by normalization of the PT-PTT and platelet counts, the patients continued to have bleeding. Bleeding stopped after factor VIIa infusion and the authors suggest that factor VIIa has the potential to act as a universal hemostatic agent, and its use should be considered where there is intractable intraabdominal hemorrhage that has failed to respond to conventional therapy. Bernstein *et al.* demonstrated that synthetic factor VIIa was effective in normalizing the PT in nonbleeding adults with hepatic cirrhosis (Child's B or C).⁸ The duration of the effect was dose-dependent with normalization of the PT for 2 h with 5 µg/kg, 4 h with 20 µg/kg, and 12 h with 90 µg/kg. Erhardtsen *et al.* demonstrated normalization of the PT after synthetic factor VIIa administration to adult volunteers treated with vitamin K antagonists.⁹

To date, there have been no major adverse effects associated with the administration of synthetic factor VIIa in pediatric-aged patients. As it must interact with TF, which is released at the site of tissue injury, there should be limited risk of thromboembolic events. Of note is the fact that although the coagulation profile (PT and PTT) will correct, synthetic factor VIIa will not increase other factor levels that are decreased related to either dilutional or consumptive effects. As such, once the factor VII levels have declined, unless there is replacement (exogenous administration or endogenous production) of these factor levels, the coagulation defect will recur. Based on the data of Bernstein *et al.*,⁸ the duration of effect of a 90 µg/kg dose is 12 h and repeat monitoring of coagulation function is suggested.

Correction of the coagulation disturbance was not achieved in the 2 children reported herein after the administration of routine doses of FFP (20–30 ml/kg). Although it is possible that the coagulation defect could have been corrected with additional FFP; in addition to rapidly correcting the coagulation defect, there are other potential advantages of synthetic factor VIIa when compared with FFP. These include no infectious disease risk; a much smaller volume, thereby allowing rapid administration without concerns of volume overload; and an easy to use preparation that is quickly diluted and administered, whereas FFP has to be thawed, necessitating

a 30–45 preparation time. The more rapid administration and correction of the coagulation defect could theoretically lead to a reduction in blood loss, improved surgical visualization, and perhaps decreased surgical time. In addition, preliminary data suggests that synthetic factor VIIa improves platelet function, adding a secondary beneficial effect on coagulation function during the perioperative period. The significant effect of factor VIIa on platelet function is demonstrated by preliminary data, suggesting that it may be an effective agent to control bleeding in patients with qualitative and quantitative platelet disorders.^{10,11} Adverse effects have been limited, including rare reports of anaphylactoid reactions. As synthetic factor VIIa is not proteolytically active, but rather must react with TF to become active, there is a limited risk of excessive thrombogenesis, and to date no increased incidence of thromboembolic complications has been noted.

Although synthetic factor VIIa was effective, the obvious shortcomings of a case report must be recognized. The findings reported are observational without a control group to demonstrate the advantages of this therapy over the administration of additional doses of FFP. Although there was correction of coagulation parameters, which should theoretically lead to a reduction of intraoperative blood loss, there was no control group to demonstrate any intraoperative benefit with regard to blood loss. This case report should not be taken as a suggestion to use synthetic factor VIIa whenever a coagulation disturbance cannot be corrected with FFP. Such therapy should be regarded as investigational rather than standard. I chose to use factor VII given the high-risk population involved (neuromuscular scoliosis) and their known predisposition to intraoperative bleeding, dilutional coagulopathy with a blood loss of more than one blood volume, a normal fibrinogen level and normal platelet count, no readily reversible etiology of the coagulopathy (heparin or warfarin therapy), and failure of standard therapy (FFP). Given the potential use of this agent, randomized investigations appear warranted to fully delineate the role of this agent in the treatment of perioperative coagulopathies in specific high-risk populations, and clinical scenarios. These trials should focus on the attainment of evidence-based medicine with evaluation of cost issues as well as the potential impact of the various therapies on intraoperative blood loss, blood product exposure, and postoperative morbidity.

References

1. Guay J, Haig M, Lortie L, Guertin MC, Poitras B: Predicting blood loss in surgery for idiopathic scoliosis. *Can J Anaesth* 1994; 41:775–81
2. Van't Veer C, Mann KG: The regulation of the factor VII-dependent coagulation pathway: Rationale for the effectiveness of recombinant factor VIIa in refractory bleeding disorders. *Semin Thromb Hemostas* 2000; 26:367–72
3. Hedner U: Recombinant coagulation factor VIIa: From the concept to clinical application in hemophilia treatment in 2000. *Semin Thromb Hemostas* 2000; 26:363–6

4. Lusher JM, Blatt PM, Penner JA, Aledort LM, Levine PH, White GC, Warriar AI, Whitehurst PA: Autoplex versus proplex: A controlled, double-blind study of effectiveness in acute hemarthroses in hemophiliacs with inhibitors to factor VIII. *Blood* 1983; 62:1135-8
5. Lusher JM: Thrombogenicity associated with factor IX complex concentrates. *Semin Hematol* 1991; 28:3-5
6. Hedner U, Glazer S, Pingel K, Alberts K, Blomback M, Schulman S, Johnsson H: Successful use of recombinant FVIIa in a patient with severe hemophilia A subjected to synovectomy (letter). *Lancet* 1988; 342:1193
7. White B, McHale J, Ravi N, Reynolds J, Stephens R, Moriarty J, Smith OP: Successful use of recombinant factor VIIa (Novoseven) in the management of intractable post-surgical intra-abdominal hemorrhage. *Br J Haematol* 1999; 107: 677-8
8. Bernstein DE, Jeffers L, Erhardtson E, Reddy KR, Glazer S, Squiban P, Bech

R, Hedner U, Schiff ER: Recombinant factor VIIa corrects prothrombin time in cirrhotic patients: A preliminary study. *Gastroenterology* 1997; 113:1930-7

9. Erhardtson R, Nony P, Dechavanne M, Ffrench P, Boissel JP, Hedner U: The effect of recombinant factor VIIa (NovoSeven) in healthy volunteers receiving acenocoumarol to an International Normalized Ratio above 2.0. *Blood Coagul Fibrin* 1998; 9:741-8

10. Poon MC, Demers C, Jobin F, Wu JWY: Recombinant factor VIIa is effective for bleeding and surgery in patients with Glanzmann thrombasthenia. *Blood* 1999; 94:3951-3

11. Kristensen J, Killander A, Hippe E, Helleberg, Ellegard J, Holm M, Kutt J, Mellqvist UH, Johansson JE, Glazer S, Hedner U: Clinical experience with recombinant factor VIIa in patients with thrombocytopenia. *Haemostasis* 1996; 26(suppl 1):159-64

Anesthesiology 2002; 96:1525-7

© 2002 American Society of Anesthesiologists, Inc. Lippincott Williams & Wilkins, Inc.

Use of Recombinant Factor VIIa (NovoSeven®) to Reduce Postoperative Bleeding after Total Hip Arthroplasty in a Patient with Cirrhosis and Thrombocytopenia

Robert Slappendel, M.D., Ph.D.,* Frank C. Huvers, M.D. Ph.D.,† Bart Benraad, M.D.,‡ Irena Novákova, M.D. Ph.D.§
Gijs G. van Hellemond, M.D.||

BESIDES a variety of optional measures to compensate for blood loss, thrombocytes and coagulation factors can be administered to treat coagulopathy resulting from specific deficiencies in cases of severe bleeding. Recently recombinant blood coagulation factor VIIa (rFVIIa, NovoSeven®) became available to treat patients with hemophilia with inhibitors of coagulation factors IX or X. rFVIIa has also been used to treat other causes of severe bleeding; for instance, in cirrhotic patients scheduled for orthotopic liver transplantation,¹⁻⁴ for thrombocytopenic patients,^{5,6} or for patients suffering from Glanzmann thrombasthenia.⁷ The authors describe the use of rFVIIa for treating a patient with liver cirrhosis and hypersplenism requiring total hip arthroplasty (THA).

Case Report

A 59-year-old woman came to our hospital for a preoperative interview 3 weeks before THA. The patient had a history of hip fracture, which

This article is accompanied by an Editorial View. Please see: Weiskopf RB: Intraoperative use of recombinant activated coagulation factor VII. *ANESTHESIOLOGY* 2002; 96:1285-6.

From the Departments of *Anesthesiology, †Internal Medicine, ‡Hospital Pharmacy, and ||Orthopedic Surgery, Sint Maartenskliniek; and the Department of §Hematology, University Hospital Nijmegen, Nijmegen, The Netherlands.

Received from Sint Maartenskliniek, Nijmegen, The Netherlands. Submitted for publication July 16, 2001. Accepted for publication February 6, 2002. Support was provided solely from institutional and/or departmental sources. First published in the *Nederlands Tijdschrift voor Anesthesiologie* as: Slappendel R, Huvers F, Benraad B, Novakova I, Van Hellemond C: Gebruik van recombinant bloedstollingsfactor VIIa (NovoSeven®) tijdens een electieve heupvervangende operatie (case report). *NtvA* 2002; 15:3-6.

Address reprint requests to Dr. Slappendel: Sint Maartenskliniek, P.O. Box 9011, 6500 GM Nijmegen, The Netherlands. Address electronic mail to: r.slappendel@maartenskliniek.nl. Individual article reprints may be purchased through the Journal Web site, www.anesthesiology.org.

was treated in 1998 using reposition osteosynthesis. During the removal of the osteosynthesis material in 1999, the patient showed an increased bleeding tendency with a severe postoperative bleed. Subsequently, the patient developed pseudoarthrosis, thereby requiring the planned THA.

The patient indicated that she still developed hematomas relatively easily. Even smaller injuries continued bleeding up to 20 min. A year before the preoperative interview, the patient was refused THA in another hospital because of the bleeding incident in 1999 and the persistent prolonged bleeding time and existing thrombocytopenia.

The patient had developed alcoholic liver cirrhosis, portal hypertension, and hypersplenism. Alcohol consumption was stopped by the patient after determination of the internal defects. Physical investigation of the patient revealed the following parameters: length 162 cm, weight 60 kg, blood pressure 140/80 mmHg, heart rate 72 beats/min. No icterus, no erythema palmare, and no spider naevi could be determined. In the patient's abdomen, neither the liver nor spleen were palpable. Laboratory investigation showed an increased prothrombin time (PT), a slightly increased bleeding time, and a clearly lowered amount of thrombocytes. Laboratory data are shown in table 1.

Surgery

The patient was administered spinal anesthesia, using intrathecal 0.1 mg morphine dissolved in 4 ml bupivacaine 0.5%,⁸ and a cemented total hip prosthesis was placed. The duration of surgery was 80 min, with a perioperative blood loss of 1,890 ml. The blood was collected and treated (filtration and washing) by a cell saver (Hemonetics 5 plus, Hemonetics, Braintree, MA). After processing the collected blood, 560 ml (hemoglobin 20.16 g/dl) was infused into the patient.

Postoperative Period

The cell saver remained connected to the patient postoperatively for further collection and processing of the lost blood. During the first 6 h after surgery, the total blood loss was 1,850 ml (fig. 1). These 1,850 ml were also treated by the cell saver, and the processed red cells, 560 ml (hemoglobin 20.5 g/dl) in total, was reinfused to the patient. The patient's coagulation status deteriorated even further, with a decrease of platelets from $55 \times 10^9/l$ to $44 \times 10^9/l$, and an increase of the PT to 20 s. Therefore, rFVIIa 100 $\mu g/Kg$ (NovoSeven®, Novo Nordisk A/S, Copenhagen, Denmark) was administered intravenously without the addition

Table 1. Laboratory Results

	Preoperative Interview	Immediately Postoperative	4 h after Surgery	Day 1	Day 2	Day 4	Normal Values
Hb (g/dl)	14.2	8.8	9.9	8.8	9.0	8.6	12–16
Ht (l/l)	0.44	0.28	0.31	0.27	0.28	0.27	0.36–0.46
Thrombocytes ($10^9/l$)	67	54	44	43	46	68	150–400
APTT (s)	nd	44	35	37	43	34	26–36
PT (s)	18	22	20	17	26	16	12–14
Fibrinogen (g/l)	3.7	2.0	1.8	1.9	2.5	3.2	2.0–4.0
Bleeding time (min)	11	nd	nd	nd	nd	nd	0–9

nd = not done.

of thrombocytes. After rFVIIa administration, the total amount of blood lost *via* the drain was 670 ml during the subsequent 11 h (fig. 1). Postoperative bleeding completely ceased 18 h postoperatively, requiring no further intervention.

Discussion

Recombinant factor VIIa forms a complex with tissue factor (TF) that is present in the wound bed, and thereby acts as a catalyst of local blood coagulation. This explains the excellent efficacy of rFVIIa in patients with hemophilia A or B suffering from inhibitors against FVIII or FIX, respectively. TF is a membrane-bound glycoprotein that is expressed on cells in the subendothelium. Tissue injury disrupts the endothelial cell barrier that normally separates TF-expressing cells from the circulating blood, thereby directly exposing TF to circulating blood, resulting in the high affinity binding of rFVIIa. The TF/rFVIIa complex activates FX to Fxa, leading to the generation of thrombin (FIIa) and subsequent fibrin formation. In healthy nonhemophiliacs this thrombin generation leads to the activation of cofactors V and VIII, as well as to the accumulation of activated thrombocytes at the site of injury.

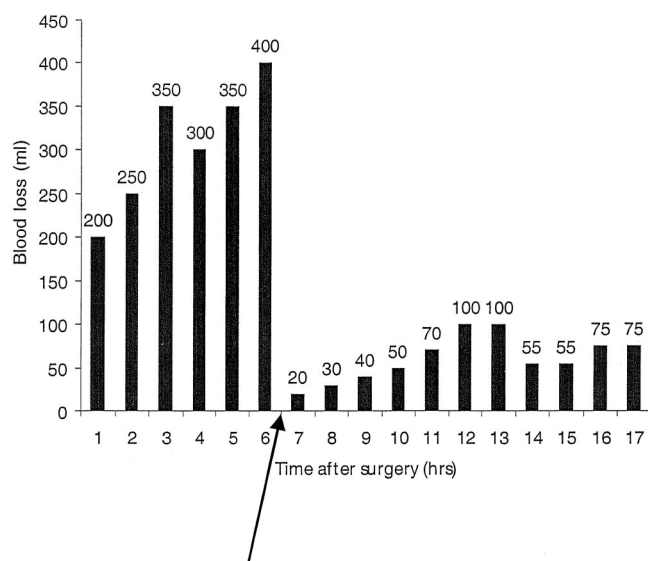


Fig. 1. Graphical presentation of blood loss after surgery.

Administering rFVIIa to patients with liver cirrhosis, thrombocytopenia, or reduced thrombocyte function may result in additional thrombin generation on the phospholipid surface of activated thrombocytes. Since thrombin generation is one of the most powerful existing activators of thrombocytes, the additional rFVIIa-induced thrombin generation might compensate for the reduced amount of thrombocytes available and the associated decreased thrombin generation.^{5,6,9,10} Furthermore, a bolus injection of rFVIIa generates a local burst of thrombin, which subsequently results in the activation of thrombin-activatable fibrinolysis inhibitor (TAFI). TAFI is activated by high concentrations of thrombin.¹¹ Activated TAFI down-regulates fibrinolysis by cleaving C-terminal lysine and arginine residues from partially degraded fibrin.¹² These lysine and arginine residues are essential cofactors in tissue-type plasminogen activator (t-PA) mediated fibrinolysis.

Recombinant FVIIa is not antigenic and does not carry the potential for transmission of disease. However, the current cost of rFVIIa, in a dose of 100 μ g/kg, is approximately € 3,000–3,800 (\$2,668–\$3,430) per patient. The risks of allogenic blood transfusions are associated with incremental hospital costs. In a recently published study these additional costs were estimated to be \$1,000–\$1,500 per unit of blood transfused.¹³

References

- Bernstein DE, Jeffers L, Erhardtson E, Reddy KR, Glazer S, Squiban P, Bech R, Hedner U, Schiff ER: Recombinant factor VIIa corrects prothrombin time in cirrhotic patients: A preliminary study. *Gastroenterology* 1997; 113:1930–7
- Bernstein D: Effectiveness of the recombinant factor VIIa in patients with the coagulopathy of advanced child's B and C cirrhosis. *Semin Thromb Hemost* 2000; 26:437–8
- Hendriks HG, Meijer K, de Wolf JT, Klompaker IJ, Porte RJ, de Kam PJ, Hagenaars AJ, Melsen T, Slooff MJ, van der Meer J: Reduced transfusion requirements by recombinant factor VIIa in orthotopic liver transplantation: A pilot study. *Transplantation* 2001; 71:402–5
- Papatheodoridis GV, Chung S, Keshav S, Pasi J, Burroughs AK: Correction of both prothrombin time and primary haemostasis by recombinant factor VII during therapeutic alcohol injection of hepatocellular cancer in liver cirrhosis. *J Hepatol* 1999; 31:747–50
- Kristensen J, Killander A, Hippe E, Helleberg C, Ellegard J, Holm M, Kutti J, Mellqvist UH, Johansson JE, Glazer S, Hedner U: Clinical experience with recombinant factor VIIa in patients with thrombocytopenia. *Haemostasis* 1996; 26(suppl 1):159–64
- Meijer K, de Graaff WE, Daenen SM, van der Meer J: Successful treatment of massive hemoptysis in acute leukemia with recombinant factor VIIa. *Arch Intern Med* 2000; 160:2216–17
- Poon MC, Demers C, Jobin F, Wu JW: Recombinant factor VIIa is effective

for bleeding and surgery in patients with Glanzmann thrombasthenia. *Blood* 1999; 94:3951-3

8. Slappendel R, Weber EWG, Dirksen R, Gielen MJM, van Limbeek J: Optimization of the dose of intrathecal morphine in total hip surgery: A dose finding study. *Anesth Analg* 1999; 88:822-6

9. Monroe DM, Hoffman M, Oliver JA, Roberts HR: Platelet activity of high dose factor VIIa is independent of tissue factor. *Br J Haematol* 1997; 99(3): 542-7

10. Kjalke M, Ezban M, Hedner U: Increased initial thrombin generation may

explain the efficacy of high dose factor VIIa in thrombocytopenia. *Blood* 1999; 94(suppl 1):45

11. Bajzar L, Manuel R, Nesheim ME: Purification and characterization of TAFI, a thrombin-activable fibrinolysis inhibitor. *J Biol Chem* 1995; 270:14477-84

12. Wang W, Boffa MB, Bajzar L, Walker JB, Nesheim ME: A study of the mechanism of inhibition of fibrinolysis by activated thrombin-activable fibrinolysis inhibitor. *J Biol Chem* 1998; 273:27176-81

13. Blumberg N, Kirkley SA, Heal JM: A cost analysis of autologous and allogeneic transfusions in hip-replacement surgery. *Am J Surg* 1996; 171:324-30