

Morphologic Changes in the Upper Airway of Children during Awakening from Propofol Administration

Ronald S. Litman, D.O.,* Eric E. Weissend, M.D.,† David A. Shrier, M.D.,‡ Denham S. Ward, M.D., Ph.D.§

Background: The purpose of this study was to determine the morphologic changes that occur in the upper airway of children during awakening from propofol sedation.

Methods: Children undergoing magnetic resonance imaging of the head underwent additional scans of the upper airway during deep sedation with propofol; this was repeated on awakening. Axial views were obtained at the most posterior sites of the pharynx at the levels of the soft palate and tongue. Measurements were then obtained of the anterior-posterior (A-P) diameter, transverse diameter, and cross-sectional areas at these levels.

Results: Data were obtained on 16 children, aged 10 months to 7 yr. In both sedated and awakening states, most children had the smallest cross-sectional area of the pharynx at the level of the soft palate. During the sedated state, at the soft palate level, the transverse diameter was most narrow in 11 children, the A-P diameter was most narrow in 1 child, and they were equal in 2 children. During the sedated state, at the level of the tongue, the transverse diameter was most narrow in 9 children, the A-P diameter was most narrow in 5 children, and they were equal in 2 children. During awakening, at the soft palate level, the transverse diameter was most narrow in none of the children, the A-P diameter was most narrow in 13 children, and they were equal in 1 child. At the level of the tongue, the transverse diameter was most narrow in 4 children, and the A-P diameter was most narrow in 12 children. During awakening, the A-P diameter of the pharynx at the level of the soft palate decreased in 12 children, increased in 1 child, and remained the same in 1 child. ($P < 0.001$). The transverse diameter increased in 11 children, decreased in 1 child, and remained the same in 2 children ($P = 0.001$). The cross-sectional area at the level of the soft palate increased in 4 children, decreased in 8 children, and stayed the same in 2 children ($P = 0.5$). During awakening, the A-P diameter of the pharynx at the level of the tongue decreased in 11 children, increased in 4 children, and remained the same in 1 child. ($P = 0.01$). The transverse diameter increased in 11 children and decreased in 5 children ($P = 0.07$). The cross-sectional area at the level of the tongue increased in 7 children, decreased in 7 children, and stayed the same in 2 children ($P = 0.9$).

Conclusions: The dimensions of the upper airways of children change shape significantly on awakening from propofol

sedation. When sedated, the upper airway is oblong shaped, with the A-P diameter larger than the transverse diameter. On awakening, the shape of the upper airway in most children changed such that the transverse diameter was larger. Cross-sectional areas between sedated and awakening states were unchanged. These changes may reflect the differential effects of propofol on upper airway musculature during awakening.

UPPER airway obstruction, an important cause of hypoxemia, may result when sedatives are used to induce unconsciousness in children.¹ Children might be particularly susceptible to upper airway obstruction because of their inherently smaller upper airways, which cause increased resistance to flow, as well as the possibility of tonsillar or adenoidal hypertrophy.² In clinical practice, we occasionally observe inspiratory stridor in children during emergence from general anesthesia that abates with administration of additional anesthetics. This observation and the knowledge that changing levels of anesthetics result in differential effects on respiratory musculature³ led us to study the morphologic changes that occur in the pharynx as anesthetics wear off. We hypothesized that certain areas of the pharynx become more narrow during awakening from general anesthesia or deep sedation as compared with the anesthetized state. To test this hypothesis, we examined magnetic resonance imaging (MRI) images of the upper airway of children while breathing spontaneously during deep sedation with propofol and during awakening.

Methods

The Research Subjects' Review Board of the University of Rochester (Rochester, New York) approved this study, and written consent was obtained from parents of each child studied. Children scheduled for elective MRI examination of the head or neck during propofol administration were eligible to participate. Exclusion criteria included a history of sleep apnea, nighttime snoring, tonsillar hypertrophy, presence of obesity, or any type of upper airway or external cranial pathology (e.g., macrocephaly). Premedication was not administered. A standard mask anesthetic technique was accomplished using sevoflurane and nitrous oxide. After consciousness was lost, an intravenous catheter was placed, sevoflurane and nitrous oxide were discontinued, and a continuous infusion of propofol, $200 \mu\text{g} \cdot \text{kg}^{-1} \cdot \text{min}^{-1}$, was begun. Spontaneous ventilation was maintained throughout the procedure. A nasal cannula provided oxygen, usually at 2 l/min. Monitors included electrocardiography, pulse oximetry, capnography (*via* the nasal cannula), and in-

* Associate Professor, Departments of Anesthesiology, Pediatrics, and Dentistry, and Chief, Division of Pediatric Anesthesia, University of Rochester School of Medicine and Dentistry. Current position: Associate Professor of Anesthesiology and Pediatrics, University of Pennsylvania School of Medicine, Philadelphia, Pennsylvania. † Fellow, Division of Pediatric Anesthesia, Department of Anesthesiology, University of Rochester School of Medicine and Dentistry. Current position: Wilford Medical Center, San Antonio, Texas. ‡ Associate Professor, Department of Radiology, University of Rochester School of Medicine and Dentistry. § Professor, Departments of Anesthesiology and Bioengineering, and Chairman, Department of Anesthesiology, University of Rochester School of Medicine and Dentistry.

Received from the Departments of Anesthesiology, Pediatrics, Dentistry, Radiology, and Bioengineering, University of Rochester School of Medicine and Dentistry, Rochester, New York. Submitted for publication June 18, 2001. Accepted for publication October 31, 2001. Supported by internal funding from the Departments of Anesthesiology and Radiology, University of Rochester.

Address reprint requests to Dr. Litman: Department of Anesthesiology and Critical Care, The Children's Hospital of Philadelphia, 34th Street and Civic Center Boulevard, Philadelphia, Pennsylvania 19104. Address electronic mail to: litmanr@email.chop.edu. Individual article reprints may be purchased through the Journal Web site, www.anesthesiology.org.

termittent automated blood pressure determinations (Medrad, Inc., Indianola, PA). A best attempt was made by the anesthesiologist to position the child's head in the neutral position (without flexion or extension), usually with a folded sheet as a roll beneath the neck or shoulders. No devices that assist with patency of the airway were used, and no attempt was made to open or close the mouth. At the completion of the indicated scans (> 45 min after discontinuation of sevoflurane), additional sagittal and axial views of the upper airway that extended down to the level of the vocal cords were obtained (this sequence of scans took 112 s to complete). This represented the configuration of the upper airway during sedation. No attempt was made to obtain images at a certain point in the respiratory cycle. After these scans were completed, the propofol was discontinued, and exactly 5 min later, the same scans of the upper airway were repeated as before. These represented the awakening views. If the child began to move during these last scans, the study was terminated, and the child was allowed to awaken. All scans were stored in the MRI computer until studies had been performed in 21 subjects.

Magnetic resonance imaging was performed on a 1.5-T unit with a quadrature head coil (GE Medical Systems, Milwaukee, WI). T1 spin-echo images were obtained with 3-mm slices at 0.5-mm intervals.

Measurements

Initially, a coronal view of the head was used to identify the most appropriate medial sagittal slice through the upper airway. Using this medial sagittal image, we identified the levels of the most posterior edges of the pharynx at the levels of the soft palate and tongue in the anterior-posterior (A-P) direction. We then used the axial slices that were closest to these levels to measure in millimeters the A-P and transverse diameters and the cross-sectional areas (figs. 1-3). Linear measurements of diameters were made directly using a GE Horizon 5X scanner, version 5.8 software (General Electric Co., Milwaukee, WI). Cross-sectional areas were directly calculated by tracing freehand the edges of the airway. The measurement software reported distances in millimeters to the nearest whole integer. Measurements were not performed at the level of the epiglottis because it is situated within the laryngeal pharynx and is not bounded laterally by any structure.

After all data were collected, each individual scan was assigned a number, and these numbers were then randomized to determine the order of measurement. Measurements were made by at least two of the authors who were blinded to the state of unconsciousness. When there was disagreement about the value of the distance measured, a final value was determined by consensus, by assistance from a third author, or both.

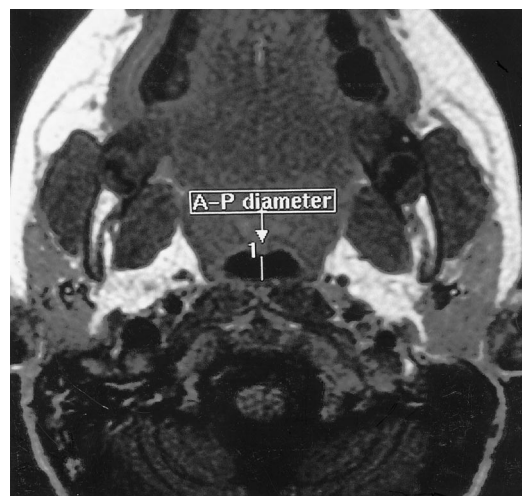


Fig. 1. Axial view of the upper airway. Measurement of anterior-posterior (A-P) diameter.

Statistical Analysis

Statistical calculations were performed by SigmaStat for Windows (Jandel, San Rafael, CA). Comparisons between sedated and awakening states were assessed using two-tailed paired *t* tests for normally distributed data and the Wilcoxon Signed Rank test for nonnormally distributed data. A *P* value less than 0.05 indicated statistical significance.

Results

Twenty-one children initially enrolled, and five were excluded because of movement artifact (three) or early awakening (two). Therefore, data are presented for 16 children. There were nine boys and seven girls, whose age ranged from 10 months to 7 yr (mean \pm SD = 3.2 ± 2.0) and whose weight ranged from 9 to 23 kg (mean \pm SD = 14.6 ± 4.9).

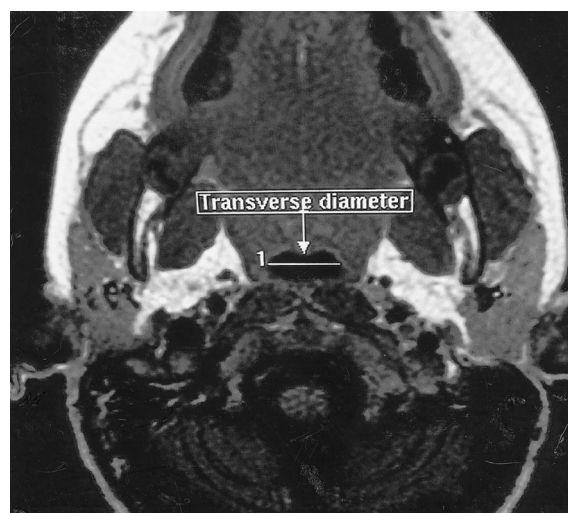


Fig. 2. Axial view of the upper airway. Measurement of transverse diameter.

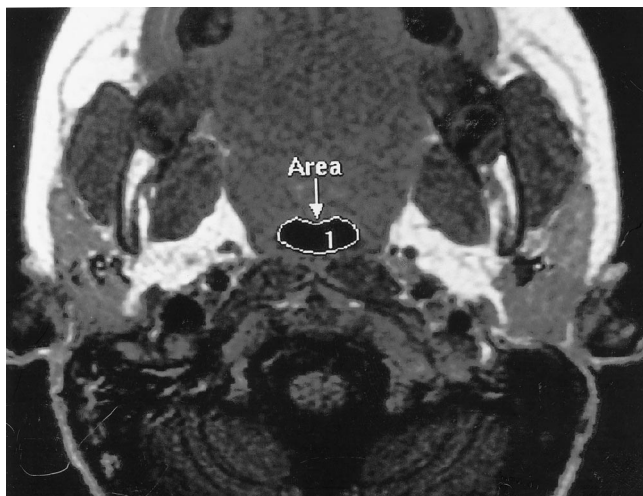


Fig. 3. Axial view of the upper airway. Measurement of cross-sectional area.

Sedated Dimensions

In the sedated state, we were able to measure the cross-sectional area of the pharynx at the level of the soft palate and tongue in 14 children (2 were technically poor images). The cross-sectional area was smallest at the level of the soft palate in 11 children and smallest at the level of the tongue in 3 children. At the level of the soft palate, the transverse diameter was most narrow in 11 children, the A-P diameter was most narrow in 1 child, and they were equal in 2 children. At the level of the tongue, all 16 children were measurable. The transverse diameter was most narrow in 9 children, the A-P diameter was most narrow in 5 children, and they were equal in 2 children.

Dynamic Changes while Awakening

During awakening, we were able to measure the cross-sectional area of the pharynx at the level of the soft palate and tongue in 14 children (2 were technically poor images). The cross-sectional area was smallest at the level of the soft palate in 12 children and smallest at the level of the tongue in 2 children. At the level of the soft palate, the transverse diameter was most narrow in none of the children, the A-P diameter was most narrow in 13 children, and they were equal in 1 child. At the level of the tongue, all 16 children were measurable. The transverse diameter was most narrow in 4 children, and the A-P diameter was most narrow in 12 children.

Comparison of the dimensions of the pharynx at the levels of the soft palate and tongue revealed significant differences between sedated and awakening states (fig. 4). During awakening, the A-P diameter of the pharynx at the level of the soft palate decreased in 12 children, increased in 1 child, and remained the same in 1 child ($P < 0.001$). The transverse diameter increased in 11 children, decreased in 1 child, and remained the same in 2 children ($P = 0.001$). The cross-sectional area at the

level of the soft palate increased in 4 children, decreased in 8 children, and stayed the same in 2 children ($P = 0.5$).

During awakening, the A-P diameter of the pharynx at the level of the tongue decreased in 11 children, increased in 4 children, and remained the same in 1 child ($P = 0.01$). The transverse diameter increased in 11 children and decreased in 5 children ($P = 0.07$). The cross-sectional area at the level of the tongue increased in 7 children, decreased in 7 children, and stayed the same in 2 children ($P = 0.9$).

During either phase of the study (sedated or awakening), no child demonstrated clinically significant upper airway obstruction as manifested by a decreased oxyhemoglobin saturation or decrement in capnometric values. Clinical indicators of upper airway obstruction (e.g., stridor, use of accessory chest wall muscles, and so forth) were not assessed while the children were inside the scanner.

Discussion

The major finding of this study is that the dimensions of the upper airway change shape significantly on awakening from propofol administration. When sedated, the upper airway is oblong shaped with the A-P diameter larger than the transverse diameter. On awakening, the shape of their upper airway in most children we studied changed such that the transverse diameter was larger. A comparison of the cross-sectional area between sedated and awakening states revealed essentially no change. Unfortunately, a control group consisting of conscious children with which to compare these findings was not included because of the near impossibility of scanning a child without some form of sedation.

A secondary finding was that while sedated, most children had the most narrow site in their pharynx at the level of the soft palate. In the past, upper airway obstruction during general anesthesia was thought to occur at the level of the base of the tongue, presumably because of anesthetic-induced genioglossus muscle relaxation.⁴ However, subsequent studies in both adults and children showed the major site of airway narrowing to be at the level of the soft palate or epiglottis.^{1,5-8} None of these previous studies investigated the anatomic relations of the structures of the upper airway during awakening.

The mechanism of these changes during awakening remains speculative. It is generally accepted that patency and stability of the upper airway are dependent on contraction of the muscles that comprise the nonbony portions of the pharyngeal wall. The start of the contraction of these pharyngeal dilators slightly precedes the contraction of the diaphragm to counteract the negative pressure generated during spontaneous respiration.⁹ Furthermore, there is evidence that the caliber of the upper airway increases during inspiration because of

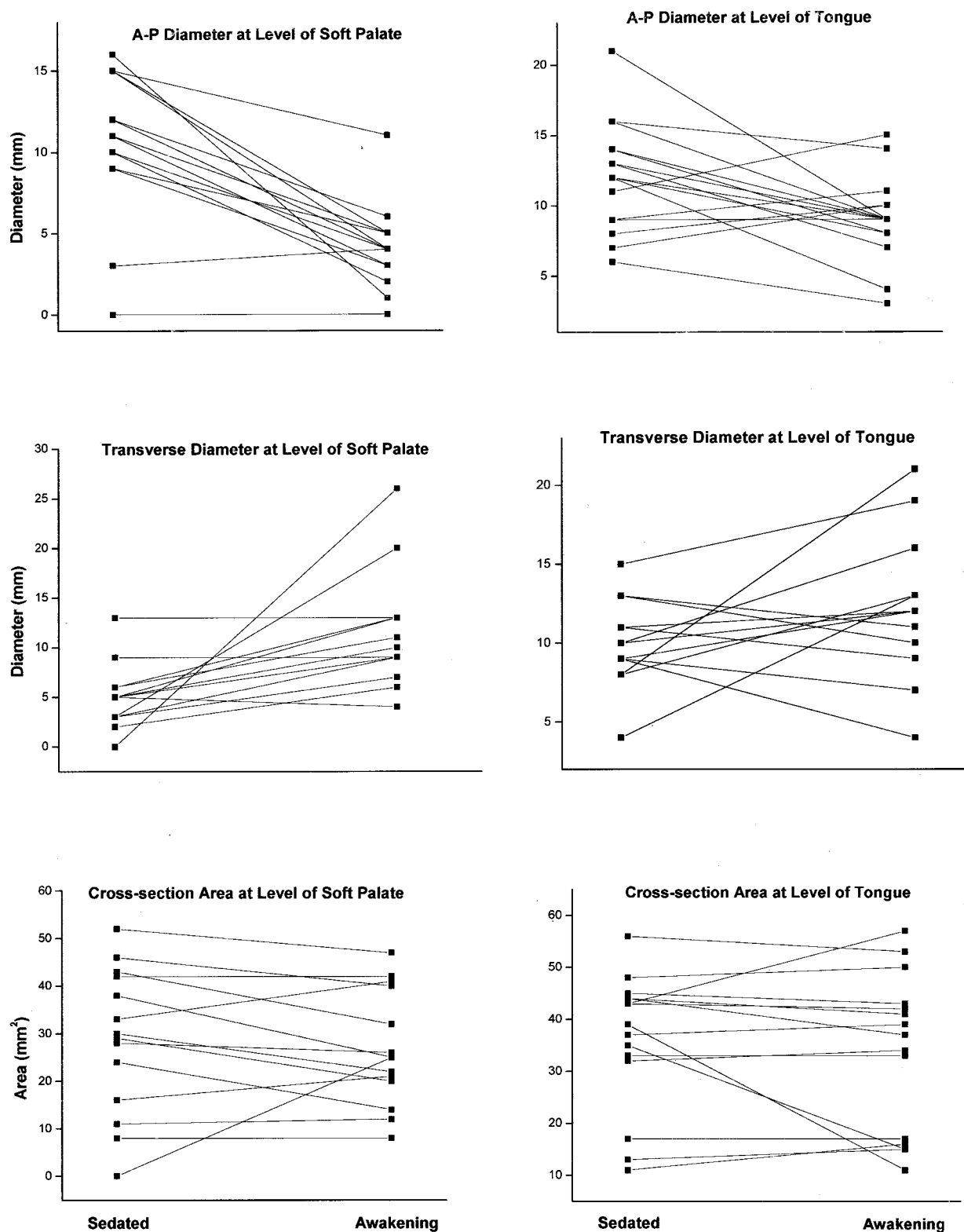


Fig. 4. Changes in diameters (*top and middle*) and cross-sectional areas (*bottom*) at the level of the soft palate (*left*) and tongue (*right*).

thoracic inspiratory activity providing caudal traction on the upper airway.¹⁰ Although the effects of general anesthesia reduce overall ventilatory drive and airway reflex activity, pharyngeal muscle activity may be more

susceptible than that of the diaphragm.³ Administration of halothane, thiopental, and diazepam results in differential effects on strength of the hypoglossal and phrenic nerves, but ketamine does not share this differential

property.³ Propofol has been shown to decrease diaphragmatic contractility in an animal model,¹¹ but its differential effects on upper airway musculature and diaphragmatic strength have not been investigated.

Another explanation is offered by a previous study that used radiography to investigate the effect of a sleep dose of thiopental on the structures of the upper airway during spontaneous ventilation.¹² These authors found anterior displacement of the epiglottis relative to the cervical spine and widening of the glottic aperture with the onset of general anesthesia. They suggested that the tonic activity that "folds" the larynx during consciousness is a protective mechanism and is lost with induction of general anesthesia.

A limitation of this study relates to the difficulty of studying the subjects in a consistent state of awakening. Because the pharmacokinetic and pharmacodynamic properties of propofol vary in different individuals, it would be difficult to precisely target a specific state of awakening. Our extensive clinical experience using this technique indicated that children almost always awaken 6–8 min after discontinuation of propofol when infused at this particular dose for the duration of a typical head scan (45–60 min). Therefore, we chose to obtain the awakening scan exactly 5 min after discontinuation of propofol in the hope of capturing the subjects at a stage of being nearly awake. There are two disadvantages of this technique. The first is that some children may awaken fully and begin to move before completion of the study (two enrolled subjects were excluded for this reason). Second, and more important, is the possibility of studying a subject in an advanced state of awakening whereby a higher level of cortical function is influencing the upper airway musculature. In this state, it is conceivable that these muscles might be in a state that renders them less prone to cause airway obstruction. This latter explanation may account for the observed variation between subjects we studied. The majority of the children who completed the study were able to lie motionless during the loud noise of the scanner but then awoke immediately when they were brought out of the scanner and exposed to the physical stimulation of monitor removal. An alternative explanation for our results is that as the children began to awaken, swallowing could have occurred, which caused the narrowing appearance on MRI.

Another limitation of our study is that all children were studied with their necks in a neutral position. Therefore,

our results would not necessarily apply to children whose necks are flexed or extended or who are receiving forward mandibular displacement. These maneuvers have been shown to alter the shapes and positions of the structures of the upper airway.¹ Likewise, the degree of mouth opening can alter the relations of the anatomic structures of the upper airway. We made no attempt to standardize mouth opening in this study. However, our clinical experience has been that the majority of children who receive propofol sedation for MRI maintain their jaw in the neutral position, somewhat midway between opened and closed.

In summary, we demonstrated morphologic changes in the shape of the upper airway of children who were awakening from propofol sedation. These findings provide further evidence of the complexity of the effects of anesthetics on upper airway musculature and suggest that propofol, like other anesthetics and sedatives, may also be associated with a differential effect not only between the diaphragm and upper airway, but between separate pharyngeal dilator muscles.

The authors thank Traci Salter, R.T.R. (Department of Radiology, Strong Memorial Hospital, Rochester, New York), and the team of magnetic resonance imaging technicians at Strong Memorial Hospital for making this study possible.

References

1. Reber A, Wetzel SG, Frei FJ, Bongartz G: Effect of combined mouth closure and chin lift on upper airway dimensions during routine magnetic resonance imaging in pediatric patients sedated with propofol. *ANESTHESIOLOGY* 1999; 90:1617–23
2. Litman RS, Kottra JA, Berkowitz RJ, Ward DS: Upper airway obstruction during midazolam/nitrous oxide sedation in children with enlarged tonsils. *Pediatr Dent* 1998; 20:318–20
3. Nishino T, Shirahata M, Yonezawa T, Honda Y: Comparison of changes in the hypoglossal and the phrenic nerve activity in response to increasing depth of anesthesia in cats. *ANESTHESIOLOGY* 1984; 60:19–24
4. Safar P, Escarraga LA, Chang F: Upper airway obstruction in the unconscious patient. *J Appl Physiol* 1959; 14:760–4
5. Boidin MP: Airway patency in the unconscious patient. *Br J Anaesth* 1985; 57:306–10
6. Abernethy LJ, Allan PL, Drummond GB: Ultrasound assessment of the position of the tongue during induction of anaesthesia. *Br J Anaesth* 1990; 65:744–8
7. Nandi PR, Charlesworth CH, Taylor SJ, Nunn JF, Dore CJ: Effect of general anesthesia on the pharynx. *Br J Anaesth* 1991; 66:157–62
8. Mathru M, Esch O, Lang J, Herbert ME, Chaljub G, Goodacre B, vanSonnenberg E: Magnetic resonance imaging of the upper airway. *ANESTHESIOLOGY* 1996; 84:273–9
9. Badr MS: Effect of ventilatory drive on upper airway patency in humans during NREM sleep. *Resp Physiol* 1996; 103:1–10
10. Van de Graaff WB: Thoracic influence on upper airway patency. *J Appl Physiol* 1988; 65:2124–31
11. Fujii Y, Hoshi T, Takahashi S, Toyooka H: Propofol decreases diaphragmatic contractility in dogs. *Anesth Analg* 1999; 89:1557–60
12. Sivarajan M, Fink R: The position and the state of the larynx during general anesthesia and muscle paralysis. *ANESTHESIOLOGY* 1990; 72:439–42