

Richard B. Weiskopf, M.D., Editor

Anesthesiology 2001; 95:544-8

© 2001 American Society of Anesthesiologists, Inc. Lippincott Williams & Wilkins, Inc.

The Heart in Blunt Trauma

Gilles Orliaguet, M.D.,* Mustapha Ferjani, M.D.,† Bruno Riou, M.D., Ph.D.‡

DIAGNOSIS of lesions of the heart related to blunt trauma is a challenge, mainly because of confusion about the terms used and the absence of recognized standards. It has been recommended that the term myocardial contusion be avoided and that the term blunt cardiac trauma be used only in the presence of pump failure or malignant cardiac rhythms.¹ These uncertainties make the literature difficult to analyze and compare. The clinician is left knowing that "myocardial contusion" occurs in blunt trauma and may be responsible for significant clinical events (arrhythmias and perioperative hemodynamic instability, including cardiogenic shock and death). Moreover, assessment of the heart in blunt trauma also includes assessment of intracardiac volume, the pericardium, and rare surgical lesions, such as valve rupture, septal defect, and coronary artery lesions. The aim of this Clinical Concepts and Commentary article is to provide the clinician with a brief review of the literature and some recommendations that could be useful in clinical practice.

Pathophysiology

Blunt trauma can induce myocardial lesions by several mechanisms: (1) direct transfer of energy during the impact on the thorax; (2) rapid deceleration of the heart; and (3) compression of the heart between the sternum and the spine. Although there is a continuum between these two entities, myocardial lesions may be divided into "myocardial commotion" and myocardial contusion. Theoretically, the term myocardial commotion should

be used when no lesion can be evidenced by any imaging method, including histology. Myocardial commotion results from low-energy impact to the precordium leading to cardiac arrest, with most events observed during athletic activity (baseball, golf, hockey). Cardiac arrest may result either from an impact 30-15 ms before the peak of the T wave, leading to ventricular fibrillation, or from an impact during the QRS complex, leading to complete heart block.² In contrast, myocardial contusion results from high energy impact and is associated with myocardial lesions (hemorrhage, increase in edema formation, necrosis, polymorphonuclear infiltrates) that increase extravascular resistance and may result in decreased coronary blood flow and cardiac function.³⁻⁵ Injury most frequently involves the right ventricle and the septum.³

Myocardial contusion may induce severe complications, the most frequent being arrhythmias. Arrhythmias may occur after even minor myocardial contusion, explaining why most of the literature in emergency medicine proposes algorithms to exclude myocardial contusion and thus the need for cardiac monitoring after thoracic trauma. Robert *et al.*⁶ recently provided convincing evidence that myocardial contusion is responsible for the reentry mechanism potentially leading to severe arrhythmias. Hemopericardium can be caused by myocardial contusion but is rarely responsible for cardiac tamponade. Severe myocardial contusion may induce a decrease in cardiac function, but frank cardiogenic shock is rarely observed.⁷ Nevertheless, because the right ventricle is more often involved than the left ventricle in myocardial contusion and because an increase in pulmonary artery resistance is often observed when adult respiratory distress syndrome occurs, a moderate decrease in right ventricular function may be a clinically relevant problem in severely traumatized patients. The hemodynamic consequences of mechanical ventilation (peak inspiratory pressure, positive end-expiratory pressure, arterial carbon dioxide tension [P_{aCO_2}]) can be more pronounced in the case of right ventricular dysfunction induced by myocardial contusion. Consequently, ventilatory management decreasing airway pressure (low tidal volume, high-frequency ventilation) may be beneficial. Cardiac rupture is a rarely observed complication.

Recent experimental studies have shown that troponin T and I are released after myocardial contusion and that

*Assistant Professor of Anesthesiology, Department of Anesthesiology and Critical Care, Centre Hospitalier Universitaire (CHU) Necker-Enfants Malades, Paris. †Associate Professor of Anesthesiology, Department of Anesthesiology, Critical Care and Hemodialysis, Military Hospital, Tunis. ‡Professor of Anesthesiology, Department of Anesthesiology, and Chairman, Department of Emergency Medicine and Surgery, CHU Pitié-Salpêtrière, Paris.

Received from the Department of Anesthesiology and Critical Care, CHU Necker-Enfants Malades, Paris, France; the Department of Anesthesiology, Critical Care and Hemodialysis, Military Hospital, Tunis, Tunisia; and the Department of Anesthesiology and Critical Care and the Department of Emergency Medicine and Surgery, CHU Pitié-Salpêtrière, Université Pierre et Marie Curie, Paris, France. Submitted for publication April 14, 2000. Accepted for publication February 6, 2001. Support was provided solely from institutional and/or departmental sources.

Address correspondence to Dr. Riou: Département d'Anesthésie-Réanimation et Service d'Accueil des Urgences, CHU Pitié-Salpêtrière, 47-81 Boulevard de l'Hôpital, 75651 Paris Cedex 13, France. Address electronic mail to: bruno.riou@psl.ap-hop-paris.fr.

The illustration for this section is prepared by Dmitri Karetnikov, 7 Tennyson Drive, Plainsboro, New Jersey 08536.

Table 1. Comparison of Diagnostic Performance of Transthoracic (TTE) and Transesophageal (TEE) Echocardiography Performed in the Same Blunt Chest Trauma Patients (n = 134)

	TTE	TEE
Feasibility	51 (38%)	131 (98%)
Hemopericardium	28 (21%)	40 (30%)
Myocardial contusion	15 (11%)	45 (34%)
Aortic rupture	3 (2%)	14 (10%)
Hemomediastinum	5 (4%)	34 (25%)
Valvar lesions	0	2 (1%)

From Chirillo *et al.*⁸

this release correlates with the energy of trauma.^{4,5} Moreover, there is an early peak probably related to membrane damage and release of unbound troponins followed by a continuous release from disintegrated myofibers.

Many other cardiac lesions may occur during blunt trauma, but they are rare (table 1).⁸ Valvar lesions occur in less than 1% of the cases and are predominantly of the aortic and mitral valves. Ventricular and atrial septal defects occur even more rarely in thoracic blunt trauma. Lesions of the coronary arteries (laceration, thrombosis, dissection of the ostium) have been found in less than 2% of cases in autopsy series. Clear suspicion of myocardial infarction (electrocardiography, troponin I concentration measurement, echocardiography) in a young trauma patient should lead to emergency coronary angiography and surgery. Pericardial trauma may lead to hemopericardium with or without myocardial lesions, and pericardial rupture with possible herniation of the heart.

Apart from the direct lesions related to trauma, the heart may have indirect lesions, mainly due to head trauma and shock. It is now well-established that head trauma, subarachnoid hemorrhage, and increases in intracranial pressure may lead to myocardial lesions. Most of the knowledge regarding these lesions has been obtained from brain-dead patients.⁹ Increase in sympathetic activity, with catecholamine storm, is responsible for prolonged norepinephrine and neuropeptide Y release within the myocardium, leading to β -adrenergic receptor desensitization, coronary vasoconstriction, and cardiomyocyte lesions. This phenomenon is associated with electrocardiographic abnormalities, troponin release, and decrease in cardiac function and has been reported to occur not only during brain death but also after severe head trauma.

Similarly, we know that hemorrhagic shock can be associated with a decrease in cardiac function. More-

over, the use of catecholamines during resuscitation of severe hemorrhagic shock may also be responsible for the myocardial lesions observed in severely traumatized patients.¹⁰ These may be involved in the decreased left ventricular function observed in severely traumatized patients.

Assessment of the Heart

In the modern era, electrocardiography, troponin I concentration measurement, and echocardiography should be used routinely to assess the heart in trauma. Nevertheless, these evaluations share some limitations. Invasive diagnostic procedures (coronary angiography, ventriculography) should be performed in few cases (< 0.1%), when a coronary lesion or a cardiac rupture is suspected.

Electrocardiographic abnormalities frequently occur in myocardial contusion, but a normal electrocardiogram does not exclude the diagnosis. The more frequent arrhythmias observed are sinus tachycardia and extrasystoles. Right bundle branch block and atrioventricular blocks are the most frequently observed conduction abnormalities. Repolarization abnormalities (ST segment and T waves) are frequent, whereas Q waves are rarely observed. Severe arrhythmias (ventricular tachycardia and fibrillation) are rarely noted but are life-threatening complications of myocardial contusion, explaining the need for cardiac monitoring.

Because a standard electrocardiogram mainly explores the left ventricle, it is not surprising that it can miss right ventricular contusion. However, addition of right precordial electrocardiographic leads do not add sensitivity for the diagnosis. Electrocardiographic abnormalities may be related to other factors in trauma patients (hypoxemia, acidosis, increase in vagal or sympathetic activities, blood electrolyte changes). The usual tachycardia related to hypovolemia, anemia, and the inflammatory process make the analysis of the electro-

cardiogram difficult in the trauma patient. Nevertheless, the rapid (within days) disappearance of electrocardiographic conduction abnormalities are thought to be a strong argument for myocardial contusion.

Although electrocardiography is a relatively poor diagnostic tool in myocardial contusion, most authors considered that it is appropriate in assessing prognosis (*i.e.*, complicated myocardial contusion). Indeed, electrocardiography has been shown to be accurate in predicting cardiac complications (sensitivity 96%, specificity 47%), especially in those necessitating therapy (sensitivity 100%),¹¹ such as antiarrhythmic drugs or defibrillation.

Serum troponin concentration is considered the most reliable biologic indicator of myocardial ischemia, even in the perioperative period. Measurement of creatine kinase and even creatine kinase MB should probably be excluded in trauma patients because of frequent skeletal muscle injury in blunt trauma.^{12,13} It should be pointed out that clinically relevant myocardial injury can occur without significant troponin release.¹² Indeed, cardiac injury involving a small area may be responsible for severe arrhythmias, whereas it could be too small to release detectable troponin concentrations. Moreover, because of the complex kinetics of troponin release, serial assessment may be required.¹³ Second, there is some convincing evidence that troponin release could occur because of the global myocardial consequences of hemorrhage and traumatic shock.¹⁰ Therefore, although an increased troponin concentration indicates myocardial injury, the injury may or may not be related to myocardial contusion. In any event, troponin I is preferred to troponin T because it is more specific.¹³

Myocardial infarction will probably be reported at an increasing frequency as either a cause or a complication of trauma in patients with coronary artery disease because of the changing demographics of trauma victims (the population is of increasing age in developed countries). Consequently, it may be difficult to interpret troponin increase in this clinical situation (myocardial contusion *vs.* infarction).

Transthoracic echocardiography may not provide high-quality imaging in trauma patients because of mechanical ventilation, pleural effusion (pericardium assessment), pneumothorax, or inability to place an injured patient in the left lateral decubitus position. Therefore, except for the assessment of the pericardium, transesophageal echocardiography (TEE) is preferable (table 1).⁸ TEE enables a rapid assessment of cardiac preload by measuring the end-diastolic area, and it enables a rapid assessment of systolic cardiac function by measuring the fractional ventricular area change. These echocardiographic measurements are valid estimates of cardiac filling and ejection. Moreover, in emergency conditions, qualitative estimates of left ventricular volumes can be used in real time to guide fluid and catecholamine administration. TEE enables diagnosis of traumatic le-

sions, such as myocardial contusion, pericardial effusion, cardiac rupture, and valvular incompetence. When pericardial effusion occurs, cardiac tamponade is diagnosed by observing right atrial collapse, right ventricular diastolic collapse, or both. TEE can be used to diagnose traumatic complications, such as systemic air embolism, which might induce coronary occlusion and thus myocardial ischemia, or to diagnose opening of the foramen ovale leading to severe hypoxia.

Although TEE is a useful tool in the assessment of trauma patients,⁸ it has some limitations. First, myocardial contusions more frequently involve the right ventricle, which is more difficult to assess using echocardiography. Second, TEE requires technical skill and experience. Third, it is not available at all trauma centers.

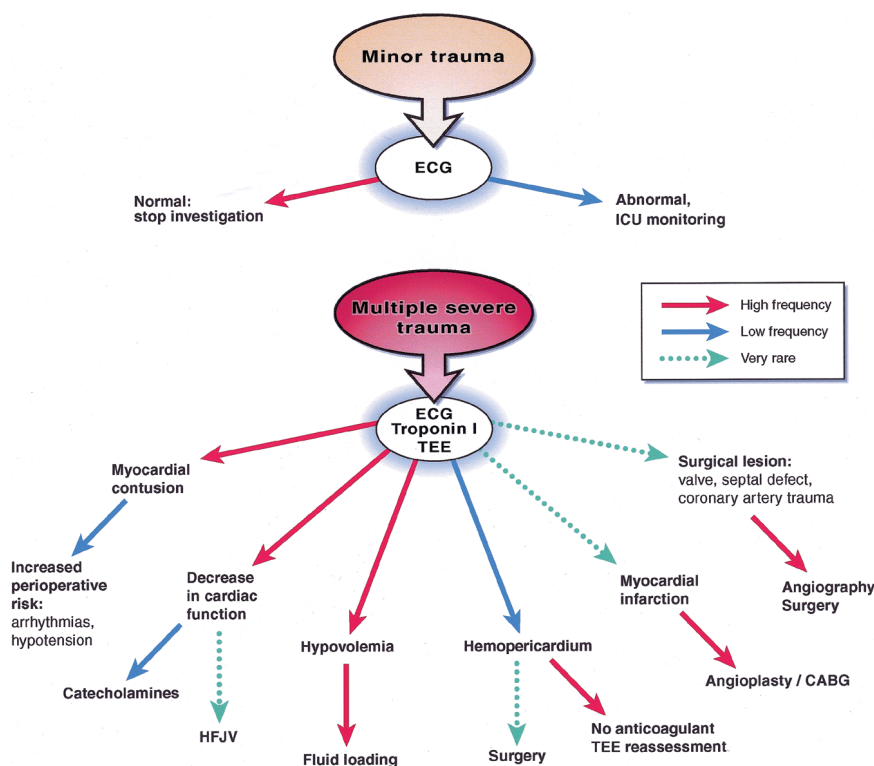
Perioperative Consequences

For the anesthesiologist, there is a need to assess the heart precisely in severe blunt trauma. First, there is a need to assess cardiac function and intracardiac volume and to identify rare cardiac traumatic lesions requiring coronary angiography, surgery, or both. Second, myocardial contusion has been shown to be associated with an increased risk of perioperative arterial hypotension, arrhythmias, or even cardiac arrest.^{11,14} This increased risk of perioperative complications has been reported up to 1 month after trauma. The magnitude of this risk is still a matter of debate. Indeed, although intraoperative mortality was greater in patients with myocardial injury (54% *vs.* 5%, $P < 0.05$), Devitt *et al.*¹⁵ observed that the incidence of intraoperative hypotension or arrhythmias were not significantly modified by the presence of myocardial contusion. They considered that the higher mortality was attributed to noncardiac causes. Nevertheless, reviewing five studies involving trauma patients with cardiac injury who underwent emergency surgery, Baum¹⁶ noted that intraoperative arrhythmias occurred in 6% of cases and severe intraoperative hypotension occurred in 16% of cases. Some factors should be considered as prognostic factors that may increase perioperative mortality in cases of myocardial contusion: atrial fibrillation, old age, and aortic rupture.¹⁷⁻¹⁹ There is a need for a large prospective study precisely assessing the perioperative morbidity (hypotension, arrhythmias) associated with heart blunt trauma in severely injured patients.

Recommendations

Two different clinical situations occur in traumatized patients. First, in minor trauma there is a need to diagnose myocardial contusion to determine the need for cardiac monitoring over the first 24 h. In contrast, in severe trauma, patients are monitored, and there is a need to assess the heart (intracardiac volume, cardiac function, pericardium, valves) and to identify those pa-

Fig. 1. Schematic algorithm for assessment of the heart in blunt chest trauma. All probabilities (colored arrows) take into account the *a priori* probability of the initial event. ECG = electrocardiography; ICU = intensive care unit; TEE = transesophageal echocardiography; HFJV = high-frequency jet ventilation; CABG = coronary artery bypass graft.



tients for whom there is a high suspicion of myocardial contusion that may exhibit an increased risk of perioperative complications.

In minor cardiac trauma, a normal electrocardiogram 3 h after trauma can exclude the risk of cardiac complication, thus eliminating the need for cardiac monitoring.²⁰ It has been recently demonstrated that troponin I or T concentrations do not add significant information in hemodynamically stable patients with chest trauma because there was a poor relation between increased troponin and early or late clinical outcome.¹³

In severely traumatized patients, the anesthesiologist should analyze the information obtained by electrocardiography, troponin I concentration measurement, and TEE. It should be pointed out that use of TEE is motivated by many reasons other than diagnosis of myocardial contusion. The anesthesiologist should identify patients with an increased risk of perioperative morbidity or an increased risk of mortality. However, currently, there is no study demonstrating that the anesthesiologist can decrease these risks by taking some preventive measures. No particular anesthetic regimen can be advocated because of its electrophysiologic consequences in the presence of myocardial contusion. Catecholamines might facilitate arrhythmias, but it is not always possible to avoid them in patients with severe trauma. Thus, the anesthesiologist must anticipate potential arrhythmias by appropriate monitoring and must ensure the availability of a defibrillator. Sakka *et al.*²¹ have recently reported two cases of late (4 and 6 days) fatal cardiac arrhythmias in patients who sustained severe chest trauma and mul-

tiple injuries. Many studies, including a meta-analysis, have recently suggested that myocardial contusion is a futile diagnosis, particularly in the absence of immediate cardiac complication. However, most of these studies have been conducted in minor chest trauma, and their conclusion might not apply to more severely traumatized patients.

The following should be considered: (1) blood volume and fluid loading should be measured precisely because right ventricular preload is critical for hemodynamic stability in severe trauma patients; (2) because of tachycardia, mechanical ventilation, and pulmonary contusion, TEE probably assesses preload more accurately than does right heart catheterization in this situation; and (3) the potential deleterious hemodynamic effect of mechanical ventilation should be considered because of the injured right ventricle.

There is no treatment that must be routinely performed in the case of myocardial contusion. In the rare cases of severe myocardial contusion with cardiac failure, several therapeutics have been advocated. Because of the small number of these cases, there is no clear consensus for appropriate treatment. Some important pathophysiologic issues should be considered: (1) the injury usually involves the right rather than the left ventricle; (2) the consequences of conventional mechanical ventilation may be deleterious; and (3) an increase in right ventricular afterload related to severe pulmonary contusion may precipitate cardiac failure. Consequently, a left ventricular assistance device may not be the therapy of choice. In addition to catecholamines, which are

often required in the treatment of severely traumatized patients and may be especially useful in cardiac failure, we advocate the use of high-frequency jet ventilation, which decreases the hemodynamic consequences of ventilation and dramatically improved oxygenation in these patients who also frequently have life-threatening pulmonary contusion.^{7,22} In these patients, high-frequency jet ventilation may be required during the first hours after trauma and consequently may be started in the emergency room or the operating room.²² If cardiac assistance is required, biventricular assistance should be considered. Aggressive therapeutic management of these rare cases is justified by the rapid recovery of myocardial contusion and its good long-term prognosis (in the absence of other lethal traumatic lesions).

Conclusion

In minor chest trauma, a normal electrocardiogram 3 h after trauma can exclude the risk of cardiac complications (fig. 1). Although the precise diagnosis of myocardial contusion remains a matter of debate, an assessment of the heart (preload, cardiac function, cardiac lesions, pericardium) after severe trauma is important (fig. 1). Three main examinations should be performed (electrocardiography, troponin I concentration measurement, TEE) to identify cardiac lesions related to thoracic or nonthoracic trauma (head trauma, catecholamines, shock). The presence of a cardiac lesion is probably associated with an increased risk of perioperative morbidity. Some factors (atrial fibrillation, old age, aortic rupture) may be associated with an increased risk of perioperative mortality. TEE is able to identify the rare cardiac lesions requiring surgery (valves, coronary arteries, ruptures) and those requiring appropriate therapeutic strategies (hemopericardium, cardiogenic shock).

References

1. Mattox KL, Flint LM, Carrico CJ, Grover F, Meredith J, Morris J, Rice C, Richardson D, Rodriguez A, Trunkey DD: Blunt cardiac injury (formerly termed "myocardial contusion"). *J Trauma* 1992; 33:649-50
2. Link MS, Wang PJ, Pandian NG, Bharati S, Udelson JE, Lee MY, Vecchiotti MA, Vanderbring BA, Mirra G, Maron BJ, Estes NA III: An experimental model of sudden death due to low-energy chest-wall impact (commotio cordis). *N Engl J Med* 1998; 338:1805-11
3. Sutherland GR, Calvin JE, Driedger AA, Holliday RL, Sibbald WJ: Anatomic and cardiopulmonary responses to trauma with associated blunt chest injury. *J Trauma* 1981; 21:1-13
4. Okubo N, Hombrouck C, Fornes P, Cosson C, Samii K, Mazoit X, Edouard A: Cardiac troponin I and myocardial contusion in the rabbit. *ANESTHESIOLOGY* 2000; 93:811-7
5. Bertinchant JP, Robert E, Polge A, de La Coussaye JE, Pignodel C, Aya G, Fabbro-Péray P, Poirey S, Ledermann B, Eledjam JJ, Dauzat M: Release kinetics of cardiac troponin I and cardiac troponin T from isolated perfused rabbit hearts after graded experimental myocardial contusion. *J Trauma* 1999; 47:474-80
6. Robert E, de La Coussaye JE, Aya AGM, Bertinchant JP, Polge A, Fabbro-Péray P, Pignodel C, Eledjam JJ: Mechanisms of ventricular arrhythmias induced by myocardial contusion. *ANESTHESIOLOGY* 2000; 92:1132-43
7. Orliaguet G, Jacquens Y, Riou B, Le Bret F, Rouby JJ, Viars P: Combined severe myocardial and pulmonary contusion: Early diagnosis with transesophageal echocardiography and management with high-frequency jet ventilation. *J Trauma* 1993; 34:455-7
8. Chirillo F, Totis O, Cavarzerani A, Bruni A, Farnia A, Sarpellon M, Ius P, Valfrè C, Sritoni P: Usefulness of transthoracic and transesophageal echocardiography in recognition and management of cardiovascular injuries after blunt chest trauma. *Heart* 1996; 75:301-6
9. Riou B, Dreux S, Roche S, Arthaud M, Goarin JP, Léger P, Saada M, Viars P: Circulating cardiac troponin T in potential heart transplant donors. *Circulation* 1995; 92:409-14
10. Edouard AR, Benoist JF, Cosson C, Mimoz O, Legrand A, Samii K: Circulating cardiac troponin I in trauma patients without cardiac contusion. *Intensive Care Med* 1998; 24:569-73
11. Healey MA, Brown R, Fleischer D: Blunt cardiac injury: is the diagnosis necessary? *J Trauma* 1990; 30:137-46
12. Ferjani M, Droc G, Dreux S, Arthaud M, Goarin JP, Riou B, Coriat P: Circulating cardiac troponin T in myocardial contusion. *Chest* 1997; 111:427-33
13. Bertinchant JP, Polge A, Nguyen-Ngoc-Lam R, Estorc J, Cohendy J, Joubert P, Poupard P, Fabbro-Péray P, Monpeyroux F, Poirey S, Ledermann B, Raczk F, Brunet J, Nigond J, de La Coussaye JE: Evaluation of incidence, clinical significance, and prognostic value of circulating cardiac troponin I and T elevation in hemodynamically stable patients with suspected myocardial contusion after blunt chest trauma. *J Trauma* 2000; 48:924-31
14. Eisenach JC, Nugent M, Miller FA, Mucha P: Echocardiographic evaluation of patients with blunt chest injury: Correlation with perioperative hypotension. *ANESTHESIOLOGY* 1986; 64:364-6
15. Devitt JH, McLean RF, McLellan BA: Perioperative cardiovascular complications associated with blunt thoracic trauma. *Can J Anesth* 1993; 40:197-200
16. Baum VC: The patient with cardiac trauma. *J Cardiothorac Vasc Anesth* 2000; 14:71-81
17. McLean RF, Devitt JH, McLellan BA, Dubbin J, Ehrlich LE, Dikson D: Significance of myocardial contusion following blunt chest trauma. *J Trauma* 1992; 33:240-3
18. Dubrow TJ, Mihalka J, Eisenhauer DM, de Virgilio C, Finch M, Mena IG, Nelson RJ, Wilson SE, Robertson JM: Myocardial contusion in the stable patient: what level of care is appropriate? *Surgery* 1989; 106:267-73
19. Kram HB, Appel PL, Shoemaker WC: Increased incidence of cardiac contusion in patients with traumatic thoracic aortic rupture. *Ann Surg* 1988; 208:615-8
20. Wisner DH, Reed WH, Riddick RS: Suspected myocardial contusion: Triage and indication for monitoring. *Ann Surg* 1990; 212:82-6
21. Sakka SG, Huettemann E, Giebe W, Reinhart K: Late cardiac arrhythmias after blunt chest trauma. *Intensive Care Med* 2000; 26:792-5
22. Riou B, Zaier K, Kalfon P, Puybasset L, Coriat P, Rouby JJ: High-frequency jet ventilation in life-threatening bilateral pulmonary contusion. *ANESTHESIOLOGY* 2001; 94:927-30