

## Perioperative Management of Severe Head Injury in a Patient with Arrhythmogenic Right Ventricular Dysplasia

Francine Bonnet, M.D.,\* Emmanuel Samain, M.D., Ph.D.,† Rémy Bocquet, M.D.,\* Frédérique Le Corre, M.D.,\* Jean Marty, M.D.‡

*ARRHYTHMOGENIC right ventricular dysplasia* (ARVD) is a recently described form of cardiomyopathy characterized by the occurrence of ventricular tachycardia of right ventricular origin.<sup>1,2</sup> ARVD is characterized by fibrofatty replacement of the right myocardium, linked in part to both apoptotic cell death and patchy myocarditis.<sup>3,4</sup> ARVD is an important cause of sudden arrhythmic death in young patients, especially during physical exercise, and severe forms of the disease may also lead to congestive heart failure. Diagnosis is based on clinical criteria and results from specialized testing—in particular, contrast ventriculography.<sup>5</sup> Antiarrhythmic drug therapy is the first step of treatment, but the severity of ventricular tachycardia (VT) may necessitate surgical or catheter ablation techniques or an implantable defibrillator.<sup>6,7</sup> Specific problems that may be encountered during the perioperative period have not been described. We report the specific management of severe head trauma in a patient with known ARVD.

### Case Report

A 19-yr-old man was admitted to the intensive care unit after multiple traumas in a motorcycle accident. Two years earlier, a family screening had been performed after the sudden cardiac death of his father at the age of 39 yr, which was related to one of the most severe forms of ARVD, Uhl disease. At this time, the patient was asymptomatic, but diagnosis of ARVD was performed according to the guidelines of the ARVD Task Force<sup>5</sup> on the presence of two major criteria: (1) familial disease, confirmed by histological findings, and (2) fibrofatty replacement of right ventricular myocardium on endomyocardial biopsy. The patient also had three minor criteria of the disease: (1) mild segmental right ventricular dilatation with normal left ventricle, (2) inverted T waves in leads V<sub>2</sub> and V<sub>3</sub> on the electrocardiogram, and (3) frequent premature ventricular complexes (PVCs) detected by Holter monitoring. Antiarrhythmic treatment with sotalol was started, and its efficacy was confirmed by a decrease in the number of PVCs.

The first examination of lesions, performed by the physician of the prehospital critical care team a few minutes later, revealed a severe closed head injury with a Glasgow Coma Scale score of 3, requiring

immediate tracheal intubation and mechanical ventilation. Hemodynamic parameters at this time were stable, with a regular sinus rhythm at a rate of 55 beats/min with no PVCs detected by electrocardiographic recording and an arterial blood pressure of 150/80 mmHg. Therapeutic measures to control intracranial pressure, including mechanical ventilation and sedation with 10 mg/h midazolam and 200 µg/h fentanyl and maintenance of systolic arterial blood pressure above 90 mmHg with fluid loading when necessary were started by the physician before the patient was taken to the hospital. After hospital admission, blood glucose and hemoglobin concentrations and arterial oxygen tension (Pao<sub>2</sub>) were maintained within normal range, and a mild hypocapnia was induced to prevent secondary cerebral ischemia. Computed tomography of the body and radiography performed at the time of arrival at the hospital revealed right temporal extradural hematoma and severe brain injury with multiple areas of focal hemorrhage disseminated in the brain, facial trauma with maxillary sinus fracture, right wrist fracture, and sprained right ankle.

Surgical evacuation of the extradural hematoma was planned. Heart rate and arterial blood pressure (by radial artery catheter) were continuously monitored. Anesthesia was deepened with isoflurane and fentanyl. Intraoperative electrocardiographic monitoring showed a sinus rhythm with rare PVC. Arterial blood pressure remained stable throughout the procedure. At the end of surgery, an intraparenchymatous pressure catheter was inserted, and intracranial pressure monitoring was started.

During the 6 h after surgery, intracranial pressure increased progressively to 25 mmHg, despite conventional therapy to control intracranial hypertension. Thus, the problem of increasing arterial blood pressure to reach a cerebral perfusion pressure of at least 60 mmHg arose. At this step, according to the protocol at our institution, invasive hemodynamic monitoring would have been indicated. In our patient, it was decided not to insert a Swan Ganz catheter to reduce the risk of severe ventricular arrhythmia during insertion of the catheter in the right ventricle. Fluid loading with 300 ml gelatin, repeated three times over 4 h, was not sufficient to reach the desired value of arterial blood pressure. Echocardiographic assessment of ventricular load was planned. Transthoracic rather than transesophageal echocardiography was performed because it was more rapidly available. Underlying hypovolemia could be eliminated, and vasopressor therapy was therefore indicated. To reduce the risk of ventricular arrhythmia, 0.25 µg · kg<sup>-1</sup> · min<sup>-1</sup> norepinephrine, instead of dopamine, which is usually tried first in this condition, was administered *via* a central line placed through the right jugular vein. Norepinephrine was effective in restoring cerebral perfusion pressure, but despite maintenance of enteral sotalol therapy, which kept the heart rate at approximately 60 beats/min, frequent ventricular PVC (5-25 per minute) with a prolonged period of bigeminy were observed. A short period of VT, lasting less than 10 s, occurred only once and did not require specific treatment. During the 8 following days, several prolonged periods of ventricular bigeminy and a short period of VT, lasting less than 10 s, occurred. This was not related to reflex bradycardia induced by the increase in intracranial pressure but may have been promoted by the brain injury-induced sympathetic stimulation. Potassium serum concentration remained within normal range, and a mild hypomagnesemia observed 3 days after admission was treated with intravenous magnesium sulfate. The arrhythmias were hemodynamically well-tolerated, and the treatment was not modified. Neurologic status deteriorated

\* Staff Anesthesiologist, † Assistant Professor of Anesthesiology, ‡ Professor of Anesthesiology.

Received from the Department of Anesthesiology, Beaujon Hospital, Assistance Publique-Hôpitaux de Paris, University Xavier Bichat Paris 7, Clichy, France. Submitted for publication March 27, 2000. Accepted for publication July 27, 2000. Support was provided solely from institutional and/or departmental sources.

Address reprint requests to Dr. Bonnet: Department of Anesthesiology, Beaujon Hospital, Assistance Publique-Hôpitaux de Paris, University Xavier Bichat Paris 7, 100 Bvd Général Leclerc, 92118 Clichy Cedex, France. Address electronic mail to: emmanuel.samain@bjn.ap-hop-paris.fr. Individual article reprints may be purchased through the Journal Web site, www.anesthesiology.org.

progressively, with the aggravation of intracerebral edema and intracranial hypertension. Despite a ventriculostomy drainage, intracranial hypertension led to brain death on the ninth postoperative day.

## Discussion

Arrhythmogenic right ventricular dysplasia is a rare but severe familial disease, with autosomal dominant inheritance and polymorphic phenotype expression. Diagnosis usually occurs in adolescents or young adults after exercise-induced ventricular arrhythmias, which range from frequent PVC to sustained poorly tolerated VT, characterized by an unusual pattern of left bundle branch block.<sup>5,8</sup> Ventricular fibrillation and sudden death have been observed during strenuous exercise.<sup>9</sup> A definitive diagnosis of ARVD is based on histologic demonstration of transmural fibrofatty changes of the right ventricle. Recently, the ARVD Task Force has proposed diagnosis criteria, including the presence of encompassing structural, histologic, electrocardiographic, arrhythmic, and genetic factors.<sup>5</sup>

Perioperative reduction of the risk for ventricular arrhythmia must rely on the understanding of arrhythmogenesis mechanisms in ARVD. Frequent provocation of arrhythmias during exercise, efficacy of antiarrhythmic agents with antiadrenergic properties, and sensitivity toward catecholamines have suggested the involvement of the adrenergic system. In this regard, localized sympathetic denervation of the right ventricle has been demonstrated in 83% of patients with ARVD.<sup>10</sup> This inhomogeneity may increase dispersion of refractory periods and conduction times among cardiomyocytes during adrenergic stimulation. Furthermore, the increase in heart rate and the shortening of the coupling intervals observed during adrenergic stimulation were suggested to be the main determinants of VT in ARVD.<sup>8</sup> Therefore, the anesthetic protocol should aim at reducing adrenergic stimulation. On the other hand, class I antiarrhythmic agents or sotalol, a  $\beta$ -blocker agent with class III properties, are widely used to prevent ventricular arrhythmias when left ventricular function is preserved. Amiodarone was reported to be better tolerated in left ventricular dysfunction. However, concern about the efficacy of drug treatment to prevent sudden death has emerged recently.<sup>6</sup>

At the time cerebral perfusion pressure decreased, despite a fluid challenge, we had to administer a vaso-

pressor. Among the catecholamines available, norepinephrine was chosen because it exerts a potent  $\alpha$ -adrenoceptor and moderate  $\beta$ -adrenoceptors agonist action. However, its effect on  $\beta$  adrenoceptors was sufficient to favor ventricular arrhythmias. Reinforcement of  $\beta$ -adrenergic blockade, possibly by intravenous infusion of a  $\beta$  blocker, could have been discussed at this step. Alternately, an agent with prominent  $\alpha$ -adrenergic and weak  $\beta$ -adrenergic agonist properties, such as phenylephrine, may have a lower potential for ventricular arrhythmia. However, the lack of significant inotropic effect of this agent at clinically relevant doses may induce a decreased cardiac index, which is difficult to evaluate in the absence of hemodynamic monitoring.

Adrenergic stimulation is the main precipitating factor of severe ventricular arrhythmia in ARVD. Perioperative management should include close monitoring of heart rhythm, maintenance of antiarrhythmic drugs, and limitation of sympathetic stimulation.

## References

1. Canu G, Atallah G, Claudel JP, Champagnac D, Desseigne D, Chevalier P, de Zuloaga C, Moncada E, Kirkorian G, Touboul P: Prognosis and long-term outcome of arrhythmogenic right ventricular dysplasia. *Arch Mal Coeur Vaiss* 1993; 86: 41-8
2. Fontaine G, Fontaliran F, Frank R: Arrhythmogenic right ventricular cardiomyopathies: Clinical forms and main differential diagnoses. *Circulation* 1998; 97:1532-5
3. Mallat Z, Tedgui A, Fontaliran F, Frank R, Durignon M, Fontaine G: Evidence of apoptosis in arrhythmogenic right ventricular dysplasia. *N Engl J Med* 1996; 335:1190-6
4. Basso C, Thiene G, Corrado D, Angelini A, Nava A, Valente M: Arrhythmogenic right ventricular cardiomyopathy: Dysplasia, dystrophy, or myocarditis? *Circulation* 1996; 94:983-91
5. McKenna WJ, Thiene G, Nava A, Fontaliran F, Blomstrom-Lundqvist C, Fontaine G, Camerini F: Diagnosis of arrhythmogenic right ventricular dysplasia/cardiomyopathy. Task Force of the Working Group Myocardial and Pericardial Disease of the European Society of Cardiology and of the Scientific Council on Cardiomyopathies of the International Society and Federation of Cardiology. *Br Heart J* 1994; 71:215-8
6. Fontaine G: The use of ICD's for the treatment of patients with arrhythmogenic right ventricular dysplasia (ARVD). *J Interv Card Electrophysiol* 1997; 1:329-30
7. Favale S, Barletta A, Dicandia CD, Rizzon P: Syncopal sustained ventricular tachycardia in a patient with right ventricular dysplasia. *Am J Cardiol* 1996; 78(suppl 5A):98-101
8. Leclercq JF, Potenza S, Maison-Blanche P, Chastang C, Coumel P: Determinants of spontaneous occurrence of sustained monomorphic ventricular tachycardia in right ventricular dysplasia. *J Am Coll Cardiol* 1996; 28:720-4
9. Peters S, Reil GH: Risk factors of cardiac arrest in arrhythmogenic right ventricular dysplasia. *Eur Heart J* 1995; 16:77-80
10. Wichter T, Hindricks G, Lerch H, Bartenstein P, Borggrefe M, Schober O, Breithardt G: Regional myocardial sympathetic dysinnervation in arrhythmogenic right ventricular cardiomyopathy: An analysis using 123I-meta-iodobenzylguanidine scintigraphy. *Circulation* 1994; 89:667-83

## Postoperative Sudden Death in Two Adolescents with Myelomeningocele and Unrecognized Arrhythmogenic Right Ventricular Dysplasia

Brigitte Houfani, M.D.,\* Philippe Meyer, M.D.,\* Jacques Merckx, M.D.,\* Pascal Roure, M.D.,\* Jean Paul Padovani, M.D.,†  
Guy Fontaine, M.D.,‡ Pierre Carli, M.D.§

*POSTOPERATIVE sudden death* is a dramatic event occurring in 1.1 per 1,000 anesthetic procedures.<sup>1</sup> A discrepancy between the clinical impression regarding the cause of death and the anatomic findings at autopsy were found in 23–39% of cases studied.<sup>2</sup> In some cases, unsuspected preexisting disease contributing directly to death could be only found at autopsy. *Arrhythmogenic right ventricular dysplasia* (ARVD) is a rarely diagnosed autosomal dominant disease described by Fontaine *et al.*<sup>3</sup> in 1979. It mainly occurs in otherwise healthy adolescents and young adults with complex ventricular arrhythmia and effort-related sudden deaths.<sup>3</sup> Only one case of ventricular tachycardia related to ARVD has been described after general anesthesia.<sup>4</sup> We report the cases of two adolescents who had previously undergone multiple anesthetic procedures and died after anesthesia for major orthopedic surgery. In these cases, the diagnosis of ARVD was only made at autopsy.

### Case Report

These two cases were observed during a 5-yr period in Hopital Necker-Enfants Malades of Paris, France, which performed 50–60 complex vertebral fusions each year. The two patients were classified as American Society of Anesthesiologists III and were adolescents with a previous history of severe myelomeningocele and Chiari II malformation. Severe muscular scoliosis developed, and anterior thoracic vertebral fusion was required. Both patients had undergone multiple previous neurosurgical, orthopedic, and urological procedures without noticeable complications. Their preoperative cardiac examinations were unremarkable, and electrocardiographic data were considered to be normal. However, in retrospect, the electrocardiogram in the second case depicted T-wave inversion in V<sub>1</sub>-V<sub>2</sub> precordial leads. Induction of anesthesia with thiopental, sufentanil, and vecuronium and maintenance with 1 minimum alveolar concentration (MAC) isoflurane

and continuous infusion of sufentanil were uneventful. The procedures lasted 9 h. Total blood loss was estimated at 1,300–1,700 ml and was replaced by total perioperative autotransfusion. Final hematocrits were 29 and 28%. After the procedure, the patients regained consciousness rapidly and were transferred to the postoperative intensive care unit, where assisted ventilation was maintained for the first postoperative hours.

#### Case 1

A 13-yr-old, 44-kg girl underwent tracheal extubation without difficulties 12 h after the end of the orthopedic procedure. The patient was then discharged to the surgical ward, alert and pain-free. Thirty hours after the end of the surgical procedure, she experienced, without preceding symptoms or increased blood loss through surgical drainage, abrupt hypotension (arterial blood pressure, 70/40 mmHg) that did not respond to immediate vascular loading. Continuous electrocardiographic monitoring at this time showed what was considered to be a sinus tachycardia (heart rate, 140 beats/min). Within minutes, cardiac arrest with asystole occurred without preceding recognized arrhythmia. Despite immediate resuscitation initiated with external chest compression, endotracheal intubation, multiple attempts to cardioversion, and epinephrine and lidocaine infusion, the patient did not regain spontaneous cardiac activity and was pronounced dead 2 h later.

#### Case 2

While still undergoing mechanical ventilation in the postoperative intensive care unit 4 h after discharge from the operating room, a 16-yr-old, 50-kg girl experienced abrupt hypotension (arterial blood pressure, 65/35 mmHg) with tachycardia that was considered to be sinus with sporadic polymorphic premature ventricular beats (heart rate, 160 beats/min). Shortly thereafter, monomorphic ventricular tachycardia occurred, followed by a short-lasting episode of ventricular fibrillation and resulting asystole. Despite classic resuscitation that was initiated immediately, she did not regain spontaneous cardiac activity, and resuscitation was discontinued after 2 h.

In both cases, pathologic examination of the heart at autopsy depicted typical features of ARVD with massive replacement of myocytes of the right myocardium by fibroadipose tissue predominating in the mediomural layers. In some places, endocardium was reduced to a thin rim of myocardial tissue. These features of ARVD were associated with a myocardial infiltration with lymphocytes and plasmocytes, suggesting an acute inflammatory reaction associated with chronic degenerative pathology.

### Discussion

Sporadic cases of ARVD have been described in young adults and children with no clinically apparent cardiac disorders who experienced exercise-induced sudden deaths and complex ventricular arrhythmias.<sup>4,6–8</sup> Typi-

\* Senior Staff Anesthesiologist, § Professor and Chairman, Department of Pediatric Anesthesia, † Senior Staff Surgeon, Department of Pediatric Orthopedic Surgery, Assistance Publique-Hopitaux de Paris et Université Paris V, Centre Hospitalier Universitaire Necker-Enfants Malades. ‡ Consulting Cardiologist, Department of Cardiology, Assistance Publique-Hopitaux de Paris, Hôpital Jean Rostand.

Received from the Departments of Pediatric Anesthesia and Pediatric Orthopedic Surgery, Assistance Publique-Hopitaux de Paris et Université Paris V, Centre Hospitalier Universitaire Necker-Enfants Malades, Paris, France, and the Department of Cardiology, Assistance Publique-Hopitaux de Paris, Hôpital Jean Rostand, Ivry, France. Submitted for publication February 8, 2000. Accepted for publication September 19, 2000. Support was provided solely from institutional and/or departmental sources.

Address reprint requests to Dr. Meyer: CHU Necker-Enfants Malades, Département d'Anesthésie-Réanimation, 149 rue de Sèvres, 75015 Paris, France. Address electronic mail to: philippe.meyer@nck.ap-hop-paris.fr. Individual article reprints may be purchased through the Journal Web site, www.anesthesiology.org.

cal histologic findings are nonhomogenous replacement of more than 20% of the myocytes by a fibroadipose tissue predominantly in the subepicardial and myocardial layers.<sup>9</sup> The hereditary autosomal dominant transmission of ARVD has been related to the localization of genes on chromosome 14q23-q24 and a locus at chromosome 3p23 with variable expression and incomplete penetrance.<sup>10,11</sup> Its prevalence is estimated to be approximately 1 in 5,000, with a 50% penetrance in some families. Recessive forms with more severe expression, as in the Naxos disease, in which dysplasia is associated with palmoplantar keratosis, have been described.<sup>4</sup> The risk of sudden death has been estimated to be 2.5% per year.<sup>11</sup> Severity of ventricular dysplasia does not correlate with long-term outcome or arrhythmic events, but the risk of sudden death seems to be higher in patients without previous episodes of ventricular tachycardia (VT), in those who have dilated right ventricle, and in those who have experienced syncope.

The implications of ARVD for anesthesiologists are important because patients with ARVD are particularly at risk for development of VT or sudden death in the perioperative period. There are no previously described cases of the association between myelomeningocele and sudden postoperative death, and there is only one previously described case of ARVD causing abrupt ventricular arrhythmia during general anesthesia.<sup>5</sup> These two consecutive cases are probably coincidental, and family genetic screening results were negative. Interestingly, both these patients had multiple previous procedures without complications. These severely disabled children probably had progressing ARVD but remained asymptomatic. The mechanism of sudden death could be exercise-induced stress related to a major surgical procedure resulting in abrupt tachyarrhythmia. In retrospect, hypotension, which was the first reported symptom, probably resulted from an episode of tachyarrhythmia that was falsely interpreted as sinus tachycardia. Histologic findings suggested some form of associated acute myocarditis of unknown origin that could play a secondary role in the abrupt development of tachyarrhythmia. A careful and oriented cardiac evaluation is mandatory in patients with personal or familial history of sudden death or VT in young individuals, exercise-induced palpitations, or syncope. Symptoms are induced by exercise, and physical examination results are normal at rest in 50% of the patients.<sup>4</sup> Giant waves observed by jugular inspection, murmur, or tricuspid regurgitation related to dilated right cavities are only observed in older patients with diffuse myocardial involvement. Common electrocardiographic anomalies include T-wave inversion in anterior precordial leads, ventricular premature complexes, and monomorphic VT with left bundle branch block induced by exercise. Surface electrocardiography shows longer QRS duration and late potential duration over the dysplastic areas. Young patients presenting with T-wave

inversion on anterior precordial leads should have echocardiography that is suggestive of severe ARVD with major dilatation when apical dyskinesia, right ventricular dilatation, structural abnormality, diastolic bulge, or systolic dyskinesia of the infero-basal wall are noted.<sup>4</sup> When present, these anomalies should lead to noninvasive explorations with spiral computed tomography and magnetic resonance imaging to define morphology of the right cavities and to identify early stages, extent of the disease, and the site of the dominant fatty cardiac involvement with spin echo magnetic resonance imaging.<sup>12</sup> This should be completed by ventricular angiography, which is the gold standard for clinical diagnosis.<sup>9</sup> The key to histologic diagnosis is endocardial biopsy. More than 90% of asymptomatic patients with high clinical risks and positive echocardiography have positive myocardial biopsy and are at risk for experiencing serious ventricular arrhythmia and sudden death. However, in some cases, the patchy nature of the myocardial infiltration makes endocardial biopsy an unreliable diagnostic technique. Patients at high risk should benefit from treatment before scheduled surgical procedures. Pharmacologic treatment is aimed at controlling emergence or recurrence of VT, but the suppression of VT has not shown a direct survival benefit.<sup>4</sup> The most useful antiarrhythmic drug is sotalol, which prevents severe arrhythmia in 60–70% of patients.<sup>13</sup> In patients with drug refractoriness, endocardial fulguration and encircling ventriculotomy have been proposed.<sup>14</sup> The progress in technology of implantable cardioverter defibrillators with nonthoracotomy leads has made this technique the most safe and efficient for preventing VT.<sup>15</sup> During anesthesia and recovery, special attention should be made to avoid noxious stimuli during light anesthesia, uncompensated blood losses, hypercarbia, hypoxia, and acidosis capable of inducing cardiac arrhythmia.<sup>16</sup> Halothane should not be used. Finally, unexplained perioperative sudden death in young patients should command autopsy with careful cardiac examination for possible fatty cardiac involvement featuring ARVD.<sup>2</sup> Familial screening is necessary when ARVD has been diagnosed.

## References

1. Aubas S, Biboulet P, Daures JP, du Cailar J: Incidence et étiologies des arrêts cardiaques survenant pendant la période opératoire et le réveil de l'anesthésie: A propos de 102 468 anesthésies. *Ann Fr Anesth Réanim* 1991; 10:436–42
2. Stothert JC, Gbaanador G: Autopsy in general surgery practice. *Am J Surg* 1991; 162:585–8
3. Fontaine G, Guiraudon G, Frank R, Cabrol C, Grosogeat Y: Arrhythmogenic right ventricular dysplasia: A previously unrecognized syndrome. *Circulation* 1979; 60(suppl 2):65–9
4. Dalal P, Fujisic K, Hupart P, Schwietzer P: Arrhythmogenic right ventricular dysplasia: A review. *Cardiology* 1994; 85:361–69
5. Massen H, Cosnay JP, Bouhazer M, Mercat C: Révélation lors de l'anesthésie d'une dysplasie ventriculaire droite arrhythmogène. *Ann Fr Anesth* 1986; 5:436–40
6. Myriantsefs M, Cariolou M, Eldar M, Minas M, Zambartas C: Exercise-induced ventricular arrhythmias and sudden cardiac death in a family. *Chest* 1997; 111:130–4
7. Kullo IJ, Edwards WD, Seward JB: Right ventricular dysplasia: The Mayo clinic experience. *Mayo Clin Proc* 1995; 70:541–8

8. Pawel BR, de Chadaverian JP, Wolk J, Donner RM, Vogel RL, Braverman P: Sudden death in childhood due to arrhythmogenic right ventricular dysplasia. *Pediatr Pathol* 1994; 14:987-95

9. Thiene G, Nava A, Corrado D, Rossi L, Penelli N: Right ventricular cardiomyopathy and sudden death in young people. *N Engl J Med* 1988; 318:129-33

10. Rampazzo A, Nava A, Danielli GA, Buja G, Daliento L, Fasoli G, Scognamiglio R, Corrado D, Thiene G: The gene for arrhythmogenic right ventricular cardiomyopathy maps to chromosome 14q23-q24. *Hum Mol Genet* 1994; 3:959-62

11. Ahmad F, Li D, Karibe A, Gonzalez O, Tapscott T, Hill R, Weilbaecher D, Blackie P, Furey M, Gardner M, Bachinski LL, Roberts R: Localization of a gene responsible for arrhythmogenic right ventricular dysplasia to chromosome 3p23. *Circulation* 1998; 98:2791-5

12. Blake LM, Scheinman MM, Higgins CB: MR features of arrhythmogenic right ventricular dysplasia. *Am J Roentgenol* 1994; 162:809-12

13. Wichter T, Borggreffe M, Haverkamp W, Chen X, Breithardt G: Efficiency of antiarrhythmic drugs in patients with arrhythmogenic right ventricular disease. *Circulation* 1992; 86:29-37

14. Ferguson TB, Cow JL: Arrhythmia surgery. *Coron Artery Dis* 1996; 7:36-44

15. Link MS, Wang PJ, Haugh CJ, Homoud MK, Foote CB, Costeas XB, Estes NA: Arrhythmogenic right ventricular dysplasia: Clinical results with implantable cardioverter defibrillators. *J Interv Card Electrophysiol* 1997; 1:41-8

16. Atlee JL, Bosnjack ZJ: Mechanisms for cardiac arrhythmias during anesthesia. *ANESTHESIOLOGY* 1990; 72:347-74

Anesthesiology 2001; 95:259-61

© 2001 American Society of Anesthesiologists, Inc. Lippincott Williams & Wilkins, Inc.

## Drug-induced Liver Disease during Continuous Epidural Block with Bupivacaine

Masataka Yokoyama, M.D.,\* Ichiro Ohashi, M.D.,† Hideki Nakatsuka, M.D.,‡ Satoshi Mizobuchi, M.D.,‡ Yuichiro Toda, M.D.,† Masaki Matsumi, M.D.,\* Kiyoshi Morita, M.D.,§ Masahisa Hirakawa, M.D.¶

BUPIVACAINE is a widely used and generally safe local anesthetic. Although adverse reactions to bupivacaine have been reported, most of them are caused by accidental intravascular injection or overdosage. Other cases include anaphylactoid reactions<sup>1</sup> and delayed cutaneous reactions.<sup>2</sup> We present four cases of liver injury that occurred during management of postherpetic neuralgia (PHN) and lumbar disc hernia by continuous epidural block with bupivacaine.

### Case Reports

#### Case 1

A 62-yr-old man with a 4-month history of T4-T5 PHN was admitted to the hospital for pain relief. He had taken 5 mg amlodipine daily for 5 yr. At the time of admission, laboratory tests, including complete blood count, liver function and enzymes, C-reactive protein (CRP), blood urea nitrogen, creatinine, electrolytes, and bleeding and coagulation times were unremarkable. After admission, an epidural injection of 0.25% bupivacaine, 4 ml, was administered four times daily, and a continuous epidural infusion of 0.25% bupivacaine was administered at a rate of 2 ml/h using a disposable continuous infusion device. The patient rested in a bed for 1 h after every bolus injection. Blood pressure and heart rate recorded every 10 min and oxygen saturation monitored continuously by pulse oximetry (SpO<sub>2</sub>) did not change at any time during treatment. Continuous infusion was performed for 12 days, and the frequency of bolus injection was decreased gradually. Also, 25 mg amitriptyline was administered daily. On the 18th day after admission to the hospital, the patient developed erythema on the trunk, a fever of 38-39°C, and general malaise. The total dose of infused bupivacaine was 1,980 mg. There was no sign of epidural

catheter infection. However, blood tests showed increases in aspartate aminotransferase (AST) to 221 (normal range, 11-32) IU/l, alanine aminotransferase (ALT) to 220 (11-32) IU/l, alkaline phosphatase (ALP) to 214 (6-39) IU/l,  $\gamma$ -glutamyl transpeptidase ( $\gamma$ -GTP) to 268 (3-40) IU/l, and CRP to 1.9 (<0.3) mg/dl. These values increased over the next week, reaching peaks of 512 IU/l AST, 976 IU/l ALT, 630 IU/l ALP, 673 IU/l  $\gamma$ -GTP, and 8.0 mg/dl CRP. Total bilirubin concentration increased to 2.1 (0.3-1.2) mg/dl, and the percentage of eosinophilic cells was 9 (0-7)%. Abdominal computed tomography and echography showed nothing abnormal. Tests for serologic markers of acute hepatitis A (immunoglobulin M anti-hepatitis A virus), B (immunoglobulin M anti-hepatitis B core antigen and -hepatitis B surface antigen), and C (immunoglobulin M anti-hepatitis C virus) were negative. Tests for immunoglobulin M anti-cytomegalo virus (CMV), anti-Epstein Barr virus (EBV), and anti-herpes zoster virus (HZV) were negative, as well. Although lymphocyte cell stimulation tests (LSTs) with amlodipine, amitriptyline, and bupivacaine were negative, the increase in liver enzymes was most suggestive of drug-induced liver disease. The epidural block and other medications were discontinued. Skin eruption and fever resolved within a week. The patient received laser therapy for control of pain. The increased liver enzymes returned gradually to normal within the next 21 days. Administration of amitriptyline and amlodipine was restarted, and the patient was discharged from the hospital without incident. However, 2 months later, he was readmitted for severe pain. An epidural injection of 4 ml lidocaine, 1%, was administered 4 times daily for 2 weeks and twice daily for 1 week. There was no increased transaminase or eosinophilia during the treatment. Since this time, the patient has been taking amitriptyline for 2 yr, and his liver function has been normal.

#### Case 2

A 72-yr-old woman had left lower extremity pain caused by an L4-L5 herniated disc. The patient had not been taking any medication. At the time of her admission to the hospital, her blood test results were normal. After admission, an epidural injection of 6 ml bupivacaine, 0.125%, was administered to the patient 4 times daily for 2 weeks and twice daily for 5 days. Blood pressure and SpO<sub>2</sub> were stable during epidural infusion. On the 20th day after admission, she reported headache and nausea and had erythema on the trunk and a fever of 38-39°C. The total dose of epidural infused bupivacaine was 495 mg. There was no sign of epidural catheter infection. However, blood tests showed increases in AST to 305 IU/l, ALT to 221 IU/l, ALP to 140 IU/l,  $\gamma$ -GTP to 100 IU/l, and CRP to 1.4 mg/dl. These values increased over the next week, reaching peaks of 891 IU/l AST, 779 IU/l ALT, 496 IU/l

\* Assistant Professor, † Junior Staff Anesthesiologist, ‡ Staff Anesthesiologist, § Associate Professor, ¶ Professor and Chairman.

Received from the Department of Anesthesiology and Resuscitology, Okayama University Medical School, Okayama City, Japan. Submitted for publication October 20, 2000. Accepted for publication February 6, 2001. Support was provided solely from institutional and/or departmental sources.

Address reprint requests to Dr. Yokoyama: Department of Anesthesiology and Resuscitology, Okayama University Medical School, 2-5-1, Shikata-cho, Okayama City, Okayama 700-8558, Japan. Address electronic mail to: masayoko@cc.okayama-u.ac.jp. Reprints may be purchased through the Journal Web site, www.anesthesiology.org.

ALP, 450 IU/l  $\gamma$ -GTP, and 4.2 mg/dl CRP. Total bilirubin concentration increased to 9.6 mg/dl, and the percentage of eosinophilic cells increased to 12%. Abdominal computed tomography and echography showed nothing abnormal. Acute hepatitis A, B, and C and hepatitis CMV, EBV, and HZV were ruled out after serologic testing. Although an LST with bupivacaine was negative, epidural block was discontinued. Skin eruption and fever resolved within a week. An L5 root block with lidocaine and steroids for control of pain was administered to the patient. The increased liver enzymes returned gradually to normal within the next 32 days.

### Case 3

A 67-yr-old woman had experienced T5–T6 PHN for 3 months and had been taking 50 mg diclofenac daily. In addition, she had trigeminal neuralgia and had taken 300 mg carbamazepine daily for more than 5 yr. At the time of her admission to the hospital, administration of a 5-ml epidural injection of 0.25% bupivacaine 4 times daily, continuous infusion of 0.25% bupivacaine at 2 ml/h, and 20 mg amitriptyline daily were begun. Diclofenac, 25 mg, was administered occasionally. There was no decrease in blood pressure during epidural infusion. Blood tests on the 14th day after admission showed increases in AST to 44 IU/l, ALT to 99 IU/l, ALP to 233 IU/l, and  $\gamma$ -GTP to 94 IU/l. The total dose of epidural infused bupivacaine was 2,210 mg. She was asymptomatic, but her liver function deteriorated over the next 20 days, showing peak values of 93 IU/l AST, 282 IU/l ALT, 391 IU/l ALP, and 322 IU/l  $\gamma$ -GTP. The percentage of eosinophilic cells was 9%. Abdominal computed tomography and echography showed nothing abnormal. Acute hepatitis A, B, and C and hepatitis CMV, EBV, and HZV were ruled out by serologic testing. LSTs with amitriptyline, bupivacaine, diclofenac, and carbamazepine were negative; however, we discontinued continuous epidural block and medications. The patient received laser therapy, and the increased concentrations of liver enzymes gradually returned to normal within 48 days. Amitriptyline administration was restarted without incident, and the patient was discharged from the hospital. Six months later, she had T10–T11 herpes zoster and was readmitted for pain control. This time, an epidural injection of 4 ml lidocaine, 1%, was administered 4 times daily for 10 days and twice daily for 5 days, in addition to 20 mg amitriptyline daily. There was no increased transaminase or eosinophilia during or after her second hospital stay.

### Case 4

An 84-yr-old woman had a 3-month history of T2–T3 PHN. She had taken 25 mg diclofenac occasionally before admission to the hospital. At the time of admission, her blood test results were normal. For continuous epidural block, 0.25% bupivacaine, 4 ml, was injected 4 times daily, in addition to continuous 0.125% bupivacaine at a rate of 2 ml/h. She did not take other medications after admission. Her blood pressure and SpO<sub>2</sub> were stable during epidural infusion. On the 13th day after admission, she reported general malaise and loss of appetite and had a fever of 38–39°C. The total dose of epidural infused bupivacaine was 1,200 mg. Blood tests showed increases in AST to 381 IU/l, ALT to 709 IU/l, ALP to 926 IU/l,  $\gamma$ -GTP to 147 IU/l, and CRP to 2.3 mg/dl and an increased amount of eosinophilic cells (12%). No sign of epidural catheter infection was observed. Abdominal computed tomography and echography did not determine the cause of the symptoms. Tests for serologic markers of acute hepatitis A, B, and C were negative; hepatitis CMV, EBV, and HZV also were ruled out. The fever resolved within 5 days. Although the results of LSTs with bupivacaine and diclofenac were negative, we decided that bupivacaine-induced liver disease was the most likely cause of the symptoms. We changed from bupivacaine to lidocaine. After this change, the increased amount of liver enzymes normalized gradually over the next 25 days.

## Discussion

The patients' histories, clinical courses, symptoms, and signs were all consistent with drug-induced liver disease. No evidence indicated that the patients had visceral herpes zoster. Other possible causes of liver disease, such as a biliary disorder or ongoing viral hepatitis, were ruled out. Although extended epidural block may cause a decrease in hepatic blood flow, limited epidural block does not change blood flow.<sup>3</sup> Limited epidural blocks with a small dose of bupivacaine were administered to the patients, and their blood pressure and SpO<sub>2</sub> did not decrease during block.

Drug-induced liver injury can be a direct toxic injury, an allergic reaction, or a metabolic aberration. Direct toxic injury is predictable, dose-related, reproducible in animal models, and associated with a relatively short latency period. With the allergic reaction, the exposure period is usually 1–5 weeks, and skin rash, fever, and eosinophilia are common. The response to challenge test is usually prompt. With the metabolic aberration, metabolic idiosyncratic abnormalities are implicated, the exposure period varies from weeks to months, and features of hypersensitivity, such as eosinophilia, are absent.<sup>4</sup> Because direct toxic drugs were not administered, these patients' responses should be classified as allergic reaction or metabolic aberration. Patient 1 had fever and skin rash, and patient 2 had fever, skin rash, and eosinophilia. Fever and eosinophilia were observed in patient 4. These patients' responses seem to fall into the category of allergic reaction, whereas the response of patient 3 seems to be a metabolic aberration because she was asymptomatic.

Although the sensitivity of the LST is low, several reports show successful use of the test to detect hypersensitivity reactions in the liver.<sup>5,6</sup> The belief is that the test often gives false-negative results but only rarely gives false-positive results in cases of drug hypersensitivity, so a positive result should establish the presence of drug hypersensitivity.<sup>5</sup> We believed that drug-induced liver disorder was very likely in these patients despite the negative tests with all drugs used.

Other drugs may cause liver dysfunction. However, amlopidine (case 1), carbamazepine (case 3), and diclofenac (cases 3 and 4) had been taken for several months or years before admission and in some cases were uneventfully reintroduced after resolution of the liver disorder. Amitriptyline was administered to two patients after admission (cases 1 and 3), but in both, the drug was readministered without difficulty after discontinuation of bupivacaine and normalization of liver enzyme concentrations. These factors make it unlikely that these other drugs were the cause of the changes seen in these patients.

We consider bupivacaine to be the most possible cause of liver injury in these patients. First, changing from bupivacaine to lidocaine with readministration of other medications normalized liver function. Furthermore, bupivacaine was the only drug being used when liver injury was observed in patients 2 and 4. Second, we had long-term experience in the use of lidocaine for control of pain in PHN patients before we began using bupivacaine. Despite having used lidocaine for the past 10 yr in PHN patients, we did not observe drug-induced liver disease as in these patients. We did not administer a challenge test to readminister bupivacaine because drug readministration is inappropriate and unethical. Because local anesthetics often contain preservative agents, clinical manifestations might be elicited by sensitization to such substances. That circumstance is unlikely in these patients because bupivacaine and lidocaine have the same preservative agent, and lidocaine did not elicit clinical manifestations.

Three of our four patients had PHN. Varicella-zoster viral infection is known to involve the CD4<sup>+</sup> population of lymphocytes and to result in suppression of immunity.<sup>7</sup> However, none of these patients were in the acute stage of herpes zoster, and one patient had lumbar disc hernia. There are several reports that the necessary duration of continuous epidural block for the treatment of PHN is approximately 4 weeks.<sup>8,9</sup> In Japan, it is common to perform continuous epidural infusion for pain relief in

PHN patients for long periods, and bupivacaine use is increasing. It is possible that this practice may result in an increase in drug-induced liver disease. Because such liver injury occurs with low frequency, liver function test screening of all patients to whom this drug is administered may not be practical. However, symptoms of liver disease or abnormalities in liver function warrant immediate discontinuation of the drug.

The authors thank Wasa Ueda, M.D., Department of Anesthesiology and Resuscitology, Kochi Medical School, Nankoku City, Kochi, Japan, for reviewing the manuscript.

## References

1. Brown DT, Beamish D, Wildsmith JAW: Allergic reaction to an amide local anaesthetic. *Br J Anaesth* 1981; 53:435-7
2. Craft CV, Good RP: Delayed hypersensitivity reaction of the knee after injection of arthroscopy portals with bupivacaine (marcaine). *Arthroscopy* 1994; 10:305-8
3. Meissner A, Weber TP, Van Aken H, Rolf N: Limited upper thoracic epidural block and splanchnic perfusion in dogs. *Anesth Analg* 1999; 89:1378-81
4. Zimmerman HJ: Drug-induced liver disease. *Drugs* 1978; 16:25-45
5. Houwerzijl J, DeGast G, Nater J, Esselink M, Nieweg H: Lymphocyte stimulation tests and patch tests in carbamazepine hypersensitivity. *Clin Exp Immunol* 1977; 29:272-5
6. Maria V, Pinto L, Victorino R: Lymphocyte reactivity to ex-vivo drug antigens in drug-induced hepatitis. *J Hepatol* 1994; 21:151-8
7. Zerboni L, Sommer M, Ware CF, Arvin AM: Varicella-zoster virus infection of a human CD-positive T-cell line. *Virology* 2000; 270:278-85
8. Morimoto M, Morimoto E, Okabayashi K, Morimoto M, Hyodo M: Use of a disposable infusion device for continuous epidural block. *Masui* 1994; 43:1336-40
9. Kang FC, Chang PJ, Chen HP, Tsai YC: Patient-controlled epidural analgesia for postherpetic neuralgia in an HIV-infected patient as a therapeutic ambulatory modality. *Acta Anaesthesiol Sin* 1998; 36:235-9

Anesthesiology 2001; 95:261-4

© 2001 American Society of Anesthesiologists, Inc. Lippincott Williams & Wilkins, Inc.

## Regional Pericarditis Mimicking Myocardial Infarction

George Youssef, M.D.,\* Sameh Khouzam, M.D.,† Juraj Sprung, M.D., Ph.D.,‡ Denis L. Bourke, M.D.§

ACUTE pericarditis is generally considered simple to diagnose because of its characteristic diffuse ST-segment elevation. In contrast, acute myocardial infarction typically presents with more localized ST-segment changes.<sup>1</sup>

We describe a patient who presented for emergency surgery with marked ST-segment elevation in the inferolateral leads, suggestive of acute myocardial ischemia

and infarction. However, a thorough diagnostic workup ruled out myocardial injury, and further evaluation suggested that the patient's electrocardiographic pattern was caused by a regional or localized pericarditis. Regional pericarditis has only been described in the postinfarction setting<sup>2-4</sup> and in a case in which the ST-segment elevation was initially more pronounced in the anterior leads but later evolved to generalized ST-segment elevation with a mild enzyme increase.<sup>5</sup>

\* Resident in Anesthesiology, Division of Anesthesiology and Critical Care Medicine, † Resident in Internal Medicine, Department of Internal Medicine, The Cleveland Clinic Foundation. ‡ Associate Professor of Anesthesiology, Department of Anesthesiology, Mayo Foundation. § Professor of Anesthesiology, Department of Anesthesiology, University of Maryland School of Medicine.

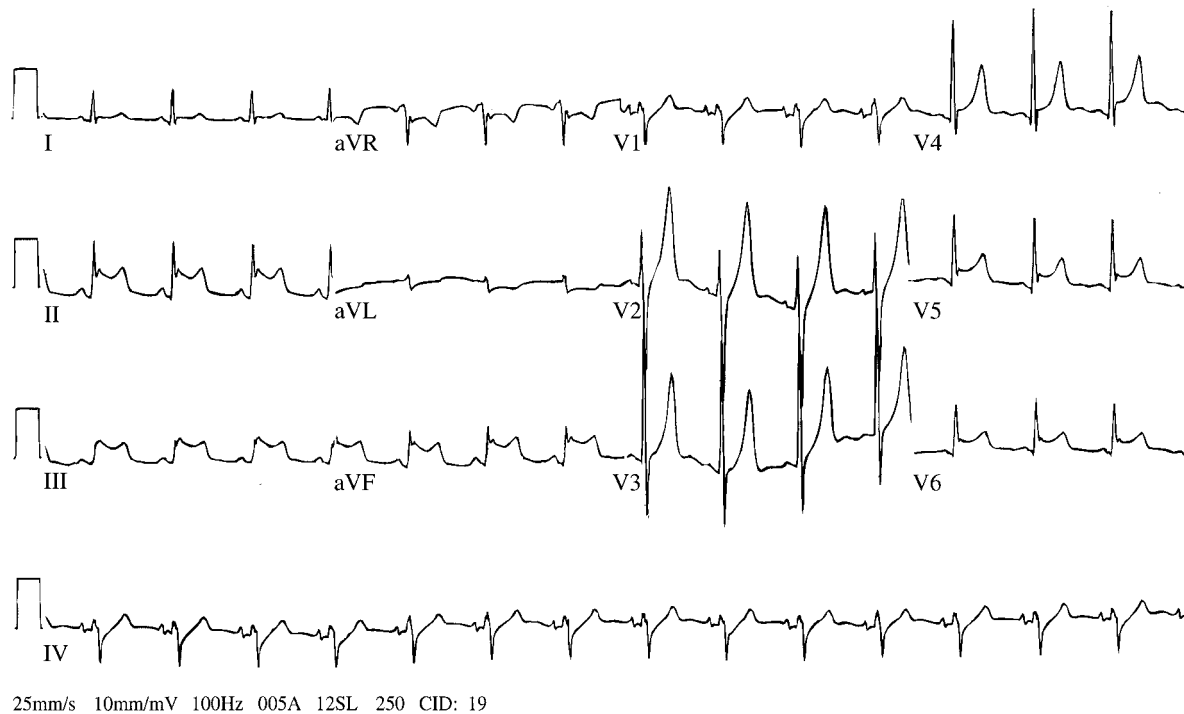
Received from the Division of Anesthesiology and Critical Care Medicine and the Department of Internal Medicine, The Cleveland Clinic Foundation, Cleveland, Ohio; the Department of Anesthesiology, Mayo Foundation, Rochester, Minnesota; and the Department of Anesthesiology, University of Maryland School of Medicine, Baltimore, Maryland. Submitted for publication October 13, 2000. Accepted for publication February 7, 2001. Support was provided solely from institutional and/or departmental sources.

Address reprint requests to Dr. Bourke: 13004 Gent Road, Reisterstown, Maryland 21136-5717. Address electronic mail to: squashwiz@aol.com. Individual article reprints may be purchased through the Journal Web site, www.anesthesiology.org.

## Case Report

A 46-yr-old man with abdominal free air shown by computed tomography scan was scheduled to undergo emergency exploratory laparotomy. One month previously, he had undergone kidney and pancreas transplantations as a result of insulin-dependent diabetes and end-stage renal disease.

In the operating room, after applying standard monitoring, the electrocardiograph showed ST-segment elevation in leads II, III, and aVF. There was no dysrhythmia. The patient denied chest pain and was hemodynamically stable (blood pressure, 125/90 mmHg; heart rate, 89



**Fig. 1. Electrocardiogram showing marked ST-segment elevation predominantly in inferior leads (II, III, aVF) and lateral leads (V<sub>4</sub>-V<sub>6</sub>). Also, peaked, tall, symmetric T waves are present in V<sub>2</sub>-V<sub>4</sub>. PR-segment depression is present in several leads and lateral leads (I, aVL).**

beats/min). A twelve-lead electrocardiogram showed ST-segment elevation in leads II, III, aVF, and V<sub>4</sub>-V<sub>6</sub> in addition to tall, peaked T waves in V<sub>2</sub>-V<sub>4</sub> (fig. 1). The laboratory report showed a serum potassium concentration of 7.2 mEq/l, a hematocrit of 25%, a creatinine concentration of 1.4 mg/dl, a bicarbonate concentration of 24 mEq/l, and a serum glucose concentration of 103 mg/dl. Other laboratory results were unremarkable.

Surgery was postponed to correct hyperkalemia and to investigate the electrocardiographic results. After treatment, when the serum potassium concentration decreased to 5.5 mEq/l, the T waves returned to normal, but the ST-segment elevation persisted. A bedside two-dimensional transthoracic echocardiogram that evaluated all the sixteen segments of the left ventricle showed hyperdynamic ventricles with no segmental wall motion abnormality and no signs of pericardial effusion. The serum troponin T concentration was 0.02 ng/ml (normal, 0.00-0.10 ng/ml), and three sets of creatine phosphokinase enzymes drawn at 8-h intervals were all within normal limits. The electrocardiographic pattern (fig. 1) was analyzed more closely. Despite the local nature of the ST-segment changes, the pattern was otherwise consistent with pericarditis. The ST-segment elevation was concave and was accompanied by upright T waves, PR depression, and reciprocal changes in aVR and V<sub>1</sub>. The patient's clinical course and the electrocardiographic analysis suggested that the electrocardiographic changes in this patient were caused by regional pericarditis.

Exploratory laparotomy for intestinal perforation was performed the next day, with an uneventful perioperative course. ST-segment elevation gradually resolved during the subsequent week (fig. 2).

## Discussion

The classic diagnostic triad of acute pericarditis includes specific electrocardiographic abnormalities, chest pain, and pericardial friction rub.<sup>1</sup> Chest pain, when

present, can be confused with that of myocardial infarction. The chest pain of pericarditis, however, is usually constant and can be relieved by sitting up and leaning forward. Further, pericardial friction rub, when present, is often evanescent and can be overlooked. Therefore, the frequency of pericarditis is thought to be underestimated.<sup>6</sup>

The electrocardiographic changes of acute pericarditis typically evolve through four stages.<sup>1,7,8</sup> Stage 1 lasts several days to 2 weeks and is characterized by widespread concave ST-segment elevation, usually less than 5 mm, with reciprocal depression in leads over the areas not bounded by the pericardial-myocardial interface, aVR and V<sub>1</sub>.<sup>4</sup> The ST-segment elevation is believed to reflect the abnormal repolarization caused by injury of the superficial myocardium or a superficial myocarditis. Except for leads aVR and V<sub>1</sub>, the PR segment is usually depressed, likely reflecting abnormal atrial repolarization caused by inflammation.<sup>7</sup> PR depression is nearly as sensitive and specific for acute pericarditis as the more familiar ST-segment changes.<sup>9</sup> During stage 2, lasting several days to weeks, the ST and PR segments both return toward isoelectric status. Stage 3 usually begins around the third week and may last for several weeks, during which T waves may become inverted. Finally, during stage 4, there is a gradual resolution of any T-wave changes.

Distinguishing acute pericarditis from myocardial infarction can be problematic. In acute pericarditis, ST-segment elevation is usually seen in most of the leads. If



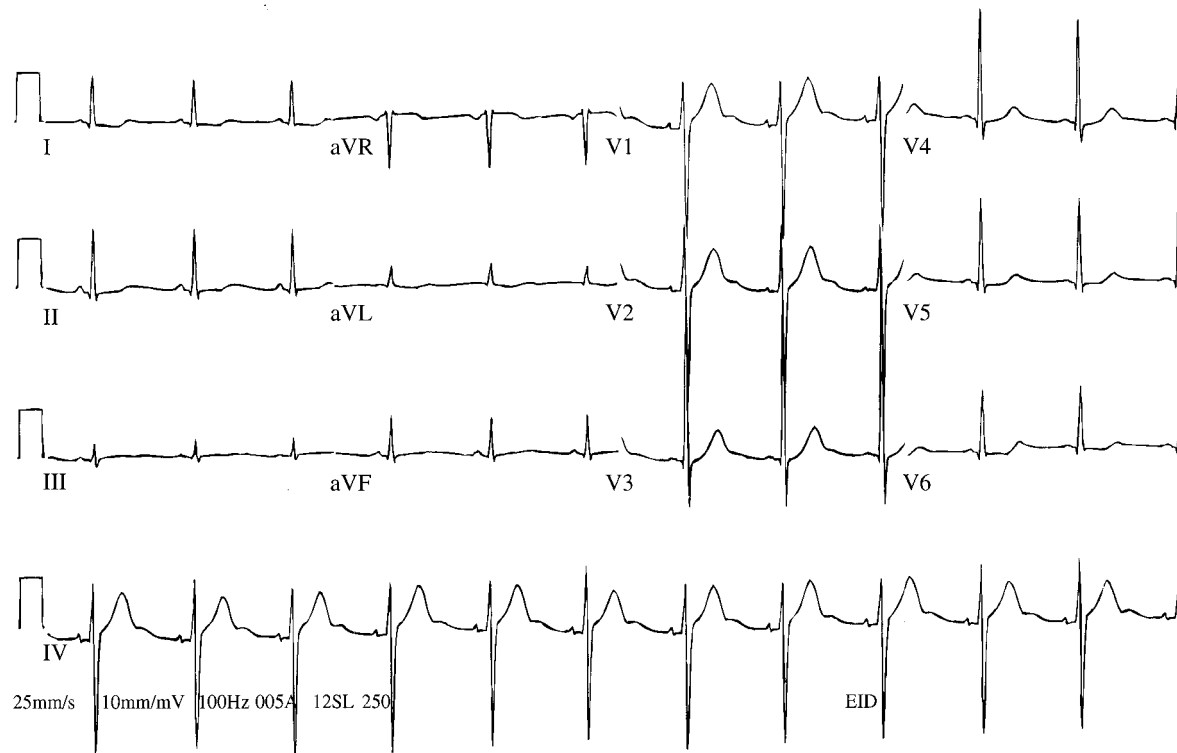


Fig. 2. Electrocardiogram showing nonspecific ST-segment changes in inferior leads (II, III, aVF).

ST-segment elevation is localized to a few leads, pericarditis can be confused with acute myocardial infarction.<sup>9,10</sup> However, ST-segment elevation observed during the acute injury stage of myocardial infarction is convex, whereas ST-segment elevation during acute pericarditis is usually concave. In addition, myocardial infarction is usually distinguished by the presence of Q waves and T-wave inversion associated with ST-segment elevation. In acute pericarditis, Q waves are absent and T-wave inversion occurs days to weeks later, after the ST segments have returned to normal.<sup>1</sup>

In the current patient, ST-segment elevation was registered predominantly in the inferolateral leads, mimicking an inferolateral wall myocardial infarction. More detailed electrocardiographic analysis in the patient showed that although the changes were regional, they were typical of pericarditis—that is, absence of Q waves, concave ST-segment elevation with reciprocal changes in aVR and V<sub>1</sub>, upright T waves, and typical PR depression. Further, myocardial infarction was ruled out by normal serum cardiac enzymes and by a two-dimensional transthoracic echocardiogram that showed no signs of regional wall motion abnormality. Although ST-segment elevation can be associated with hyperkalemia, it is unlikely in this patient because ST-segment elevation persisted after the potassium concentration decreased to the normal range and the peaked T waves returned to normal morphology.

This is a rare instance of regional pericarditis mimicking inferolateral myocardial infarction with no evidence

of an underlying myocardial infarction. Regional pericarditis has been described in several previous instances; however, these cases are somewhat different from the current case.<sup>2-5</sup>

In one case of atypical pericarditis, marked (greater than 5 mm), localized ST-segment elevation in the anterior precordial leads mimicked acute myocardial infarction.<sup>5</sup> Myocardial infarction was considered unlikely on the basis of lack of symptoms, a two-dimensional echocardiogram showing no significant localized wall motion abnormalities, and only a slight increase in the peak creatine phosphokinase MB. However, the following day, the ST-segment elevation became more generalized, and a new pericardial friction rub became audible. Further, subsequent studies ruled out acute myocardial infarction. In this case of pericarditis, the initial presentation was that of an atypical regional pericarditis.

Regional pericarditis has also been described in the post-myocardial infarction setting.<sup>2-4</sup> Further, acute abdominal disorders (*e.g.*, pancreatitis, cholecystitis, hepatitis, and peritonitis) have been reported to cause electrocardiographic patterns mimicking pericarditis. ST-segment elevation observed in patients with gastrointestinal emergencies can be difficult to distinguish from acute myocardial infarction.<sup>11</sup> Additionally, similar electrocardiographic findings are not uncommon after cardiac surgery. Finally, vasospastic angina may present with localized ST-segment changes similar to those we describe; however, they are typically accompanied with clinical symptoms (chest pain) or signs (dysrhythmias).<sup>12</sup>

In the current patient, pericarditis mimicked inferolateral wall myocardial infarction. This case shows that localized ST-segment changes in the absence of symptoms and signs of myocardial infarction can be consistent with a diagnosis of pericarditis and that a two-dimensional echocardiogram is an invaluable aid to rapid diagnosis.

## References

- Alexander RW, Schlant RC, Fuster V: The Heart. New York, McGraw-Hill, 1998, pp 2169-74
- Oliva PB, Hammill SC, Edwards WD: The electrocardiographic diagnosis of regional pericarditis in acute inferior myocardial infarction. *Eur Heart J* 1993; 14:1683-9
- Oliva PB, Hammill SC, Edwards WD: Electrocardiographic diagnosis of postinfarction regional pericarditis. *Circulation* 1993; 88:896-904

- Oliva PB, Hammill SC: The clinical distinction between regional postinfarction pericarditis and other causes of postinfarction chest pain. *Clin Cardiol* 1994; 17:471-8
- Jain A: "Tombstone" anterior ST-segment elevations secondary to acute pericarditis: The role of two-dimensional echocardiogram. *Clin Cardiol* 1997; 20:404-6
- Surawicz B, Lasserter KC: Electrocardiogram in pericarditis. *Am J Cardiol* 1970; 26:471-4
- Spodick DH: Diagnostic electrocardiographic sequences in acute pericarditis: Significance of PR segment and PR vector changes. *Circulation* 1973; 48: 575-80
- Teh BS, Walsh J, Bell AJ, Walker SJ, Kilpatrick D: Electrical current paths in acute pericarditis. *J Electrocardiol* 1993; 26:291-300
- Hancock WE: Acute myocardial infarction or pericarditis. *Hosp Pract (Off Ed)* 1992; 27:25-6
- Braunwald E: A Textbook of Cardiovascular Medicine. Philadelphia, WB Saunders, 1997, pp 1482-3
- Ryan ET, Pak PH, DeSanctis RW: Myocardial infarction mimicked by acute cholecystitis. *Ann Intern Med* 1992; 116:218-20
- Sprung J, Lesitsky MA, Jagetia A, Tucker C, Saffian M, Gottlieb A: Cardiac arrest caused by coronary spasm in two patients during recovery from epidural anesthesia. *Reg Anesth* 1996; 21:253-60

Anesthesiology 2001; 95:264-6

© 2001 American Society of Anesthesiologists, Inc. Lippincott Williams & Wilkins, Inc.

## Severe, Refractory Hypotension during Anesthesia in a Patient on Chronic Clomipramine Therapy

T. Philip Malan, Jr., Ph.D., M.D.,\* Paul E. Nolan, Jr., Pharm.D.,† Peter R. Lichtenthal, M.D.,\* J. Scott Polson, M.D.,\* Susan L. Tebich, M.D.,‡ Raj K. Bose, M.B.B.S.,§ Jack G. Copeland III, M.D.¶

HYPOTENSION is a risk when therapy with tricyclic antidepressants (TCAs) is administered.<sup>1</sup> Severe hypotension is rare with therapeutic doses of TCAs; however, severe hypotension may occur during overdose.<sup>2</sup> The risk of hypotension in patients to whom therapeutic doses of TCAs are administered and who undergo general anesthesia seems to be low. A literature search yielded only a single case report in the English language, describing significant hypotension after induction of general anesthesia in a patient undergoing TCA therapy who also had a functioning epidural in place.<sup>3</sup> A second case report, in the Spanish-language literature, described a patient to whom TCAs were administered and in whom significant hypotension developed after dosing of an epidural catheter during combined general-epidural anesthesia.<sup>4</sup> We report herein a case of vasodilation and hypotension during general anesthesia that we believe was caused by long-term clomipramine therapy. Our case differs from previous cases in that this patient underwent general anesthesia alone, without epidural blockade.

## Case Report

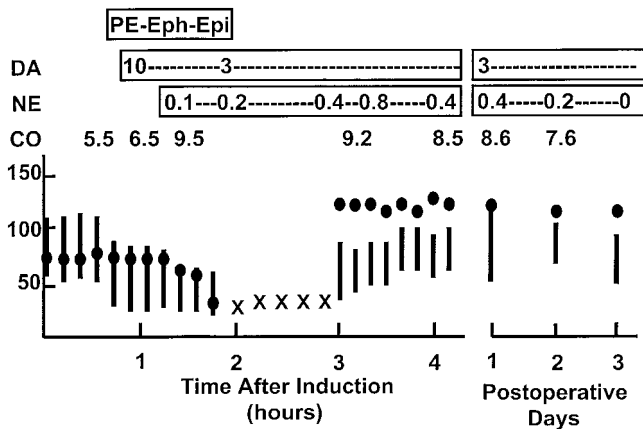
A 57-yr-old man (101 kg, 193 cm) was scheduled to undergo repair of the mitral valve. An echocardiogram revealed severe mitral regurgitation with left ventricular dilation (diastolic dimension of 6.4 cm). Cardiac catheterization revealed a left ventricular ejection fraction of 60%, cardiac output of 6.2 l/min, pulmonary artery pressure of 26/12 mmHg, and pulmonary capillary wedge pressure of 12 mmHg, with a V wave to 18 mmHg. Preoperative blood pressure was 108/70 mmHg, with a pulse of 68 beats/min. The preoperative electrocardiogram was normal. The patient's medical history included prurigo nodularis, a skin condition, on the lower extremities. He had been treated for 2 yr with clomipramine, 150 mg at bedtime, for pruritus, and he continued this treatment the night before surgery. He was also taking finasteride.

Blood pressure before induction was 105/65 mmHg, and heart rate was 70 beats/min (fig. 1). After placement of a radial artery catheter, general anesthesia was induced with sodium thiopental (250 mg) and fentanyl (250 µg). Intubation of the trachea was facilitated with succinylcholine (100 mg), and anesthesia was maintained with isoflurane. After induction, blood pressure was 105/65 mmHg, and heart rate was 75 beats/min. A pulmonary artery catheter and transesophageal echocardiography probe were inserted. Cardiac output was 5.5 l/min, pulmonary artery pressure was 35/20 mmHg, blood pressure remained at 105/65 mmHg, heart rate was 70 beats/min, and systemic vascular resistance was 1,020 dyne · s · cm<sup>-5</sup>. Forty-five minutes after induction of anesthesia, systolic blood pressure decreased to 90 mmHg, heart rate was 75 beats/min, cardiac output was 6.5 l/min, and systemic vascular resistance was 680 dyne · s · cm<sup>-5</sup>. Attempts to increase blood pressure with ephedrine (30 mg total) and phenylephrine (500 µg total) were unsuccessful. Isoflurane was decreased to 0.2% inhaled concentration. A dopamine infusion (10 µg · kg<sup>-1</sup> · min<sup>-1</sup>) was initiated without effect. After skin incision and sternotomy, systolic blood pressure decreased precipitously to 55 mmHg, and heart rate decreased from 75 to 60 beats/min. An allergic reaction was considered as the cause of hypotension, although there were no other characteristics of an allergic reaction, such as bronchospasm, flushing,

\* Associate Professor, ‡ Assistant Professor, Department of Anesthesiology, † Professor, Department of Pharmacy Practice and Science, § Assistant Professor, ¶ Professor, Division of Cardiothoracic Surgery, Department of Surgery, The University of Arizona.

Received from the Department of Anesthesiology, The University of Arizona, Tucson, Arizona. Submitted for publication September 27, 2000. Accepted for publication February 15, 2001. Support was provided solely from institutional and/or departmental sources.

Address reprint requests to Dr. Malan: Department of Anesthesiology, The University of Arizona, PO Box 245114, Tucson, Arizona 85724-5114. Address electronic mail to: malan@u.arizona.edu. Individual article reprints may be purchased through the Journal Web site, www.anesthesiology.org.



**Fig. 1.** Selected hemodynamic parameters and treatment with cardiovascular drugs. PE = phenylephrine (see text for doses); Eph = ephedrine (see text for doses); Epi = epinephrine (see text for doses); DA = dopamine ( $\mu\text{g} \cdot \text{kg}^{-1} \cdot \text{min}^{-1}$ ); NE = norepinephrine ( $\mu\text{g} \cdot \text{kg}^{-1} \cdot \text{min}^{-1}$ ); CO = cardiac output.

or rash. Multiple boluses of ephedrine (100 mg total), phenylephrine (5 mg total), and epinephrine (1.5 mg total) were administered without significant effects on blood pressure or heart rate. Approximately 4 l crystalloid solution was administered during this period. Cardiac output was noted to be 9.5 l/min, and systemic vascular resistance was 310  $\text{dyne} \cdot \text{s} \cdot \text{cm}^{-5}$ . Heart rate remained at 60 mmHg, and pulmonary artery pressure remained at 35/20 mmHg. Transesophageal echocardiography revealed a hyperdynamic left ventricle with good filling during diastole. A norepinephrine infusion ( $0.1 \mu\text{g} \cdot \text{kg}^{-1} \cdot \text{min}^{-1}$ ) was begun with minimal effect on blood pressure or heart rate. Suddenly, third-degree atrioventricular block developed in the patient. At this sign of potential myocardial ischemia, cardiopulmonary bypass was begun.

The mitral valve was repaired. During cardiopulmonary bypass, norepinephrine infusion was continued ( $0.2 \mu\text{g} \cdot \text{kg}^{-1} \cdot \text{min}^{-1}$ ) to maintain mean arterial pressure at 30 mmHg. Fentanyl (2 mg) and midazolam (5 mg) were administered, and isoflurane was discontinued. A high-dose opioid-based anesthetic regimen was selected at this point to minimize myocardial depression. No change in blood pressure was noted with these changes in anesthetic management. Before termination of cardiopulmonary bypass, norepinephrine was increased to  $0.4 \mu\text{g} \cdot \text{kg}^{-1} \cdot \text{min}^{-1}$ , and the patient was successfully weaned from bypass. After bypass, norepinephrine was maintained between 0.2 and  $0.8 \mu\text{g} \cdot \text{kg}^{-1} \cdot \text{min}^{-1}$ , resulting in a systolic blood pressure of 90–100 mmHg, a heart rate of 115, a cardiac output of 9.2 l/min, and a systemic vascular resistance of 540  $\text{dyne} \cdot \text{s} \cdot \text{cm}^{-5}$ . Surgery was completed, and the patient was transferred to the intensive care unit.

The trachea was extubated the following morning. Further history revealed that before surgery, the patient had experienced noticeable dizziness when standing, which had been attributed by his primary care physician to clomipramine. This, together with a relatively low preoperative blood pressure, led to the presumptive diagnosis of TCA-induced hypotension precipitated by anesthesia. Clomipramine was withheld, and the patient was gradually weaned from norepinephrine. Norepinephrine was discontinued on the third postoperative day. During the first three postoperative days, the patient displayed significant postural hypotension.

**Discussion**

Significant hypotension is common in TCA overdose. Although it is rare when TCAs are taken in routine doses, it has been reported at therapeutic serum concentra-

tions.<sup>5</sup> TCAs have  $\alpha$  adrenoreceptor-blocking properties.<sup>6</sup> Clomipramine, the drug used in this case, binds to and blocks  $\alpha_1$  receptors.<sup>7</sup> Although clomipramine also functions as an  $\alpha_2$ -receptor antagonist,<sup>7</sup> a role for  $\alpha_2$ -receptor activation in clomipramine-induced hypotension was suggested by the finding that yohimbine, an  $\alpha_2$ -receptor-selective antagonist, increased blood pressure in patients with depression and clomipramine-induced orthostatic hypotension.<sup>8</sup> Chronic TCA administration may also lead to hypotension by blocking norepinephrine reuptake into presynaptic nerve terminals. Desmethylclomipramine, the principal metabolite of clomipramine, blocks norepinephrine and serotonin reuptake.<sup>9</sup> This may lead to depleted catecholamine reserves in nerve terminals, thereby limiting compensatory hemodynamic responses. In addition, chronic exposure of postsynaptic adrenergic receptors to the high concentrations of norepinephrine produced by reuptake inhibition may cause down-regulation of these receptors, leading to decreased responsiveness to catecholamines.<sup>10</sup>

These pharmacologic actions of clomipramine may have led to the features observed in this case. Myocardial depression and vasodilation produced by the general anesthetic agents may have led to compensatory activation of the sympathetic nervous system. When the depleted catecholamine reserves of the sympathetic terminals were exhausted, hypotension may have ensued. The lack of responsiveness of blood pressure to normally effective doses of phenylephrine and epinephrine may have resulted from adrenergic receptor down-regulation and from blockade of the  $\alpha$  adrenoreceptor by clomipramine. The lack of significant responses of heart rate to epinephrine may have been because of  $\beta$ -adrenergic-receptor down-regulation.

This patient's hypotension was ultimately treated with high doses of norepinephrine. Other treatments, standard in TCA overdose, were not used because the diagnosis of TCA toxicity was not immediately apparent. In this case, cardiopulmonary bypass was a planned event, although early initiation of bypass was precipitated by third-degree atrioventricular block. When cardiopulmonary bypass had been started, it was decided that there was no advantage to be gained by aborting the surgery.

Of note in this case was the lack of dysrhythmias or conduction abnormalities until the patient had significant hypotension. The third-degree atrioventricular block experienced by this patient seemed to be related in part to hypotension because it transiently resolved during an increase in blood pressure. Conduction abnormalities are a key feature of many cases of TCA toxicity,<sup>11</sup> and were observed after dosing of the epidural catheter in the patient described by Sprung *et al.*<sup>4</sup>

Finasteride, the other long-term medication used by this patient, encourages hair growth by inhibiting type II 5- $\alpha$  reductase, thereby blocking the conversion of tes-

tosterone to 5- $\alpha$  testosterone.<sup>12</sup> It is not associated with hypotension.

Long-term TCA use seems to be an infrequent and perhaps underrecognized cause of hypotension during anesthesia. We hypothesize that preoperative postural hypotension may be a risk factor for TCA-related hypotension during anesthesia. It was present in the current patient and in the patient described by Sprung *et al.*<sup>4</sup>

## References

1. Glassman AH: Cardiovascular effects of antidepressant drugs: Updated. *Int Clin Psychopharmacol* 1998; 13:S25-30
2. Newton EH, Shih RD, Hoffman RS: Cyclic antidepressant overdose: a review of current management strategies. *Am J Emerg Med* 1994; 12:376-9
3. Sprung J, Schoenwald PK, Levy P, Krajewski LP: Treating intraoperative hypotension in a patient on long-term tricyclic antidepressants: A case of aborted aortic surgery. *ANESTHESIOLOGY* 1997; 86:990-2

4. Boada S, Solsona B, Papaceit J, Rull M: Hipotensión por bloqueo simpático refractaria a efedrina en una paciente en tratamiento crónico con antidepressivos tricíclicos. *Rev Esp Anestesiología Reanim* 1999; 46:364-6
5. Shannon M, Liebelt EL: Toxicology reviews: Targeted management strategies for cardiovascular toxicity from tricyclic antidepressant overdose: The pivotal role for alkalization and sodium loading. *Ped Emerg Care* 1999; 14:293-8
6. Auguet M, Clostre F, DeFeudis FV: Effects of antidepressants on receptor-activated and Ca<sup>2+</sup>-activated contractions of rabbit isolated aorta. *Gen Pharmacol* 1986; 17:607-10
7. Hall H, Ogren SO: Effects of antidepressant drugs on different receptors in the brain. *Eur J Pharmacol* 1981; 70:393-407
8. Lacomblez L, Bensimon G, Isnard F, Diquet B, Lecrubier Y, Puech AJ: Effect of yohimbine on blood pressure in patients with depression and orthostatic hypotension. *Clin Pharmacol Ther* 1989; 45:241-51
9. Hyttel J: Serotonin uptake inhibitors. Serotonin: From Cell Biology to Pharmacology and Therapeutics. Edited by Vanhoutte PM, Paoletti R, Brunello N, Maggi FM, Norwell, MA, Kluwer Academic Publishers, 1989, pp 459-64
10. Banerjee SP, Kung LS, Riggi SJ, Chanda SK: Development of beta-adrenergic receptor subsensitivity by antidepressants. *Nature* 1977; 268:455-6
11. Shannon M, Merola J, Lovejoy FH: Hypotension in severe tricyclic antidepressant overdose. *Am J Emerg Med* 1988; 6:439-42
12. Steiner JF: Clinical pharmacokinetics and pharmacodynamics of finasteride. *Clin Pharmacokinetics* 1996; 30:16-27

Anesthesiology 2001; 95:266-8

© 2001 American Society of Anesthesiologists, Inc. Lippincott Williams & Wilkins, Inc.

## Spinal Anesthesia at the Cervicothoracic Level

Roupen Hatzakorzian, M.D.,\* Ross Robbins, M.D.,† Gilles Plourde, M.D., M.Sc.†

WE report a case in which spinal anesthesia at the cervico-thoracic level (C7-T1 intervertebral space) was performed successfully for a urologic procedure in a patient with muscular dystrophy and thoracolumbar kyphoscoliosis.

### Case Report

A 59-yr-old bed-ridden man with advanced Becker muscular dystrophy<sup>1</sup> and severe thoracolumbar scoliosis was scheduled to undergo urgent laser lithotripsy of right renal pelvic and bladder stones. The patient had been admitted to the hospital 15 days previously for an upper urinary tract infection, which was treated with ampicillin and gentamycin. His left kidney had been nonfunctional for several years secondary to postrenal obstruction.

The patient had several general anesthetics in the past, often complicated by postoperative pneumonia requiring tracheal intubation and mechanical ventilation. Intubation of the trachea had required many attempts and had been performed either blindly *via* the nose or *via* the mouth with direct laryngoscopy, which revealed a very limited view of the larynx. Ventilation with face mask had been satisfactory.

Lumbar spinal anesthesia had been used for previous urologic procedures but did not provide adequate analgesia, probably because the spinal deformity interfered with the distribution of the local anesthetic. On another occasion, epidural anesthesia had been attempted but abandoned after multiple attempts.

The patient's history included congenital cardiomyopathy and coronary artery disease with previous myocardial infarction. Home medication included 0.125 mg digoxin daily, 50 mg triamterene daily, 12.5 mg captopril twice daily, 40 mg furosemide daily, 20 mg lovastatin daily, sublingual nitroglycerin as required, and 1 mg lorazepam daily at bedtime.

The patient was alert and cooperative. His height and weight were 135 cm and 40 kg, respectively. Blood pressure was 100/60 mmHg, heart rate was 75 beats/min, respiratory rate was 14 breaths/min, and oral temperature was 38.0°C. The patient was unable to move any part of his body below the neck. He had a Mallampati class 4 airway<sup>2</sup> with an 8-mm opening of the mouth and normal teeth. Extension of the neck was normal. Examination of the thorax revealed a severe right convex kyphoscoliosis and reduced breath sounds bilaterally.

Arterial blood gas testing with room air showed a pH of 7.43, an arterial carbon dioxide tension (Paco<sub>2</sub>) of 36 mmHg, and an arterial oxygen tension (PaO<sub>2</sub>) of 82 mmHg. The coagulogram and platelet count were normal. Forced expiratory volume in 1 s and forced vital capacity were 1.00 and 1.25 l, respectively (both 35% of predicted value). The chest radiogram (fig. 1) revealed a severe thoracolumbar scoliosis with normal lung parenchyma.

The patient did not want to have general anesthesia because of his experience with multiple postoperative pneumonias. He fully appreciated the seriousness of his physical condition and coherently expressed his concerns about the distress resulting from prolonged mechanical ventilation.

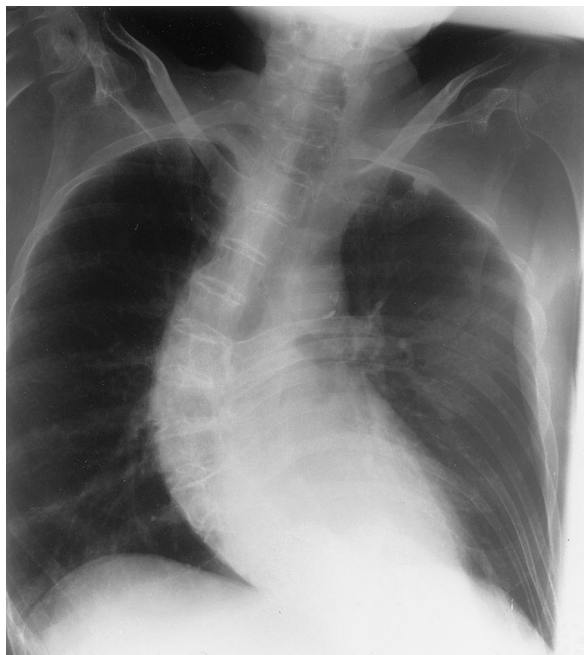
We proposed spinal anesthesia at the cervico-thoracic level. We told the patient that there were two particularly serious risks. The first was trauma to the spinal cord from the needle with the possibility of permanent paralysis or of loss of feeling or both in one or more limbs. The possibility of severe chronic pain syndrome was also discussed. The second major risk was the development of total spinal anesthesia, which would require ventilatory support in exactly the same way as general anesthesia. This complication could also necessitate major drug support of heart function and blood circulation to prevent cardiac arrest. The patient understood and accepted the risks.

After placement of the electrocardiographic leads, pulse oximeter, and noninvasive blood pressure cuff, a right internal jugular catheter was inserted during local anesthesia. Oxygen was administered by face mask. The difficult airway cart and fiberoptic bronchoscope were brought into the room. While the patient was held sitting, an 18-gauge

\* Resident, † Associate Professor and Attending Staff.

Received from the Departments of Anesthesia, McGill University, Montreal, Quebec, Canada, and Royal Victoria Hospital, Montreal, Quebec, Canada. Submitted for publication October 9, 2000. Accepted for publication February 15, 2001. Dr. Plourde holds a scholarship from the Fonds de la Recherche en Santé du Québec, Montreal, Quebec, Canada.

Address reprint requests to Dr. Plourde: Royal Victoria Hospital, Department of Anesthesia, 687 Pine Avenue West, Room S5.05, Montreal, Quebec, Canada H3A 1A1. Address electronic mail to: gilles.plourde@staff.mcgill.ca. Individual article reprints may be purchased through the Journal Web site, www.anesthesiology.org.



**Fig. 1.** Chest radiograph showing severe thoracolumbar scoliosis with normal lung parenchyma.

needle introducer was inserted in aseptic conditions at the C7-T1 spinal interspace (technically the most appealing space). A 27-gauge Quincke-Babcock spinal needle was placed in the introducer and advanced into ligamentous tissue. After removing the stylet obturator, the Quincke-Babcock needle was advanced slowly until cerebrospinal fluid appeared. The patient reported no paresthesia. Hyperbaric bupivacaine (0.75%; 15 mg) was injected in the subarachnoid space in 3 min. At the end of the injection, systolic blood pressure decreased from a baseline of 100 to 60 mmHg. Infusion of epinephrine was started, and systolic blood pressure returned to 90-100 mmHg. The patient was kept sitting for 10 min before being placed in the lithotomy position. The level of sensory block assessed with pin-prick test was C5 on the left side and T4 on the right. Heart rate remained between 60 and 80 beats/min.

The patient occasionally reported pain. His statements were sometimes vague ("My back hurts. Could you move me a little?"), sometimes specific to the site of surgery. If position adjustment failed to relieve the pain or if the discomfort was at the surgical site, we gave small (25-50  $\mu$ g) boluses of fentanyl (total dose of 350  $\mu$ g over 2 h 45 min). Systolic blood pressure was maintained between 90-110 mmHg by titration of the epinephrine drip. Oxygen saturation remained greater than 98%. The epinephrine drip was tapered down and discontinued at the end of surgery. The patient was transferred to the surgical ward the next day after an overnight stay in the surgical intensive care unit.

Five days later, the patient came back for right percutaneous nephrolithotomy and removal of the double-J tube. Spinal anesthesia at the C7-T1 level was performed as described. However, the dose of hyperbaric bupivacaine was increased to 22.5 mg to establish a more complete block. Epinephrine infusion was started just before spinal injection to prevent arterial hypotension. The level of sensory block was T4 on both sides. Systolic blood pressure was maintained at 90-100 mmHg, and oxygen saturation was maintained above 98%. Fentanyl (two 50- $\mu$ g boluses) was administered to relieve occasional pain. Propofol (80 mg in 10-mg boluses) was administered for sedation. The procedure lasted 2.5 h. After spending a night in the surgical intensive care unit, the patient was transferred to the surgical ward. The patient went home 4 days later. He subsequently expressed his gratitude for the quality of intraoperative analgesia.

## Discussion

Although spinal anesthesia at the cervico-thoracic level is, and must remain, an exceptional procedure, we felt that it was a suitable option for this patient. The surgical procedure required general or neuraxial anesthesia. There were two reasons against choosing general anesthesia: patient refusal and likelihood of postoperative pneumonia. Lumbar spinal anesthesia would likely not have provided sufficient analgesia, based on past experience. The spinal deformity made placement of an epidural needle in the lumbar or mid-thoracic area very difficult or impossible. Even with successful placement of the epidural catheter, the spinal deformity would have likely interfered with the spread of the anesthetic solution. A high thoracic (T1 or T2) epidural would have been easy to perform but would probably not have provided adequate anesthesia because of the distance from the dermatomal level of surgical stimulation. Abnormal spreading of the anesthetic solution also remained a concern. Furthermore, the large volume of local anesthetic required with a high thoracic epidural could have produced an unacceptably high block.

Although this patient had favorable course, this procedure involves serious risks and must not be viewed with complacency. Damage to the spinal cord from the needle could have led to severe, permanent sequelae. The neuroradiologic literature<sup>3,4</sup> nevertheless provides some reassurance. The experience with intentional puncture of the cervical or thoracic cord for diagnosis or treatment of cystic lesions shows that the appearance of cerebrospinal fluid reliably precedes contact with the cord. Furthermore, paresthesia usually occurs when the needle passes between the posterior columns. We therefore expected that free flow of cerebrospinal fluid would indicate correct needle placement and that paresthesia would reveal accidental contact with the spinal cord. To facilitate immediate detection of cerebrospinal fluid, we advanced the Quincke-Babcock needle through the interspinous ligament without the obturator stylet. We believed that this would give an earlier and safer indication of reaching the intrathecal space than would stepwise advances with intermittent obturator removal.

The risk of total spinal anesthesia was also a serious concern, mainly because of the requirement for mechanical ventilation. We judged that this risk was acceptable despite anticipated difficulties with endotracheal intubation because we were sure that adequate ventilation could be achieved with a face mask or with a laryngeal mask airway.

Total spinal anesthesia did not develop, but we nevertheless observed a rapid onset of severe arterial hypotension, which was easily corrected with infusion of epinephrine. Hypotension likely resulted from the combination of the sitting position and almost immediate thoracic and lumbar sympathectomy. There was no bra-

dyscardia although the cardioaccelerator fibers (T1-T4) were probably affected.

Spinal anesthesia at the thoracic or cervical level may offer a solution under exceptional circumstances when general anesthesia or conventional regional techniques are contraindicated or impossible to perform. The patient should be fully informed of the risks and of the exceptional nature of this procedure. There must be no doubt about the ability to achieve adequate ventilation of the lungs in the event of total spinal anesthesia. A hyperbaric solution of local anesthetic should be used. The patient should be left sitting for at least 10 min to avoid total spinal anesthesia and to establish an adequate block. An

infusion of epinephrine should be immediately available to treat arterial hypotension, bradycardia, or both.

## References

1. Emery AE: The muscular dystrophies (review). *Br Med J* 1998; 23:357-62
2. Mallampati SR, Gatt SP, Gugino LD, Desai SP, Waraksa B, Freiberg D, Liu P: A clinical sign to predict difficult tracheal intubation: a prospective study. *Can Anaesth Soc J* 1985; 32:429-34
3. Tampieri D, Melanson D, Ethier R: Spinal cord puncture: Diagnostic and therapeutic aspects, *Imaging of Brain Metabolism: Spine and Cord Interventional Neuroradiology*. Edited by Nadjmi M. New York, Springer-Verlag, 1989, pp 197-200
4. Quencer RM: Needle aspiration of intramedullary and intradural extramedullary masses of the spinal cord. *Radiology* 1980; 134:115-126

Anesthesiology 2001; 95:268-70

© 2001 American Society of Anesthesiologists, Inc. Lippincott Williams & Wilkins, Inc.

## Perioperative Temperature Changes in a Patient with Shapiro Syndrome

Andrew J. Owen, M.D.,\* Steven B. Backman, M.D.C.M., Ph.D., F.R.C.P.C.†

*SHAPIRO syndrome*, first described in 1969,<sup>1</sup> is an extremely rare condition consisting of the clinical triad of recurrent hypothermia, sweating, and chills in the presence of agenesis of the corpus callosum. The periodicity of the hypothermic episodes ranges from hours to years, and episodes may last hours to weeks.<sup>2</sup> Typically, but not invariably, there are associated central nervous system abnormalities affecting structures, particularly in the hypothalamus, that are related to thermoregulation.<sup>2</sup> Although the effect of anesthesia and surgery on thermoregulation are well-known,<sup>3</sup> such an effect has never been described in patients with Shapiro syndrome. In this report, we describe the clinical course and perioperative temperature changes of a patient with Shapiro syndrome who underwent elective cholecystectomy. The temperature changes in a group of normal patients undergoing the same procedure are compared.

### Case Report

A 49-yr-old man presented for elective laparoscopic cholecystectomy for treatment of cholelithiasis. He was diagnosed with Shapiro syndrome approximately 11 yr previously when he experienced attacks of flushing and profuse, drenching diaphoresis that were sometimes followed by the sensation of cold and shivering. The patient was

treated with phenobarbital, and, over several weeks, the attacks diminished in frequency and finally stopped.

The attacks resumed, without any obvious precipitating event, 13 months before scheduled cholecystectomy and continued for 8 months. The episodes occurred 10-20 times per day and lasted 20-120 min. During the initial phase of the attacks, examination revealed profuse sweating and vasodilatation. Later, the skin was cold to touch and body temperature was as low as 31°C. Rigidity in the extremities was noted, although this may have been secondary to shivering. In addition, he seemed to be inattentive. Blood analysis indicated a normal complete blood count and blood chemistry. Cortisol (AM), thyroid stimulating hormone, free T<sub>4</sub>, and prolactin concentrations were normal. Imaging studies revealed agenesis of the corpus callosum. Electroencephalographic recording during an attack indicated generalized disturbances compatible with cortical and subcortical grey matter dysfunction but no epileptiform activity. Autonomic testing demonstrated minimal heart rate changes during deep breathing or tilting, although blood pressure changes were within the normal range during the latter maneuver. A variety of medications (phenobarbital, procyclidine, carbidopa-levodopa, clonidine, carbamazepine, divalproex, and chlorpromazine) were tried without any obvious benefit. As with the first series of attacks, they gradually diminished in frequency and then stopped.

At the time of surgery, the patient had not experienced hypothermic episodes for 5 months and was not taking any medication. General anesthesia was induced with 2 mg midazolam, 200 mg propofol, and 150 µg fentanyl, and muscle paralysis was achieved with 50 mg rocuronium. Anesthesia was maintained with desflurane (3.2-6.0%) in an O<sub>2</sub>-N<sub>2</sub>O (40%:60%) mixture, and fentanyl was administered in 50-µg bolus doses as needed (total 250 µg). Cefazolin, 1 g, was administered shortly after induction, and muscle paralysis was reversed at the end of surgery with 2.5 mg neostigmine and 0.6 mg glycopyrrolate. Monitoring consisted of electrocardiography (leads II and V), pulse oximetry, capnography, and a nerve stimulator. Oral temperature was recorded before induction and in the postanesthesia care unit using an IVAC TEMP.PLUS II thermometer (San Diego, CA). Ambient operating room and nasopharyngeal temperatures were recorded using a Datex-Engstrom AS/3 anesthesia monitor and temperature probe (Helsinki, Finland). Invasive systemic arterial pressure was recorded *via* a catheter inserted into a radial artery. Routine thermal care was used, which consisted of standard surgical draping. Intravenous fluid

\* Resident, Department Anesthesia, McGill University. † Associate Professor, Faculty of Medicine, McGill University, and Director, Department of Anesthesia, Royal Victoria Hospital.

Received from the Department of Anesthesia, McGill University, Montreal, Quebec, Canada, and the Department of Anesthesia, Royal Victoria Hospital, Montreal, Quebec, Canada. Submitted for publication September 5, 2000. Accepted for publication February 16, 2001. Support was provided solely from departmental sources.

Address reprint requests to Dr. Backman: Department of Anesthesia, Royal Victoria Hospital, 687 Pine Avenue West, Montreal, Quebec, Canada H3A 1A1. Address electronic mail to: mdb@musica.mcgill.ca. Individual article reprints may be purchased through the Journal Web site, www.anesthesiology.org.

(normal saline) was not heated. After induction, intravenous fluid was administered throughout the procedure at a maintenance rate ( $4 \text{ ml} \cdot \text{kg}^{-1} \cdot \text{h}^{-1}$  [first 10 kg] +  $2 \text{ ml} \cdot \text{kg}^{-1} \cdot \text{h}^{-1}$  [second 10 kg] +  $1 \text{ ml} \cdot \text{kg}^{-1} \cdot \text{h}^{-1}$  [remainder] =  $136 \text{ ml} \cdot \text{kg}^{-1} \cdot \text{h}^{-1}$ ) via a catheter inserted into an upper extremity.

In a subsequent series of 10 control patients undergoing elective laparoscopic cholecystectomy, the perioperative temperature changes were recorded for comparison. These patients were anesthetized using the same drugs and received identical thermal care.

The patient with Shapiro syndrome had an uneventful perioperative course. Blood pressure and heart rate were within limits normally observed. The ambient operating room temperature was  $22^\circ\text{C}$ . The nasopharyngeal temperature decreased rapidly from a baseline of  $37.2^\circ\text{C}$  during the first 10 min and then gradually decreased to a plateau of  $36.0^\circ\text{C}$  at 40 min (fig. 1A) during the operation. For the controls, the ambient operating room temperature was  $21.6^\circ\text{C} \pm 1.3$  (mean  $\pm$  SD,  $n = 10$ ). They demonstrated a similar rapid initial decrease in temperature, from a baseline of  $36.7 \pm 0.3$  to  $36.4 \pm 0.7^\circ\text{C}$  in the first 10 min, and their temperatures continued to decrease throughout the procedure (fig. 1A). In the postanesthesia care unit, the temperature of the Shapiro syndrome patient gradually increased and reached baseline by 50 min (fig. 1B). The temperature of the controls also increased gradually in the postanesthesia care unit but remained lower at any given time period compared with that of the Shapiro syndrome patient and did not return to baseline by 60 min (time of discharge). The Shapiro syndrome patient had an uneventful postoperative course and did not experience subsequent hypothermic episodes.

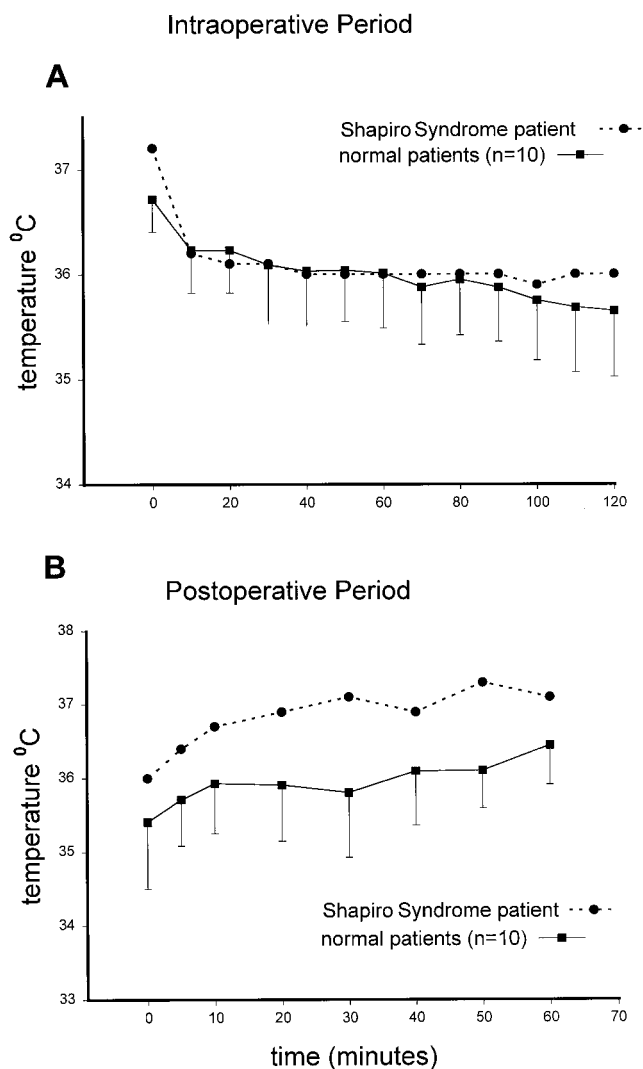
## Discussion

Shapiro syndrome, or spontaneous periodic hypothermia, is an extremely rare neurologic disorder with previously unreported anesthetic considerations. We present the case of a patient with this disorder in whom abnormal thermoregulatory responses were not observed during anesthesia and surgery.

Reduction in temperature observed during anesthesia and surgery is common and is attributed to increased heat loss (radiation, convection, evaporation, and conduction) and altered thermoregulation. Volatile and intravenous anesthetic drugs reduce, in a dose-dependent manner, the threshold temperature that triggers heat-conserving mechanisms, such as vasoconstriction and shivering.<sup>3</sup> This results in a predictable pattern of change in core temperature.

It is thought that the fluctuating body temperature observed in Shapiro syndrome is produced by an altered balance between the anterior hypothalamic heat-dissipating and the posterior hypothalamic heat-conserving centers.<sup>2</sup> This results in an abnormal lower core temperature set point; the thermoregulatory mechanisms that defend this new set point still function normally, with an intact autonomic nervous system controlling the temperature-regulating effectors. The underlying cause for this altered balance is unknown. Suggested mechanisms include central nervous system structural abnormalities, degenerative processes, neurochemical dysfunction, inflammatory processes, and seizure activity.<sup>2</sup>

With the Shapiro syndrome patient described in this report, there were no signs of disturbed thermoregulation



**Fig. 1.** Temperature (ordinate) as a function of time (abscissa) is plotted during the intraoperative (A) and postoperative (B) periods. Data were obtained from a patient with Shapiro syndrome (filled circles) and from normal patients (filled squares) undergoing laparoscopic cholecystectomy. The temperature recorded at time zero during the intraoperative period (A) was obtained just before induction, whereas that recorded during the postoperative period (B) was obtained immediately after arrival in the postanesthesia care unit. Error bars indicate SDs.

tion during the preoperative period, and temperature fluctuations were similar to those observed in the controls. Importantly, anesthesia did not trigger a hypothermic episode typical of Shapiro syndrome. This is consistent with the notion that anesthetics do not alter the hypothalamic temperature set point but instead change thermoregulatory threshold values, whereas hypothermia in Shapiro syndrome is a result of an abnormal set point.

It is interesting to consider the approach one should take had this patient experienced hypothermic attacks at the time of surgery. Perioperative hypothermia, even when mild, may be associated with adverse effects.

These include impaired wound healing, increased surgical blood loss, cardiac arrhythmia and ischemia, shivering, discomfort, and decreased drug metabolism.<sup>3</sup> For elective surgery, delaying the case until the patient is symptom-free seems prudent. In the event of emergency surgery during a symptomatic period, profound hypothermia should be treated appropriately to avoid its adverse effects. Because of the abnormally low thermoregulatory set point, active rewarming could be hindered by the patient's normally functioning heat dissipating mechanisms, and a temperature value closer to the lowered set point may have to be accepted. However, because anesthetics inhibit thermoregulatory control, the ability to defend the lowered set point may be reduced. Hypothermia should be avoided in patients with Shapiro syndrome who are symptom-free, as in any other type of patient. Evidence from one patient with this disorder suggests that changes in body temperature *per se* do not act as a trigger.<sup>4</sup> Obviously, with this type of patient, it is important that temperature is recorded during the perioperative period and that appropriate equipment is available for active rewarming.

Abnormal cardioregulatory responses have been reported with patients experiencing episodic hypothermia.

These include paroxysmal hypertension,<sup>2</sup> hypotension,<sup>4</sup> bradycardia,<sup>5,6</sup> tachycardia<sup>4</sup> and electrocardiographic abnormalities.<sup>1</sup> Conceivably, the marked increase in peripheral blood flow and diaphoresis associated with the hypothermic attacks could contribute to a reduction in central volume. Therefore, consideration should be given to invasive monitoring.

In summary, we describe an uneventful anesthetic procedure for a patient with Shapiro syndrome undergoing cholecystectomy. The anesthetic agents described in this report were not observed to precipitate a profound hypothermic episode.

## References

1. Shapiro WR, Williams GH, Plum F: Spontaneous recurrent hypothermia accompanying agenesis of the corpus callosum. *Brain* 1969; 92:423-36
2. Kloos RT: Spontaneous periodic hypothermia. *Medicine* 1995; 74:268-80
3. Sessler DI: Temperature monitoring. *Anesthesia*, 5th edition. Edited by Miller RD. Philadelphia, Churchill Livingstone, 2000, pp 1367-89
4. Fox RH, Wilkins DC, Bell JA, Bradley RD, Browse NL, Cranston WI, Foley TH, Gilby ED, Hebden A, Jenkins BS, Rawlins MD: Spontaneous periodic hypothermia: Diencephalic epilepsy. *Br Med J* 1973; 2:693-5
5. LeWitt PA, Newman RP, Greenberg HS, Rocher LL, Calne DB, Ehrenkranz JRL: Episodic hyperhidrosis, hypothermia, and agenesis of corpus callosum. *Neurology* 1983; 33:1122-9
6. Thomas DJ, Green ID: Periodic hypothermia. *Br Med J* 1973; 2:696-7