

## Severe Bronchospasm and Desaturation in a Child Associated with Rapacuronium

Steven S. Kron, M.D.\*

THE use of rapacuronium has been associated with occasional episodes of self-limited increased airway pressure with or without mild oxygen (O<sub>2</sub>) desaturation and wheezing. To our knowledge, this is the first report of severe bronchospasm associated with a transient inability to ventilate and marked O<sub>2</sub> desaturation after its administration.

### Case Report

The patient was a 10-yr-old girl who was brought to the operating room to undergo appendectomy. Except for 1 week of abdominal pain and mild nausea but no vomiting, her history was negative. There were no previous anesthetics, environmental or drug allergies, recent upper respiratory infection, or reactive airway disease. No one in her household smoked. She weighed 62 kg and was 138 cm tall. Except for findings related to her surgical problem, her physical examination was unremarkable, and her chest was clear.

While the patient was preoxygenated for 3 min using a 6-l/min flow of O<sub>2</sub>, the usual monitors were applied. Then, 1 mg midazolam and 50 µg fentanyl were administered intravenously. After an additional 2 min of oxygen administration, a rapid sequence induction was performed with 150 mg propofol, immediately followed by 100 mg intravenous rapacuronium (approximately 1.6 mg/kg). After 30 s, O<sub>2</sub> saturation was noted to decrease from 100% to approximately 95%. We elected to administer ventilation by mask for an additional 45 s with 100% O<sub>2</sub> while applying cricoid pressure. Her chest rose, but O<sub>2</sub> saturation improved only slightly to 96%. A cuffed No. 6.5 endotracheal tube was placed in her trachea with apparent ease, followed by an immediate attempt at manual ventilation. Despite ventilating pressures of up to 30 cm H<sub>2</sub>O, breath sounds, chest movement, endotracheal tube fogging, end-tidal carbon dioxide, or gastric sounds could not be detected. The anesthesia circuit was rechecked quickly and was observed to be patent. While maintaining cricoid pressure, the endotracheal tube was removed and noted to be unobstructed, and an attempt was made at bag and mask ventilation. Unlike with the preintubation mask ventilation, this time, there were no chest movements, breath sounds, or end-tidal carbon dioxide. The patient was reintubated easily, but ventilation remained impossible. Approximately 2 min had

elapsed since her initial intubation. At this point, she also was noted to have truncal erythema and an O<sub>2</sub> saturation of 70%. She was given four doses of 100 µg albuterol aerosol *via* the endotracheal tube, and ventilation was attempted again with 8% sevoflurane in O<sub>2</sub>. During the next minute, it became possible to ventilate with small tidal volumes and ventilating pressures between 20 and 30 cm H<sub>2</sub>O. O<sub>2</sub> saturations began to increase, and wheezing breath sounds could now be heard. A treatment of 2.5 mg nebulized albuterol was administered *via* the endotracheal tube, and 50 mg benadryl was administered intravenously. During the ensuing 5 min, manual ventilation became progressively easier with tidal volumes increasing to 350–450 ml at pressures of 15–20 cm H<sub>2</sub>O. The patient's O<sub>2</sub> saturation increased to 100%, breath sounds returned to normal, and the erythema dissipated. During this event, her blood pressure had ranged between 90/60 and 110/50 mmHg, and her pulse had ranged between 90 and 115 beats/min. Anesthesia was continued with 2–4% sevoflurane, 2 l/min O<sub>2</sub>, and 2 l/min N<sub>2</sub>O. Rocuronium, 10 mg, was required to assist with relaxation. Surgery proceeded uneventfully with the removal of an inflamed retrocecal appendix. Muscle relaxation was reversed with 1 mg neostigmine and 0.2 mg glycopyrrolate. With the patient spontaneously breathing, volumes of 250–400 ml at a respiratory rate of 20 breaths/min, and an equal train-of-four, nitrous oxide was discontinued. We elected to extubate the patient deeply, so after 5 min of 4% sevoflurane in O<sub>2</sub>, the stomach and oropharynx were thoroughly suctioned, and the endotracheal tube was removed. She continued to breathe 100% O<sub>2</sub> spontaneously, awoke, and was transferred to the postanesthesia care unit, where her O<sub>2</sub> saturation with room air was 99–100% and her chest was clear. Chest radiography results were negative. She was transferred to the pediatric unit and was discharged on the second postoperative day.

### Discussion

This patient had no factors predisposing her to a reactive airway. Of the anesthetics used for induction, midazolam, fentanyl, and propofol usually are not associated with bronchospasm. Increased airway pressure with or without wheezing and O<sub>2</sub> desaturation has been reported in clinical studies of rapacuronium. The manufacturer's package insert reports an incidence of 3.2%, with no data about the severity. Kahwaji *et al.*<sup>1</sup> reported bronchospasm and erythema that developed in an American Society of Anesthesiologists class I patient 30 s after 2 mg/kg rapacuronium and gradually subsided after salbutamol. Mild wheezing developed in a second patient after a dose of 1 mg/kg. These authors suggest that histamine release is responsible. Fleming *et al.*<sup>2</sup> studied 336 patients; half were intubated with 1 mg/kg succinylcholine, and half were intubated with 1.5 mg/kg rapacuronium. Bronchospasm, defined as wheezing, occurred in five of the rapacuronium patients, as opposed to only two of the succinylcholine patients. All but one of these patients had factors predisposing to broncho-

This article is accompanied by an Editorial View. Please see: Goudsouzian NG: Rapacuronium and bronchospasm. ANESTHESIOLOGY 2001; 94:727–8.

\* Attending Anesthesiologist, Anesthesia Department, New Britain General Hospital, and Clinical Assistant and Professor of Anesthesiology, Department of Anesthesiology, University of Connecticut Health Center, Farmington, Connecticut.

Received from New Britain General Hospital, New Britain, Connecticut. Submitted for publication May 15, 2000. Accepted for publication November 30, 2000. Support was provided solely from institutional and/or departmental sources.

Address reprint requests to Dr. Kron: New Britain General Hospital, 100 Grand Street, New Britain, Connecticut 06050. Address electronic mail to: skmel@aol.com or sschron@netscape.net. Individual article reprints may be purchased through the Journal Web site, www.anesthesiology.org.

spasm, and six cases were mild and were resolved with minimal or no therapy. One patient in the rapacuronium group had bronchospasm of "moderate severity" that required subsequent doses of  $\beta$  agonist and intravenous steroids.

In a similar study, Sparr *et al.*<sup>3</sup> found 4 cases of increased airway pressure and 14 cases of bronchospasm among the 168 patients intubated with 1.5 mg/kg rapacuronium. This incidence of 10.7% pulmonary side effects was compared with 4.1% of 167 patients intubated with succinylcholine. One of the rapacuronium patients, who had a previous history of chronic bronchitis, was noted to have had "a serious adverse experience." After intubation, bronchospasm developed in the patient, and O<sub>2</sub> saturation decreased to 88% before improvement with bronchodilators. An accompanying editorial<sup>4</sup> suggests that histamine or leukotriene release may be responsible but noted that this remains to be proven. Levy *et al.*<sup>5</sup> described bronchospasm in 7 of 47 patients to whom 1–3 mg/kg rapacuronium was administered but note that in some of these patients there may have been other provoking factors. Interestingly, histamine concentrations were measured in this study and noted to increase to more than 1 ng/ml in five patients, but none of these patients experienced bronchospasm or erythema, suggesting that histamine is not the cause of the pulmonary problem.

In the current patient, although more severe ventila-

tory dysfunction developed after intubation, O<sub>2</sub> saturation unexpectedly decreased 30 s after rapacuronium administration and before airway instrumentation. The patient had been preoxygenated thoroughly, so it is probable that the initial decrease in O<sub>2</sub> saturation was secondary to the evolving bronchospasm.

In summary, a case of rapacuronium-associated severe bronchospasm and O<sub>2</sub> desaturation in a child with no predisposing factors is presented. Fortunately, the patient responded quickly and well to  $\beta$ -adrenergic therapy and deepening anesthesia and was free of symptoms by the end of treatment.

## References

1. Kahwaji R, Bevan DR, Bikhazi G, Shanks C, Fragen R, Dyck B, Angst M, Matteo R: Dose-ranging study in younger adult and elderly patients of Org 9487, a new rapid-onset, short duration muscle relaxant. *Anesth Analg* 1997; 84: 1011–8
2. Fleming NW, Chung F, Glass PS, Kitts J, Kirkegaard-Nielsen H, Gronert G, Chan V, Gan T, Cicuttini N, Caldwell J: Comparison of the intubating conditions provided by rapacuronium (ORG 9487) or succinylcholine in humans during anesthesia with fentanyl and propofol. *ANESTHESIOLOGY* 1999; 91:1311–7
3. Sparr HJ, Mellinghoff H, Blobner M, Noldge-Schomburg G: Comparison of intubating conditions after rapacuronium (Org 9487) and succinylcholine following rapid sequence induction in adult patients. *Br J Anaesth* 1999; 82:537–41
4. Goulde MR, Hunter JM: Rapacuronium (Org 9487): Do we have a replacement for succinylcholine? (editorial). *Br J Anaesth* 1999; 82:489–91
5. Levy JH, Pitts M, Thanopoulos A, Szlam F, Bastian R, Kim J: The effects of rapacuronium on histamine release and hemodynamics in adult patients undergoing general anesthesia. *Anesth Analg* 1999; 89:290–5

Anesthesiology 2001; 94:924–5

© 2001 American Society of Anesthesiologists, Inc. Lippincott Williams & Wilkins, Inc.

## How Serious Is the Bronchospasm Induced by Rapacuronium?

Mohamed Naguib, M.B., B.Ch., M.Sc., F.F.A.R.C.S.I., M.D.\*

RAPACURONIUM (16-N-allyl, 17- $\beta$ -propionate analog of vecuronium) is a new rapid-onset, short-acting, nondepolarizing steroidal neuromuscular blocking drug. Concern has been raised with respect to possible respiratory effects of rapacuronium. The following case report describes a patient in whom severe bronchospasm developed after rapacuronium administration.

This article is accompanied by an Editorial View. Please see: Goudsouzian NG: Rapacuronium and bronchospasm. *ANESTHESIOLOGY* 2001; 94:727–8.

\* Associate Professor.

Received from the Department of Anesthesia, University of Iowa College of Medicine, Iowa City, Iowa. Submitted for publication July 13, 2000. Accepted for publication July 19, 2000. Support was provided solely from institutional and/or departmental sources. Dr. Naguib has received research grants sponsored by Burroughs Wellcome Company, United Kingdom, and Organon, Inc., West Orange, New Jersey.

Address reprint requests to Dr. Naguib: University of Iowa College of Medicine, Department of Anesthesia, 200 Hawkins Drive, GJCP, Iowa City, Iowa 52242-1009. Address electronic mail to: mohamed-naguib@uiowa.edu. Individual article reprints may be purchased through the Journal Web site, [www.anesthesiology.org](http://www.anesthesiology.org).

## Case Report

A 34-yr-old woman, American Society of Anesthesiologists class I, who weighed 90 kg and was 173.5 cm tall was scheduled to undergo laparoscopic tubal ligation. Her medical history was not significant, except for hepatitis B at the age of 13 yr and a history of depressive disorder. The patient was not taking medication. She was a smoker (10 cigarettes per day). Examination was unremarkable. Routine monitoring was used. The patient was preoxygenated, achieving an oxygen saturation measured by pulse oximetry (SpO<sub>2</sub>) of 100%. Anesthesia was induced with 1 mg midazolam, 150  $\mu$ g fentanyl, and 200 mg propofol, followed immediately by 1.4 mg/kg rapacuronium. Anesthesia was maintained immediately with 4% inspired desflurane in oxygen. One minute after administration of rapacuronium, intubation was achieved easily. Severe bronchospasm (wheezing, increased airway pressure during positive pressure ventilation [peak inspiratory pressure of 45 cm H<sub>2</sub>O], and prolonged expiratory phase) occurred just after tracheal intubation. Positive pressure ventilation became exceedingly difficult. Inhalational bronchodilator (albuterol) therapy was administered *via* an AeroVent® Collapsible Holding Chamber (Monaghan Medical Corp., Plattsburg, NY) attached to the inspiratory limb of the anesthetic circuit. SpO<sub>2</sub> decreased to 85% despite the administration of 100% oxygen, and PETCO<sub>2</sub> was 47 mmHg. This lasted for 7 min. The clinical picture gradually improved afterward, and SpO<sub>2</sub> increased slowly to 92%. Approximately 15 min after rapacuronium administration, the wheezing resolved, the peak inspiratory pressure decreased

to 28 cm H<sub>2</sub>O, and SpO<sub>2</sub> increased to 96%. The content of one albuterol nebulizer was administered during this event. Each actuation administers 90 µg albuterol. After this event, anesthesia was maintained with 60% nitrous oxide and desflurane (end-tidal concentration, 2.6–3.0%) in oxygen. Neuromuscular block was maintained with 0.2 mg/kg rocuronium. At the end of surgery, 0.03 mg/kg neostigmine and 0.006 mg/kg glycopyrrolate were administered to the patient for antagonism of residual neuromuscular block. The patient had an uneventful recovery. No further bronchospasm was noted during her postoperative course.

## Discussion

Although the overall reported incidence of bronchospasm (in controlled trials) after rapacuronium and succinylcholine were 3.2 and 2.1%, respectively (data from Organon Inc., West Orange, NJ), others<sup>1</sup> noted 18 incidents of such events (10.7%) after rapacuronium compared with 7 cases (4.1%) after succinylcholine. In the latter study, only one patient in the rapacuronium group, who had a history of obstructive airway disease, had severe bronchospasm after intubation.<sup>1</sup> Our patient had severe bronchospasm after rapacuronium despite the facts that she was not asthmatic and that she received propofol for induction. Kahwaji *et al.*<sup>2</sup> reported two serious adverse effects (tachycardia and bronchospasm) that occurred in a 29-yr-old, 100-kg man with American Society of Anesthesiologists physical status I within 30 s of administration of 2.0 mg/kg rapacuronium.

Rapacuronium may release histamine and produce slight changes in blood pressure and heart rate after administration.<sup>3</sup> However, it seems that the bronchospasm noted with rapacuronium is mediated *via* mechanisms that do not seem to be related to histamine

release.<sup>3</sup> The affinity of neuromuscular blockers for the muscarinic receptor seems to have some influence on neural control of airway caliber. Pancuronium and atracurium (but not vecuronium) were found to enhance the increases in pulmonary resistance induced by vagus nerve stimulation, probably by blocking prejunctional muscarinic receptors (M<sub>2</sub>) that physiologically inhibit vagally mediated increases in pulmonary resistance.<sup>4,5</sup> Blockage of M<sub>3</sub> muscarinic receptors on airway smooth muscle inhibits vagally induced bronchoconstriction.<sup>5</sup> Pancuronium and gallamine had affinities for the M<sub>2</sub> muscarinic receptor within the clinical dose range.<sup>6</sup> The affinity of rapacurium for muscarinic receptors has not been studied. Therefore, there is insufficient evidence to make a definite statement on how rapacuronium induces bronchospasm. It seems prudent, therefore, to avoid using rapacuronium in patients with asthma or airway hyperreactivity.

## References

1. Sparr HJ, Mellinshoff H, Blobner M, Nolge-Schonburg G: Comparison of intubating conditions after rapacuronium (Org 9487) and succinylcholine following rapid sequence induction in adult patients. *Br J Anaesth* 1999; 82:537–41
2. Kahwaji R, Bevan DR, Bikhazi G, Shanks CA, Fragen RJ, Dyck JB, Angst MS, Matteo R: Dose-ranging study in younger adult and elderly patients of ORG 9487, a new rapid-onset, short-duration muscle relaxant. *Anesth Analg* 1997; 84:1011–8
3. Levy JH, Pitts M, Thanopoulos A, Szlam F, Bastian R, Kim J: The effects of rapacuronium on histamine release and hemodynamics in adult patients undergoing general anesthesia. *Anesth Analg* 1999; 89:290–5
4. Vettermann J, Beck KC, Lindahl SG, Brichant JF, Rehder K: Actions of enflurane, isoflurane, vecuronium, atracurium, and pancuronium on pulmonary resistance in dogs. *ANESTHESIOLOGY* 1988; 69:688–95
5. Okanami OA, Fryer AD, Hirshman C: Interaction of nondepolarizing muscle relaxants with M<sub>2</sub> and M<sub>3</sub> muscarinic receptors in guinea pig lung and heart. *ANESTHESIOLOGY* 1996; 84:155–61
6. Hou VY, Hirshman CA, Emala CW: Neuromuscular relaxants as antagonists for M<sub>2</sub> and M<sub>3</sub> muscarinic receptors. *ANESTHESIOLOGY* 1998; 88:744–50

## Bronchospasm after Rapacuronium in Infants and Children

George H. Meakin, M.D.,\* Erik H. Pronske, M.D.,† Jerrold Lerman, M.D.,‡ Rosemary Orr, M.D.,§ Denise Joffe, M.D.,|| Anne M. Savaree, M.D.,# Anne M. Lynn, M.D.\*\*

IN December 2000, subscribers to the Paediatric Anaesthesia Conference discussion group <PAC@anaes.sickkids.on.ca> were invited to post their experiences with rapacuronium (Raplon; Organon Inc., West Orange, NJ) in children in the USA. Specific side effects or responses to rapacuronium were neither requested nor encouraged. The postings yielded 19 cases of bronchospasm, of which 12 were described as severe, from six respondents. These reports caused such concern that the respondents felt obliged to bring this to the attention of their colleagues. Three of the cases are summarized below.

### Case Reports

#### Case 1

The patient was a 12-yr-old, 64-kg boy with a diagnosis of acute appendicitis. He had a history of mild reactive airways disease that was characterized by occasional use of an albuterol inhaler but no previous hospital stays. His last occurrence of wheezing was 1-2 months before this admission. Chest examination results were unremarkable. In the operating room, a rapid sequence induction consisting of 1 mg intravenous midazolam, 75 µg fentanyl, 200 mg propofol, and 100 mg rapacuronium was performed. Cricoid pressure was applied, and the trachea was intubated by the resident. When squeezing the reservoir bag, the resident reported that the tube was not "in the trachea" and removed it. After reintubation, he remained unable to ventilate the lungs. No expired carbon dioxide was noted on the capnograph. The staff knew the tube had passed into the trachea, but when the staff squeezed the reservoir bag, it felt like "ventilating cement." After albuterol and isoflurane were administered by inhalation and a dose of vecuronium, chest movement gradually became evident with bag com-

pression, and a capnogram trace appeared. At this time, the oxygen saturation percentage was in the low 80s. Epinephrine 50 µg was administered intravenously with continued improvement in chest compliance and oxygen saturation. When the airways had stabilized, surgery proceeded uneventfully. Recovery was uneventful.

#### Case 2

The patient was a 41/2-yr-old girl who presented to the emergency department with the sudden onset of a prolonged seizure. The seizure had been treated with rectal diazepam. An anesthesiologist was consulted to intubate the trachea electively because of increasing respiratory distress. Medical history included a mild upper respiratory tract infection without fever or anorexia. Chest radiography was unremarkable. Additional history included spina bifida, panhypopituitarism, choanal atresia, developmental delay, and reactive airways disease. Medication history included phenobarbital, hydrocortisone, L-thyroxine, growth hormone, and albuterol prn. There were no known allergies. The child had a fever of 40°C. Hydrocortisone was administered intravenously. Immediately after a single dose of both propofol and rapacuronium, the anesthesiologist noted "severe bronchospasm, dropping oxygen saturations, very difficult to ventilate." The child then experienced asystole for 30 s, with a return of the pulse after a single dose of epinephrine. Chest radiography after stabilizing the child revealed bilateral pneumothoraces. After treating these, the child was stabilized and recovered.

#### Case 3

The patient was a 3-week-old, 3.4-kg healthy infant who presented for pyloromyotomy. After the stomach was suctioned, a rapid sequence induction was performed using 10 mg propofol, 7 mg rapacuronium, and 0.050 mg intravenous atropine. The trachea was intubated, but there was no capnogram trace after two breaths. The tube was removed and the trachea was reintubated. Again, there was no capnogram trace. After confirming by direct laryngoscopy that the tube passed through the vocal cords, the lungs were ventilated vigorously for 60-90 s with 100% oxygen. During that time, air entry was poor and bronchospasm was auscultated bilaterally. At this time, the chest appeared to move somewhat with inflation. The pulse oximeter did not register an oxygen saturation during this period, and heart rate slowed. As bradycardia developed, a capnogram trace began to appear, and, soon thereafter, the pulse oximeter registered a saturation of 99%. There was no evidence of a rash. With the return of the capnogram trace and an oxygen saturation reading, surgery and anesthesia proceeded uneventfully.

This article is accompanied by an Editorial View. Please see: Goudsouzian NG: Rapacuronium and bronchospasm. *ANESTHESIOLOGY* 2001; 94:727-8.

\* Senior Lecturer in Paediatric Anaesthesia, University Department of Anaesthesia, Royal Manchester Children's Hospital. † Chief of Anesthesia, The Children's Hospital of Austin, Austin, Texas. ‡ Professor of Anaesthesia and Siemens Chair in Paediatric Anaesthesia, University of Toronto, Hospital for Sick Children, Toronto, Canada. § Associate Professor of Anesthesiology and Pediatrics, \*\* Professor of Anesthesiology and Pediatrics, University of Washington, Seattle, Washington. || Assistant Professor of Anesthesiology and Pediatrics, Children's National Medical Center, Washington, DC. # Assistant Professor of Anesthesiology and Pediatrics, University of Maryland Medical System, Baltimore, Maryland.

Received from the Department of Anaesthesia, Royal Manchester Children's Hospital, University of Manchester, Pendlebury, Manchester, United Kingdom. Submitted for publication January 11, 2001. Accepted for publication February 27, 2001. Support was provided solely from institution and/or departmental sources. Dr. Meakin has received funding for research regarding the drug rapacuronium by Organon Teknika bv, Boxtel, The Netherlands.

Address reprint requests to Dr. Meakin: University Department of Anaesthesia, Royal Manchester Children's Hospital, Manchester M27 4HA, United Kingdom. Address electronic mail to: george.meakin@man.ac.uk. Individual article reprints may be purchased through the Journal Web site, [www.anesthesiology.org](http://www.anesthesiology.org).

### Discussion

A total of 19 cases of bronchospasm after rapacuronium were reported to the discussion group. All of the events occurred in children, whose ages ranged from infancy to adolescence. Four of the children had a confirmed history of reactive airways disease, whereas one did not. In two cases, rapacuronium was used to facili-

tate a rapid sequence induction of anesthesia. In the 12 cases of severe bronchospasm, the onset of symptoms was rapid, with extreme stiffness of the lungs noted immediately after intubation and absence of the end-tidal carbon dioxide trace. In three cases, intubation of the trachea was questioned because the lungs were uncharacteristically stiff to ventilate, and the capnogram trace was absent. However, laryngoscopy confirmed correct placement of the tube. Some of the respondents stated that this was the worst postintubation bronchospasm they had ever encountered, others that it was like trying to "ventilate a brick" or "ventilate cement."

Reddening of the skin (a possible sign of histamine release) was noted in one patient. The absence of clinical evidence of histamine release was noted specifically in five other patients. In one of these, plasma histamine concentration measured within 5 min of the event was normal. Treatment for the bronchospasm included increasing the level of anesthesia, increasing the administration of albuterol or epinephrine, or both. However, most cases resolved spontaneously after a few minutes, and none lasted more than 10 min. Additional complications that were observed included hemoglobin oxygen desaturation in one child and bilateral pneumothoraces in another.

Although the details from some of the cases are incomplete, together, these experiences suggest an association between administration of rapacuronium and the abrupt development of severe, albeit short-lived and self-limit-

ing bronchospasm in pediatric patients. One author, who contributed 2 of the 19 cases, subsequently reviewed her institutional experience with rapacuronium and identified a total of 8 cases of bronchospasm after rapacuronium for an incidence of 8 in 500 (1.6%). This incidence is consistent with a published incidence of 1.2% in infants and children<sup>1</sup> and 1.1% in adults<sup>2</sup> (although incidences as great as 8.3% and 14.8% have been reported in adults).<sup>3,4</sup> Some of the anesthesiologists involved with these cases are now reluctant to use rapacuronium in infants or children with a history of reactive airway disease or in those in whom bronchospasm would be tolerated poorly. Readers should be aware of this potentially serious side effect of rapacuronium and are encouraged to report all adverse events after administration of rapacuronium to the Food and Drug Administration and the manufacturer.

## References

1. Meakin GH, Meretoja OA, Mutsch J, Taivainen T, Wirtavuori K, Schönstedt R, Perkins R, McCluskey A: A dose-ranging study of rapacuronium in pediatric patients. *ANESTHESIOLOGY* 2000; 92:1002-9
2. Kahwaji R, Bevan DR, Bikhazi G, Shanks CA, Fragen RJ, Dyck JB, Angst MS, Matteo R: Dose-ranging study in younger adults and elderly patients of ORG 9487, a new, rapid onset, short duration muscle relaxant. *Anesth Analg* 1997; 84: 1011-8
3. Sparr HJ, Mellinghoff H, Blobner M, Noldge-Schomburg G: Comparison of intubating conditions after rapacuronium (Org 9487) and succinylcholine following rapid sequence induction in adult patients. *Br J Anaesth* 1999; 82:537-41
4. Levy JH, Pitts M: The effects of rapacuronium on histamine release and hemodynamics in adult patients undergoing general anesthesia. *Anesth Analg* 1999; 89:290-5

Anesthesiology 2001; 94:927-30

© 2001 American Society of Anesthesiologists, Inc. Lippincott Williams & Wilkins, Inc.

## High-frequency Jet Ventilation in Life-threatening Bilateral Pulmonary Contusion

Bruno Riou, M.D., Ph.D.,\* Khaled Zaier, M.D.,† Pierre Kalfon, M.D.,‡ Louis Puybasset, M.D., Ph.D.,‡  
Pierre Coriat, M.D.,§ Jean-Jacques Rouby, M.D., Ph.D.\*

TRAUMA is the leading cause of death among young people in developed countries.<sup>1</sup> Because up to 80% of trauma deaths occur during the first 24 h after trauma,<sup>1</sup> early resuscitation and rapid assessment of trauma lesions are of paramount importance to improving the prognosis. Among traumatic lesions, pulmonary contusion is frequent but has not been recognized as an independent prognosis factor.<sup>2-4</sup> In very few cases, pul-

monary contusion may lead to severe hypoxia and hypercarbia, which cannot be adequately controlled using conventional mechanical ventilation. Hypoxia and hypercarbia may have deleterious effects, such as enhancement of brain injury and development of circulatory shock.<sup>5</sup> In the most severe cases, aggressive therapeutic methods, such as extracorporeal membrane oxygenation (ECMO), have been reported.<sup>6</sup> At our institution, high-frequency jet ventilation (HFJV) has been used routinely for many years for the treatment of severe acute respiratory distress syndrome.<sup>7,8</sup> We report a series of severe trauma patients with life-threatening pulmonary contusion successfully treated with HFJV when the conventional mechanical ventilation approach failed to provide appropriate gas exchange. The current data suggest that HFJV can be a life-saving technique in severely hypoxemic patients with bilateral pulmonary contusion.

\* Professor of Anesthesiology, † Resident in Anesthesiology, ‡ Assistant Professor of Anesthesiology, § Professor of Anesthesiology and Chairman.

From the Department of Anesthesiology and Critical Care, Centre Hospitalier Universitaire Pitié-Salpêtrière, Université Pierre et Marie Curie, Paris, France. Submitted for publication January 14, 2000. Accepted for publication October 12, 2000. Support was provided solely from institutional and/or departmental sources.

Address reprint requests to Dr. Riou: Département d'Anesthésie-Réanimation, CHU Pitié-Salpêtrière, 47 Boulevard de l'Hôpital, 75651 Paris Cédex 13, France. Address electronic mail to: bruno.riou@psl.ap-hop-paris.fr. Individual article reprints may be purchased through the Journal Web site, www.anesthesiology.org.

**Table 1. Evolution of the Main Hemodynamic, Ventilatory, and Arterial Blood Gas Parameters in Nine Patients with Life-threatening Pulmonary Contusion during Conventional Mechanical Ventilation and High-frequency Jet Ventilation (HFJV)**

	Admission	Conventional Ventilation	HFJV	24 h after Admission
Arterial pH	7.21 ± 0.13	7.19 ± 0.14	7.31 ± 0.14	7.39 ± 0.08*
Paco <sub>2</sub> (mmHg)	56 ± 21	60 ± 18	51 ± 18	40 ± 6†
Pao <sub>2</sub> (mmHg)	91 ± 71	73 ± 24	237 ± 26*†	185 ± 52*†
Fio <sub>2</sub> (%)	100 ± 0	100 ± 0	96 ± 13	58 ± 17*†
Pao <sub>2</sub> /Fio <sub>2</sub>	91 ± 71	73 ± 24	254 ± 101*†	322 ± 49*†
Tidal volume (ml)	563 ± 95	669 ± 151	136 ± 59*†	143 ± 45*†
Ventilatory rate (breaths/min)	21 ± 9	16 ± 2	250 ± 51*†	233 ± 83*†
EEP (cm H <sub>2</sub> O)	4 ± 5	10 ± 3*	—	—
P <sub>aw</sub> (cm H <sub>2</sub> O)	—	—	11 ± 2	10 ± 2
MAP (mmHg)	70 ± 23	86 ± 16	85 ± 16	90 ± 13
Heart rate (beats/min)	100 ± 18	114 ± 7	112 ± 19	109 ± 16

Initial data with HFJV were obtained within 1 h after the onset of HFJV. Data are mean ± SD.

\*  $P < 0.05$  versus admission. †  $P < 0.05$  versus conventional ventilation.

Paco<sub>2</sub> = arterial partial pressure of carbon dioxide; Pao<sub>2</sub> = arterial partial pressure of oxygen; Fio<sub>2</sub> = inspired fraction of oxygen; EEP = end-expiratory pressure; P<sub>aw</sub> = mean airway pressure; MAP = mean arterial pressure.

## Patients and Methods

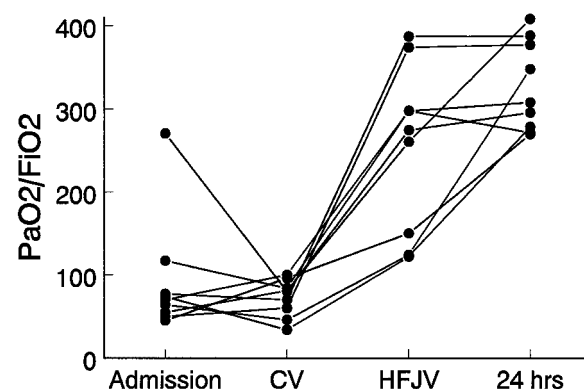
During a 6-yr period (1990–1996), 1,241 severe trauma patients were admitted to our Level 1 Trauma Centre. All trauma patients who received HFJV during the first 24 h after admission were identified and included in the study. One of these patients has been reported previously.<sup>9</sup> The decision to perform HFJV was made by the senior anesthesiologist in charge of the emergency room because of the severity of pulmonary contusion. All patients fulfilled the following criteria: (1) partial pressure of oxygen (Pao<sub>2</sub>) less than 100 mmHg with an inspired fraction of oxygen (Fio<sub>2</sub>) of 100%; (2) progressive decrease in Pao<sub>2</sub> during the last hours without any trend to stabilization or improvement; (3) failure of further increases in positive end-expiratory pressure (PEEP) to improve Pao<sub>2</sub> or impossibility to increase PEEP because of hemodynamic consequences; (4) bilateral pulmonary contusion. An anesthesiologist and a nurse from the surgical intensive care unit initiated and adjusted HFJV in the emergency room. The decision to implement HFJV during the early period after trauma admission always was related to severe hypoxemia or circulatory shock. We did not include patients in whom HFJV was initiated because of systemic gas embolism related to pulmonary contusion.<sup>10</sup>

The following data were collected: age; sex; trauma lesions; administration of colloids, crystalloids, blood, and catecholamines; duration of stay in intensive care unit; and mortality. The following ventilatory parameters were recorded during conventional mechanical ventilation: ventilatory rate, tidal volume, and PEEP. The following parameters were measured at admission, during conventional mechanical ventilation, just before HFJV, 15–30 min after HFJV, and 24 h after admission: arterial pH, Pao<sub>2</sub> and partial pressure of carbon dioxide (Paco<sub>2</sub>), Pao<sub>2</sub>/Fio<sub>2</sub> ratio, mean arterial pressure measured using an indwelling radial or femoral artery catheter, and heart rate. The following indices were calculated: injury sever-

ity score (ISS), probability of survival according to the Trauma and Injury Severity Score (TRISS) methodology,<sup>11</sup> and the Lung Injury Severity Score (LIS)<sup>12</sup>

High-frequency jet ventilation was performed using an AMS 1000 ventilator (Acutronic Medical Systems AG, Hirzel, Switzerland). Rewarming and humidification of gases were provided by a HH-812 Jet humidifier (Acutronic Medical Systems). Additional conventional ventilation (low rate, 4–6 breaths/min; low tidal volume, 75–100 ml) was obtained using a CPU 1 ventilator (Ohmeda, Maurepas, France). Mean airway pressure was monitored continuously with a catheter located in the trachea 10 cm distal to the tip of the injector cannula, as previously reported.<sup>7,8</sup>

Data are mean ± SD. Comparison of several means was performed using repeated-measures analysis of variance. A  $P$  value less than 0.05 was considered significant.



**Fig. 1.** Evolution of the partial pressure of oxygen/inspired fraction of oxygen (Pao<sub>2</sub>/Fio<sub>2</sub>) ratio during the first 24 h in nine patients with life-threatening pulmonary contusion. Initial data with high-frequency jet ventilation (HFJV) were obtained within 1 h after the onset of HFJV. CV = conventional mechanical ventilation; 24 hrs: 24 h after admission, during HFJV.

## Results

Over a 6-yr period, HFJV was used during the first 24 h after admission in nine patients (six male, three female) because of life-threatening hypoxemia related to pulmonary contusion. The incidence of life-threatening pulmonary contusion defined by this criteria was 0.73% (95% confidence interval, 0.26–1.20%). The mean age was  $29 \pm 15$  yr (range, 8–58 yr), the mean ISS was  $50 \pm 17$  (range, 20–75), the mean TRISS was  $0.63 \pm 0.36$  (range, 0.08–0.96), and the mean LIS was  $3.4 \pm 0.3$  (range, 3–4). These scores signify severe multisystem injuries. Associated head trauma was present in seven patients, abdominal trauma was present in four patients, spine trauma was present in four patients, and pelvic trauma in was present in two patients. All patients had severe thoracic trauma with bilateral pulmonary contusion. Chest radiography showed bilateral extensive and diffuse alveolar hyperdensities in all cases. Other traumatic thoracic lesions included hemothorax in three patients, pneumothorax in two patients, and aortic rupture in one patient. All patients underwent transesophageal echocardiography: mean left ventricular ejection fraction was  $45 \pm 29\%$  (range, 10–71%), myocardial contusion was observed in five patients, and three patients had severe decrease in left ventricular ejection fraction ( $< 30\%$ ). A search for a patent foramen ovale was performed in five patients; all results were negative. During the first 24-h period, fluid resuscitation consisted of  $1.8 \pm 1.3$  l crystalloids,  $3.7 \pm 1.8$  l colloids,  $7 \pm 8$  units packed erythrocytes,  $3 \pm 3$  units fresh frozen plasma, and  $4 \pm 5$  platelet units. Catecholamines were administered in eight patients (epinephrine in three patients, norepinephrine in four patients, dopamine in five patients, and dobutamine in one patient). After HFJV, the dose of catecholamines was decreased in six patients and increased in two patients.

Tracheal intubation was performed in all patients during the early resuscitation phase (delay,  $51 \pm 68$  min after trauma). HFJV was initiated  $7 \pm 6$  h after trauma. Table 1 shows the evolution of the main hemodynamic, ventilatory, and blood gas parameters. Figure 1 depicts the evolution of the  $P_{aO_2}/F_{iO_2}$  ratio during the first 24 h.

The mean stay in the intensive care unit was  $40 \pm 38$  days. Death occurred in four patients and was always related to severe brain injury. In the five surviving patients, HFJV was maintained for  $7 \pm 5$  days (range, 3–15 days).

## Discussion

We report that HFJV dramatically increased  $P_{aO_2}$  in a group of trauma patients with life-threatening hypoxemia related to bilateral pulmonary contusion. Despite severe pulmonary contusion, death always occurred because of brain injury and not because of pulmonary contusion, and weaning of HFJV was obtained success-

fully in all the remaining patients. These results confirm previous reports that suggest that HFJV can be effective as a rescue therapy for refractory acute lung dysfunction.<sup>13,14</sup>

The current study cannot definitely assess the mechanisms involved in the beneficial effect of HFJV. Because of the emergency and critical conditions, a pulmonary computed tomography scan could not be obtained in most of these patients at the early phase. Nevertheless, thoracic radiography highly suggested that diffuse pulmonary contusion occurred, and thus that alveolar recruitment induced by HFJV was likely the main mechanism responsible for the marked increase in  $P_{aO_2}$  observed in our patients. HFJV is known to induce an increase in functional residual capacity by trapping intrapulmonary gases because of incomplete exhalation during the short expiratory time (auto-PEEP effect). Two other mechanisms should be considered. First, closure of a patent foramen ovale may have reduced hypoxemia, as previously reported.<sup>15</sup> However, it should be noted that an increase in pulmonary artery pressure (potentially leading to right-to-left intracardiac shunt) usually is not observed at the very early stage of pulmonary contusion and that we failed to find evidence of any patent foramen ovale using transesophageal echocardiography in five of these patients. Second, an improvement in hemodynamic conditions may have contributed to the HFJV-induced increase in  $P_{aO_2}$ . This last effect can be complex because an increase in cardiac output can decrease  $P_{aO_2}$  through capillary recruitment but also can increase  $P_{aO_2}$  through an increase in mixed venous oxygen saturation. In patients with septic shock, Fuscaldi *et al.*<sup>16</sup> have shown that mean arterial pressure and cardiac output are higher during HFJV than during conventional mechanical ventilation when compared at the same airway pressure and  $P_{aCO_2}$ . However, this hemodynamic improvement was associated with a small deterioration in arterial oxygenation.<sup>16</sup>

Because the mean PEEP value was not high in our study, one can argue that a marked increase in PEEP might have induced an effect similar to that observed with HFJV. In our patients, such an increase in PEEP could not be applied without marked alteration in hemodynamic conditions. Associated right ventricle contusion is likely to explain that our patients poorly tolerated any further increase in intrathoracic pressure.<sup>9</sup> At an identical level of mean airway pressure, HFJV is better hemodynamically tolerated than PEEP in shocked patients.<sup>17</sup> It should be pointed out that high PEEP is associated with high peak inspiratory pressure that can be harmful in patients with pulmonary contusion because it increases pulmonary edema,<sup>18</sup> causes barotrauma through alveolar rupture, and facilitates pulmonary venous gas embolism.<sup>10</sup> It has been demonstrated recently that reducing tidal volume during mechanical ventilation in ARDS decreases mortality.<sup>19</sup> High PEEP and low tidal volume induce hypercapnia that is dele-

rious in patients with head trauma. As shown in table 1, HFJV enabled control of  $\text{Paco}_2$  and  $\text{Pao}_2$  in patients with severe life-threatening pulmonary contusion. Moreover, the fluid loading required to overcome the hemodynamic effects of PEEP on venous return also may increase extravascular lung water.

In conclusion, in rare cases of severe bilateral pulmonary contusion refractory to conventional mechanical ventilation, HFJV may be a life-saving procedure. Because of the rarity of these cases, there is a low possibility that a randomized trial could ever be conducted. Therefore, traumatologists, intensivists, and anesthesiologists should be aware of this therapeutic possibility and should try HFJV before irreversible consequences of hypoxemia or hypercarbia occur in these severe trauma patients. Moreover, HFJV is probably a more simple procedure than ECMO, which sometimes has been used in such patients<sup>6</sup> but usually is contraindicated in severe head trauma.

## References

1. Capan LM, Miller SM, Turndorf H: Trauma overview, Trauma Anesthesia and Intensive Care. Edited by Capan LM, Miller SM, Turndorf H. Philadelphia, Lippincott, 1991, pp 3-28
2. Clark GC, Schechter WP, Trunkey DD: Variables affecting outcome in blunt chest trauma: flail chest vs. pulmonary contusion. *J Trauma* 1988; 28:298-304
3. Johnson JA, Cogbill TH, Wingo ER: Determinants of outcome after pulmonary contusion. *J Trauma* 1986; 26:695-7
4. Hoff SJ, Shotts SD, Eddy VA, Morris JA: Outcome of isolated pulmonary contusion in blunt trauma patients. *Am Surg* 1994; 60:138-42
5. Wilson RF, Gibson DB, Antonenko D: Shock and acute respiratory failure after chest trauma. *J Trauma* 1977; 17:697-705
6. Voeckel W, Wenzel V, Rieger M, Antretter H, Padosch S, Schoberberger W: Temporary extracorporeal membrane oxygenation in the treatment of acute traumatic lung injury. *Can J Anaesth* 1998; 45:1044-8
7. Rouby JJ, Simonneau G, Benhamou D, Sartene R, Sardnal F, Deriaz H, Duroux P, Viars P: Factors influencing pulmonary volumes and  $\text{CO}_2$  elimination during high-frequency jet ventilation. *ANESTHESIOLOGY* 1985; 63:473-82
8. Rouby JJ, Viars P: Clinical use of high frequency jet ventilation. *Acta Anaesthesiol Scand* 1989; 90(suppl):134-9
9. Oriaguet G, Jacquens Y, Riou B, Le Bret F, Rouby JJ, Viars P: Combined severe myocardial and pulmonary contusion: Early diagnosis with transesophageal echocardiography and management with high-frequency jet ventilation. *J Trauma* 1993; 34:455-7
10. Saada M, Goarin JP, Riou B, Rouby JJ, Jacquens Y, Guesde R, Viars P: Systemic gas embolism complicating pulmonary contusion: Diagnosis and management using transesophageal echocardiography. *Am J Respir Crit Care Med* 1995; 152:812-5
11. Boyd CR, Tolson MA, Copes WS: Evaluating trauma care: the TRISS method. *J Trauma* 1987; 27:370-8
12. Murray JF, Matthay MA, Luce JM, Flick MR: An expanded definition of the adult respiratory distress syndrome. *Am Rev Respir Dis* 1988; 138:720-3
13. Borg UR, Stoklosa JC, Siegel JH, Wiles CE, Belzberg H, Blevins S, Cotter K, Laghi F, Rivkind A: Prospective evaluation of combined high-frequency ventilation in post-traumatic patients with adult respiratory distress syndrome refractory to optimized conventional ventilatory management. *Crit Care Med* 1989; 17:1129-42
14. Claridge JA, Hostetter RG, Lowson SM, Young JS: High-frequency oscillatory ventilation can be effective as rescue therapy for refractory acute lung dysfunction. *Am Surg* 1999; 65:1092-6
15. Fellahi JL, Mourgeon E, Goarin JP, Law-Koune JD, Riou B, Coriat P, Rouby JJ: Inhaled nitric oxide-induced closure of a patent foramen ovale in a patient with acute respiratory distress syndrome and life-threatening hypoxia. *ANESTHESIOLOGY* 1995; 83:635-8
16. Fuscuardi J, Rouby JJ, Barakat T, Mal H, Godet G, Viars P: Hemodynamic effects of high-frequency jet ventilation in patients with and without circulatory shock. *ANESTHESIOLOGY* 1986; 65:485-91
17. Rouby JJ, Houissa M, Brichant JF, Baron JF, McMillan C, Arthaud M, Amzallag P, Viars P: Effects of high-frequency jet ventilation on arterial baroreflex regulation on heart rate. *J Appl Physiol* 1987; 63:2216-22
18. Dreyfuss D, Soler P, Basset G, Saumon G: High inflation pressure pulmonary edema: Respective effects of high airway pressure, high tidal volume and positive expiratory pressure. *Am Rev Respir Dis* 1988; 137:1159-64
19. The Acute Respiratory Distress Syndrome Network: Ventilation with lower tidal volumes for acute lung injury and the acute respiratory distress syndrome. *N Engl J Med* 2000; 342:1301-8

Anesthesiology 2001; 94:930-2

© 2001 American Society of Anesthesiologists, Inc. Lippincott Williams & Wilkins, Inc.

## Jet Ventilation for Fiberoptic Bronchoscopy

Ivan David, M.D.,\* Miloslav Marel, M.D., C.Sc.,† Renata Pipková, M.D.,‡ Jiří Najbrt, M.D.,§ Pavel Vychodil, M.D.,|| Jan Schützner, M.D., C.Sc.,# Pavel Pafko, M.D., Dr.Sc.\*\*

ACUTE pulmonary or lobar collapse is a troublesome complication after thoracic surgery and may mandate aggressive intervention. Therapeutic fiberoptic bronchoscopy is a standard intervention for the treatment of atelectasis in the intensive care setting.<sup>1</sup>

After tracheal resection, airway management for fiberoptic bronchoscopy in patients with general anesthesia is frequently difficult, particularly in cases in which the resected tracheal segment is long (e.g., 4-5 cm) and the degree of postoperative neck flexion is necessarily extreme. We report a case of intermittent low-frequency jet ventilation, applied *via* the instrument channel of a flexible fiberoptic bronchoscope (FFB), for the emergency treatment of postoperative atelectasis after tracheal reconstruction.

## Case Report

An 18-yr-old male underwent cardiopulmonary resuscitation after arrhythmia complicating acute myocarditis. After 3 days of ventilatory support, he was extubated successfully and was discharged subsequently. Six weeks later, he was referred to our university hospital. At the time of presentation, he exhibited respiratory distress with inspiratory and expiratory stridor. Rigid bronchoscopy revealed severe tra-

\* Consultant Cardiothoracic Anaesthetist, § Consultant Anaesthetist, || Registrar Anaesthetist, Department of Anesthesia and Intensive Care, † Assistant Professor, Department of Respiratory Medicine, ‡ Consultant Radiologist, Department of Radiology, 2nd School of Medicine, # Assistant Professor, \*\* Professor of Surgery, 3rd Department of Surgery, 1st School of Medicine, Motol University Hospital Prague.

Received from the Department of Anesthesia and Critical Care, Motol University Hospital, Prague, Czech Republic. Submitted for publication July 6, 2000. Accepted for publication December 1, 2000. Supported by the National Health Insurance System (The General Health Insurance Company, Prague, Czech Republic). Presented at the annual meeting of the European Cardiothoracic Intensive Care Workgroup, London, United Kingdom, October 14, 2000.

Address reprint requests to Dr. David: Department of Anesthesia and Intensive Care, Motol University Hospital, V Úvalu 84, 150 06 Praha 5, Czech Republic. Address electronic mail to: ivan.david@volny.cz. Individual article reprints may be purchased through the Journal Web site, www.anesthesiology.org.

cheal stenosis just below the cricoid cartilage. Electrocoagulation and dilatation were performed, and the patient was able to breathe spontaneously and comfortably after the procedure. A spiral computed tomography scan 2 days later showed the stenosis to extend 40 mm from its proximal origin, 30 mm below the vocal cords, with an ID of 7.4–8.2 mm.

One week after this admission, tracheal resection was performed. A tracheal segment of 45 mm in length was resected, followed by end-to-end suture. The length of resection rendered head extension impossible. As per our protocol, the patient was extubated immediately after surgery and was transferred subsequently to the surgical intensive care unit. After an initial stable course, on the first postoperative day, he had a substantial decrease in peripheral oxygen saturation ( $\text{SpO}_2$ ) to 81%. Chest radiography showed complete atelectasis of the left lung. We elected to perform fiberoptic bronchoscopy during general anesthesia with manual ventilation *via* face mask.

After induction of anesthesia by titration of propofol up to a dose of 2.5 mg/kg, we initially verified that manual ventilation *via* face mask was feasible. We then commenced an infusion of propofol at the usual dose of  $9 \text{ mg} \cdot \text{kg}^{-1} \cdot \text{h}^{-1}$  (i.e.,  $150 \mu\text{g} \cdot \text{kg}^{-1} \cdot \text{min}^{-1}$ ). Topical lidocaine was applied to the larynx *via* the instrument channel of the FFB, and it proved unnecessary to administer muscle relaxants. The FFB passed easily through the tracheal anastomosis to the tracheal bifurcation, and no signs of recent bleeding were noted. A thick, white mucous plug was identified, situated 1 cm below the orifice of the left main bronchus. We instilled a mucolytic preparation and commenced suction clearance of the plug and other secretions.

Unfortunately, the mucous proved extremely tenacious, and the procedure was complicated by recurrent decreases in  $\text{SpO}_2$  to unacceptable levels. It proved necessary to repeatedly interrupt fiberoptic bronchoscopy to reestablish more effective manual ventilation. After repeated interruptions and ongoing recurrent desaturations, we decided to use jet ventilation.

We used the Paravent PAT<sub>E</sub> ventilator (Elmet Ltd., Přelouč, Czech Republic). This device features a high-powered jet nozzle and incorporates a Venturi principle to enhance administered gas volume. We connected the jet to the suction channel (2.2 mm diameter) of the FFB (Olympus BF 20D, Tokyo, Japan). We then ventilated with pure oxygen using a low-frequency regime at a respiratory rate of 20 breaths/min and a driving pressure of 80 kPa (600 mmHg or 12 psi). Inspiratory to expiratory time ratio was set at 1:1. The tip of the FFB was placed 1–2 cm above the carina.

Using this approach, we were able to achieve  $\text{SpO}_2$  levels higher than 95%, and it proved possible to continue the procedure in a controlled and safe fashion. Chest excursion could be easily observed clinically, and, at the end of the procedure, chest excursions were symmetrical. When  $\text{SpO}_2$  decreased to 90%, we interrupted suction and repeated the jet ventilation maneuver. For vigorous bronchial toilet and to encourage mobilization of secretions, the patient underwent ventilation for a brief period (three times for 1 or 2 min) using a high-frequency mode with a respiratory rate of 180 breaths/min. Finally, we awakened the patient, and the subsequent chest radiography clearly documented successful treatment with reexpansion of the left lung.

## Discussion

This case highlights two particular difficulties that may be faced in the management of pulmonary atelectasis after tracheal reconstruction. First, extreme flexion of the neck presents substantial difficulties for securing a stable airway during an anesthetic procedure. In addition, there is the potential for direct damage to the tracheal anastomoses from any tracheal instrumentation, particularly from blindly placed endotracheal tubes.

The optimum technique for airway management was the subject of much deliberation in this case. Extreme forward tilting of the head prevented insertion of a laryngeal mask airway<sup>2</sup> or an endotracheal tube *via* a traditional intubation technique. In addition, the possibility of direct tracheal suture injury, even with careful insertion of the endotracheal tube, was of great concern. Finally, we opted for the combination of intravenous anesthesia and manual ventilation *via* face mask as described.

There is very limited information in the literature about the use of the instrument ("suction") channel of the FFB for jet ventilation. In 1980, Satyanarayana *et al.*<sup>3</sup> evaluated this technique in animals and in eight adult volunteers scheduled to undergo minor surgery. He observed excellent arterial oxygenation and hypocarbia and reported no complications. Dalens *et al.*<sup>4</sup> reported a series of 49 pediatric patients with respiratory distress, aged 3 days to 3 yr, who underwent bronchoscopic examination using a similar technique. As in our report, after every distal exploration, the FFB tip was withdrawn to above the carina to ensure bilateral pulmonary insufflations, which were then given for 15 s at a respiratory rate of 50 to 60 breaths/min. Gas exchange was acceptable, and no complications were observed.

In the latest report, Baraka<sup>5</sup> applied a similar technique in a 2-yr-old child who was scheduled for bronchoscopy because of atelectasis and pneumonic infiltrates. Unfortunately, the pediatric bronchoscope (3.4 mm OD) could not pass easily through a 4-mm endotracheal tube. He tried to perform the procedure *via* a size 2 laryngeal mask airway (7.0 mm ID), which was technically feasible, but low lung compliance made mechanical ventilation difficult, and, after a decrease in  $\text{SpO}_2$  to 85%, intermittent jet ventilation of oxygen *via* the instrument channel ensured adequate oxygenation.

These latter two reports imply that the technique can be used safely even in patients with ventilatory compromise.<sup>4,5</sup> Although they involved children, we believe that the principles involved may be equally applicable in certain situations in the adult.

One of the obvious risks of this approach is the potential for inadvertently causing barotrauma if the tip of the FFB slips beyond the carina and "wedges" in a bronchus. The added advantage of jetting *via* the instrument channel of the FFB is that the position of the jet source can be directly controlled visually, thus enhancing the safety of the procedure. Excessive hyperinflation must be avoided also, and effective exhalation must be ensured. The FFB OD is 5.8 mm, whereas the narrowest lumen diameter of the normal tracheal segments was measured by computed tomography as 15 mm. Therefore, difficulties with exhalation are more likely to originate at laryngeal or upper airway level and can be minimized by ensuring a clear airway. If gas trapping is still a feature, it is easily

recognized clinically and can be managed simply by intermittent interruption of jet ventilation.

Another risk, albeit theoretical, that should be considered is the possibility of direct damage to the FFB. The instrument channel in this type of FFB is a polytetrafluoroethylene tube and is unlikely to be damaged if it remains patent. In addition, the risk that the channel could be blocked so tightly that it could lead to a rupture is negligible.

Although the indications for jet ventilation *via* the instrument channel of an FFB may be rare, they are more likely to be applicable in a challenging situation and particularly in the presence of a difficult airway management problem. In this case report, the technique greatly facilitated the therapeutic procedure and enhanced its safety. In addition, it decreased the risk of inadvertent tracheal trauma caused by the need for frequent removal

and reinsertion of the FFB when applying face mask ventilation.

The authors thank Brian F. Keogh, M.D., F.R.C.A., Consultant Cardiothoracic Anaesthetist, The Royal Brompton Hospital, London, United Kingdom, for his most useful comments and assistance in preparing the manuscript.

## References

1. Dellinger RP: Fiberoptic bronchoscopy in critical care medicine, Textbook of Critical Care, 3rd edition. Edited by Shoemaker WC, Ayres SM, Grenvik A, Holbrook PR. Philadelphia, WB Saunders, 1995, pp 761-71
2. Atherton DP, O'Sullivan E, Lowe D, Charters P: A ventilation-exchange bougie for fiberoptic intubations with the laryngeal mask airway. *Anaesthesia* 1996; 51:1123-6
3. Satyanarayana T, Capan L, Ramanathan S, Chalon J, Turndorf H: Broncho-fiberscopic jet ventilation. *Anesth Analg* 1980; 59:350-4
4. Dalens B, Labbe A, Haberer JP: Respiratory assistance secured by jet-ventilation during broncho-fiberscopy in forty-nine infants. *ANESTHESIOLOGY* 1982; 57:551-2
5. Baraka A: Jet ventilation via the suction port during fiberoptic bronchoscopy in a child. *Paediatr Anaesth* 1997; 7:87-8