

Prolonged Coma after Unreamed, Locked Nailing of Femoral Shaft Fracture

Robert J. Byrick, M.D.,* Robert E. Korley, M.D.,† Michael D. McKee, M.D.,‡ Emil H. Schemitsch, M.D.§

USING transesophageal echocardiography, echogenic material can be shown in the right ventricle during many orthopedic procedures.¹ Recently, transcranial Doppler-recorded microembolic signals have been described during femoral fracture fixation, suggesting that medullary pressurization may be associated with systemic microembolism and pulmonary fat and marrow emboli.²

Although reamed, locked intramedullary nailing is the procedure of choice for most femoral shaft fractures, some investigators advocate the use of small-diameter, locking, unreamed nails to decrease the risk of fat emboli.^{3,4} We report a case of severe intraoperative fat embolism after an unreamed locked intramedullary nailing.

Case Report

A previously healthy 17-yr-old woman was injured on her right side by a motor vehicle. At arrival to our hospital, she was fully awake and alert. There was no evidence of head, chest, or abdominal injuries. She reported pain in the right thigh and the pelvis and had an 8-cm laceration on her right hip. Her heart rate was 130 beats/min (electrocardiography showed sinus tachycardia) and her respiratory rate was 24 breaths/min. Blood pressure was 115/75 mmHg. Laboratory investigations showed mild acidosis (pH: 7.32; partial pressure of carbon dioxide [P_{CO_2}]: 42 mmHg; partial pressure of oxygen [P_{O_2}]: 183 mmHg; fraction of inspired concentration of oxygen [FI_{O_2}]: 0.4) and hemoglobin concentration was 11.7 g/dl, with a platelet count of $357 \times 10^9/l$. Radiographs showed a stable lateral-compression-type pelvic fracture and a displaced, transverse, right femoral shaft fracture. Radiographs of cervical, thoracic, and lumbar sections of the spine were normal, as was the chest radiograph.

Fourteen hours after injury, oxygen saturation as measured by pulse oximetry (Sp_{O_2}) before induction of general anesthesia was 98% breathing oxygen ($FI_{O_2} = 0.5$). The patient was alert, cooperative, and recalled the accident and all events after injury (Glasgow Coma Scale = 15). Vital signs were normal; however, heart rate was 130 beats/min. Anesthesia was induced using midazolam, fentanyl citrate, and propofol. Tracheal intubation was facilitated using succinylcholine. The patient underwent ventilation using oxygen in air. Anesthesia was maintained with isoflurane, intravenous fentanyl, and morphine. Vecuronium was used to provide muscle relaxation.

The patient's hip laceration was irrigated and debrided. Using manual traction, the femoral fracture was reduced, and fixation was achieved using a titanium, unreamed AO femoral nail that was statically locked (9×380 mm; Synthes, Mississauga, Canada). The nail passed across the fracture site with minimal difficulty, and no guidewire or reaming was used. During passage of the nail across the fracture site, approximately three brief episodes of oxygen desaturation (Sp_{O_2} of 83%) were noted. Each episode was no longer than 3 min, and Sp_{O_2} returned to 98% ($FI_{O_2} = 1.0$). The P_{aO_2} value after one episode was 9 mmHg ($FI_{O_2} = 1.0$).

After surgery, the patient did not regain consciousness. At examination, she was unresponsive to pain and displayed Babinski reflexes bilaterally and generalized hyperreflexia, with increased tone in all extremities. No lateralizing neurologic findings were detected. Eight hours after surgery, she had a generalized tonic-clonic seizure, which lasted approximately 1 min. Electroencephalography showed slow wave activity that was consistent with moderate to severe encephalopathy. Computerized tomography (CT) was normal. Magnetic resonance imaging (MRI) was performed. The T2-weighted MRI images showed multiple punctate lesions in the subcortical white matter, the centrum semiovale, and the basal ganglia (fig. 1). Transesophageal echocardiography showed good ventricular function and no intracardiac defect, specifically no patent foramen ovale.

Within 24 hours of injury, the patient's hemoglobin concentration decreased to 78 g/l and platelet count was $131 \times 10^9/l$. Chest radiography showed bilateral, ill-defined pulmonary infiltrates. A pulmonary artery catheter was inserted, and the occluded pressure was 12 mmHg and pulmonary artery pressure was 43/25 mmHg. No petechiae were noted. The patient was comatose and required ventilatory support. She had a low-grade fever without evidence of infection. Respiratory function improved over 4 days, with minimal change in neurologic status. On day 6 after surgery, her neurologic state improved (Glasgow Coma Scale = 6). She was extubated 16 days after surgery and was able to answer questions by gesturing (Glasgow Coma Scale = 11). Twenty-six days after injury, the patient was discharged to a rehabilitation hospital.

Five months later, neurologic function was steadily improving (Glasgow Coma Scale = 15), and she had returned to school. The family noted significant personality and cognitive changes and limited conversational skills. Another MRI was performed. The T2-weighted images (fig. 2) showed resolution of the hyperintense focal subcortical lesions; however, a diffuse periventricular white matter abnormality was noted. The femoral fracture healed uneventfully.

Discussion

Although intraoperative cardiovascular collapse and death has been reported in one case of prophylactic femoral nailing,⁵ we report a case of intraoperative cerebral microembolism after unreamed intramedullary rod fixation. The classic triad of fat embolism syndrome consists of respiratory distress, neurologic dysfunction, and petechial rash.⁶ Factors that determine the "intravasation" of marrow products into the venous circulation

* Professor, Department of Anaesthesia, † Medical Student, ‡ Assistant Professor, § Associate Professor, Division of Orthopedic Surgery.

Received from the Department of Anaesthesia and the Division of Orthopedic Surgery, St. Michael's Hospital, University of Toronto, Ontario, Canada. Submitted for publication April 11, 2000. Accepted for publication July 25, 2000. Support was provided solely from institutional and/or departmental sources.

Address reprint requests to Dr. Byrick: Department of Anaesthesia, St. Michael's Hospital, 30 Bond Street, Toronto, Ontario, Canada, M5B 1W8. Address electronic mail to: robert.byrick@utoronto.ca. Individual article reprints may be purchased through the Journal Web site, www.anesthesiology.org.

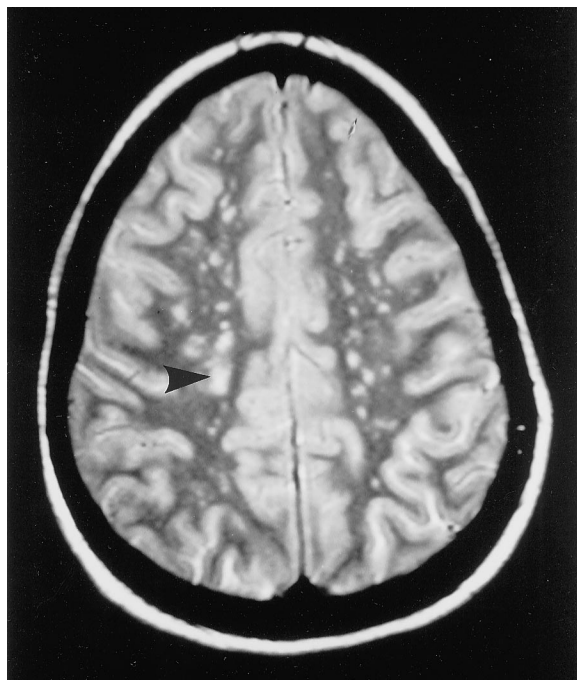


Fig. 1. Scans of T2-weighted magnetic resonance imaging performed within 24 h of surgery and showing widespread hyperintense lesions in subcortical white matter (arrow).

include disruption of the medullary contents, pressurization of the marrow cavity, and the availability of open vessels. These factors are present during intramedullary rod fixation.

In this case, intraoperative hypoxemia and hypotension were transient and do not explain the profound and lasting neurologic and cognitive dysfunction. Although preoperative desaturation suggested fat embolism syndrome, no neurologic findings were detectable before anesthesia. In fat embolism syndrome, patients may have focal neurologic signs or generalized encephalopathy (confusion, seizures, coma).⁷ No intracardiac defect was found; however, paradoxical emboli can occur through a patent foramen ovale.⁸ In this patient, transpulmonary passage of fat occurred. This has been shown in animal models in which cerebral intravascular fat also is found.⁹

The advantages of the interlocking of nails in the treatment of diaphyseal femoral fractures are well-established. However, one of the complications of intramedullary nailing includes embolization of marrow contents, and unreamed femoral nails are advocated to minimize this risk because of the resultant reduction in intramedullary pressure.⁴ Medullary pressurization and embolization depend on surgical factors, such as the velocity of nail insertion or the gap between nail and cortical bone when entering the distal fragment.³ Our case emphasizes that, although there may be a reduced incidence, severe fat embolism can occur when unreamed, locked femoral nails are used.

Neither the degree nor the duration of hypoxemia in this case would be expected to cause severe cerebral

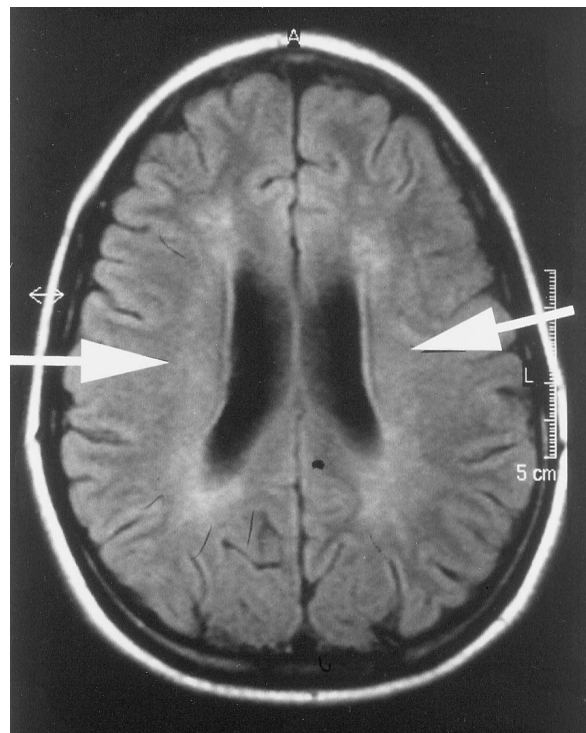


Fig. 2. Scans of T2-weighted magnetic resonance imaging performed 5 months after injury and showing persisting diffuse periventricular abnormalities.

injury in a young patient. It is important to emphasize that MRI is necessary to show the characteristic cerebral lesions in the acute stage of fat embolism syndrome. The CT scan in such cases is normal.¹⁰ The distribution of lesions shown during MRI (fig. 1) is characteristic and suggests transpulmonary microemboli, with resultant acute perivascular edema. Takahashi *et al.*¹¹ characterized the lesions seen during MRI after cerebral fat embolism as high intensity signals located in areas of brain that are perfused by perforating arteries. Their disappearance during subsequent MRI, coincident with resolution of the neurologic signs and symptoms, emphasized the clinical importance.¹¹ Six of 11 patients in the study became alert within 10 days; however, one patient had severe, persisting neurologic impairment for 2 months (55 days), with persistent abnormalities seen during MRI. In our patient, the first MRI scan (fig. 1) showed characteristic hyperintense lesions, suggesting focal perivascular edema. Five months after injury, the patient had marked neurocognitive deficits, and MRI (fig. 2) showed lasting signal intensity abnormalities and morphologic lesions. The characteristic MRI pattern had changed to a nonspecific pattern, consistent with diffuse periventricular ischemic injury. This emphasizes that the microvascular lesions in the acute phase can result in long-term neurologic impairment.

The authors thank Dr. Walter Kucharzyk, Professor, Chairman, Department of Diagnostic Imaging, University of Toronto, for advice and review of the MRI scans.

References

1. Ereth, MH, Weber JG, Abel MD, Lennon RL, Lewallen DG, Ilstrup DM, Rehder K: Cemented versus noncemented total hip arthroplasty—Embolism, hemodynamics, and intrapulmonary shunting. *Mayo Clin Proc* 1992; 67:1066-74
2. Forteza AM, Koch S, Romano JG, Zych G, Bustillo IC, Duncan RC, Babikian VL: Transcranial Doppler detection of fat emboli. *Stroke* 1999; 12:2687-91
3. Wenda K, Runkel M, Degrief J, Ritter G: Pathogenesis and clinical relevance of bone marrow embolism in medullary nailing demonstrated by intraoperative echocardiography. *Injury* 1993; 24(suppl):S73-81
4. Kropfl A, Berger U, Neureiter H, Hertz H, Schlag G: Intramedullary pressure and bone marrow fat intravasation in unreamed femoral nailing. *J Trauma* 1997; 42(5):946-54
5. Peter E, Schopfer A, Le Coultre B, Hoffmeyer P: Fat embolism and death during prophylactic osteosynthesis of a metastatic femur using an unreamed femoral nail. *J Orthop Trauma* 1997; 3:233-4
6. Gurd AR: Fat embolism: An aid to diagnosis. *J Bone Joint Surg Br* 1974; 52B:732-7
7. Jacobson DM, Terrence CF, Reinmuth OM: The neurologic manifestations of fat embolism. *Neurology* 1986; 36:847-51
8. Pell, ACH, Hughes D, Keating J, Christie J, Busuttill A, Sutherland GR: Brief report: Fulminant fat embolism syndrome caused by paradoxical embolism through a patent foramen ovale. *N Engl J Med* 1993; 329:926-9
9. Byrick RJ, Mullen JB, Mazer CD, Guest CB: Transpulmonary systemic fat embolism: studies in mongrel dogs after cemented arthroplasty. *Am J Respir Crit Care Med* 1994; 150:1416-22
10. Satoh H, Kurisu K, Ohtani M, Arita K, Okabayashi S, Nakahara T, Migita K, Iida K, Kuroki K, Ohbayashi N: Cerebral fat embolism studied by magnetic resonance imaging, transcranial Doppler sonography and single photon emission computed tomography: Case report. *J Trauma* 1997; 43:345-8
11. Takahashi M, Suzuki R, Osakabe Y, Asai JI, Miyo T, Nagashima G, Fujimoto T, Takahashi Y: Magnetic resonance imaging findings in cerebral fat embolism: Correlation with clinical manifestations. *J Trauma* 1999; 46:324-7

Anesthesiology 2001; 94:165-7

© 2001 American Society of Anesthesiologists, Inc. Lippincott Williams & Wilkins, Inc.

Potential Damage to the Larynx Associated with Light-guided Intubation: A Case and Series of Fiberoptic Examinations

Kazuyoshi Aoyama, M.D.,* Ichiro Takenaka, M.D.,† Etsuko Nagaoka, M.D.,‡ Tatsuo Kadoya, M.D.,§ Takeyoshi Sata, M.D.,|| Akio Shigematsu, M.D.#

A lighted stylet is a useful device for routine or difficult endotracheal intubation.¹⁻³ With light-guided intubation, the incidence of complications is reported to be low, but the larynx can be injured during the blind advancement of the endotracheal tube.¹ We report a case in which malpositioning of the epiglottis occurred after tracheal intubation with a lighted stylet, and difficulty was encountered in replacing the displaced epiglottis. This case prompted us to observe closely a series of intubations by use of a light wand.

Case Report

A 78-yr-old, 150-cm, 64-kg woman with sternal osteomyelitis was scheduled for curettage of a lesion. Preanesthetic examination showed Mallampati class 2 airway. After induction of anesthesia and muscle relaxation, an experienced anesthesiologist performed orotracheal intubation with use of a 7.5-mm ID endotracheal tube using a lighted stylet (Trachlight, Laerdal Medical, Armonk, NY). This was performed using the standard method,⁴ with the patient's head and neck extended and the jaw thrust. During tube advancement, the operator felt the tube tip touch something slightly, and then proper transillumination of the soft tissues of the neck immediately was seen below the

thyroid prominence. The Trachlight was removed, and placement of the endotracheal tube was confirmed by use of capnography and auscultation. After the tube was secured, a fiberscope-video camera system was passed into the nasopharynx⁵ to examine the supraglottic airway. Fiberscopy showed that the epiglottis was partially pushed into the laryngeal inlet, along with the endotracheal tube (fig. 1). We unsuccessfully attempted to restore the epiglottis to the correct position using a laryngoscope and Magill forceps for 10 min. We then extubated the trachea and replaced the endotracheal tube during video visual control.⁵ The epiglottis was seen to be in the normal position. The patient reported a slight sore throat the next day.

Methods

After institutional approval and written informed consent was obtained, we fiberoptically observed the advancement of the endotracheal tube during light-guided intubation⁶ in 20 patients. After anesthetic induction and paralysis, an assistant inserted a fiberoptic bronchoscope attached to a video camera monitoring system into the nasopharynx⁵ before intubation. An experienced anesthesiologist performed routine orotracheal intubation using a Trachlight. Endotracheal tubes with 7.5 mm ID were used for female patients and those with 8.0 mm ID were used for male patients. The operator advanced the tube gently, and when a resistance was felt or a glow was seen at an improper location, the tube tip was withdrawn backward and redirected. The assistant recorded the location where the tube advanced and whether the tube came in contact with the laryngeal structures. If the operator felt a resistance, the assistant recorded this information. The time to intubation also was measured.

Results

Nine men and 11 women were studied (mean age, 65 ± 12 yr; mean weight, 56 ± 9 kg [mean ± SD]).

* Chief Anesthesiologist, ‡ Staff Anesthesiologist, Department of Anesthesia, Moji Rosai Hospital. † Staff Anesthesiologist, § Chief Anesthesiologist, Department of Anesthesia, Nippon Steel Yawata Memorial Hospital. || Associate Professor, # Professor, Department of Anesthesiology, University of Occupational and Environmental Health, Japan.

Received from the Departments of Anesthesia, Moji Rosai Hospital, Kitakyushu, Japan; Nippon Steel Yawata Memorial Hospital, Kitakyushu, Japan; and the Department of Anesthesiology, University of Occupational and Environmental Health, Japan, Kitakyushu, Japan. Submitted for publication January 31, 2000. Accepted for publication August 3, 2000. Support was provided solely from institutional and/or departmental sources.

Address reprint requests to Dr. Aoyama: Department of Anesthesia, Moji Rosai Hospital, 3-1 Higashi-minatomachi, Moji-ku, Kitakyushu, 801-0853 Japan. Address electronic mail to: aoyamak@mojih.rofuku.go.jp. Individual article reprints may be purchased through the Journal Web site, www.anesthesiology.org.

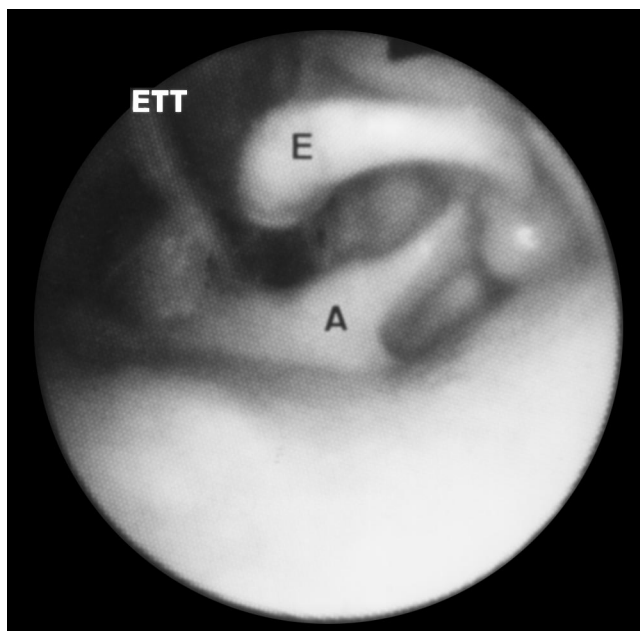


Fig. 1. Fiberoptic view of the larynx showing the incorrect position of the epiglottis after light-guided intubation. The epiglottis (E) is partially pushed into the laryngeal inlet, along with the endotracheal tube (ETT). The epiglottis is folded down and displaced laterally. A = arytenoid cartilage (right).

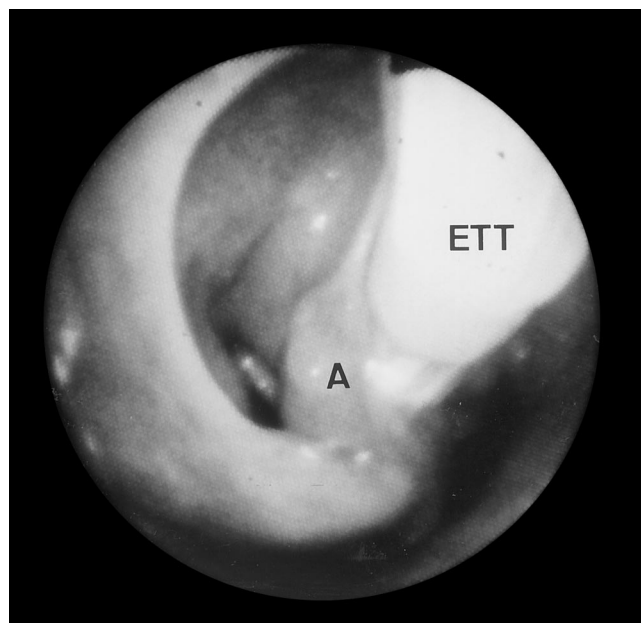


Fig. 2. Fiberoptic view of the larynx during probing in the pharynx with a light wand. The right arytenoid cartilage (A) is markedly displaced by the endotracheal tube (ETT). The operator could not detect this displacement because a glow was not seen in the neck and resistance was not felt. The tube tip was redirected, and intubation was accomplished.

Rapid tracheal intubation was successful in all patients. Fiberscopy showed that the epiglottis was lifted from the posterior pharyngeal wall by use of a jaw thrust maneuver before intubation. In nine patients (45%), the endotracheal tube tip was advanced into the trachea without making contact with the laryngeal structures. In 11 patients (55%), the tube tip came in contact 13 times with the laryngeal structures at some point during intubation (table 1). In four occurrences of contact, the operator either felt resistance or saw the glow in an improper location; however, in nine occurrences of contact, the operator could not notice the contact or could not detect the incorrect tube position. In two cases in which the tube tip made contact with the epiglottis, the tube

pushed the epiglottis into the laryngeal inlet during tube advancement; however, the epiglottis returned to the correct position. No resistance was felt in these instances. In two cases, during probing in the pharynx with use of a light wand, the tube tip markedly displaced the arytenoids, and the operator did not feel resistance (fig. 2). In two cases, although the glow was seen in the correct location, the forward advancement of the tube was halted after the stiff inner stylet was retracted. Fiberscopy showed that the tube collided with the anterior commissure. In one of the cases, the tube slipped and entered the glottis after the tube was rotated. In another case, the tube and Trachlight were withdrawn and intubation was successful on the second attempt.

Table 1. The Site of Contact of the Endotracheal Tube during Light-guided Intubation and the Detection of the Contact

	Site of Contact				Glow	Resistance	Progress of the Tube
	Epiglottis (n = 6)	Vallecula (n = 2)	Arytenoids (n = 3)	Anterior Commissure (n = 2)			
Detectable	2	2			Improper or not seen	(+)	The tube was redirected.
Undetectable	4*		1		Not seen†	(-)	The tube slipped off and entered the glottis.
			2		Not seen	(-)	The tube displaced the structure, and the tube was redirected.
				2		Proper	(+)

The number of contacts is shown. There were 13 contacts of the endotracheal tube with the laryngeal structures in 11 patients.

* Transient folding of the epiglottis was noted in two of these patients. † The glow was not seen when the tube tip hit the structures, and the proper glow was observed when the tube entered the glottis.

Discussion

The current case report shows that incorrect positioning of the epiglottis can occur during light-guided intubation, and is difficult to restore. In this case, the tube probably pushed the epiglottis into the laryngeal inlet during tube advancement; however, we thought the intubation was successful because proper transillumination was immediately observed. We did not advance the tube forcefully. A similar event was encountered in our formal study. Our study confirmed that, without the operator feeling resistance, the tube could push the epiglottis into the laryngeal inlet; however, in both cases observed during our prospective study, the epiglottis spontaneously returned to the correct position. A displaced epiglottis might not return to its original position depending on the size and elasticity of the epiglottis, on the size of the endotracheal tube, and on the degree of the folding of the epiglottis. Fortunately, we detected this complication early and restored the displaced epiglottis to the proper position. However, further complications would have developed, such as edema, circulatory disturbance, or mechanical damage to the epiglottis, if the malposition of the epiglottis had remained unnoticed. We reported a case of a similar malposition of the epiglottis during blind intubation through the intubating laryngeal mask, which resulted in edema of the epiglottis.⁷

Our study suggests that there are potential risks of laryngeal damage in addition to the down-folding of the epiglottis. If the operator detects resistance or sees a glow in an improper location when the tube makes contact with the laryngeal structures, the tube is redirected and damage can be avoided. However, the tube

tip could displace the arytenoid cartilages markedly even though resistance could not be felt because the tissues are soft, floppy, and relaxed. If the operator continues to advance the tube forcefully, injury to the arytenoid cartilages may occur.^{8,9} When the tube makes contact with the anterior commissure, tube position may be judged as adequate because the glow was seen in the correct location. The tube may slip when the tube is rotated⁴; however, forceful advancement and multiple attempts should be avoided to avert damage to the vocal cords.

References

1. Hung OR, Pytka S, Morris I, Murphy M, Launcelott G, Stevens S, MacKay W, Stewart RD: Clinical trial of a new lightwand device (Trachlight) to intubate the trachea. *ANESTHESIOLOGY* 1995; 83:509-14
2. Hung OR, Pytka S, Morris I, Murphy M, Stewart RD: Lightwand intubation. II. Clinical trial of a new lightwand for tracheal intubation in patients with difficult airways. *Can J Anesth* 1995; 42:826-30
3. Ellis DG, Jakymec A, Kaplan RM, Stewart RD, Freeman JA, Bleyaert A, Berkebile PE: Guided orotracheal intubation in the operating room using a lighted stylet: A comparison with direct laryngoscopic technique. *ANESTHESIOLOGY* 1986; 64:823-6
4. Hung OR, Stewart RD: Illuminating stylet (Lightwand), *Airway Management: Principles and Practice*. Edited by Benumof JL. St. Louis, Mosby, 1995, pp 342-52
5. Aoyama K, Takenaka I, Sata T, Shigematsu A: Use of the fibrescope-vidé camera system for difficult tracheal intubation. *Br J Anaesth* 1996; 77:662-4
6. Yamamoto T, Aoyama K, Takenaka I, Kadoya T, Uehara H: Light-guided tracheal intubation using a Trachlight: Causes of difficulty and skill acquisition. *Masui* 1999; 48:672-7
7. Takenaka I, Aoyama K, Nagaoka E, Seto A, Nijima K, Kadoya T: Malposition of the epiglottis after tracheal intubation via the intubating laryngeal mask. *Br J Anaesth* 1999; 83:962-3
8. Sziget CL, Baeuerle JJ, Mongan PD: Arytenoid dislocation with lighted stylet intubation: Case report and retrospective review. *Anesth Analg* 1994; 78:185-6
9. Debo RF, Colonna D, Dewerd G, Gonzalez C: Cricoid arytenoid subluxation: Complication of blind intubation with a lighted stylet. *Ear Nose Throat J* 1989; 68:517-20

Anesthesiology 2001; 94:167-9

© 2001 American Society of Anesthesiologists, Inc. Lippincott Williams & Wilkins, Inc.

Anesthetic Management of a Parturient with Superior Vena Cava Obstruction for Cesarean Section

Yoo K. Chan, F.F.A.R.C.S.I.,* Kwee P. Ng, F.A.N.Z.C.A.,† Chiaw L. Chiu, F.R.C.A.,‡ Gopalakrishnan Rajan, M.B.B.S.,‡ Khong C. Tan, M.B.B.S.,§ Yew C. Lim, F.R.C.S.¶

SUPERIOR vena cava (SVC) obstruction is rare and usually complicates tumors in the mediastinum.¹ It may affect the venous drainage of the airway, leading to shortness of breath, stridor, and cough, which may worsen with the extension of the mass into the anterior

mediastinum. The detailed management of SVC obstruction in a parturient has not been reported in the anesthetic literature. We report treatment of a parturient who presented for delivery of a neonate at 34 weeks' gestation, with SVC obstruction syndrome with anterior mediastinal extension of a tumor.

* Associate Professor, † Lecturer, ‡§ Medical Officer, Department of Anaesthesia, ¶ Professor, Department of Surgery.

Received from the Departments of Anaesthesia and Surgery, Faculty of Medicine, University of Malaya, Kuala Lumpur, Malaysia. Submitted for publication February 21, 2000. Accepted for publication August 7, 2000. Support was provided solely from institutional and/or departmental sources.

Address reprint requests to Dr. Chan: Department of Anaesthesia, Faculty of Medicine, University of Malaya, Lembah Pantai, 59100 Kuala Lumpur, Malaysia. Address electronic mail to: chanyk@medicine.med.um.edu.my. Individual article reprints may be purchased through the Journal Web site, www.anesthesiology.org.

Case Report

A 35-yr-old woman (gravida 4 para 1) with SVC obstruction was referred for anesthetic assessment at 32 weeks' gestation. Medical history included an above-knee amputation of the left leg 4 yr previously for a malignant schwannoma and metastatic lesions in the upper lobe of the left lung 2 years after the amputation. She was orthopneic

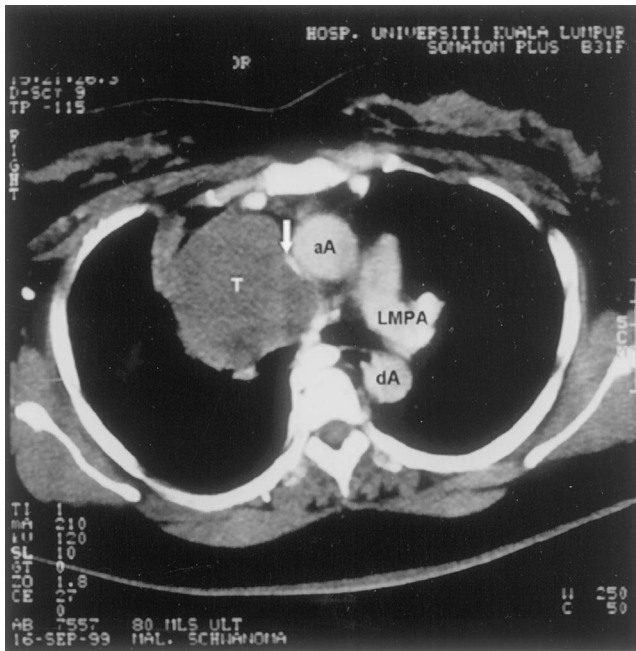


Fig. 1. Computed tomographic scan of the thorax at the level of the superior vena cava. The superior vena cava (indicated by white arrow) is narrowed and compressed by the tumor. T = tumor; aA = ascending aorta; dA = descending aorta; LMPA = left main pulmonary artery.

and had distended neck veins, but air entry was normal in both lungs. Chest radiography showed a widened mediastinum with a mass taking up half the right hemithorax. Computed tomography also showed a mass in the paratracheal region that was compressing the SVC (fig. 1). Arterial blood gas while the patient was breathing room air showed a respiratory alkalosis with hypocapnia (pH 7.58, partial pressure of carbon dioxide [P_{CO_2}] = 28.9 mmHg, partial pressure of oxygen [P_{O_2}] = 97.3 mmHg, bicarbonate [HCO_3^-] = 27 mm, base excess = 6.9).

A course of radiotherapy was attempted to shrink the tumor, but after 3 cycles over 2 weeks, severe orthopnoea and hypoxia developed (pH 7.38, P_{CO_2} = 30.9 mmHg, P_{O_2} = 48.0 mmHg, HCO_3^- = 18.9, base excess = -5.4 with room air), and radiotherapy was discontinued. The patient was propped up and administered dexamethasone and 35% oxygen *via* mask, which partially alleviated her symptoms. Because of the presence of metabolic acidosis, the decision was made to expedite the delivery of the neonate *via* cesarean section.

An epidural anesthetic was planned, with the cardiothoracic surgeon standing by and the cardiopulmonary bypass pump readily accessible. Intravenous access was secured on the right foot and left hand. Baseline blood pressure, measured *via* right radial artery cannulation was 140/90 mmHg, pulse was 120 beats/min, and pulse oximeter reading was 99% with 35% oxygen by mask. After insertion of the epidural catheter while the patient was in the sitting position and administration of 3 ml bupivacaine, 0.5%, she was laid supine with a head-up tilt of 30°. While establishing an adequate anesthetic level, the cardiothoracic surgeon prepared the left femoral vessels for immediate cannulation, if necessary. Fractionated boluses of 0.5% epidural bupivacaine to a total of 12 ml achieved a block to T4-T6. The cesarean section was uneventful and resulted in the delivery of a 2-kg girl infant, with an Apgar score of 9/10 at 1 and 5 min. Blood pressure was well maintained with a minimum of 90/55 mmHg and titration of ephedrine boluses was necessary to a total of 47.5 mg, with infusion of 500 ml Ringer's lactate and 500 ml Gelafundin (a polymerasate of degraded succinylated gelatin, with mean molecular weight 35,000; B. Braun Pharmaceutical Industries, Penang, Malaysia).

Postoperatively, the patient was administered 5,000 U subcutaneous heparin twice daily for 5 days. Respiratory distress improved, and by the second postoperative day arterial blood gas was normal for breathing room air. The patient was discharged on the sixth postoperative day and was last seen 6 months later, by which time she had undergone a sixth course of chemotherapy; she is symptom free.

Discussion

Numerous reports stress the high mortality and morbidity²⁻⁶ associated with general anesthesia in patients with SVC syndrome. In part, this is caused by partial or total airway obstruction and inability to perform ventilation for the patient.⁷ With this and the well-being of the fetus in mind, we considered regional anesthesia to be a better alternative for this patient. Spinal anesthesia was ruled out because rapid sympathectomy and hemodynamic decompensation might have been disastrous because of obstructed venous return from the upper extremities, caused by the mediastinal mass and from the lower extremities by the gravid uterus. Continuous spinal anesthesia and combined spinal-epidural anesthesia were rejected because little is known about the dynamics of intrathecal distribution of local anesthetics in patients with SVC and inferior vena cava obstruction. Epidural anesthesia was thought to be the best option. The lower-than-usual dose of bupivacaine necessary to achieve a level of T4 was not unexpected. The decrease in blood pressure was managed successfully by titration of ephedrine and fluids.

In the event of an unsuccessful epidural, we planned to administer a general anesthetic *via* rapid-sequence induction with femoral-femoral access to institute immediate cardiopulmonary bypass if intubation or ventilation were not possible.^{5,8} Venous return to the heart from the upper limbs may be compromised in SVC syndrome. Hence, intravenous drugs and fluids were administered through the intravenous cannula on the right foot. The cannula in the left hand was placed inferior vena cava obstruction before delivery prevented venous return from the lower limbs. Intraarterial monitoring was essential to immediately detect and manage changes in blood pressure. Central venous pressure monitoring was not attempted because it would have been unreliable in the presence of SVC obstruction and would not have altered our choice of management.

We initially hoped to rely on options such as chemotherapy, radiotherapy, and steroid therapy to shrink the tumor mass^{2,9,10} before surgery to decrease the anesthetic risk of respiratory obstruction or cardiovascular decompensation. With respect to the effects on the fetus, radiotherapy was considered to be safer than chemotherapy. Unfortunately malignant schwannomas are not sensitive to radiotherapy or chemotherapy, and this option was not helpful in this particular case. In summary, the anesthetic management of a parturient with

SVC obstruction is presented herein, and the various methods to produce a safe outcome for parturient and fetus were discussed.

The authors thank B. J. Abdullah, F.R.C.R., Department of Radiology, Faculty of Medicine, University of Malaya, Kuala Lumpur, Malaysia, for interpreting the computed tomography scan.

References

- Bell DR, Woods RL, Levi JA: Superior vena caval obstruction: a 10 year experience. *Med J Aust* 1986; 145:566-8
- Tonnesen AS, Davis FG: Superior vena caval and bronchial obstruction during anesthesia. *ANESTHESIOLOGY* 1976; 45:91-2
- Todres ID, Reppert SM, Walker PF, Grillo HC: Management of critical airway obstruction in a child with a mediastinal tumour. *ANESTHESIOLOGY* 1976; 45:100-2
- Keon TP: Death on induction of anesthesia for cervical node biopsy. *ANESTHESIOLOGY* 1981; 55:471-2
- Goh MH, Liu XY, Goh YS: Anterior mediastinal mass: an anaesthetic challenge. *Anaesthesia* 1999; 54:670-82
- Northrip DR, Bohman BK, Tsueda K: Total airway occlusion and superior vena cava syndrome in a child with an anterior mediastinal tumour. *Anesth Analg* 1986; 65:1079-82
- Shapiro HM, Sanford TJ, Schaldach AL: Fiberoptic stylet laryngoscope and sitting position for tracheal intubation in acute superior vena caval syndrome. *Anesth Analg* 1984; 63:161-2
- Pullerits J, Holzman R: Anaesthesia for patients with mediastinal masses. *Can J Anaesth* 1989; 36:681-8
- Mackie AM, Watson CB: Anaesthesia and mediastinal masses: A case report and review of the literature. *Anaesthesia* 1984; 39:899-903
- Turoff RD, Gomez GA, Berjian R, Park JJ, Lawrence DD, Panahon A, Douglass HA Jr: Postoperative respiratory complications in patients with Hodgkin's disease: Relationship to the size of the mediastinal tumour. *Eur J Cancer Clin Oncol* 1985; 21:1043-6

Anesthesiology 2001; 94:169-70

© 2001 American Society of Anesthesiologists, Inc. Lippincott Williams & Wilkins, Inc.

A Warm Air Blanket Causes Intraoperative Airway Obstruction

R. David Warters, M.D.,* Charles Lee, M.D.,† Peter Szmuk, M.D.,‡ Tibi Ezri, M.D.§

THE safety of the anesthetized patient is facilitated by the use of many devices, such as standard monitors, eye tapes, warm air blankets, and heat moisture exchangers (HMEs). However, this myriad of ancillary devices occasionally may complicate airway management. We report a case of a foreign body causing a potentially lethal intraoperative airway obstruction.

Case Report

A 32-yr-old man was brought to the operating room 1 day after a 9-m fall for repair of a tile-C left hemipelvic disruption and a closed comminuted subtrochanteric fracture of the left proximal femur. History and physical examination showed that the man weighed 100 kg, had no previous medical problems, and had a class II airway. No hemodynamic or neurovascular derangements were noted. The patient was anesthetized with thiopental, fentanyl, and rocuronium and was intubated on the first attempt with an 8.0-mm ID endotracheal tube (ETT). Mechanical ventilation was initiated, and anesthesia was maintained with a mixture of N₂O in oxygen and isoflurane. A warm air blanket (Bair Hugger; Augustine Medical, Eden Prairie, MN) and an HME (Humid Vent; Lous Gilbeck AB, Upplands-Vasby, Sweden) were used to help decrease heat loss during the procedure.

After reduction of the hemipelvic disruption, preparations were made to transfer the patient to a fracture table for the femur repair. Fractional inspired oxygen was increased to 1.0 for several minutes before the transfer. Then, the circuit was disconnected from the HME, which remained connected to the ETT, and the patient was moved to the fracture table. The circuit was reconnected quickly, but the patient could not undergo ventilation as evidenced by the absence of chest movement and end-tidal carbon dioxide, a peak inspiratory pressure of more than 50 cm H₂O, and a tidal volume of less than 100 ml. Then,

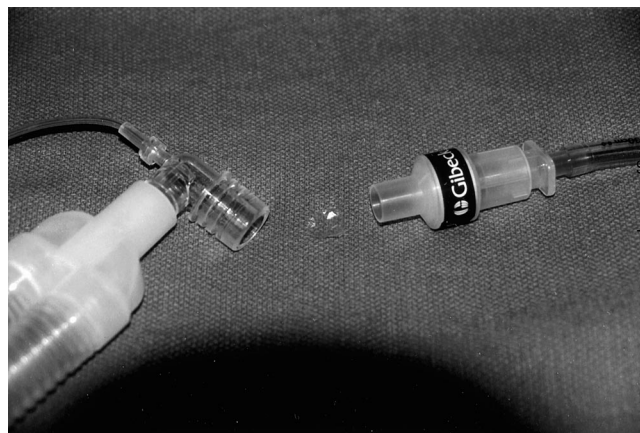

Fig. 1. A piece of plastic from a warm air blanket found lodged in a heat moisture exchanger.

ventilation was attempted vigorously with use of the reservoir bag without success. As oxygen saturation began to decrease, the circuit was disconnected from the ETT, and a suction catheter was advanced showing patency of the ETT lumen. While the circuit was disconnected, it was noted that the reservoir bag did not collapse. An Ambu bag was connected immediately to the ETT, the patient underwent ventilation easily, and oxygen saturation returned to 100%.

Subsequent examination of the circuit showed a piece of plastic from the warm air blanket (fig. 1) lodged in the HME. The plastic head drape apparently had become trapped between the circuit and the HME, resulting in a small piece being torn off and occluding the airway. After removal of the obstructing plastic piece, the circuit was reconnected, and surgery was resumed without further incident.

Discussion

Many cases of intraoperative airway obstruction have been reported in the literature.¹⁻⁵ Hosking *et al.*¹ have proposed a practical algorithm for the management of airway obstruction. The first step is for the patient to undergo manual ventilation with the reservoir bag to

* Associate Professor, †‡§ Assistant Professor, Department of Anesthesiology.

Received from the University of Texas-Houston Medical School, Houston, Texas. Submitted for publication May 12, 2000. Accepted for publication August 22, 2000. Support was provided solely from institutional and/or departmental sources.

Address reprint requests to Dr. Warters: Department of Anesthesiology, 6431 Fannin, #5.020, Houston, Texas 77030. Address electronic mail to: robert.d.warters@uth.tmc.edu. Individual article reprints may be purchased through the Journal Web site, www.anesthesiology.org.

remove the ventilator as a source of obstruction. If ventilation is performed easily, it is likely the fault lies within the ventilator. The second step, in the event of continued obstruction, should distinguish between circuit and ETT causes. ETT obstruction can be ruled out by passing a suction catheter or by successful direct ETT ventilation. If direct ETT ventilation is successful, then the circuit comes under suspicion. When the circuit and ETT have been eliminated as causes, patient sources of resistance, such as bronchospasm, pneumothorax, or pulmonary edema must be considered. In the current case, the ETT and the patient were eliminated as causes of obstruction when ventilation was restored by direct ETT ventilation.

In the current patient, disconnecting and subsequent reconnecting of the circuit trapped a piece of the warm air blanket within the HME, producing total obstruction of the airway. An HME was implicated previously in airway obstruction in an infant. In that case, a small piece of paper was caught in the HME, preventing effective ventilation.⁶

Anesthesiology 2001; 94:170-2

Various causes of airway obstruction exist in the operative environment. When an obstruction is recognized, a systematic approach to diagnosis and treatment must be implemented. Because of the wide variety of adjunct devices used by anesthesiologists, we must always be aware of the possibility of an obstructing foreign body.

References

1. Hosking MP, Lennon RL, Warner MA, Gray JR, Masley P, DeLuca, IA, Didier EF: Endotracheal tube obstruction: Recognition and management. *Mil Med* 1989; 154:489-91
2. Roy B, Barman B, Dutta C, Basu SM: An unusual foreign body obstructing endotracheal tube connector. *J Indian Med Assoc* 1995; 93:358
3. Uehira A, Tanaka A, Oda M, Sato T: Obstruction of an endotracheal tube by lidocaine jelly. *ANESTHESIOLOGY* 1981; 55:598-9
4. Bandy DP, Theberge DM, Richardson DD: Obstruction of naso-endotracheal tube by inferior turbinate. *Anesth Prog* 1991; 38:27-8
5. Bhargava M, Pothula SN, Joshi S: The obstruction of an endotracheal tube by the plastic coating sheared from a stylet: A revisit. *ANESTHESIOLOGY* 1998; 88:548-9
6. Casta A, Houck CS: Acute intraoperative endotracheal tube obstruction associated with a heat and moisture exchanger in an infant. *Anesth Analg* 1997; 84:939-40

© 2001 American Society of Anesthesiologists, Inc. Lippincott Williams & Wilkins, Inc.

Selective Lobar-Bronchial Blocking for Pediatric Video-assisted Thoracic Surgery

Masahiko Takahashi, M.D.,* Masahiro Yamada, M.D.,† Izumi Honda, M.D.,‡ Masato Kato, M.D.,§ Makoto Yamamuro, M.D.,|| Yasuhiko Hashimoto, M.D.#

FOR pediatric video-assisted thoracic surgery, surgical access has been conventionally accomplished by the total collapse of the ipsilateral lung *via* blocking^{1,2} or intubation^{3,4} of the selected main bronchus. However, single-lung ventilation includes possible detrimental effects on the physiologic conditions in small children.⁵ More selected exposure of the targeted intrathoracic space may decrease these risks.

Recently, we reported a newly devised double-access-portal endotracheal tube (DAPT) for pediatric one-lung anesthesia.⁶ The tube provides independent access for ventilation and bronchial blocking using a balloon-tipped catheter so that fiberoptic adjustment of the balloon position is possible during sufficient ventilation.

The current report describes the successful use of this device for selective lobar-bronchial blocking.

Case Reports

Case 1

A 5-yr 9-month-old boy (105 cm, 15.3 kg) was scheduled to undergo video-assisted correction of pectus excavatum. In this procedure, a large steel correcting bar is passed through the right middle intercostal space and advanced subinternally across the anterior mediastinum to the same intercostal space on the left side.⁷ To avoid complications, good exposure of the deformed substernal area that makes contact with the pericardium in the right intrathoracic cavity is necessary.

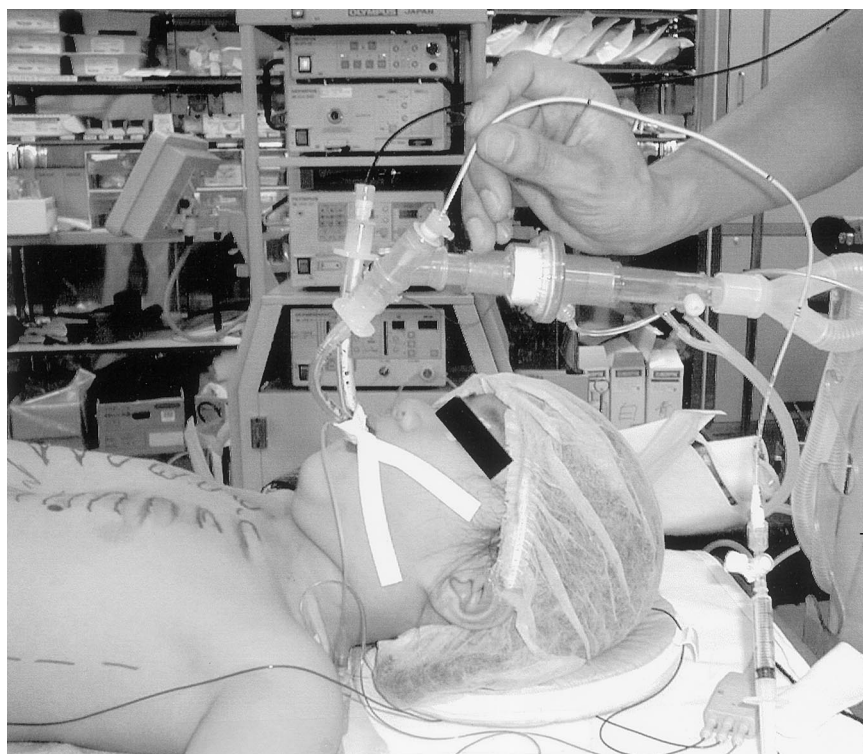
Anesthesia was induced using sodium thiopental, fentanyl, and vecuronium and maintained with oxygen, air, sevoflurane, fentanyl, and vecuronium. The patient's trachea was intubated with a 5.5-mm ID uncuffed DAPT, and ventilation was controlled *via* the main port of the DAPT. Subsequently, a 4-French Fogarty catheter (Fogarty Occlusion Catheter; Baxter Healthcare Co., Irvine, CA) was introduced through a Y connector (Bodai Swivel Y; Sontek Medical Inc., Hingham, MA) on the ventilating port of the DAPT under the vision of a 2.2-mm OD fiberscope (Olympus LF-P; Olympus Optical Co. Ltd., Tokyo, Japan) that was passed through the side port (fig. 1). To ensure airtightness, we used 8-French catheter sheathes (Radifocus, 2.5-mm ID; Terumo Co. Ltd., Tokyo, Japan) with slitted rubber caps on both access ports. The balloon of the Fogarty catheter was advanced and placed at the right bronchus intermedius (between the orifice of the upper and middle lobar bronchi, fig. 2). The inflation of the balloon with 1.3 ml air provided good surgical access to the substernal area with the

* Assistant Professor, †‡ Clinical Fellow, § Associate Professor, || Professor, # Professor and Chairman, Department of Anesthesiology and Emergency Medicine.

Received from the Department of Anesthesiology and Emergency Medicine, Tohoku University Postgraduate Medical School, Sendai, Japan. Submitted for publication June 19, 2000. Accepted for publication August 31, 2000. Support was provided solely from institutional and/or departmental sources.

Address reprint requests to Dr. Takahashi: Department of Anesthesiology and Emergency Medicine, Tohoku University Postgraduate Medical School, 1-1 Seiryō, Aoba-ku, Sendai 981-8574, Japan. Address electronic mail to: m-takaha@mail.cc.tohoku.ac.jp. Individual article reprints may be purchased through the Journal Web site, www.anesthesiology.org.

Fig. 1. The positioning of a 4-French Fogarty balloon in a selected lobar bronchus *via* a double-access-port endotracheal tube (DAPT) during fiberoptic vision. Ventilation is accomplished *via* a Y connector on the main port of the DAPT. A flexible bronchofiberscope is passed through the side port. To ensure airtightness, 8-French catheter sheaths with slitted rubber caps are placed on both access ports.



deflation of the right middle and lower lobes. The duration of the lobar blocking was 34 min. No detrimental changes in hemodynamics or blood gases were observed during the period of lobar collapse. Before completion of the operation, the Fogarty catheter was removed and appropriate reinflation of the lobes was confirmed *via* thoracoscopic inspection. The bronchial wall where the balloon was placed was also confirmed to be intact before extubation. The repair was completed in 72 min without complications. The patient was discharged from the hospital 10 days after the procedure; cosmetic result was satisfactory.

Case 2

A 5-yr 6-month-old girl (113 cm, 18.6 kg) was scheduled to undergo thoracoscopic resection of a neurofibroma in the right lower posterior mediastinum. Anesthesia was induced using nitrous oxide and sevoflurane in oxygen and maintained with oxygen, air, sevoflurane, fentanyl, and vecuronium. Ventilation was controlled *via* a 5.0-mm ID cuffed DAPT. The patient's right middle and lower bronchi were blocked with the balloon of a 4-French Fogarty catheter using the same technique as in case 1. The exposure of the surgical area was excellent, and inflation of the right upper lobe did not disturb the surgical procedures. The duration of the selective lobar-bronchial block was 110 min. Ventilation of the left lung and the right upper lobe stabilized hemodynamics and oxygenation during the procedure. The operation was completed in 138 min. No lung-associated or other complications developed after the operation, and the patient was discharged 1 week after the procedure.

Discussion

Because of recent improvements in surgical and optical instruments, a more limited exposure rather than the total collapse of the ipsilateral lung may be sufficient for VATS in children. The current report showed two cases. We applied the described technique for blocking tar-

geted lobes in three other VATS cases, including a partial resection of the left lower lobe for a metastatic tumor (9 yr) and two patients (5 and 6 yr) with pectus excavatum. The exposure of the targeted thoracic cavity was excellent and sufficient for surgical access in each patient. There was no case in which the selective lobar collapse was aborted because of a critical depression in either hemodynamics or oxygenation. No serious lung-related complications were observed in the patients.

We used Fogarty catheters for blocking the selected bronchi. Advantages of using this catheter as a blocker include the variation of balloon sizes available and good controllability of the catheter tip with use of a guide wire. However, the lack of a suction port in the Fogarty

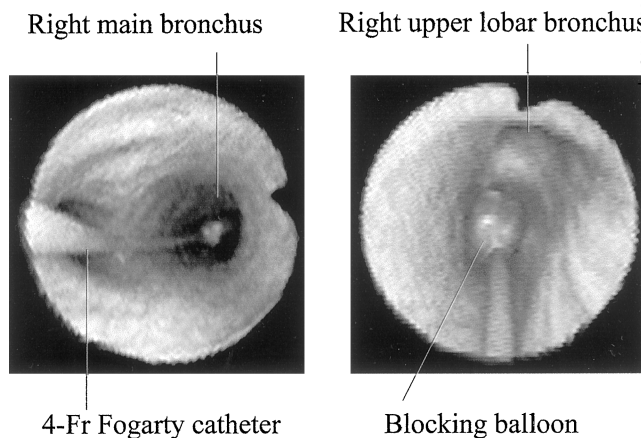


Fig. 2. The fiberoptic views of the blocking balloon in the bronchi. (Left) Tracheal view. (Right) Right bronchial view.

catheter impedes two important tasks during the selective bronchial blockade. First, rapid deflation of lobes is difficult when needed. We inflated the balloon in the end-expiratory phase, but often a certain period of time passed until complete collapse occurred by absorption atelectasis. Second, continuous positive airway pressure cannot be administered to the deflated lobes. This may increase the risk of hypoxemia and residual atelectasis; however, neither was observed in these patients.

The successful blocking of the desired lobes depends on the precise introduction and alignment of the blocker balloon. Using a DAPT fabricated by combining two conventional endotracheal tubes,⁶ we achieved the fiberoptic-aided introduction of a Fogarty catheter into a targeted bronchus without difficulty while maintaining sufficient ventilation. Manual preforming of the guidewire in the Fogarty catheter also facilitates control of the placement of the catheter tip. The simultaneous use of ventilation could reduce the risk of hypoxemia during block positioning and could allow for realignment of the balloon in the event of intraoperative dislocation.

In small children, the risk of bronchial injury as a result of balloon blocking should be considered. Therefore, the choice of an appropriate balloon size and inflation of the balloon using a minimal volume of air also are important. In our experience, a 4-French Fogarty balloon (maximum OD, 9 mm with 1.7 ml air) was suitable for blocking a selected bronchus in the 5- to 6-yr-old patients. In the 9-yr-old patient, however, because this size did not

block the left lower bronchus sufficiently, we switched to a 6-French catheter (maximum balloon OD, 13 mm) during the operation. For younger patients, a size smaller than 4-French may be necessary.

Minimal access thoracic and chest wall surgery has been performed in children and has provided great benefits, such as smaller incisions, improved cosmesis, decreased procedural pain, and shorter hospital stay duration.⁸ Video-assisted techniques have facilitated the use of these minimally invasive procedures. However, conventional one-lung anesthesia for these procedures is not ideal. The selective lobar-bronchial blocking described herein can reduce further the invasiveness of such procedures.

References

1. Vale R: Selective bronchial blocking in a small child. *Br J Anaesth* 1969; 41:453-4
2. Hogg CE, Lorhan PH: Pediatric bronchial blocking. *ANESTHESIOLOGY* 1970; 33:560-2
3. Watson CB, Bowe EA, Bruck W: One-lung anesthesia for pediatric thoracic surgery: A new use of the fiberoptic bronchoscope. *ANESTHESIOLOGY* 1982; 56:314-5
4. McGahren ED, Kern JA, Rodgers BM: Anesthetic techniques for pediatric thoracoscopy. *Ann Thorac Surg* 1995; 60:927-30
5. Tönz M, Bachmann D, Mettler D, Kaiser G: Pulmonary function after one-lung ventilation in newborns: The basis for neonatal thoracoscopy. *Ann Thorac Surg* 1998; 66:542-6
6. Takahashi M, Horinouchi T, Kato M, Hashimoto Y: Double-access-pore endotracheal tube for selective lung ventilation in pediatric patients. *ANESTHESIOLOGY* 2000; 93:308-9
7. Nuss D, Kelly RE Jr, Croitoru DP, Katz ME: A 10-year review of a minimally invasive technique for the correction of pectus excavatum. *J Pediatr Surg* 1998; 33:545-52
8. Rescorla FJ: Pediatric surgery. *J Am Coll Surg* 2000; 190:196-205