

Transcranial Doppler Ultrasonography as a Screening Technique for Detection of a Patent Foramen Ovale before Surgery in the Sitting Position

Ruediger Stendel, M.D.,* Hans-Joachim Gramm, M.D.,† Klaus Schröder, M.D.,‡ Conny Lober, C.S.,§ Mario Brock, M.D.||

Background: Venous air embolism has been reported to occur in 23–45% of patients undergoing neurosurgical procedures in the sitting position. If venous air embolism occurs, a patent foramen ovale (PFO) is a risk factor for paradoxical air embolism and its sequelae. Preoperative screening for a PFO is therefore recommended by some investigators. The reference standard for identifying a PFO is contrast-enhanced transesophageal echocardiography (c-TEE). Contrast-enhanced transcranial Doppler ultrasonography (c-TCD) and contrast-enhanced transthoracic echocardiography (c-TTE) are noninvasive alternative methods, but so far there are no studies as to their diagnostic validity in neurosurgical patients.

Methods: The sensitivity and specificity of c-TCD and c-TTE in detecting a PFO were determined in a prospective study using c-TEE as the reference standard. Preoperative c-TCD, c-TTE, and c-TEE studies were performed during the Valsalva maneuver after intravenous echo-contrast medium (D-Galactose, Echovist-300, Schering AG, Berlin, Germany) was administered in 92 consecutive candidates (47 men and 45 women; mean age, 51 yr; range, 25–72 yr) before neurosurgical procedures in the sitting position.

Results: A PFO was detected in 24 of the 92 patients (26.0%) using c-TEE. c-TCD correctly identified 22 patients, whereas c-TTE only correctly identified 10. This corresponds to a sensitivity of 0.92 for c-TCD and 0.42 for c-TTE. The negative predictive value was 0.97 for c-TCD compared with 0.83 for c-TTE. The prevalence of a PFO in patients with a posterior fossa lesion was 27%, and in the group with cervical disc herniation was 24% as detected by c-TEE. The incidence of intraoperative venous air embolism was 35% in cases of cervical foraminotomy and 75% in posterior fossa surgery as detected by c-TEE.

Conclusions: c-TCD is a highly sensitive and highly specific method for detecting a PFO. Because c-TCD is noninvasive, it may be more suitable than c-TEE for routine preoperative

screening for a PFO. C-TTE is not reliable in detecting a PFO. (Key words: Atrial septal defects; contrast echocardiography; neurosurgical procedure; paradoxical air embolism; venous air embolism.)

MANY neurosurgeons prefer the sitting position for neurosurgical procedures in the posterior fossa and in the cervical spine because it provides optimum access to midline lesions, improves cerebral venous drainage, lowers intracranial pressure, and promotes gravity drainage of blood and cerebrospinal fluid.¹ However, during procedures in the sitting position, venous air embolism (VAE) has been reported to occur in 23–45% of the patients, depending on the type of operation and the monitoring method used.^{2–4} VAE can cause a paradoxical air embolism in the presence of a right-to-left shunt, e.g., of a patent foramen ovale (PFO), and probably also by transpulmonary passage.^{5,6} Increases in pulmonary vascular resistance and right atrial pressure will predispose to paradoxical air embolism if VAE occurs. Paradoxical air embolism has been reported to occur in 14% of neurosurgical patients undergoing surgery in the sitting position and may result in serious, possibly fatal coronary and cerebral ischemic complications.⁷ Although the influence of screening a PFO preoperatively on the outcome after procedures in the sitting position has not been shown, its objective is to identify absolute and relative contraindications for the sitting position and to assess the individual risk-benefit ratio.¹

The reference standard for detecting a PFO is contrast-enhanced transesophageal echocardiography (c-TEE). However, this method is semi-invasive and uncomfortable for the patient. Furthermore, it cannot be used on children and in emergency situations. Although c-TEE is rarely associated with complications such as bleeding, aspiration, or esophageal perforation, when such complications occur, they may be severe.⁸

Contrast-enhanced transcranial Doppler ultrasonography (c-TCD) and contrast-enhanced transthoracic echocardiography (c-TTE) are alternative methods for detecting a PFO. However, their diagnostic validity has not yet been determined in neurosurgical patients.

The present study was designed to compare the sensitivity, specificity, and predictive values of c-TCD and c-TTE in the preoperative detection of PFO in a patient cohort scheduled for neurosurgical procedures in the sitting position.

Additional material related to this article can be found on the ANESTHESIOLOGY Web site. Go to the following address, click on Enhancements Index, and then scroll down to find the appropriate article and link. <http://www.anesthesiology.org>.

* Staff Neurosurgeon, || Professor and Chairman, Department of Neurosurgery, † Attending Physician, Department of Anesthesiology and Critical Care Medicine, ‡ Staff Cardiologist, § Cardiac Sonographer, Department of Cardiology and Pulmonology.

Received from the Departments of Neurosurgery, Anesthesiology and Critical Care Medicine, and Cardiology and Pulmonology, Benjamin Franklin Medical Center, Freie Universität Berlin, Berlin, Germany. Submitted for publication December 30, 1999. Accepted for publication May 2, 2000. Support was provided solely from institutional and/or departmental sources.

Address reprint requests to Dr. Stendel: Department of Neurosurgery, Benjamin Franklin Medical Center, Freie Universität Berlin, Hindenburgdamm 30, D-12200 Berlin, Germany. Address electronic mail to: stendel@medizin.fu-berlin.de. Individual article reprints may be purchased through the Journal Web site, www.anesthesiology.org.

Patients and Methods

Patients

The study protocol was approved by the institutional Committee on Medical Ethics. All patients gave their written, informed consent to participation in the clinical trial.

The prospective study comprised 92 consecutive patients (47 men, 45 women) with a mean age of 51 yr (range, 25–72 yr) who were to undergo neurosurgical procedures in the sitting position. Fifty-one patients (55.4%) were undergoing surgery for a lesion in the posterior fossa, and 41 patients (44.6 %) were undergoing surgery for a cervical disc herniation. All patients were submitted to c-TCD, c-TEE, and c-TTE 1 day before surgery and anesthesia.

Echo-contrast Medium

The echo-contrast medium (Echovist-300; Schering AG, Berlin, Germany) consists of D-galactose microspheres and generates air-filled microbubbles with a mean diameter of 5–6 μm after dissolution and agitation in sterile water. The only contraindication to the contrast medium is galactose intolerance. In Germany, the use of this echo-contrast medium is approved for children aged ≥ 6 yr and adults. As compared with agitated saline or gelatin solutions, this contrast agent offers a higher particle stability and a defined bubble size.

Valsalva Maneuver

The Valsalva maneuver was performed by maximal inspiration, followed by a forced expiration against the closed glottis, mouth, and nose for 5 s and then releasing and normal breathing for 2 min.

Contrast-enhanced Transcranial Doppler Ultrasonography

These studies were performed with the awake patient supine and the upper part of the body elevated by 30°. The equipment used was the Medasonics CDS (Medilab GmbH, Würzburg, Germany) with two 2-MHz transducers. The middle cerebral artery was insonated from both sides through the temporal window at a depth of 50 mm. The Valsalva maneuver was performed 5 s after intravenous injection of 10 ml of echo-contrast medium into the right cubital vein.^{9,10} The effectiveness of the Valsalva maneuver could be monitored by means of c-TCD by observing the increase in heart rate and the decrease in blood flow in the middle cerebral artery after the increase of intrathoracic pressure during inspiration, and the decrease in heart rate during the expiration phase of the Valsalva maneuver.

Contrast-enhanced Transthoracic Echocardiography

Contrast-enhanced transthoracic echocardiography was performed using a 2.5-MHz monoplane electrical

transducer and the Ultramark 9 (ATL Inc., San Diego, CA) with the awake patient lying on his or her left side and the upper part of the body elevated by 30°. No sedation was used. The heart was imaged in a four-chamber view. A 10-ml bolus dose of echo-contrast medium was injected into the right cubital vein. The Valsalva maneuver was performed 5 s after the injection of the echo-contrast medium.

Contrast-enhanced Transesophageal Echocardiography

Contrast-enhanced transesophageal echocardiography was performed using a 5-MHz monoplane electrical transducer and the Ultramark 9 (ATL Inc.) with the awake patient lying on his or her left side and the upper part of the body elevated by 30°. Local anesthesia of the pharynx was performed using lidocaine spray. Furthermore, the ultrasound probe was prepared with lidocaine gel 2%. In addition, agitated patients received a mild sedation with midazolam at a dosage of 0.5–1 mg intravenously. Scanning was performed along the short axis showing both atria. Ten milliliters of intravenous echo-contrast medium was injected into the right cubital vein. The Valsalva maneuver was performed 5 s after injection.

Contrast-enhanced transthoracic echocardiography, c-TEE, and c-TCD studies were repeated two times and performed consecutively within 3 h. In case of a PFO detection in only one or two of the three measurements, the result was considered positive.

Patent Foramen Ovale Criteria

A PFO was considered to be demonstrated by c-TTE and c-TEE when contrast medium crossed the atrial septum during the first 3–10 heart cycles (fig. 1A) in at least one examination. Although D-galactose echo-contrast medium normally does not “survive” transpulmonary passage, limitation to a maximum of 10 heart cycles (based on the normal circulatory transit time) ensured that the appearance of microbubbles in the left atrium is not caused by intrapulmonary shunting of contrast medium.¹¹ A PFO was considered to be demonstrated by c-TCD by means of acoustic and visual detection of unilateral or bilateral high-intensity transient signals caused by the contrast medium in the middle cerebral artery during the first 3–15 heart cycles (fig. 1B; refer to the Web enhancement for a video) in at least one examination.⁹ These high-intensity transient signals caused by the contrast medium are unilateral from the baseline, last 10–50 ms, occur randomly throughout the cardiac cycle, and are associated with typical acoustic signals.¹⁰

Contrast-enhanced transthoracic echocardiography and c-TEE were recorded on videotape for offline evaluation. c-TCD curves were stored on the Doppler computer system. The findings were analyzed independently by experienced investigators (c-TCD, R.S.; c-TTE, C.L.; c-TEE, K.S.) who were blinded to the results of the other tests.

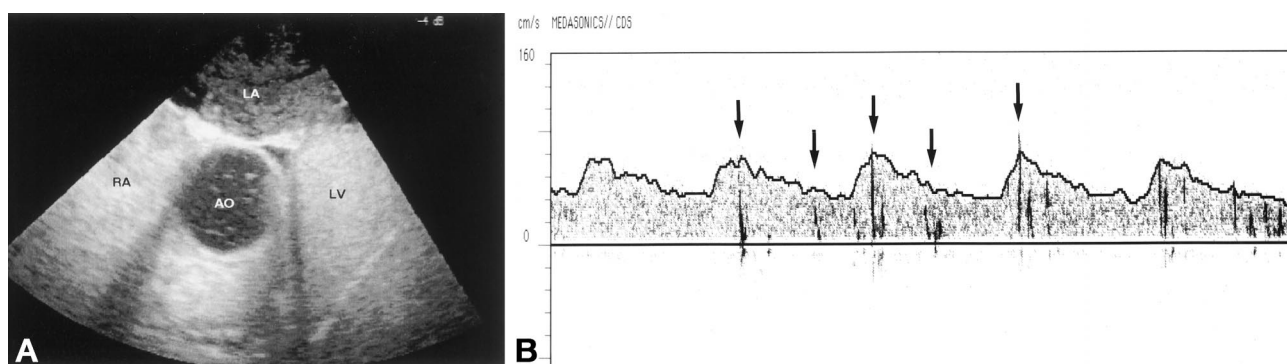


Fig. 1. (A) Atrial septal crossing of contrast medium during the Valsalva maneuver as detected by contrast-enhanced two-dimensional transesophageal echocardiography (c-TEE). RA = right atrium; LA = left atrium; AO = aorta; LV = left ventricle. (B) Visual detection of high-intensity transient signals caused by the presence of contrast medium (cm-HITS; arrows) in the middle cerebral artery in contrast-enhanced transcranial Doppler ultrasonography (c-TCD).

Anesthetic Management

Whenever a PFO was demonstrated by c-TEE, clinical management was altered either by choosing a different surgical position or extreme caution to prevent or stop aspiration of air. In the case of prolonged VAE, the patient was repositioned to reduce the height gradient between the right atrium and the surgical field. If necessary, the procedure was discontinued. Neuroanesthesia included routine continuous intraoperative TEE monitoring to detect VAE and paradoxical air embolism.⁷

Statistical Analysis

Sensitivity, specificity, and predictive values were calculated using standard equations. Differences between proportions were evaluated using a two-sided chi-square test. A *P* value < 0.05 was considered statistically significant.

Results

Contrast-enhanced transesophageal echocardiography revealed a PFO in 24 patients (26.0%). c-TCD identified 22 and c-TTE only 10 patients. The prevalence of a PFO in patients with a posterior fossa lesion was 27%, and in the group with cervical disc herniation was 24% as detected by c-TEE. In case of a PFO, the operative position was changed to the prone or park bench position in most patients with a posterior fossa lesion. There was no change in positioning in patients with PFO and cervical disc herniation.

A sensitivity of 0.92 for c-TCD and 0.42 for c-TTE was calculated using c-TEE as the gold standard. This difference between c-TTE and c-TEE was statistically significant (*P* < 0.05). There was no significant difference between the sensitivity of c-TCD and c-TEE. The specificity of c-TCD was 1, and the negative predictive value was 0.97. For c-TTE the specificity was likewise 1, and the negative predictive value was 0.83 (table 1). There were no different results from repeated c-TEE, c-TTE, and c-TCD measurements. The two patients with a pos-

itive c-TEE finding and a negative c-TCD result had only a small PFO with little crossover of contrast medium.

There were no side effects caused by the echo-contrast medium. No complications occurred during the c-TEE, c-TCD, or c-TTE studies. In the present study there was no case in which c-TCD could not be used because of an inadequate temporal bone window.

The incidence of intraoperative VAE was 35% in cases of cervical foraminotomy and 75% in posterior fossa surgery as detected by c-TEE. None of these patients developed paradoxical air embolism. In no patient was a PFO detected intraoperatively that had not been detected preoperatively.

Discussion

The presence of a PFO is not an uncommon finding. Autopsy studies have shown an overall prevalence of 27% in patients with no history of cardiac disease. This incidence decreases with age from 34% during the first three decades to 25% during the fourth to eighth decades of life.¹²

Contrast-enhanced transesophageal echocardiography combined with a standardized Valsalva maneuver is the reference standard for detecting a PFO because of its

Table 1. Diagnostic Characteristics of Contrast-enhanced Transcranial Doppler Ultrasonography (c-TCD), Contrast-enhanced Transthoracic Echocardiography (c-TTE), and Contrast-enhanced Transesophageal Echocardiography (c-TEE) in Detecting a Patent Foramen Ovale (PFO) before Operations in the Sitting Position

	c-TCD	c-TTE	c-TEE
PFO (%)	22 (23.9)	10 (10.8)*	24 (26.0)
Sensitivity	0.92	0.42*	1
Specificity	1	1	1
Positive predictive value	1	1	1
Negative predictive value	0.97	0.83	1

c-TEE was defined as the gold standard (n = 92, chi-square test).

* *P* < 0.05.

high sensitivity and specificity as compared with cardiac catheterization and autopsy.^{13,14}

The major disadvantages of TEE are its considerable technical and manpower requirements and the semi-invasive and uncomfortable nature of the method. The TEE probe could not be placed in 1.9% of the patients in a multicenter study by Daniel *et al.*⁸ comprising 10,419 patients. In 0.9% of the remaining patients, the study had to be discontinued because of the patient's inability to tolerate the TEE probe (0.6%) or because of pulmonary (0.07%), cardiac (0.07%), or hemorrhagic complications (0.02%). One of the latter was fatal. In summary, complications of TEE are rare but may be severe.

Contrast-enhanced transthoracic echocardiography and c-TCD are alternative modalities for PFO detection. The clinical application of Doppler ultrasound was first described by Gillis *et al.*¹⁵ for *in vivo* detection of circulating gas emboli during decompression sickness. Later it was also used for the noninvasive detection of middle cerebral artery air embolism during carotid endarterectomy and cardiopulmonary bypass.^{16,17} Based on these results, Teague and Sharma¹⁸ and Chimowitz *et al.*¹⁹ characterized c-TCD as an additional method for identifying patients with interatrial or intrapulmonary right-to-left shunts. c-TCD was found to be superior to c-TTE in detecting a right-to-left shunt. However, these studies were strongly limited by the absence of a reference standard.

In recent years, considerable interest has evolved in the systematic comparison of diagnostic techniques for the detection of a PFO. This was prompted by the observation of an association between stroke of unknown cause and the prevalence of a PFO.²⁰ In these cohorts, the sensitivity and specificity of c-TCD in detecting a PFO compared with c-TEE as the reference standard ranged from 0.68 to 1.0 and 0.82 to 1, respectively.^{9,21-28} The ranges of the sensitivity and specificity of c-TTE were 0.47-0.63 and 0.78-1, respectively.^{13,21-23} However, the prevalence of a PFO is reported to be significantly higher in patients with stroke of unknown cause (up to 66%) as compared with both age-matched controls and neurosurgical patients (10-33%).^{5,20,21,26} To the best of our knowledge there has been no previous prospective study comparing the diagnostic validity of c-TCD and c-TTE in patients scheduled for a neurosurgical procedure in the sitting position.

The position of the patient, the amount of echo-contrast medium, and the time elapsed between injection of the echo-contrast medium and the Valsalva maneuver have been reported to influence the sensitivity of the detection of a PFO.^{9,10} Therefore, a standardized protocol was used to ensure comparability of the techniques and to achieve a maximal sensitivity and specificity.

In the present study, c-TCD had a sensitivity of 0.92. This is in agreement with the highest values in the literature.^{9,22,25-28} Of 24 patients with a PFO verified by

c-TEE, there were two false-negative results for c-TCD. In both patients there was only a very small pressure PFO with little crossover of the contrast medium during the Valsalva maneuver.

A pressure PFO opens only if a pressure reversal occurs in both atria, as is the case, for instance, during the Valsalva maneuver. The main mechanism for an increase of the right atrial pressure during neuroanesthesia in the sitting position is the increase of pulmonary vascular resistance caused by VAE.²⁹⁻³¹ The risk of a paradoxical air embolism in patients with a small, pressure PFO is therefore not only dependent on the presence of the PFO but on the relation of the amount of entrained air and the size of the PFO. The slightly lower sensitivity of c-TCD as compared with c-TEE is of little significance in clinical routine.

However, patients with permanent PFO may be more in danger to suffer from paradoxical embolism during neurosurgical procedures. Studies regarding the topic of differentiation pressure and permanent PFO have revealed a proportion of pressure-dependent shunts of 50-60% of all detectable PFOs.^{32,33} However, the goal of the present study was not to distinguish between permanent and pressure PFO, but to assess an individual risk-benefit ratio concerning the sitting position. Taking into account the relatively high rate of VAE during procedures in the sitting position, both patient groups (with permanent and pressure PFO) may be at risk to suffer from paradoxical air embolism.

Contrast-enhanced transthoracic echocardiography has a lower sensitivity in detecting a PFO as compared with c-TEE.^{13,22,23} This was confirmed by a sensitivity of 0.42 in the present study.

The experience level necessary to reliably use c-TCD to screen for a PFO is relatively low because of the clear visual and acoustic signs of the high-intensity transient signals caused by contrast medium. As noted previously, high-intensity transient signals caused by the contrast medium can be easily distinguished from motion artifacts. However, in approximately 5-10% of the general population and in up to 40% of female patients older than 65 yr, it may be impossible to obtain an adequate signal quality for c-TCD because of a thick temporal bone.³⁴ Increasing the power of the ultrasonic beam and increasing the sample volume may help in this situation.

In conclusion, c-TCD is a highly sensitive and specific method for detecting a PFO if a standardized protocol is used. Because of its relative simplicity and noninvasive character, and because of the aforementioned disadvantages of c-TEE, c-TCD may be an acceptable alternative method for the preoperative screening for a PFO.

References

- Porter JM, Pidgeon C, Cunningham AJ: The sitting position in neurosurgery: A critical appraisal. *Br J Anaesth* 1999; 82:117-28

2. Young ML, Smith DS, Murtagh F, Vasquez A, Levitt J: Comparison of surgical and anesthetic complications in neurosurgical patients experiencing venous air embolism in the sitting position. *Neurosurgery* 1986; 18:157-61
3. Matjasko J, Petrozza P, Cohen M, Steinberg P: Anesthesia and surgery in the seated position: Analysis of 554 cases. *Neurosurgery* 1985; 17:695-702
4. Black S, Ockert DB, Oliver WC, Cucchiara RF: Outcome following posterior fossa craniectomy in patients in the sitting or horizontal positions. *ANESTHESIOLOGY* 1988; 69:49-56
5. Gronert GA, Messick JM, Cucchiara RF, Michenfelder JD: Paradoxical air embolism from a patent foramen ovale. *ANESTHESIOLOGY* 1979; 50:548-9
6. Bedell EA, Berge KH, Losasso TJ: Paradoxical air embolism during venous air embolism: Transesophageal echocardiographic evidence of transpulmonary air passage. *ANESTHESIOLOGY* 1994; 80:947-50
7. Mammoto T, Hayashi Y, Ohnishi Y, Kuro M: Incidence of venous and paradoxical air embolism in neurosurgical patients in the sitting position: Detection by transesophageal echocardiography. *ACTA Anaesthesiol Scand* 1998; 42: 643-7
8. Daniel WG, Erbel R, Kasper W, Visser CA, Engberding R, Sutherland GR, Grube E, Hanrath P, Maisch B, Dennig K, Scharlt M, Kremer P, Angermann C, Iliceto S, Curtius JM, Mügge A: Safety of transesophageal echocardiography: A multicenter survey of 10,419 examinations. *Circulation* 1991; 83:817-21
9. Zanette EM, Mancini G, De Castro S, Solaro M, Cartoni D, Chiarotti F: Patent foramen ovale and transcranial Doppler: Comparison of different procedures. *Stroke* 1996; 27:2251-5
10. Schwarze JJ, Sander D, Kukla C, Wittich I, Babikian VL, Klingelhöfer J: Methodological parameters influence the detection of right-to-left shunts by contrast transcranial Doppler ultrasonography. *Stroke* 1999; 30:1234-9
11. Karnik R, Stöllberger C, Valentin A, Winkler W-B, Slany J: Detection of patent foramen ovale by transcranial contrast Doppler ultrasound. *Am J Cardiol* 1992; 69:560-2
12. Hagen PT, Scholz DG, Edwards WD: Incidence and size of patent foramen ovale during the first 10 decades of life: An autopsy study of 965 normal hearts. *Mayo Clin Proc* 1984; 59:17-20
13. Chen W-J, Kuan P, Lien W-P, Lin F-Y: Detection of patent foramen ovale by contrast transesophageal echocardiography. *Chest* 1992; 101:1515-20
14. Schneider B, Zienkiewicz T, Jansen V, Hofmann T, Noltenius H, Meinertz T: Diagnosis of patent foramen ovale by transesophageal echocardiography and correlation with autopsy findings. *Am J Cardiol* 1996; 77:1202-9
15. Gillis MF, Peterson PL, Karagianes MT: In vivo detection of circulating gas emboli associated with decompression sickness using the Doppler flowmeter. *Nature* 1968; 217:965-7
16. Padayachee TS, Gosling RG, Bishop CC, Burnand K, Browne NL: Monitoring middle cerebral artery blood velocity during carotid endarterectomy. *Br J Surg* 1986; 73:98-100
17. Padayachee TS, Parsons S, Theobald R, Linley J, Gosling RG, Deverall PB: The detection of microemboli in the middle cerebral artery during cardiopulmonary bypass: A transcranial Doppler ultrasound investigation using membrane and bubble oxygenators. *Ann Thorac Surg* 1987; 44:298-302
18. Teague SM, Sharma MK: Detection of paradoxical cerebral echo contrast embolization by transcranial Doppler ultrasound. *Stroke* 1991; 22:740-5
19. Chimowitz MI, Nemec JJ, Marwick TH, Lorig RJ, Furlan AJ, Salcedo EE: Transcranial Doppler ultrasound identifies patients with right-to-left cardiac or pulmonary shunts. *Neurology* 1991; 41:1902-4
20. Lechat PH, Mas JL, Lascault G, Loron PH, Theard M, Klimczak M, Drobinski G, Thomas D, Grosgeat Y: Prevalence of patent foramen ovale in patients with stroke. *N Engl J Med* 1988; 318:1148-52
21. Pearson AC, Labovitz AJ, Tatineni S, Gomez CR: Superiority of transesophageal echocardiography in detecting cardiac source of embolism in patients with cerebral ischemia of uncertain etiology. *J Am Coll Cardiol* 1991; 17:66-72
22. Nemec JJ, Marwick TH, Lorig RJ, Davison MB, Chimowitz MI, Litowitz H, Salcedo EE: Comparison of transcranial Doppler ultrasound and transesophageal contrast echocardiography in the detection of interatrial right-to-left shunts. *Am J Cardiol* 1991; 68:1498-502
23. Di Tullio M, Sacco RL, Venketasubramanian N, Sherman D, Mohr JP, Homma S: Comparison of diagnostic techniques for the detection of a patent foramen ovale in stroke patients. *Stroke* 1993; 24:1020-4
24. Itoh T, Matsumoto M, Handa N, Maeda H, Hougaku H, Tsukamoto Y, Kondo H, Tanouchi J, Kamada T: Paradoxical embolism as a cause of ischemic stroke of uncertain etiology: A transcranial Doppler sonographic study. *Stroke* 1994; 25:771-5
25. Jauss M, Kaps M, Keberle M, Haberbosch W, Dorndorf W: A comparison of transesophageal echocardiography and transcranial Doppler sonography with contrast medium for detection of patent foramen ovale. *Stroke* 1994; 25:1265-5
26. Job FP, Ringelstein EB, Grafen Y, Flachskampf FA, Doherty C, Stockmann A, Hanrath P: Comparison of transcranial contrast Doppler sonography and transesophageal contrast echocardiography for the detection of patent foramen ovale in young stroke patients. *Am J Cardiol* 1994; 74:381-4
27. Klötzsch C, Janssen G, Berlit P: Transesophageal echocardiography and contrast-TCD in the detection of a patent foramen ovale: Experiences with 11 patients. *Neurology* 1994; 44:1603-6
28. Nygren AT, Jogestrand T: Detection of patent foramen ovale by transcranial Doppler and carotid duplex ultrasonography: A comparison with transesophageal echocardiography. *Clin Physiol* 1998; 18:327-30
29. Deal CW, Fielden BP, Monk I: Hemodynamic effects of pulmonary air embolism. *J Surg Res* 1971; 11:533-8
30. Verstaappen FJT, Bernards JA, Kreuzer F: Effects of pulmonary gas embolism on circulation and respiration in the dog. III. Excretion of venous gas bubbles by the lung. *Pflügers Arch* 1977; 370:67-70
31. Perkins-Pearson NAK, Marshall WK, Bedford RF: Atrial pressures in the sitting position. *ANESTHESIOLOGY* 1982; 57:493-7
32. Black S, Muzzi DA, Nishimura RA, Cucchiara RF: Preoperative and intraoperative echocardiography to detect right-to-left shunt in patients undergoing neurosurgical procedures in the sitting position. *ANESTHESIOLOGY* 1990; 72:436-9
33. Lynch JJ, Schuchard GH, Gross CM, Wann LS: Prevalence of right-to-left atrial shunting in a healthy population: Detection by Valsalva maneuver contrast echocardiography. *Am J Cardiol* 1984; 53:1478-80
34. Widder B: Doppler- und Duplexsonographie der hirnersorgenden Arterien, 4th Edition. Berlin, Springer, 1995, pp 162-3