

## Systemic Anaphylaxis Associated with Intramammary Isosulfan Blue Injection Used for Sentinel Node Detection under General Anesthesia

Michael A. Lyew, M.D.,\* Thomas C. Gamblin, M.D.,† Macram Ayoub, M.D.‡

IDENTIFICATION of the sentinel lymph node, a marker for metastatic disease, is used increasingly for the surgical management of melanomas and tumors of the head and neck, breast, thyroid, and genitourinary and gastrointestinal tracts.<sup>1</sup> Isosulfan blue (Lymphazurin; Ben Venue Laboratories, Bedford, OH) is the agent most commonly used, occasionally in conjunction with technetium sulfur colloid. Allergic reactions to this dye were reported previously during lymphangiography.<sup>2,3</sup> We report a systemic reaction associated with use of isosulfan blue for detection of the axillary sentinel node in breast cancer.

### Case Report

A 48-yr-old woman was scheduled to undergo excision of a ductal carcinoma of the left breast and sentinel node biopsy. She had no history of drug or food allergies, hay fever, or bronchial asthma. Two hours before surgery, 1 mCi technetium sulfur colloid was injected near the lump. Two milligrams midazolam was administered intravenously for premedication.

Anesthesia was induced using 100 mg propofol, 20  $\mu$ g sufentanil, and 30 mg rocuronium and maintained using isoflurane in nitrous oxide and oxygen after tracheal intubation. Vital signs were stable, with a blood pressure of 120/60 mmHg, a heart rate of 80 beats/min, and a pulse oxygen saturation ( $\text{SpO}_2$ ) of 99%. Five milliliters of isosulfan blue, 1%, was injected in 4 quadrants around the mass. Five minutes later, blood pressure decreased to 75/30 mmHg, with a heart rate of 85 beats/min and an  $\text{SpO}_2$  of 94 or 95%. The inspired gases were changed to 100% oxygen, and isoflurane was temporarily discontinued. One liter of lactated Ringer's solution was rapidly infused. A total of 50 mg ephedrine was administered, with little effect on the blood pressure but with a significant increase in heart rate and the occurrence of ventricular extrasystoles. The breath sounds were bilateral with no evidence of wheezing. When the drapes covering the face were lifted, marked swelling of the eyelids and lips was seen. Urticaria and erythema were not apparent at the site of dye injection or in the axilla. Fifty milligrams diphenhydramine, 1 g methylprednisolone, and 20 mg famotidine were administered. Blood pressure was maintained at 85-90/40-50

mmHg with subsequent doses of phenylephrine. The extrasystoles disappeared. After 15 min, blood pressure increased to 160/90 mmHg and then settled at 100-110/50 mmHg, with a heart rate of 100 beats/min and an  $\text{SpO}_2$  of 99%. Axillary lymph node dissection was performed because the sentinel node showed metastases. At the end of the procedure, swelling of the eyelids and lips still were present. Direct laryngoscopy showed that the upper airway and vocal cords, however, appeared to be normal. The airway remained clear after extubation.

The facial swelling was absent by the following morning (18 h after the event). The plasma histamine concentration was 0.92 ng/ml (normal  $\leq 1.0$  ng/ml). At the time of the reaction, the plasma histamine concentration was 11.2 ng/ml, and the serum complement levels were as follows: C3, 90 mg/dl (normal, 86-184 mg/dl); C4, 17 mg/dl (normal, 20-59 mg/dl). The immunoglobulin E level then was 38 IU/ml (normal 0-160 IU/ml).

Four weeks later, intradermal testing with a dose of 0.02 ml isosulfan blue, 0.1%, yielded a pruritic 5-mm wheal with a surrounding 2.5-cm flare within 20 min. No reaction was seen in five healthy control subjects. Intradermal testing with use of 0.02-ml doses of propofol, 0.1 mg/ml; sufentanil, 0.05  $\mu$ g/ml; midazolam, 0.01 mg/ml; and rocuronium, 0.01 mg/ml, yielded negative results. Subsequent anesthesia with use of these agents was uneventful. It was recommended that future use of the dye either be avoided or be covered by pretreatment if no alternative was available.

### Discussion

Isosulfan blue is a 2,5-disulfonated member of the triphenylmethane group of dyes, with a molecular weight of 563.13 d. Binding to serum proteins that leak into the interstitium causes it to enter the regional lymphatics, which become colored.<sup>4</sup> Therefore, surgical exposure is facilitated. The incidence of adverse reactions is 1.5%. Many of these reactions are mild, with localized wheals and urticaria, but systemic anaphylaxis has also been reported.<sup>3</sup> The reactions are mediated by histamine that is released either directly or through complement activation from mast cells or basophils.<sup>3</sup> Serum tryptase measurement is advocated to confirm that the high plasma histamine level is because of its release from mast cells. However, serum tryptase does not signal histamine release from basophils, and therefore its level may be in the normal range during a systemic reaction mediated by these cells.<sup>5</sup>

The temporal sequence of events and the positive skin test results with use of 0.1% isosulfan blue suggest that this substance was the cause of the systemic reaction. A false-positive wheal and flare response is possible at this dilution because the dye has anionic activity. However, at this dilution in control subjects, no reactions were seen with this agent in our case, or with other triphenylmethane dyes in a previous report.<sup>6</sup> In our patient, the reaction resembled that which was considered pos-

This article is featured in "This Month in Anesthesiology." Please see this issue of ANESTHESIOLOGY, page 5A.

\* Associate Clinical Professor, Department of Anesthesiology, † Resident, ‡ Professor, Department of Surgery.

Received from the Department of Anesthesiology, Mercer University School of Medicine, Macon, Georgia. Submitted for publication December 3, 1999. Accepted for publication March 21, 2000. Support was provided solely from institutional and/or departmental sources.

Address reprint requests to Dr. Lyew: Department of Anesthesiology, Children's Medical Center-M.C.G., BT 2651, 1446 Harper Street, Augusta, Georgia 30912. Address electronic mail to: mlyew@mail.mcg.edu. Individual article reprints may be purchased through the Journal Web site, www.anesthesiology.org.

Key words: Allergy; dye.

itive for an allergic response to patent blue, the counterpart to isosulfan blue (4-mm wheal with surrounding 2.5-cm flare).<sup>7</sup> Latex allergy is an unlikely cause of anaphylaxis in this patient because previous and subsequent anesthesia administrations with latex-containing equipment were uneventful.

This case highlights the need to suspect anaphylaxis when hemodynamic instability occurs after the injection of isosulfan blue. Further studies are needed to standardize the criteria for skin testing and reactivity because the reported values are based on only a few studies. In addition, the effectiveness of steroids and H<sub>1</sub>- and H<sub>2</sub>-receptor blocking agents for prevention of reactions in susceptible individuals remains to be determined.

The authors thank M. Castresana, M.D., Professor, and A. Cancel, M.D., Associate Professor, Department of Anesthesiology, Mercer University School of Medicine, Macon, Georgia, for their editorial assistance.

Anesthesiology 2000; 93:1146-7

## References

1. Bilchik AJ, Giuliano A, Essner R, Bostik P, Kelemen P, Foshag IJ, Sostrin S, Turner RR, Morton DL: Universal application of intraoperative lymphatic mapping and sentinel lymphadenectomy in solid neoplasms. *Cancer J Sci Am* 1998; 4:351-8
2. Hirsch JI, Tisnado J, Cho SR, Beachley MC: Use of isosulfan blue for identification of lymphatic vessels: Experimental and clinical evaluation. *Am J Roentgenol* 1982; 139:1061-4
3. Longnecker SM, Guzzardo MM, Van Voris LP: Life threatening anaphylaxis following subcutaneous administration of isosulfan blue 1%. *Clin Pharm* 1985; 4:219-21
4. Coleman RL, Whitten CW, O'Boyle J, Sidhu B: Unexplained decrease in measured oxygen saturation by pulse oximetry following injection of lymphazurin 1% (isosulfan blue) during a lymphatic mapping procedure. *J Surg Oncol* 1999; 70:126-9
5. LaRoche D, Vergnaud M, Sillard B, Soufarapis H, Brickard H: Biochemical markers of anaphylactoid reactions to drugs: Comparison of plasma histaminase and tryptase. *ANESTHESIOLOGY* 1991; 75:945-9
6. Kopp WL: Anaphylaxis from alphazurine 2G during lymphography. *JAMA* 1966; 198:668-9
7. Quilicini A, Hogendijk S, Hauser C: Anaphylaxis to patent blue (letter). *Dermatology* 1998; 197:400

© 2000 American Society of Anesthesiologists, Inc. Lippincott Williams & Wilkins, Inc.

## Factious Desaturation Due to Isosulfan Dye Injection

Roland R. Rizzi, M.D.,\* Kurien Thomas, M.D.,† Samuel Pilnik, M.D., F.A.C.S.‡

SINCE its initial report in the literature in 1993, sentinel lymph node biopsy has become a common technique for determining stage for patients with breast cancer.<sup>1</sup> The surgery involves the injection of the ipsilateral breast with isosulfan dye or radioactive technetium sulfur colloid to locate the node or nodes for biopsy. We report two cases of factious desaturation during this type of operation that probably occurred because of interference with pulse oximetry by isosulfan dye absorption.

### Case Reports

#### Case 1

A 58-yr-old woman was scheduled to undergo a left lumpectomy and sentinel node biopsy. The patient was injected with radioactive technetium colloid approximately 2 h previously in the nuclear medicine department. General anesthesia was provided with oxygen, nitrous oxide, and desflurane, supplemented by fentanyl and rocuronium. The intraoperative course was uneventful until 8 min after the injection of 5 ml isosulfan dye into the subcutaneous tissue of the left breast, at

which time the oxygen saturation, evaluated with an Ohmeda 525 respiratory gas monitor (Ohmeda, Austell, GA), rapidly decreased to 91%. An arterial blood gas sample (Chiron 855; Ciba-Corning Diagnostics Corp., Medfield, MA) showed a pH of 7.59, partial pressure of arterial carbon dioxide (Paco<sub>2</sub>) was 27 mmHg, and partial pressure of arterial oxygen (Pao<sub>2</sub>) was 212 mmHg. The cooximeter reading was 92%. The operation proceeded without further problems, and oxygen saturation returned to baseline 45 min later.

#### Case 2

A 50-yr-old woman was scheduled to undergo a left-sided reexcision of breast tissue and sentinel node biopsy. The patient was injected with radioactive technetium colloid approximately 1.5 h before proceeding to the operating room. She was administered oxygen, nitrous oxide, and isoflurane, supplemented by fentanyl, midazolam, and rocuronium for general anesthesia. The operation proceeded uneventfully until 12 min after the injection of 5 ml isosulfan dye into the subcutaneous tissue of the left breast, at which time, oxygen saturation decreased to 89%. No cause could be deduced, and no corrective action successfully increased oxygen saturation. An arterial blood gas sample showed a pH of 7.42, a Paco<sub>2</sub> of 31 mmHg, and a Pao<sub>2</sub> of 189 mmHg. The cooximetry reading was 91%. The surgery was completed without further problems, and oxygen saturation returned to baseline 25 min after the initial event.

This article is featured in "This Month in Anesthesiology." Please see this issue of ANESTHESIOLOGY, page 5A.

\* Adjunct Attending Physician, † Assistant Adjunct Attending Physician, Department of Anesthesiology, ‡ Associate Attending Physician, Department of Surgery.

Received from the Department of Anesthesiology, Lenox Hill Hospital, New York, New York. Submitted for publication March 7, 2000. Accepted for publication May 1, 2000. Support was provided solely from institutional and/or departmental sources.

Address reprint requests to Dr. Rizzi: 100 East 77th Street, New York, New York 10021. Address electronic mail to mdski@msn.com. Individual article reprints may be purchased through the Journal Web site, www.anesthesiology.org.

Key words: Breast; oximetry; sentinel.

injection of 3 ml lymphazurin dye during a lymphatic mapping procedure for cervical cancer.<sup>3</sup>

We experienced two episodes of factitious desaturation in the initial 31 cases of sentinel node biopsy at our institution. These two cases seem to represent interference with pulse oximetry, because the  $P_{aO_2}$  remained in the normal range, rather than an absolute reduction in the oxygen transport by hemoglobin of the patient. Pulse oximetry uses spectrophotometric analysis and plethysmography to calculate oxygen saturation of hemoglobin at two wavelengths—usually red 660 and near-infrared 940.<sup>4</sup> It has been reported previously that the accuracy of this monitor can be affected by indigo carmine, indocyanine green, nail polish, and methylene blue.<sup>5,6</sup> The presence of any substance in blood that absorbs light in the red or infrared spectrum can alter oxygen saturation readings. We believe that isosulfan dye used in sentinel node biopsy can, in some instances, be absorbed in sufficient quantities as to present this problem for the anesthesiologist. After the occurrence of the two cases described, one of the authors volunteered to participate in an informal experiment. A peripheral venous indwelling catheter was inserted, and at 45 min intervals, various quantities of isosulfan dye were injected. An injection of 0.1 ml did not cause a change in  $Sp_{O_2}$ . A dose of 0.25 ml resulted in a reduction in  $Sp_{O_2}$  to 97% from 99% in less than 2 min. An  $Sp_{O_2}$  of 94% was obtained after 0.5 ml isosulfan dye was administered. Last, when 1.0 ml dye was injected, the  $Sp_{O_2}$  decreased to 89%.

Why these two particular cases showed pulse oximetry interference, probably because of greater absorption of dye, is unclear. In all 31 procedures, isosulfan dye volume was equal, and the surgeon reported that it was injected into the subcutaneous tissue. The time course to desaturation from injection of dye and from recovery to baseline in the two reported cases argues against an intravascular injection. Our informal investigation also seems to rule out intravascular injection, but it supports the hypothesis that small quantities of absorbed isosulfan dye can interfere with oxygen saturation monitoring. As anesthesiologists gain further experience with this new procedure, it may become evident which factors increase the risk for interference, and recommendations regarding the proper evaluation of similar episodes of desaturation after dye injection can be determined.

## References

1. Krag DN, Weaver DL, Alex JC: Surgical resection and radiolocalization of the sentinel lymph node in breast cancer using a gamma probe. *Surg Oncol* 1993; 2:335–40
2. Veronesi U, Paganelli G, Galimberti V: Sentinel node biopsy to avoid axillary dissection in breast cancer with clinically negative lymph nodes. *Lancet* 1997; 349:1864–7
3. Coleman RL, Whitten CW, O'Boyle J, Sidhu B: Unexplained decrease in measured oxygen saturation following injection of lymphazurin 1% during lymphatic mapping. *J Surg Oncol* 1999; 70(2):126–9
4. Kelloher JF: Pulse oximetry. *J Clin Monit* 1989; 5:37–40
5. Scheller MS, Unger RJ, Kelner MJ: Effects of intravenously administered dyes on pulse oximetry. *ANESTHESIOLOGY* 1986; 65:550–5
6. Cote CJ, Goldstein A, Fuchman WH: The effect of nail polish on pulse oximetry. *Anesth Analg* 1988; 67:683–7

Anesthesiology 2000; 93:1147–9

© 2000 American Society of Anesthesiologists, Inc. Lippincott Williams & Wilkins, Inc.

## Bilateral Intraoperative Atelectasis in a Child with Latex Allergy

Ralf Gebhard, M.D.,\* Evan G. Pivalizza, M.B., Ch.B., F.F.A.S.A.,† Susan Nasri, M.D.,‡  
Jaques E. Chelly, M.D., Ph.D., M.B.A.§

THE onset and manifestations of anaphylaxis vary. In patients administered general anesthesia, early signs and symptoms are potentially masked and especially difficult to interpret. Anesthetic agents can alter mediator release<sup>1</sup> and, therefore, delay early recognition of the underlying problem. We present a case of bilateral atelectasis in a child with an allergic reaction to latex.

## Case Report

A 6-yr-old girl (18 kg) was scheduled to undergo dental restoration during general anesthesia. The patient had a preoperative medical history of seizures, cerebral palsy, and developmental delay. Allergies were reported for tegretol and antihistamines. Seizure activity was well-controlled with use of phenobarbital, and previous surgeries performed during general anesthesia, including laparotomy, ventriculo-peritoneal shunt placement, and dental restorations, were uneventful.

After oral premedication with midazolam and placement of standard monitoring devices, general anesthesia was induced *via* mask inhalation with use of halothane. Intravenous access was obtained, and intravenous fentanyl (50  $\mu$ g) and rocuronium (10 mg) were administered. Nasal intubation with use of direct laryngoscopy was performed using an uncuffed, 5.0-mm ID, nasal RAE endotracheal tube (ETT). Equal bilateral breath sounds, symmetric chest movement, and normal end-tidal carbon dioxide confirmed correct placement of the ETT. Anesthesia was maintained with isoflurane in 70%  $N_2O$  and 30%  $O_2$ . Before the start of surgery, the child was administered 225 mg clindamycin intravenously, a throat pack was placed in the pharynx, and 4 ml

\* Assistant Professor, † Associate Professor, ‡ Resident, § Professor, Director of Regional Anesthesia and Clinical Research, Department of Anesthesiology.

Received from the Department of Anesthesiology, The University of Texas—Houston Medical School, Houston, Texas. Submitted for publication February 14, 2000. Accepted for publication May 17, 2000. Support was provided solely from institutional and/or departmental sources.

Address reprint requests to Dr. Gebhard: 6431 Fannin, MSB 5.020, Houston, Texas 77030. Address electronic mail to: r\_gebhard@yahoo.com. Individual article reprints may be purchased through the Journal Web site, www.anesthesiology.org.

Key words: Mediator release; peak inspiratory pressure; pulmonary complications.



lidocaine, 2%, with epinephrine 1:100,000 was injected into the gingiva. This injection was repeated 60 min later.

After 2 h of uneventful anesthesia administration, a sudden increase of the peak inspiratory pressure from 18 to 35 mmHg was noted, followed by a decrease in oxygen saturation measured by pulse oximetry ( $\text{SpO}_2$ ) from 99% to 95%. Because the surgical team had stopped the procedure to review radiographs at that time, it was believed that these events were not related to any surgical stimulation.

The ETT was inspected immediately, and the throat pack was removed. No kinking, obstruction, or displacement of the ETT could be detected. Because  $\text{SpO}_2$  further decreased to 80% and heart rate increased from 105 to 135 beats/min in the absence of blood pressure changes (95/40 mmHg), inspiratory oxygen fraction ( $\text{FiO}_2$ ) was increased to 1.0, and depth of anesthesia was deepened with use of 25 mg intravenous thiopental. An additional 10 mg rocuronium was injected, and the child underwent manual ventilation.  $\text{SpO}_2$  remained in the 80% range. After the surgical field was undraped, decreased movement of the right side of the chest was observed; breath sounds over the right lung were almost silent. No wheezing could be heard. Endobronchial positioning of the ETT was ruled out with direct laryngoscopy. Bronchoscopy was performed using a pediatric fiberoptic bronchoscope. This revealed a small amount of secretions in the right upper lobe and in the left lower lobe of the lung. Secretions were aspirated, and the patient was administered two puffs of albuterol aerosol. This resulted in an increase of the oxygen saturation to 95 or 96%;  $\text{FiO}_2$  remained at 1.0. Peak inspiratory pressure decreased to 28 mmHg. A chest radiograph showed right upper lobe and left lower lobe atelectasis with the ETT in good position and a preexisting moderate levoscoliosis. Because the estimated remaining surgery time was 15 min, the decision was made to complete the procedure.

At the end of surgery, oxygenation continued to improve ( $\text{FiO}_2$  was 0.7 mmHg;  $\text{SpO}_2$  was 97%). After the drapes were undone for the second time, erythema of the chest, the neck, and the upper arms was noted, accompanied by a swollen lower lip. Subcutaneous epinephrine (5  $\mu\text{g}$ ), followed by 100 mg intravenous hydrocortisone, were administered, which resulted in an increase of the  $\text{SpO}_2$  to 100% over the next 10 min, and  $\text{FiO}_2$  decreased stepwise to 0.5 mmHg. The patient was extubated 8 h later in the intensive care unit after subsequent chest radiography indicated resolved atelectasis; oxygen saturation was 99% with an  $\text{FiO}_2$  of 0.3 mmHg. The patient was discharged from the hospital the next day.

Despite our suspicion of an allergic reaction to latex being related to the interoperative complication, the patient's parents refused to allow allergy testing for latex. A week later, during a follow-up visit in the dentist's office, an oral examination was performed in which latex gloves were used. A swollen face and respiratory distress immediately developed, which resolved with benadryl administration and removal of the antigen.

## Discussion

A sudden increase in peak inspiratory pressure can have multiple causes, making it useful to have a systematic approach to detect the underlying problem.<sup>2</sup> Clinical examination of the patient, inspection of the ETT, and direct laryngoscopy helped to exclude bronchospasm, kinking or obstruction of the ETT, and endobronchial intubation, respectively. Chest radiography led to the diagnosis of atelectasis, but only the delayed onset of skin symptoms raised suspicion of an allergic reaction being related to this intraoperative complication. Because the last intravenous medication was given more than 2 h previously, latex was highly suspected to be the responsible allergen. The reaction to the subsequent

latex exposure 1 week later makes our initial diagnosis even more likely.

In the past decade, there was an increased number of intraoperative allergic reactions to latex. High-risk groups include patients with spina bifida and severe urogenital defects, healthcare workers, and rubber-industry employees.<sup>3</sup> During general anesthesia, the onset of symptoms varies from a few minutes after start of the procedure<sup>4</sup> to 60 min,<sup>5</sup> and it can include cutaneous (rash, urticaria), respiratory (bronchospasm), or cardiovascular manifestations (hypotension, tachycardia, or complete collapse).<sup>6</sup> It is not known what determines which organ system will be affected, to what extent, and at what time after exposure. In the current case, the first signs occurred 2 h after the beginning of surgery, and skin manifestations developed 30 min later. It has been reported that certain anesthetics can delay the clinical manifestations and may modify mediator release,<sup>1</sup> making it unpredictable as to how and when a person undergoing general anesthesia will react to an allergen. Furthermore, the subsequent epinephrine injections in the gingiva also may have contributed to the observed delay between allergen exposure and onset and may have affected the magnitude of the clinical symptoms.

The occurrence of atelectasis is a well-documented complication of thoracic or upper abdominal surgery,<sup>7</sup> but there are also many reports regarding instances of inner mechanical obstruction, such as mucous plugs<sup>9,10</sup> or outer compression by mediastinal masses,<sup>11</sup> that led to atelectasis independent of the site of the surgical intervention. In asthmatic children, the incidence of atelectasis can be 40%,<sup>12</sup> but in our patient, history was negative for preexisting pulmonary disease. Finally, atelectasis related to anaphylactic reactions has been observed in bronchopulmonary aspergillosis<sup>13</sup> and as a complication of toxic epidermal necrolysis.<sup>14</sup>

In contrast, atelectasis related to an allergic reaction to latex has not been described. It is difficult to determine what mechanism led to atelectasis in our patient. Many factors, such as secretions and the coexisting moderate levoscoliosis, may have contributed to the clinical manifestation. Because the child had no symptoms of an upper respiratory infection or any pulmonary problems, we believe that the latex allergy was a significant factor in the development of right upper and left lower lobe atelectasis.

## References

1. Kettlekamp NS, Austin DR, Downes H, Cheek DB, Hirshman CA: Inhibition of d-tubocurarine-induced histamine release by halothane. *ANESTHESIOLOGY* 1987; 66:666-9
2. Hosking MP, Lennon RL, Warner MA, Gray JR, Masley P, DeLuca LA, Didier EP: Endotracheal tube obstruction: Recognition and management. *Mil Med* 1989; 154:489-91
3. Ebo DG, Stevens WJ, De Clerck LS: Latex anaphylaxis. *Acta Clin Belg* 1995; 50:87-93
4. Tomita S, Sugawara K, Tamakawa S, Saitoh Y: Intraoperative anaphylaxis caused by latex surgical gloves. *Masui* 1998; 47:213-6
5. Gutierrez-Garcia JM, Marquez-Espinos C, Rodriguez-Ramos M, Gomez-

- Sanchez S, Covenas-Pena R: Latex allergy. Reaction to intraoperative anaphylaxis. *Rev Esp Anestesiol Reanim* 1997; 44:371-3
6. Pollard RJ, Layon AJ: Latex allergy in the operating room: Case report and a brief review of the literature. *J Clin Anesth* 1996; 8:161-7
7. Huang TJ, Hsu RW, Sum CW, Liu HP: Complications in thoracoscopic spinal surgery: A study of 90 consecutive patients. *Surg Endosc* 1999; 13:346-50
8. Orringer MB, Marshall B, Iannettoni MD: Transhiatal esophagectomy: Clinical experience and refinements. *Ann Surg* 1999; 230:392-400
9. Samuels SI, Brodsky JB: Profound intraoperative atelectasis. *Br J Anaesth* 1989; 62:216-8
10. Pivalizza EG, Tonnesen AS: Acute life-threatening intraoperative atelectasis. *Can J Anaesth* 1994; 41:857-60

11. Mackie AM, Watson CB: Anesthesia and mediastinal masses. A case report and review of the literature. *Anaesthesia* 1984; 39:899-903
12. Nuhoglu Y, Bahceciler N, Yuksel M, Kodalli N, Barlan IB, Yildizeli B, Basaran MM: Thorax high resolution computerized tomography findings in asthmatic children with unusual clinical manifestations. *Ann Allergy Asthma Immunol* 1999; 82:311-4
13. Nomura K, Sim JJ, Yamashiro Y, Hoshino M, Nakayama H, Hosaka K, Uchida K: Total collapse of the right lung in a patient with allergic bronchopulmonary aspergillosis. *Nihon Kokyuki Gakkai Zasshi* 1998; 36:469-72
14. Lebarry F, Wolkenstein P, Gisselbrecht M, Lange F, Fleury-Feith J, Delclaux C, Roupie E, Revuz J, Roujeau JC: Pulmonary complications in toxic epidermal necrolysis: A prospective clinical study. *Intensive Care Med* 1997; 23:1237-44

Anesthesiology 2000; 93:1149-52

© 2000 American Society of Anesthesiologists, Inc. Lippincott Williams & Wilkins, Inc.

## Hyperbaric Oxygen Reverses Organ Dysfunction in Severe Anemia

J. Eric Greensmith, M.D., Ph.D.\*

HIGH oxygen content within the plasma that can supplement, or even supplant, the hemoglobin-bound oxygen can be achieved by use of hyperbaric oxygen administration. In 1960, Boerema *et al.*<sup>1</sup> exsanguinated pigs and then "reanimated" them by treatment in a hyperbaric chamber. Forty years later, hyperbaric therapy can be life saving when used as temporizing or definitive therapy in cases of severe anemia when transfusion is difficult to achieve or refused.

### Case Reports

#### Case 1

A 20-yr-old woman with a history of dysfunctional uterine bleeding underwent control of erratic and heavy menstrual bleeding *via* synthetic estrogen-progesterone hormonal therapy. The patient discontinued taking the medication and subsequently experienced 7 days of severe dysfunctional uterine bleeding.

At admission to another hospital, while in the supine position, the patient had a heart rate of 88 beats/min and a blood pressure of 125/81 mmHg. While in an upright position, she reported "dizziness and a pounding head," with a heart rate of 120 beats/min and a blood pressure of 145/78 mmHg. Hemoglobin and hematocrit concentrations were 5.3 g/dl and 15%, respectively. Because of the patient's religious prohibition against transfusion, therapy was limited to 25 mg conjugated estrogens and volume resuscitation with 2 l normal saline solution and 500 ml hetastarch. There was no record of oxygen administration. She was transferred to our institution, and her hemoglobin and hematocrit concentrations were 3.5 g/dl and 10%, respectively. She was administered a second dose of intravenous estrogens. A Foley catheter was inserted through the cervical os into the uterine cavity and inflated to tamponade uterine bleeding. At arrival to the surgical intensive care unit, she was pale and asthenic, without pain or discomfort. She was administered humidified oxygen *via* face mask. Over the next 2 h at rest, her heart rate was 120-134 beats/min, and her blood pressure was 110-141/47-62 mmHg,

but she reported retrosternal chest pressure that was not radiating (fig. 1A). Twelve-lead electrocardiography (ECG) showed ST-segment changes in V1-V3 that were consistent with myocardial ischemia.

Because of her refusal to be administered blood or blood components, the patient underwent hyperbaric therapy at 2.4 absolute pressure in atmospheres (ATA) with an inspiratory oxygen fraction ( $\text{FiO}_2$ ) of 1.0. After 3 min at 2.4 ATA, the patient's chest pressure and ECG changes resolved (fig. 1B). The patient continued to be pain free for 127 min at 2.4 ATA and during the 5 min of an "air break" when  $\text{FiO}_2$  was 0.21 at 2.4 ATA (this is a standard practice to minimize the chance of oxygen toxicity seizures). After completion of a 120-min period of pressurization, supplemental oxygen was removed, and the chamber returned to 1 ATA over 7 min, with the patient's  $\text{FiO}_2$  at 0.21. At 1.0 ATA, the patient reported severe substernal chest pressure with recurrence of the ECG ST-segment depression in lead II (fig. 1C). The chamber underwent repressurization to 2.4 ATA with an  $\text{FiO}_2$  of 1.0. Within 3 min, the chest pressure and ECG abnormality resolved.

Five milligrams of morphine was titrated intravenously. The patient remained alert and cooperative. The second return to 1 ATA was slowed to 0.03 ATA/min. Depressurization was accomplished with an  $\text{FiO}_2$  of 1.0. Angina or ECG changes did not recur (fig. 1D). The patient was returned to the intensive care unit.

The patient was treated using hyperbaric therapy eight more times initially twice a day, and later once a day. She continued to receive oxygen *via* a high-flow face mask when she was at 1 ATA with an  $\text{FiO}_2$  of 1.0 administered *via* hood in the hyperbaric chamber with appropriate air breaks. During the third hyperbaric treatment, the patient reported a new type of chest discomfort: a burning sensation that was made worse during administration of hyperbaric therapy. She also experienced a sharp burning sensation during breathing, and a dry nonproductive cough developed. The patient had a high  $\text{FiO}_2$  for more than 72 h, ranging from an  $\text{FiO}_2$  of 1.0 at 2.4 ATA in the hyperbaric chamber to an  $\text{FiO}_2$  of 0.7 during use of the face mask at 1 ATA in the intensive care unit. A clinical diagnosis of oxygen-associated pulmonary toxicity was determined. The patient was administered 800 mg vitamin E by mouth twice daily, and all symptoms resolved during the ensuing 24 h, despite continued exposure to high concentrations of oxygen.

Each day after presentation, the patient appeared to be more animated. The patient was allowed to stand and perform simple exercises in the hyperbaric chamber while at 2.4 ATA with an  $\text{FiO}_2$  of 1.0. She had no further angina and ECG was normal. No effort was made to have her exercise at 1 ATA. The patient was administered 300 units/kg erythropoietin daily, folate, cyanocobalamin, and oral iron. A hematocrit concentration evaluated on hospital day 5 was 16%. Her reticulocyte count was 274.2 thousand/mm<sup>3</sup> (normal, 16-100). The patient continued to improve, with no further angina pectoris; she was transferred from the intensive care unit on hospital day 6 and discharged from the hospital on day 8. Eighteen days after admission, hemoglobin

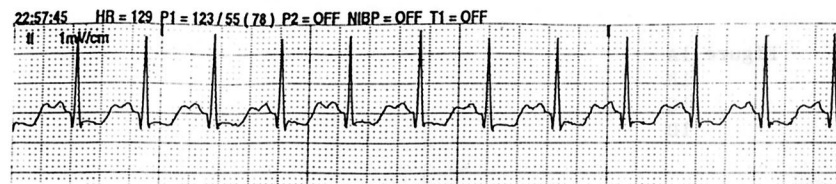
\* Assistant Professor.

Received from the Department of Anesthesia, The University of Iowa Hospitals and Clinics, Iowa City, Iowa. Submitted for publication December 3, 1999. Accepted for publication May 26, 2000. Support was provided solely from institutional and/or departmental sources.

Richard B. Weiskopf, M.D., served as acting Editor-in-Chief for this article.

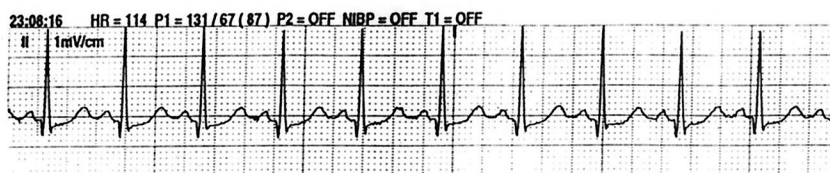
Address reprint requests to Dr. Greensmith: Department of Anesthesia, The University of Iowa Hospitals and Clinics, 200 Hawkins Drive, Iowa City, Iowa 52242-1009. Address electronic mail to: je-greensmith@uiowa.edu. Individual article reprints may be purchased through the Journal Web site, [www.anesthesiology.org](http://www.anesthesiology.org).

## Resolution of the Case



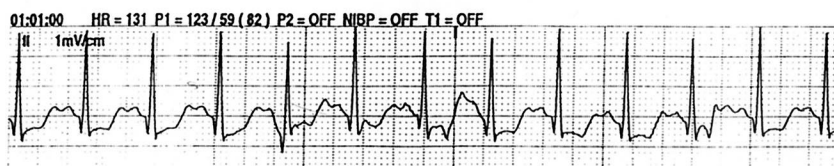
**A**

PRE-HBO  
 $F_{iO_2}$  0.7  
 1 ATA  
 HR 129  
 BP 123/55 (78)  
 With Angina



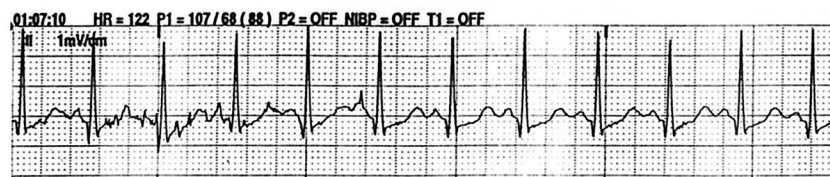
**B**

During HBO  
 $F_{iO_2}$  1.0  
 2.4 ATA  
 HR 114  
 BP 131/67 (87)  
 No Angina



**C**

During "ascent" from HBO  
 $F_{iO_2}$  0.21  
 1.4 ATA  
 HR 131  
 BP 123/59 (82)  
 With Angina



**D**

Post - HBO  
 $F_{iO_2}$  1.0  
 1 ATA  
 HR 122  
 BP 107/68 (88)  
 No Angina

**Fig. 1.** Standard lead II electrocardiogram during four points in the clinical course of patient 1. (A) Prehyperbaric oxygen (HBO) ST-segment depression while experiencing angina pectoris. (B) Resolution of ST-segment depression and angina during hyperbaric oxygen treatment at 2.4 ATA. (C) Abrupt recurrence of ST-segment changes and angina during rapid ascent with an  $F_{iO_2}$  of 0.21. (D) Slow ascent to 1 ATA while breathing, with an  $F_{iO_2}$  of 1.0. No ST-segment depression or symptoms.

and hematocrit concentrations increased to 8.4 g/dl and 29.2%, respectively. Troponin I levels 4 days after admission were within normal limits. The patient reported easy fatigability, but there was no clinical evidence of neurologic sequelae.

### Case 2

A 45-yr-old woman presented to a community hospital with mental status changes and a hematocrit concentration of 12.8% 15 days after an apparently uncomplicated vaginal delivery of a neonate and postpartum bilateral tubal ligation. Medical history included calcific aortitis of unknown origin that necessitated aortic valve replacement and right internal mammary artery bypass 6 yr previously. The patient was

prescribed warfarin for her aortic valve prosthesis, which was suspended after her pregnancy was diagnosed. Anticoagulation was maintained with use of subcutaneous heparin. After vaginal delivery of a neonate and postpartum tubal ligation, warfarin anticoagulation was resumed. Prothrombin time was 112 s, with an international normalized ratio of 9.9. During previous aortic valve replacement surgery, the patient underwent transfusion, and an erythrocyte antibody (anti-c) was reported to have developed.

At arrival in the intensive care unit, hemoglobin and hematocrit concentrations were 2.6 g/dl and 9%, respectively. Initial blood lactate concentration was 7.4 mEq/l. The patient was administered oxygen *via* face mask. While undergoing assessment for hyperbaric therapy, the patient had a tonic clonic seizure and became unresponsive. She underwent ventilation *via* mask, with an  $F_{iO_2}$  of 1.0, and was trans-



ported rapidly to the hyperbaric chamber. The chamber was compressed to 2.4 ATA, and ventilation was maintained *via* a mask, with an  $\text{Fio}_2$  of 1.0. Within 5 min at 2.4 ATA, the patient regained consciousness and became ebullient. Central venous partial pressure of oxygen ( $\text{Pvo}_2$ ) was 186 mmHg.

The patient was administered a total of 14 units of fresh frozen plasma and 8 units of packed erythrocytes. This large-volume infusion caused congestive heart failure, as evidenced by rales, an  $\text{S}_3$ , and tachypnea that necessitated tracheal intubation and sedation with the patient remaining at 2.4 ATA. Posttransfusion hemoglobin concentration was 9.4 g/dl, and the international normalized ratio decreased to 1.9. Lactate decreased to 1.9 mEq/l (normal, 0.5–2.2). The chamber was decompressed, and exploratory laparotomy was performed; 3 l liters blood was found in the peritoneal cavity. No further blood or blood component administration was necessary, and the patient was discharged on postoperative day 12 without apparent sequelae.

## Discussion

This case report describes our attempts to avoid morbidity and mortality in young women with profound blood loss anemia. Transfusion of erythrocytes was the medical therapy of choice, but this was limited by patient consent and by difficulties in crossmatching in the respective cases. Hyperbaric oxygen therapy maximized plasma-dissolved oxygen, pending an increase in oxygen-carrying capacity.

At 1 atm of ambient pressure, blood with a hematocrit concentration of 43.5%<sup>2</sup> that is fully saturated with oxygen contains approximately 19 ml oxygen/dl blood, with dissolved oxygen contributing less than 2% of the total blood-oxygen content.

With a hemoglobin concentration of 3.0 g/dl, total blood-oxygen content while breathing room air decreases to 4.1 ml oxygen/dl blood, with dissolved oxygen representing 7% of blood-oxygen content. Because sustained oxygen extraction from hemoglobin exceeds 60% in only the most dire circumstances,<sup>3,4</sup> a more realistic estimate of oxygen available for biologic consumption is 2.5 ml oxygen/dl blood. The 0.3 ml/dl of dissolved oxygen is approximately 10% of the available oxygen.

At 2.4 ATA with an  $\text{Fio}_2$  of 1.0, the arterial partial pressure of oxygen approaches 1,600 mmHg,<sup>5</sup> and dissolved oxygen content is approximately 4.8 ml oxygen/dl blood, which is a quantity sufficient to supply the majority of metabolic oxygen requirements. Total blood oxygen content with a hemoglobin concentration of 3.0 g/dl is approximately 8.7 ml oxygen/dl blood. Using 60% as a maximal value for sustained hemoglobin-bound oxygen extraction, the biologically useful oxygen content is 7.1 ml oxygen/dl blood. Sixty-seven percent of the usable oxygen is from the dissolved oxygen.

Survivors have been reported to have had hemoglobin concentrations comparable with our patients' anemic states. Lichtenstein *et al.*<sup>6</sup> described combined deep sedation, neuromuscular blockade, hemodilution, and cooling to a core body temperature of 29°C to reduce oxygen consumption 57% below baseline in a 37-yr old Jehovah's Witness with a hematocrit concentration of 4%.

Myking and Schreiner<sup>7</sup> treated a middle-aged woman with idiopathic hemolytic anemic crisis and mental status changes of syncope, urinary incontinence, paresthesia, disorientation, and stupor when the patient's hemoglobin concentration nadir was 3 g/dl. All symptoms were interrupted with use of hyperbaric oxygen therapy, and this relief persisted for several hours after each hyperbaric treatment.

Amonic *et al.*<sup>8</sup> reported the case of a 26-yr-old male Jehovah's Witness who refused transfusion despite a bleeding gastric lesion and who had a hemoglobin concentration of 2.2 g/dl and evidence of congestive heart failure, myocardial ischemia, and cerebral insufficiency. The patient was treated at 2 ATA with an  $\text{Fio}_2$  1.0 in 6-l cycles over the following 3 days. The patient was discharged 16 days after surgery, with a hematocrit concentration of 26%.

Recently, a similar case to ours was reported.<sup>9</sup> A 38-yr-old Jehovah's Witness experienced a placental abruption and bled, causing the hemoglobin concentration nadir to reach 2 g/dl. Despite tracheal intubation, sedation, and neuromuscular blockade to minimize oxygen consumption, a metabolic acidosis and subsequent ECG changes suggestive of myocardial ischemia developed. Cardiac output was  $7.6 \text{ l} \cdot \text{min}^{-1} \cdot \text{m}^{-2}$  with epinephrine support. Hyperbaric oxygen was administered for 90 min at 2 ATA and was associated with a reduced heart rate and cardiac output and with resolution of ischemic ECG changes and metabolic acidosis. Hyperbaric treatments were discontinued 16 days postpresentation when the hemoglobin concentration was 3.6 g/dl and the patient was asymptomatic.

In our cases, the lower limits of hemoglobin concentration, consistent with myocardial sufficiency in the one case and cerebral sufficiency in the other case, were identified, and the decrement in oxygen delivery was rectified with use of hyperbaric oxygen therapy. In the second case, a central  $\text{Pvo}_2$  was 186 mmHg, which suggested that a surfeit of oxygen dissolved in the patient's plasma, and the hemoglobin-bound oxygen was unused (mixed venous oxygen saturation = 100%).

The oxygenation effects of hyperbaric oxygen are ephemeral; the tissue partial pressure of oxygen ( $\text{po}_2$ ) has been reported to remain elevated for minutes to hours after the hyperbaric exposure.<sup>10</sup> For the second patient, transfusion effected the cure. This raises the question: why did the first patient, who refused transfusion, have no reported recurrences of hypoxia after removal from the hyperbaric environment. One possibility is that the ECG changes and symptoms the patient experienced before hyperbaric treatments represented an accumulation of anaerobic metabolic products and stresses that were cleared after sufficient oxygen was supplied. Periodic hyperbaric oxygen therapy may have prevented reaccumulation of metabolites to the threshold for symptoms. Furthermore, hyperbaric oxygen ther-

apy has been associated with a decrease in sympathetic tone and a lower heart rate, both of which would be beneficial in the presence of myocardial ischemia.<sup>11</sup> Heart rates during periods of angina in the chamber (129 and 131 beats/min) were increased relative to heart rates when angina was absent (114 and 122 beats/min).

The only other intervention in addition to slowing of the pressurization during hyperbaric oxygen therapy and maintaining an  $\text{FIO}_2$  of 1.0 was the administration of morphine. Morphine decreases oxygen consumption 9–21% in critically ill patients, depending on the level of oxygen consumption.<sup>12</sup> Morphine may have decreased the metabolic oxygen consumption enough that the patient was able to meet this reduced level of oxygen consumption.

## References

1. Boerema I, Meyne NG, Brummelkamp WK, Bouma S, Mensch MH, Kamermans F, Hanf MS, Van Aalderen A: Life without blood. *J Cardiovasc Surg* 1960; 182:133–46
2. Snyder JV, Carroll GC: Tissue oxygenation: A physiologic approach to a clinical problem. *Curr Probl Surg* 1982; 19:650–719
3. McMichan JC: Continuous monitoring of mixed venous oxygen saturation: Theory applied to practice, Continuous Measurement of Blood Oxygen Saturation in the High Risk Patient. Edited by Schweiss JF. San Diego, Beach International, 1983, pp 27–44
4. Dantzker DR, Foresman B, Gutierrez G: Oxygen supply and utilization relationships. *Am Rev Respir Dis* 1991; 143:675–9
5. Weaver LK: Management of critically ill patients in the monoplace hyperbaric chamber, *Hyperbaric Medicine Practice*. Edited by Kindwall EP. Flagstaff, Best Publishing, 1995, pp 174–246
6. Lichtenstein A, Eckhart WF, Swanson KJ, Vacanti CA, Zapol WM: Unplanned intraoperative and postoperative hemodilution: Oxygen transport and consumption during severe anemia. *ANESTHESIOLOGY* 1988; 69:119–22
7. Myking O, Schreiner A: Hyperbaric oxygen in hemolytic crisis. *JAMA* 1974; 227:1161–2
8. Amonic RS, Cockett AT, Lorhan PH, Thompson JC: Hyperbaric oxygen therapy in chronic hemorrhagic shock. *JAMA* 1969; 208:2051–4
9. McLoughlin PL, Cope TM, Harrison JC: Hyperbaric oxygen therapy in the management of severe acute anemia in a Jehovah's Witness. *Anaesthesia* 1999; 54:879–98
10. Wells CH, Goodpasture JE, Horrigan DJ: Tissue gas measurements during hyperbaric oxygen exposure, *Proceedings of the Sixth International Congress of Hyperbaric Medicine*. Edited by Smith G. Aberdeen, Aberdeen University Press, 1977, pp 118–24
11. Villanucci S, Di Marzio GE, Scholl M, Pirovine C, d'Adamo C, Settini M: Cardiovascular changes induced by hyperbaric oxygen therapy, *European Undersea Biomedical Society Meeting 16th*. Foundation for Hyperbaric Medicine, Amsterdam, 1990, p 247
12. Rouby JJ, Eurin B, Glaser P, Guillosson JJ, Nafziger J, Guesde R, Viars H: Hemodynamic and metabolic effects of morphine in the critically ill. *Circulation* 1981; 64:53–9 Assistant Professor.