

Anesthesiology
2000; 93:902
© 2000 American Society of Anesthesiologists, Inc.
Lippincott Williams & Wilkins, Inc.

P-V Approach Revisited

To the Editor:—We read the article “Controlled Airway Pressure Therapy, Nitric Oxide Inhalation, Prone Position, and Extracorporeal Membrane Oxygenation (ECMO) as Components of an Integrated Approach to ARDS”¹ with great interest, and we congratulate the authors for their well-conducted study. A lung-protective strategy with reduction of shear stress by keeping positive end-expiratory pressure above the lower inflection point and avoiding overdistension by keeping peak airway pressure below the upper inflection point of the pressure-volume curve produces good results.

At our institution, the ventilatory management of acute respiratory distress syndrome is pressure-controlled ventilation and the attempt to achieve optimal positive end-expiratory pressure derived from pressure-volume curves, as documented by Lazarus^{2,3} approximately 15 yr ago.

Although this first evidence of lung volume-oriented ventilation did not receive a good response, Ullrich *et al.*¹ supported this approach in their large-scale clinical study. Therefore, clinical experience with the pressure-volume approach of the 1980s and recent scientific evidence should have the desired impact on ventilation strategy in critical care units.

We hope to gain more clinical experience from such studies to help us in critical care medicine in the 21st century.⁴

Gunther Pestel, M.D.
Staff Anesthesiologist
gunther.pestel@cc-online.de

Anesthesiology
2000; 93:902-3
© 2000 American Society of Anesthesiologists, Inc.
Lippincott Williams & Wilkins, Inc.

In Reply:—We appreciate the interest expressed by Drs. Pestel and Rothhammer with regard to our recent article.¹ Although pressure-controlled ventilation with positive end-expiratory pressure is an integral component of our treatment algorithm, we did not measure pressure-volume curves of the lungs, but rather set the values of positive end-expiratory pressure and peak inspiratory pressure according to previous clinical studies.^{2,3} Therefore, no inference can be made from our findings about the feasibility or clinical value of setting ventilatory pressure limits according to measures of pressure-volume curves in patients with acute respiratory distress syndrome.

In addition, we emphasize that we cannot take credit for “the desired impact on ventilatory strategy in critical care units” because this goal has been achieved by others in large, randomized clinical trials.^{4,5} Our study, however, provides evidence for an additional hypothesis; namely, that a combined treatment strategy, including the best available conventional management protocol and extracorporeal membrane oxygenation results in an improved survival rate for patients with acute respiratory distress syndrome.

Anton Rothhammer, M.D.
Head of Department
Associate Professor in Anesthesia
Department of Anesthesiology and Critical Care Medicine
Leopoldina-Hospital of the City of Schweinfurt
Schweinfurt, Germany

References

1. Ullrich R, Lorber C, Röder G, Urak G, Faryniak B, Sladen RN, Germann P: Controlled airway pressure therapy, nitric oxide inhalation, prone position, and extracorporeal membrane oxygenation (ECMO) as components of an integrated approach to ARDS. *ANESTHESIOLOGY* 1999; 91:1577-86
2. Lazarus G: End-inspiratory lung volume as the limiting factor of ventilation with PEEP (German). *Anaesthesist* 1983; 32:582-90
3. Lazarus G: PEEP ventilation without hyperinflation of the lung (German). *Anaesthesist* 1985; 34:59-64
4. Bigatello L, Hurford W, Pesenti A: Ventilatory management of severe acute respiratory failure for Y2K. *ANESTHESIOLOGY* 1999; 91:1567-70

(Accepted for publication April 11, 2000.)

Roman Ullrich, M.D.
Staff Anesthesiologist
roman.ullrich@univie.ac.at
Peter Germann, M.D.
Associate Professor in Anesthesia
Department of Anesthesia and General Intensive Care
Medicine
Vienna General Hospital, University of Vienna
Vienna, Austria
peter.germann@univie.ac.at

References

1. Ullrich R, Lorber C, Röder G, Urak G, Faryniak B, Sladen RN, Germann P: Controlled airway pressure therapy, nitric oxide inhalation, prone position, and extracorporeal membrane oxygenation (ECMO) as components of an integrated approach to ARDS. *ANESTHESIOLOGY* 1999; 91:1577-86

CORRESPONDENCE

2. East TD, Boehm SH, Wallace CJ, Clemmer TP, Weaver LK, Orme JF Jr, Morris AH: A successful computerized protocol for clinical management of pressure control inverse ratio ventilation in ARDS patients. *Chest* 1992; 101:697-710

3. Germann P, Pöschl G, Leitner C, Urak G, Ullrich R, Faryniak B, Röder G, Kaider A, Sladen R: Additive effect of nitric oxide inhalation on the oxygenation benefit of the prone position in the adult respiratory distress syndrome. *ANESTHESIOLOGY* 1998; 89:1401-6

4. Amato MBP, Barbas CSV, Medeiros DM, Magaldi RB, Schettino GDP, Lorenzi G, Kairalla RA, Deheinzelin D, Munoz C, Oliveira R,

Takagaki TY, Larvalho CRR: Effect of a protective-ventilation strategy on mortality in the acute respiratory distress syndrome. *N Engl J Med* 1998; 338:347-54

5. The Acute Respiratory Distress Syndrome Network: Ventilation with lower tidal volumes as compared with traditional tidal volumes for acute lung injury and the acute respiratory distress syndrome. *N Engl J Med* [serial online]. March 10, 2000

(Accepted for publication April 11, 2000.)

Anesthesiology
2000; 93:903

© 2000 American Society of Anesthesiologists, Inc.
Lippincott Williams & Wilkins, Inc.

Extreme Pulmonary Hypertension and Anesthesia Induction

To the Editor:—We read with great interest the case report of Höhn *et al.*,¹ which recommended arteriovenous femoral cannulation during local anesthesia before induction of general anesthesia in the case of severe pulmonary hypertension. We believe that this statement is judicious; however, we describe a case in which this procedure failed.

A 50-yr-old woman was scheduled to undergo double lung transplantation for severe pulmonary hypertension resulting from scleroderma. Transthoracic echocardiography showed a rapid increase in systolic pulmonary arterial pressure from June 1999 (80 mmHg) to September 1999 (126 mmHg). In October, her clinical condition worsened further: dyspnea was significant, movement to the supine position was impossible, and attempts were associated with faintness. Inhaled nitric oxide slightly improved the clinical status of the patient, although it was ineffective in decreasing pulmonary arterial pressure. Emergency lung transplantation was performed. We decided to perform cardiac cannulation *via* the femoral artery and vein with use of a local anesthetic before induction of anesthesia. The femoral vessels were surgically exposed, with the patient in the sitting position during local anesthesia. The sitting position did not allow complete insertion of the cannulas. Attempting to move the patient to the semisitting position was impossible because of the refusal of the patient, who was experiencing distress as a result of respiratory failure. We had to use general anesthesia (including intravenous sufentanil, etomidate, and rocuronium bromide) with the patient in the sitting position. Circulatory failure and cardiac arrest occurred immediately after induction of anesthesia. Tracheal intubation and external cardiac massage were immediately performed. Then, complete insertion of the cannulas was achieved, anesthesia was achieved, and cardiopulmonary bypass was begun. Double lung transplantation was performed uneventfully. Then, the patient was discharged from the hospital.

Anesthesiology
2000; 93:903-4

© 2000 American Society of Anesthesiologists, Inc.
Lippincott Williams & Wilkins, Inc.

In Reply:—We thank Dalibon *et al.* for drawing the attention of clinicians to the delicate anesthetic and surgical treatment of patients with severe pulmonary hypertension. Indeed, some patients with end-stage pulmonary hypertension experience such extreme respiratory

In conclusion, we agree with Höhn *et al.*¹ about the use of the femoral route during local anesthesia for the cannulation of the patient undergoing lung transplantation in whom a significant increase in pulmonary arterial pressure was seen. However, extreme and unusual clinical situations exist in which this procedure could fail.

Nicholas Dalibon, M.D.
Staff Anesthesiologist
anesthésie@hopital-foch.org
Marc Moutafis, M.D.
Staff Anesthesiologist
Ngai Liu, M.D.
Staff Anesthesiologist
Mireille Michel-Cherqui, M.D.
Staff Anesthesiologist
Marc Fischler, M.D.
Chairman
Department of Anesthesiology
Hopital Foch
Suresnes, France

Reference

1. Hohn L, Schweizer A, Morel DR, Spiliopoulos A, Licker M: Circulatory failure after anesthesia induction in a patient with severe primary pulmonary hypertension. *ANESTHESIOLOGY* 1999; 91:1943-5

(Accepted for publication April 21, 2000.)

distress that they are unable to sustain the supine position. In this situation, the patient should be prepared and draped during light sedation, and the surgeon should be ready to cannulate the femoral vessels immediately after anesthesia induction and tracheal intubation.

CORRESPONDENCE

was obstructive sleep apnea, which included "choking and gasping for air while asleep," despite treatment with continuous positive airway pressure. He also had a Mallampati classification III airway. Without complications, he had undergone nasal WuScope intubation during general anesthesia for diagnostic endoscopy and biopsies 3 months previously. Nasal WuScope intubation was performed again without difficulty for lingual tonsillectomy. Although the two patients were scheduled to undergo anticipated difficult direct laryngoscopy, with our extensive experience with the WuScope, we were comfortable enough to perform tracheal intubation during general anesthesia.

As Omote *et al.*¹ mentioned, lack of space, which impedes advancement of the fiberoptic, and bloody secretions, which can obscure the visual field, are the problems with the flexible fiberoptic technique in cases such as the one described. In contrast, the WuScope tubular blade provides a mechanical means to gently push away the tonsillar tissue. The wedged tip enters the vallecula, stretches the glossoepiglottic mucous membrane, and lifts the epiglottis, thus locating and exposing the larynx easily. To remove blood in the airway, we first used a Yankauer suction (ConMed Corp., Utica, NY) to clean thoroughly the posterior pharyngeal wall, where the blood usually is collected. As the blade enters the oropharynx and advances toward the larynx, additional blood may be removed using an 18-French suction catheter through the endotracheal tube lumen.

WuScope intubation, as opposed to the LMA technique, is an entirely visually guided procedure. We agree with previous authors^{2,4} that the LMA may be inadvisable in such cases of periglottic soft tissue obstruction. Because of the blind nature of the LMA technique, placing an LMA or intubating through it could potentially worsen the situation by further pushing the redundant soft tissue to block the glottic opening or causing more bleeding.

As also mentioned by the authors, lingual tonsil airway obstruction often was unanticipated. However, from the two cases described, we

Anesthesiology
2000; 93:905-6
© 2000 American Society of Anesthesiologists, Inc.
Lippincott Williams & Wilkins, Inc.

Dantrolene in Malignant Hyperthermia (MH)-Susceptible Patients with Exaggerated Exercise Stress

To the Editor:—The fascinating report by Wappler *et al.*¹ described unsuccessful use of oral dantrolene in controlling exercise-related symptoms in a malignant hyperthermia-susceptible man. The authors used daily doses of dantrolene, and the patient experienced migraine, dizziness, and severe muscle weakness, forcing discontinuation of dantrolene. We used dantrolene to control somewhat similar symptoms in a patient in whom contracture testing showed malignant hyperthermia susceptibility, but we instructed him to withhold its use until he began to experience stress symptoms.² This approach obviated complications associated with the use of dantrolene and yet was highly satisfactory for control in this patient. We have had intermittent contact with this patient during the past 20 yr, and he continues to

Support was provided solely from institutional and/or departmental sources.

Anesthesiology, V 93, No 3, Sep 2000

believe that history of heavy snoring or obstructive sleep apnea, particularly in a not-so-obese patient, may be an important clue in preanesthetic airway evaluation to alert the practitioners of possible periglottic lesions, such as LTH, which may cause soft tissue airway obstruction during anesthesia.

The WuScope technique has worked well for us in dealing with pharyngeal soft tissue obstructions, such as in patients with LTH, and should be considered by others in managing this difficult airway problem.

Scott R. Andrews, M.D.
Staff Anesthesiologist
scott.andrews@ncal.kaiperm.org
Monique F. Mabey, M.D.
Chief Anesthesiologist
Kaiser Permanente Medical Center
Hayward, California

References

1. Omote K, Kawamata T, Imaizumi H, Namiki A: Case of Cowden's disease that caused airway obstruction during induction of anesthesia. *ANESTHESIOLOGY* 1999; 91:1537-40
2. Fundingsland BW, Benumof JL: Difficulty using a laryngeal mask airway in a patient with lingual tonsil hyperplasia. *ANESTHESIOLOGY* 1996; 84:1265-6
3. Jones DH, Cohle SD: Unanticipated difficult airway secondary to lingual tonsillar hyperplasia. *Anesth Analg* 1993; 77:1285-8
4. Langenstein H, Andres AH: Do not rely on a laryngeal mask in major periglottic pathology. *Br J Anaesth* 1999; 83: 685a-6a

(Accepted for publication May 1, 2000.)

have effective control. In addition, he has learned to minimize the factors that seem to be associated with the onset of symptoms.

Gerald A. Gronert, M.D.
Professor Emeritus
UC Davis
Albuquerque, New Mexico
gagronert@ucdavis.edu

References

1. Wappler F, Fiege M, Antz M, Esch JS: Hemodynamic and metabolic alterations in response to graded exercise in a patient susceptible to malignant hyperthermia. *ANESTHESIOLOGY* 2000; 92:268-72
2. Gronert GA, Thompson RL, Onofrio BM: Human malignant hyperthermia: Awake episodes and correction by dantrolene. *Anesth Analg* 1980; 59:377-8

(Accepted for publication May 18, 2000.)

Anesthesiology
2000; 93:906
© 2000 American Society of Anesthesiologists, Inc.
Lippincott Williams & Wilkins, Inc.

Use of a Condom as a Blade Cover for Laryngoscope

To the Editor:—Use of a laryngoscope during intubation is a daily routine for every anesthesiologist. However, cleansing and sterilization of the laryngoscope blade is a nuisance to nurses or other paramedical personnel because blood clots or sputum may lodge into small spaces, which are difficult to clean completely. Since July 1999, our department has used a condom as a blade cover during laryngoscopy, and our use has been successful.

The advantages of using a condom as a blade cover are as follow:

1. ease of availability and inexpensiveness (approximately \$0.06 each)

Support was provided solely from institutional and/or departmental sources.

Anesthesiology
2000; 93:906-7
© 2000 American Society of Anesthesiologists, Inc.
Lippincott Williams & Wilkins, Inc.

Fiberoptic Laryngoscopy (WuScope) For Double-lumen Endobronchial Tube Placement in Two Difficult-intubation Patients

To the Editor:—Placement of double-lumen endobronchial tubes (DLTs) may be difficult because of anatomic factors that predispose patients to difficult intubation and because of the large external diameter of DLTs.^{1,2} Moreover, rupture of the proximal endotracheal cuff of the DLT may occur during difficult intubation because the thin-walled cuff is located 8–11 cm from the tip of the DLT, where it can easily be torn on the maxillary teeth.

We describe the use of fiberoptic laryngoscopy with the WuScope (Pentax Precision Instruments, Orangeburg, NY) to facilitate placement of a DLT in two patients with abnormal airway anatomy.

A 33-yr-old man was involved in a motor vehicle accident that resulted in multiple injuries, including a descending thoracic aortic laceration just below the left subclavian artery. He was scheduled for repair of the aortic laceration. The patient's trachea had been intubated with use of a standard tube, and no intubation difficulties were noted at that time. Cervical spine radiographs were normal, but, because of a depressed level of consciousness, there was still a chance of spine injury, and a rigid cervical collar was in place. Examination showed that the airway was otherwise normal.

The trachea and oropharynx were suctioned, and the endotracheal tube was removed after 10 min of preoxygenation. A 39-French, left

Supported in part by the Department of Anesthesiology, Metro-Health Center, Cleveland, Ohio. Pentax Precision Instruments, Orangeburg, New York, loaned an extra WuScope System to the Department of Anesthesiology.

2. adequate transparency, enabling a high degree of light penetration
3. adequate elasticity to accommodate almost any blade size
4. ease of mounting and dismounting because of readily available lubricant
5. good bacteria and virus barrier

Edmund C. So, M.D.
Department of Anesthesia
Chi-Mei Foundation Hospital
Tainan, Taiwan
edmundso@ipx.ntntc.edu.tw

(Accepted for publication April 26, 2000.)

DLT (Broncho-cath; Mallinckrodt Medical, St. Louis, MO) could not be inserted using conventional laryngoscopy because of poor glottic visualization. A 37-French, left DLT then was inserted using a Heine Corazzelli-London articulating laryngoscope (Heine USA Ltd., Dover, NH) and inline stabilization (grade II view with external laryngeal pressure and activation of the lever). The endotracheal cuff, however, was torn by the patient's upper teeth. Another attempt, using a 35-French DLT, had a similar cuff rupture.

Fiberoptic laryngoscopy using the WuScope was performed with use of large, adult-sized blades.³ A 35-French, left DLT was inserted via the passage created by the main blade and bivalve element (fig. 1) through the vocal cords and into the trachea (grade 1 view). Flexible fiberoptic bronchoscopy confirmed satisfactory tube position, and surgery was completed without complications.

A 37-yr-old woman presented with a 7-month history of dry cough. Radiographic examination showed a dilated noncommunicating bronchus, with mucoid impaction and a large feeding arterial vessel arising from the distal thoracic aorta at the lower diaphragm. She was scheduled for right lower lobectomy.

Airway examination showed a 35-mm mouth opening with temporal mandibular joint clicking, a normal thyromental distance, protruding maxillary incisors, and Mallampati II classification.

After induction of general anesthesia and neuromuscular blockade, a 37-French, left DLT could not be inserted using conventional laryngoscopy because of a grade III view. Insertion of a Univent tube (Fuji Systems Corp., Tokyo, Japan), size 7, using conventional laryngoscopy and an anteriorly directed stylet also was unsuccessful. A 35-French,

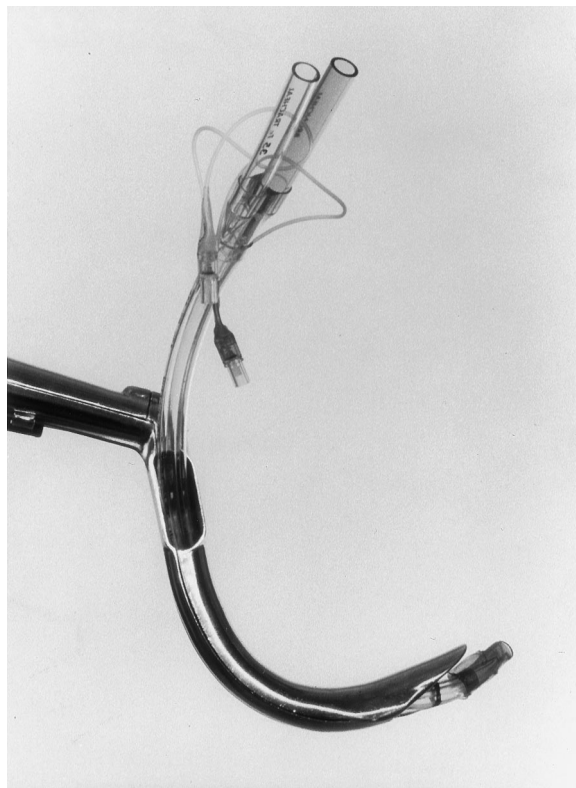


Fig. 1. Fiberoptic laryngoscope (WuScope). Note the oropharyngeal airway-shaped blade and tubular blade structure with the built-in passage through which a 35-French left endobronchial tube has been inserted.

left DLT was inserted with fiberoptic laryngoscopy using the adult-sized WuScope blades as described in patient 1. A grade I view of the glottis was obtained on the first attempt, and the DLT was inserted.

The WuScope is composed of a tubular, curved, bivalved rigid blade and a flexible fiberscope to facilitate oral intubation without the need for head extension.^{4,5} At least 20 mm of mouth opening is necessary to insert the rigid blades.

It has previously been shown that glottic exposure and tracheal intubation were relatively easy using the WuScope, even in patients with anatomic factors that would normally prevent a complete view of the vocal cords, such as cervical spine instability, hypoplastic mandible, and protruding maxillary incisors.³

One advantage of the WuScope is that the two rigid blades combine to form a tubular exoskeleton, which not only provides a passage through which the DLT tube can be placed, but also protects the proximal endotracheal cuff from tearing as the DLT is moved through the glottic opening.

With the WuScope, it may be necessary to insert a DLT that is smaller than desired because of the tubular nature of the blade system. For example, we have found that, when using the large adult-sized blades, left 35- and 37-French DLTs slid through easily, whereas the left 39-Fr DLT was extremely tight. When using the adult-sized blades, only the 35-Fr DLT could easily be inserted.

Although other techniques for lung separation are available, the WuScope was used in these two patients because it was readily available, and considerable experience had already been achieved with this technique.

The WuScope permitted DLT intubation in two patients with difficult airway anatomy. Advantages of the WuScope include an oropharyngeal airway-shaped blade to allow a view of the laryngeal aperture without the need for head extension; a handle-to-blade angle of 110° which allows easy placement into the mouth; a tubular blade structure which protects the fiberscope from secretions, blood, and redundant soft tissue; a built-in passage through which the DLT can be inserted and continuous viewing of the DLT as it moves into the trachea. Disadvantages of the WuScope include high cost (approximately \$9,800), the need for smaller DLTs (e.g., 35-37 French), and the need for learning to assemble and disassemble the blades and manipulate the scope.

Charles E. Smith, M.D., F.R.C.P.C.
Associate Professor
csmith@metrohealth.org
Mohan Kareti, M.D.
Senior Resident
Department of Anesthesiology
MetroHealth Medical Center
Case Western Reserve University
Cleveland, Ohio

References

1. Benumof JL: Separation of the two lungs, *Anesthesia for Thoracic Surgery*. Philadelphia, WB Saunders, 1987, pp 223-59
2. Mallampati SR: Recognition of the difficult airway, *Airway Management: Principles and Practice*. Edited by Benumof JL. St. Louis, Mosby-Year Book, 1996, pp 126-42
3. Smith CE, Sidhu TS, Lever J, Pinchak AB: The complexity of tracheal intubation using rigid fiberoptic laryngoscopy (WuScope). *Anesth Analg* 1999; 89:236-9
4. Smith CE, Pinchak AB, Sidhu TS, Radesic BP, Pinchak AC, Hager JF: Evaluation of tracheal intubation difficulty in patients with cervical spine immobilization: Fiberoptic (WuScope) versus conventional laryngoscopy. *ANESTHESIOLOGY* 1999; 91:1253-9
5. Wu TL, Chou HC. A new laryngoscope: The combination intubating device. *ANESTHESIOLOGY* 1994; 81:1085-7

(Accepted for publication April 26, 2000.)

Anesthesiology
2000; 93:908
© 2000 American Society of Anesthesiologists, Inc.
Lippincott Williams & Wilkins, Inc.

Intraoral Separation of a Reinforced Endotracheal Tube

To the Editor:—Wire-reinforced endotracheal tubes (ETTs) are used in situations in which there is potential for kinking of the tube.¹ Various complications have been described, one of which is permanent occlusion, which occurs when the tube is compressed between the teeth.^{2,3} We report a different but related type of complication.

A 4-yr-old girl was scheduled for tonsillectomy and adenoidectomy. General anesthesia was induced, and the trachea was intubated using a wire-reinforced 4-mm ID ETT (Bivona Inc., Gary, IN). A mouth gag with a grooved blade was positioned to protect the tube and permit surgical access. A clinically insignificant air leak was noted during the procedure. At the end of the surgery, the gag was removed, with no apparent change in the leak. As the patient emerged from anesthesia, the ETT was removed, but resistance was noted as a result of a partially closed jaw. However, only the proximal portion of the tube was retrieved, with a clean break noted, along with an unraveled reinforcing wire (fig. 1). Signs of airway obstruction developed immediately, with stridor, retractions, and cyanosis. A laryngoscope was inserted, but the distal segment of the ETT could not be found in the oropharynx. Manual mask ventilation was started, with rapid improvement in oxygenation. Fluoroscopy showed that the distal ETT segment was just below the glottis. The level of the anesthetic was deepened, and the distal segment was extracted using endolaryngeal microsurgery forceps. There were no postoperative complications.

The cause of this event was not immediately evident. There was no evidence that the tube was compressed during surgery, and the minimal air leak makes it unlikely that the tube had been transected before removal was attempted. The most likely explanation was that the tube was lacerated soon after placement, perhaps between the mouth gag and the lower teeth. When traction was applied, the tube separated at the point of the initial cut.

To reproduce this event, we tested a new ETT of identical size and construction. A set of false teeth was placed on a firm surface, and the ETT was compressed between the lower teeth and the mouth gag. This did not result in persistent compression of the tube, but it did produce a laceration on the silicone coating of the tube. Manual traction applied to the lacerated tube resulted in relatively easy separation. The manufacturer of the ETT was informed of this event.

This report indicates that a wire-reinforced ETT can be cut during routine surgery. In such cases, separation of the tube at the point of the laceration can occur when force is used to remove the tube through partially closed teeth.

Rita Rodriguez, M.D.
Senior Physician
Department of Anesthesiology
Hospital of Medina del Campo

Support was provided solely from institutional and/or departmental sources.

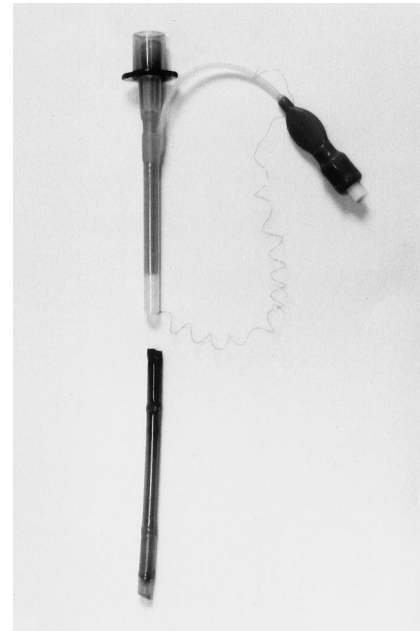


Fig. 1. Photograph of the separated segments of the endotracheal tube and the partially unraveled reinforcing wire.

Hermenegildo González, M.D.
Honorific Professor
Department of Pediatrics
University of Valladolid
Valladolid, Spain
Continuity Medical Education Coordinator
Hospital of Medina del Campo
med010461@nacom.es
Antonia Carranza, M.D.
Senior Physician
Department of Otorhinolaryngology
Hospital of Medina del Campo
Valladolid, Spain

References

1. Bousfield JD: Armored tracheal tubes for neuroanesthesia. *Anesthesia* 1986; 41:776
2. Hoffmann CO, Swanson GA: Oral reinforced endotracheal tube crushed and perforated from biting. *Anesth Analg* 1989; 69:552-3
3. Peck MJ, Needleman SM: Reinforced endotracheal tube obstruction. *Anesth Analg* 1994; 79:193

(Accepted for publication May 23, 2000.)

CORRESPONDENCE

Anesthesiology
2000; 93:909
© 2000 American Society of Anesthesiologists, Inc.
Lippincott Williams & Wilkins, Inc.

Insertion of a Fogarty Catheter through an Endotracheal Tube for One-lung Ventilation: A New Method

To the Editor:—A Fogarty or Foley catheter has been used as a bronchial blocker when one-lung ventilation is necessary in children.¹⁻⁴ The blocker catheter can be passed either through^{1,2} or alongside^{3,4} the endotracheal tube. In the former method, the catheter usually is inserted into an endotracheal tube through a right-angle connector with a self-sealing diaphragm or suction port.^{1,2} One major problem associated with this method is that the blocker may easily be dislodged when the connector is detached from the endotracheal tube (e.g., to insert a suction catheter into the trachea) or when a fiberoptic is inserted into or removed from the endotracheal tube alongside the catheter to confirm the blocker position. We report a simple method to minimize this problem.

A 1-month-old boy with congenital cystic adenomatoid malformation of the left lung was scheduled for left upper lobectomy. Chest radiography showed that the mediastinum was markedly shifted to the right. We planned to block the left bronchus after induction of anesthesia, but before injection of a muscle relaxant, to minimize further expansion of the left lung. In the operating room, anesthesia was induced by inhalation of an increasing concentration of sevoflurane in oxygen.

A small hole was made to the side of an endotracheal tube (3.5 mm ID) close to the tube connector. An 18-gauge needle was used to pierce the tube, and the needle was rotated to make a round hole. Resulting debris was removed. A 3-French Fogarty catheter, with its tip curved, was passed through the hole into the tube (fig. 1), and integrity of the cuff of the catheter was confirmed. The combination was inserted into the trachea using a laryngoscope, and adequate ventilation was confirmed. A fiberoptic bronchoscope was inserted into the endotracheal tube (via a self-sealing connector), and the Fogarty catheter was advanced easily into the left bronchus during fiberoptic view. The fiberoptic was removed, and a transparent drape was used to cover the endotracheal tube hole through which the Fogarty catheter entered. After adequate one-lung ventilation was confirmed, vecuronium was injected. Throughout the operation, which was performed without complication, the Fogarty catheter was not dislodged, and there was no gas leak around the tube hole.

Because the Fogarty catheter was inserted through a hole made to the side of the endotracheal tube (fig. 1), there was little risk of dislodgment of the Fogarty catheter during detachment or attachment of the right-angle connector or during insertion of the fiberoptic into and its removal from the endotracheal tube. It was easy to affix the catheter to the endotracheal tube using adhesive tape. Although the manufacturer may not accept liability for a modified device, we believe that this method is clinically useful.

Support was provided solely from institutional and/or departmental sources.

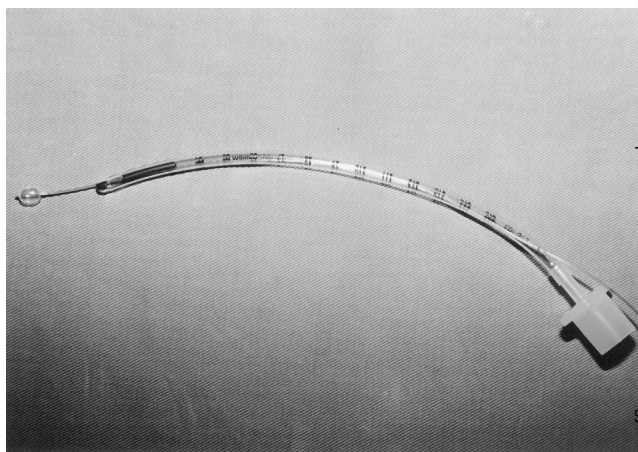


Fig. 1. A device for one-lung ventilation.

Takashi Asai, M. D., Ph.D.
Research Associate
asait@takii.kmu.ac.jp
Sakahiro Ikeda, M.D.
Research Associate
Koh Shingu, M.D.
Professor
Department of Anesthesiology
Kansai Medical University
Osaka, Japan

References

1. Ransom ES, Norfleet EA: Syringe cap prevents leaks during one lung ventilation. *ANESTHESIOLOGY* 1995; 82:1538
2. Larson CE, Gasior TA: A device for endobronchial blocker placement during one-lung anesthesia. *Anesth Analg* 1990; 71:311-2
3. Hammer GB, Manos SJ, Smith BM, Skarsgard ED, Brodsky JB: Single-lung ventilation in pediatric patients. *ANESTHESIOLOGY* 1996; 84: 1503-6
4. Asai T, Oishi K, Shingu K: Use of the laryngeal mask for placement of a bronchial blocker in children. *Acta Anaesthesiol Scand* 2000; 44:767-9

(Accepted for publication May 24, 2000.)

Anesthesiology
2000; 93:910
© 2000 American Society of Anesthesiologists, Inc.
Lippincott Williams & Wilkins, Inc.

Glottic Adduction during Hiccups in the Presence of a Cuffed Endotracheal Tube

To the Editor:—The *hiccup reflex* is a series of brief, powerful, spasmodic inspiratory events accompanied by glottic closure.¹⁻² Two mechanisms that cause glottic closure during hiccups are possible. One is a passive process that results from suppression of laryngeal abductor muscles, such as posterior cricoarytenoid muscles.²⁻⁵ The other is an active process that results from activation of laryngeal adductor muscles, such as thyroarytenoid muscles.⁴ However, no data are available regarding the intralaryngeal muscle activities during human hiccups. The following report suggests that an active process is involved in glottic closure during hiccups in humans.

A 42-yr-old woman (height, 160 cm; weight, 58 kg) presented for laryngomicrosurgery. After anesthesia was induced rapidly using fentanyl (0.1 mg), thiopental (325 mg), and vecuronium (7 mg), the patient's trachea was intubated with a 6.5-mm ID spiral tube, and anesthesia was maintained with nitrous oxide (66%), oxygen (33%), and isoflurane (0.5-1.5%). Approximately 30 min after induction, the patient abruptly experienced a series of spasmodic inspiratory efforts accompanied by glottic movements toward closure, which was observed through direct laryngoscopy. The glottic movements were recorded on a videotape recorder (video clip in Web Enhancement). To alleviate these spasmodic inspiratory events, we increased the inhalational isoflurane concentration from 0.7 to 2.0% and injected additional vecuronium (3 mg) intravenously. Approximately 1 min later, the inspiratory depth of these spasmodic inspiratory efforts gradually decreased, and they eventually stopped. Simultaneously, the glottic adduction gradually was attenuated and eventually stopped.

Most anesthesiologists conventionally use the term *hiccups* for this occurrence. Without a cuffed endotracheal tube, high-velocity airflow between the vocal cords could facilitate glottic closure during hiccups (Bernoulli effect).² The presence of an endotracheal tube clearly ruled

out the Bernoulli component. Moreover, the fact that neuromuscular blockade stopped glottic adduction indicates a possible contribution of laryngeal adductor muscles. The glottic adduction observed during this occurrence may involve an active process, possibly attributed to activation of laryngeal adductors. To our knowledge, this is the first report to indicate that there may be an active process in glottic closure during human hiccups. Further studies are needed to confirm this hypothetical contribution of laryngeal adductors.

The complication of hiccups that occur during laryngomicrosurgery during general anesthesia may provide a valuable opportunity for investigation of the mechanism that causes glottic closure during human hiccups.

Tsutomu Oshima, M.D, Ph.D.

Assistant Professor
oshimat@cc.gifu-u.ac.jp

Kiyoshi Nagase, M.D.

Postgraduate Student

Shuji Dohi, M.D, Ph.D.

Professor and Chair

Department of Anesthesiology and Critical Care Medicine
Gifu University School of Medicine
Gifu, Japan

References

1. Newsom Davis J: An experimental study of hiccup. *Brain* 1970; 93:851-72
2. Launois S, Bizet JL, Whitelaw WA, Cabane J, Derenne JPH: Hiccup in adults: An overview. *Eur Respir J* 1993; 6:563-75
3. Oshima T, Sakamoto M, Arita H: Hiccuplike response elicited by mechanical stimulation of dorsal epipharynx of cats. *J Appl Physiol* 1994; 76:1888-95
4. Arita H, Oshima T, Kita I, Sakamoto M: Generation of hiccup by electrical stimulation of cats. *Neurosci Lett* 1994; 175:67-70
5. Oshima T, Sakamoto M, Tatsuta H, Arita H: GABAergic inhibition of hiccup-like reflex induced by electrical stimulation in medulla of cats. *Neurosci Res* 1998; 30:287-93

Additional material related to this article can be found on the ANESTHESIOLOGY Web site. Go to the following address, click on Enhancements Index, and then scroll down to find the appropriate article and link. <http://www.anesthesiology.org>

Support was provided in part by Grant-in-Aid 12671460 from the Ministry of Education, Science, and Culture, Tokyo, Japan.

(Accepted for publication May 25, 2000.)

Anesthesiology
 2000; 93:911
 © 2000 American Society of Anesthesiologists, Inc.
 Lippincott Williams & Wilkins, Inc.

A Novel Technique for Conversion of Nasotracheal Tube to Orotracheal

To the Editor:—Occasionally, it is necessary to change a nasally placed endotracheal tube to an orally placed one.¹ There is significant risk of losing control of the airway during this procedure, especially in the case of a difficult intubation. A 19-yr-old man who sustained a C5 fracture that resulted in quadriplegia was nasotracheally intubated. When pneumonia developed, the patient required mechanical ventilation. We were asked to change the nasal endotracheal tube to an oro-tracheal tube. This intervention was complicated by the fact that a halo was used on the patient, causing initial difficulty in intubation.

We decided to maintain the position of the endotracheal tube and convert from nasal to oral. The patient's airway was treated with topical local anesthetic, and he was sedated using intravenous propofol. Laryngoscopy was performed using a Macintosh 3 blade. The endotracheal tube was visualized and grasped with a Kelly clamp as high behind the uvula as possible. An assistant cut the tube at the 28-cm mark. The Kelly clamp was used to move the tube deeper into the trachea. The laryngoscope was removed, and a finger was placed in the mouth behind the endotracheal tube. The tube was brought out through the mouth, the adapter was reattached, and the ventilator

circuit was connected. A carbon dioxide sensor was used to ensure that the tube was still endotracheal, breath sounds were checked, and the tube was retaped.

The equipment necessary for difficult intubation was available in case the tube was inadvertently removed from the trachea. This technique is an easy, atraumatic alternative to changing a nasal to an oral endotracheal tube.

David M. Gabriel, M.D.
 Instructor in Anesthesiology
Ruben J. Azocar, M.D.
 Chief Resident in Anesthesiology
 Department of Anesthesiology
 Boston University Medical Center
 Boston, Massachusetts 02118
 rumaja@rcn.com

Reference

1. Seiden AM: Sinusitis in the critical care patient. *New Horiz* 1993; 1:261-70

(Accepted for publication May 25, 2000.)

Support was provided solely from institutional and/or departmental sources.