

Pulsus Alternans during General Anesthesia with Halothane

Effects of Permissive Hypercapnia

Mahmood Saghaei, M.D.,* Mojtaba Mortazavian, M.D.†

Background: Pulsus alternans is a classic type of abnormal pulse. It can be defined as a regular alternation of pulse amplitude in which runs of weak and strong beats follow each other alternatively without any change in cycle length. It may be a sign of severe decompensated congestive heart failure. The authors infrequently encountered some cases of pulsus alternans during halothane anesthesia with spontaneous respiration in otherwise normal subjects in association with high levels of end-tidal carbon dioxide. This study was conducted to determine if there is any relation between this phenomena and hypercapnia.

Methods: One hundred twenty patients undergoing elective lower extremity surgery were selected. Halothane was used for maintenance of anesthesia, and the patients were allowed to breath spontaneously. The occurrence of pulsus alternans was determined by plethysmographic display of pulse wave and then confirmed by palpation of the radial artery.

Results: Ten patients (8.3%) developed pulsus alternans together with elevated levels of end-tidal carbon dioxide (57 ± 4 mmHg vs. 41 ± 4 mmHg in patients without pulsus alternans [mean \pm SD]). The pulsus alternans disappeared after switching to controlled ventilation and 15–20% reduction in end-tidal carbon dioxide. During the period of pulsus alternans, vital signs and electrocardiography remained within normal limits.

Conclusions: There may be some relation between occurrence of pulsus alternans and hypercapnia during halothane anesthesia. Pulsus alternans occurs in a small fraction of spontaneously breathing, halothane-anesthetized patients. Although hypercapnia is clearly a factor, the mechanism of this phenomenon is unknown. (Key words: Carbon dioxide; plethysmography; pulse oximetry; respiratory acidosis; spontaneous respiration.)

* Assistant Professor.

† Resident of Anesthesiology.

Received from the Department of Anesthesia and Critical Care, Esfahan University of Medical Sciences, Esfahan, Iran. Submitted for publication May 24, 1999. Accepted for publication February 7, 2000. Supported by Esfahan University of Medical Sciences, Faculty of Medicine, Research Department, Esfahan, Iran. Presented at the 5th Iranian Congress of Anesthesiology and Critical Care, Tehran, Iran, April 30–May 4, 1998.

Address reprint requests to Dr. Saghaei: PO Box 931, Al-Zahra Medical Center, Esfahan, Iran. Address electronic mail to: msaqaeci@noornet.net

PULSUS alternans (PA) is defined by regular alternation of weak and strong heart beats, without changes in cycle length.¹ This may be seen physiologically when the pulse rate is two times the respiratory rate.² After a single extrasystole in otherwise healthy persons, the heart may show alternation for several beats.²⁻⁴ It has long been known that this type of pulse may be seen in the presence of severe decompensated congestive heart failure, aortic insufficiency, hypovolemia, or in the face of paroxysmal tachycardias.² In our previous experiences we sporadically had observed a particular alternativity in pulse oxymetric displays of some patients during halothane anesthesia with spontaneous respiration, which was associated with high levels of end-tidal carbon dioxide (ET_{CO₂}). Checking the gap between systolic pressures of two succeeding pulses had definitely proved the presence of PA in those patients.² No other cardiorespiratory abnormality had been found in those cases if they were placed on mechanical ventilation up to 1 min after the development of PA. Although sinus rhythm was present in all of the cases, some developed mild to moderate degrees of cardiorespiratory problems (e.g., hypoxia, tachycardia, hypertension, and hypotension) if the initiation of mechanical ventilation was delayed more than 2–3 min after the appearance of PA. The PA disappeared after ventilatory support in all patients, which lowered carbon dioxide levels. Based on these observations and *in vitro* animal studies,^{5,6} the authors investigated the possible association between hypercapnia and PA.

Materials and Methods

After institutional approval and patient consent were obtained, 120 adult, nonsmoking, nonobese patients undergoing elective lower extremity procedures were studied. Patients with respiratory, cardiovascular, electrolyte, and renal diseases were excluded. Patients with

pulse oxymetric hemoglobin saturation (Sp_{O_2}) lower than 94% on air were also excluded. No premedication was given. On arrival in the operating room, the patient's electrocardiogram (ECG) was monitored continuously with central subclavicular lead (CS_5) attachment using lead I and II alternatively. Arterial blood pressure was measured with an automated noninvasive device (Cardiicap; Datex/Division of Instrument Corp., Helsinki, Finland). Pulse oxymetric monitoring of Sp_{O_2} was performed using a device capable of plethysmographic display of pulse volume curve (Cardiicap). Side stream ET_{CO_2} monitoring with sampling port near the proximal end of endotracheal tube was performed throughout the procedure (Cardiicap). Anesthesia was induced with thiopentone 5 mg/kg, morphine 0.1 mg/kg, succinyl choline 1.5 mg/kg followed by tracheal intubation, and controlled and/or assisted ventilation until restoration of spontaneous respiration. The patients were then allowed to breathe spontaneously. A mixture of halothane 1-2% and N_2O 50% in oxygen through a Bain circuit with a total fresh gas flow of 7 l/min was used for maintenance of anesthesia, so that end-tidal halothane and N_2O concentrations of 1.4-1.6% and 48-52%, respectively, were obtained (Cardiicap). The plethysmographic pulse display was examined visually throughout the procedure to detect any sign of PA that persisted for at least 30 s. The presence of PA was verified by finger palpation of radial artery. Patients who developed dysrhythmias associated with PA (other than sinus tachycardia) as evidenced by ECG monitoring were excluded from the study. The highest ET_{CO_2} in every 15-min interval was recorded throughout the procedure together with its corresponding vital signs and Sp_{O_2} . After termination of the procedure, the maximum recorded ET_{CO_2} and its associated vital signs were selected as representative

measurements of the patient. If the patient developed PA, then the ET_{CO_2} at that moment was selected. A fresh vital sign and Sp_{O_2} record was taken after documenting the presence of PA (at 30 s after appearance of PA), and then controlled ventilation was started after administering 0.3 mg/kg atracurium. The level of ET_{CO_2} at which alternation disappeared was recorded.

Statistical Analysis

Frequency distribution of patients with and without PA was calculated according to their ET_{CO_2} level. Mean ET_{CO_2} , age, systolic and diastolic blood pressure, heart and respiratory rate, and Sp_{O_2} for the two groups were determined and compared using the Student *t* test. The relation between age and ET_{CO_2} in the two groups was examined with linear regression analysis. $P < 0.05$ was considered significant.

Results

None of the patients developed significant rebreathing as demonstrated by inspiratory concentrations of carbon dioxide near zero. The end-tidal halothane concentration was 1.4-1.6% in all patients. Onset of PA occurred 15-35 min after induction of anesthesia (four cases before and six cases after surgical stimulation). No significant differences in respiratory and heart rate, blood pressure, and Sp_{O_2} were found between the two groups (table 1). Patients in the PA group were significantly more hypercapnic than those in the non-PA group. The mean age of patients in the PA group was also significantly higher than that of those in the non-PA group (table 1). Thirty-five patients (29%) developed moderate to severe hypercapnia ($ET_{CO_2} > 44$ mmHg),⁷ and 10

Table 1. Age and Cardiorespiratory Parameters in Two Groups

	Alternans		Nonalternans	
	Mean \pm SD	Range	Mean \pm SD	Range
Age (yr)*	59 \pm 13	29-71	44 \pm 18	14-85
ET_{CO_2} (mmHg)*	57 \pm 4	52-65	41 \pm 4	30-50
Heart rate (/min)	81 \pm 11	64-95	86 \pm 13	60-110
Respiratory rate (/min)	22 \pm 3	18-28	23 \pm 4	12-29
Systolic blood pressure (mmHg)	122 \pm 11	110-140	128 \pm 17	100-150
Diastolic blood pressure (mmHg)	76 \pm 9	60-88	75 \pm 9	57-95
Pulse oxymetric saturation (%)	99 \pm 0.8	98-100	98 \pm 0.8	97-100

* $P < 0.001$.

ET_{CO_2} = end-tidal carbon dioxide.

PULSUS ALTERNANS DURING ANESTHESIA

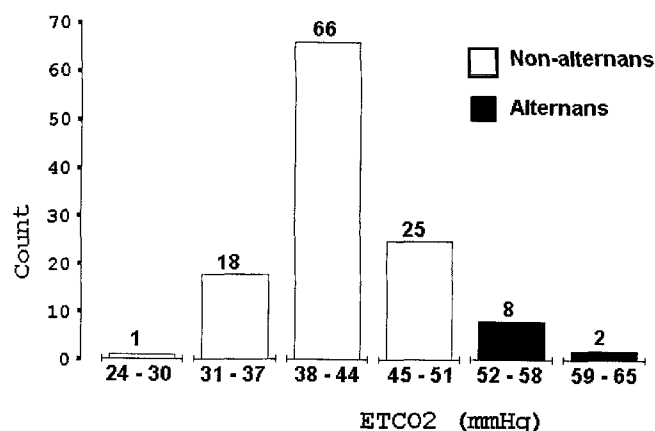


Fig. 1. Frequency distribution of patients based on their ET_{CO₂}.

(28.5%) of these hypercapnic patients (8.3% of total) showed alternating pulse (fig. 1 and table 2). Finger plethysmography showed an abrupt occurrence of PA in all patients in the PA group. The degree of alternation in pulse wave amplitude estimated visually was approximately 50%, *i.e.*, the amplitude ratio of two adjacent pulse waves was approximately 0.5. Finger palpation of the radial artery confirmed alternation in pulse. No evidence of electrical alternans was detected in ECG monitoring. Careful visual examination of ECG monitoring did not show any pathologic changes in P wave morphology or any kind of dysrhythmia. ST segment and T wave pattern were normal before and after the event. Auscultation of the lungs and heart was normal (no rales, S₃ and/or S₄). No abnormal respiratory movement (*e.g.*, inspiratory retractions, active expiration) was found before or after the onset of PA. There was no relationship between respiratory phases and alternans pattern in plethysmographic display (heart rate to respiratory rate ratio ≥ 2.5). The alternation in pulse disappeared completely after establishment of controlled ventilation, when a 15–20% reduction in ET_{CO₂} occurred, which took approximately 51 ± 2 s (mean \pm SD; range, 46–55 s, not correlated with ET_{CO₂}). The total duration of PA

Table 2. Frequency Distribution of the Patients between Two Groups*

	ET _{CO₂} > 44 (mmHg)	ET _{CO₂} \leq 44 (mmHg)	Total
Alternans	10	0	10
Nonalternans	25	85	110
Total	35	85	120

* $P < 0.001$ (Fisher exact test).

ET_{CO₂} = end-tidal carbon dioxide.

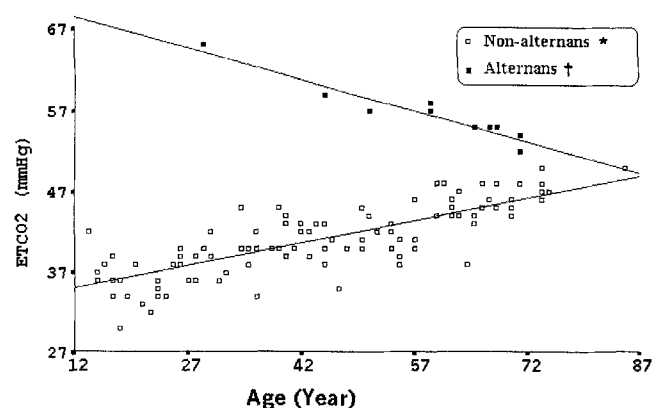


Fig. 2. Linear regression analysis of ET_{CO₂} with age. * $r = 0.8$, $P < 0.05$. † $r = -0.9$, $P < 0.05$.

was 91 ± 3 s (range, 84–98 s). The ET_{CO₂} at the time of PA disappearance was 47 ± 1.9 mmHg (range, 44–51 mmHg) and significantly correlated with ET_{CO₂} at PA appearance ($r = 0.95$, $P < 0.001$). There was also some hysteresis in the ET_{CO₂} at onset and offset of PA. Unlike a significant positive correlation between ET_{CO₂} and age in the non-PA group, there was a significant negative correlation between threshold ET_{CO₂} for development of PA and the age in the PA group; older patients had a lower threshold ET_{CO₂} (fig. 2). The lowest ET_{CO₂} at appearance of PA was 52 mmHg in a 71-yr-old man, and the highest ET_{CO₂} in the non-PA group was 50 mmHg in two women 74 and 85 yr of age.

Discussion

Respiratory acidosis has a series of well-known cardiovascular consequences, especially during halothane anesthesia. Hypercapnia can cause direct depression of cardiac muscle, but at the same time it causes reflex sympathetic stimulation. In addition, increases in cardiac output in response to hypercapnia tend to be minimal during halothane anesthesia.⁸ In this study, a possible effect of hypercapnia on myocardial contractility was examined, which is the alternation in pulse amplitude. Although a very strong association between hypercapnia and development of PA has been shown in this study, it cannot be said that this relationship is a cause-and-effect one. Both may be the result of a coincidental factor such as certain patterns of autonomic nervous system activities that may be inherent in anesthesia with spontaneous respiration. This relationship has not been investigated and reported *in vivo*. McCall⁵ and Orchard⁶ have shown that hypercapnia caused mechanical alternans in isolated

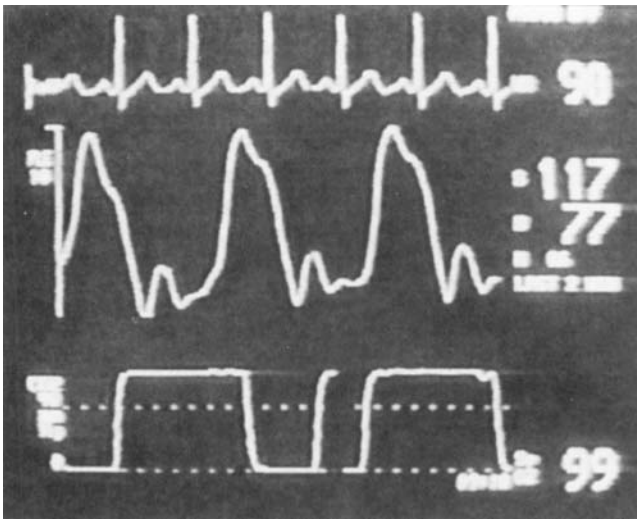


Fig. 3. A typical alternans pattern associated with hypercapnia ($ET_{CO_2} = 60$ mmHg) in the presence of 1.6% end-tidal halothane concentration. Parallel electrocardiogram, plethysmogram, and capnogram tracing 10 min after induction of anesthesia in a 39-yr-old man approximately 130 s after development of pulsus alternans. The blood pressure shown here was recorded at the very beginning of PA. This patient developed sinus tachycardia, tachypnea, systolic hypertension (165 mmHg) followed by blood pressure reduction (90/55 mmHg), and minimal desaturation (oxygen saturation 94%, fraction of inspired oxygen = 1) 3 min after PA occurrence.

ferret myocardial fiber. The presence of PA may falsely divide the measured heart rate values by a factor of two.⁹ A possible explanation for the appearance of PA during general anesthesia with halothane in association with hypercapnia is that these two factors both may cause a decompensation in the contractility state of the left ventricle.⁸ There also may be a role for myocardial ischemia induced by elevated levels of carbon dioxide.¹⁰ Other drugs and techniques may also contribute to the development of PA during general anesthesia. Freeman and Steinbrook¹¹ described a patient who developed PA after fentanyl injection.

In the present study, the total duration of PA was < 2 min, and no patient developed abnormality in vital signs that could be attributed to the development of PA. Although no controlled study has been performed to investigate the effects of longer durations of PA on vital

signs, based on their past and present personal experiences (fig. 3) with hypercapnia-induced PA (duration longer than 2 min), the authors suggest initiation of controlled ventilation to lower ET_{CO_2} and stop the PA.

A special and possibly new use of pulse oxymetry has been demonstrated in this study, *i.e.*, monitoring of consecutive plethysmographic pulse waves with respect to the equality of neighboring waves' amplitude. It is evident that this device can be used to diagnose PA, although its sensitivity and specificity have not yet been determined.

In conclusion, in addition to the classic use of pulse oxymetry for monitoring arterial oxygenation, there may be a role for it to detect high levels of hypercapnia during general anesthesia, especially with spontaneous respiration.

References

1. Pulsus alternans. Dorland's Illustrated Medical Dictionary: 28th ed. Philadelphia, Saunders, 1994, p 1388
2. Perloff JK, Braunwald E: The physical examination, Heart disease, 5th Edition. Edited by Braunwald E. Philadelphia, Saunders, 1997, pp 22-3
3. Carlson CJ: Postextrasystolic pulsus alternans and heart rate. *Am J Physiol* 1984; 246:H245-9
4. Lab MJ: Pulsus alternans. *Cardiovasc Res* 1993; 27:1407-12
5. McCall E: The effect of acidosis on interval-force relation and mechanical restitution in ferret papillary muscle. *J Physiol Lond* 1991; 432:45-63
6. Orchard CH: Mechanical alternans during acidosis in ferret heart muscle. *Circ Res* 1991; 68:69-76
7. Shangraw RE: Acid base balance, Anesthesia, 5th Edition. Edited by Miller RD. Philadelphia, Churchill Livingstone, 2000, pp 1392-3
8. Benumof JL: Respiratory physiology and respiratory function during anesthesia, Anesthesia, 5th Edition. Edited by Miller RD. Philadelphia, Churchill Livingstone, 2000, pp 614-5
9. Mark JB, Slaughter TF, Reves JG: Cardiovascular monitoring, Anesthesia, 5th Edition. Edited by Miller RD. Philadelphia, Churchill Livingstone, 2000, pp 1161-229
10. Dilly SG: Electrophysiological alternans and restitution during acute regional ischemia in the myocardium of anesthetized pigs. *J Physiol Lond* 1988; 402:315-33
11. Freeman AB, Steinbrook RA: Recurrence of pulsus alternans after fentanyl injection in a patient with aortic stenosis and congestive heart failure. *Can Anaesth Soc J* 1985; 32:654-7