

References

1. Mandabach M, McCann D, Thompson G: Body art: Another concern for the anesthesiologist. *ANESTHESIOLOGY* 1998; 88:279-80
2. Rosenberg A, Young M, Bernstein R, Albert D, Mandabach M,

Anesthesiology
2000; 93:308-9
© 2000 American Society of Anesthesiologists, Inc.
Lippincott Williams & Wilkins, Inc.

McCann D, Thompson G. Tongue rings: Just say no. *ANESTHESIOLOGY* 1998; 89:1279-80

(Accepted for publication March 8, 2000.)

Double-access-port Endotracheal Tube for Selective Lung Ventilation in Pediatric Patients

To the Editor:—Recent developments of thoroscopic surgical instruments and techniques have increased the demand for selective lung ventilation in younger children. Because the use of pediatric double-lumen endotracheal tubes¹ is limited, this is conventionally accomplished by blocking the required bronchus with a Fogarty embolectomy catheter² or with a pulmonary artery catheter.³ In most reported cases, a bronchial blocker is placed blindly or through a rigid bronchoscope before tracheal intubation. Appropriate positioning of the blocker is subsequently confirmed by fiberoptic bronchoscopy, auscultation, or chest radiography. However, these methods entail two major disadvantages. First, hypoxemia can occur during the placement of a blocker. Second, when dislocation of the blocker occurs during surgery, repositioning is difficult.

To overcome these problems, we fabricated a double-access-port endotracheal tube by combining two conventional Murphy-type tubes for the use of one-lung ventilation in pediatric patients.

For the equipment preparation (fig. 1), a tracheal tube of the appropriate inner diameter (ID) (uncuffed or cuffed) is selected (inner tube). Another tube of ID within 0.5 mm larger than the outer diameter (OD) of the inner tube is prepared (outer tube). A side port is made at a position approximately 8 cm from the proximal end of the inner tube. The distal three fifths of the outer tube is cut off, and a side port slightly larger than the OD of the inner tube is also made at 2 or 3 cm proximal from the distal cut end. These side holes can be cut simply with scissors in the folded tubes and with an appropriate surgical instrument, such as an aorta punch. The inner tube then protrudes from the side port through the distal cut end of the outer tube, such that the side port of the inner tube is placed within the outer tube lumen. To facilitate insertion, water lubrication is helpful. For a cuffed inner tube, an inverse insertion is recommended to avoid possible cuff damage. A tight air seal can be easily achieved by taping if an air leak is found at the bifurcation of the tubes. The taping can also prevent slippage of the tubes that could result in an airway obstruction. The 15-mm connector of the outer tube is sealed with a silted rubber cap so that it can be used as an access port for a blocking catheter. To ensure airtightness during the blocker operation, we insert a shortened catheter sheath into this rubber cap.

This tube provides independent access for blocker operations and ventilation both. Thus, sufficient ventilation can be obtained during the

blocker positioning. This could decrease the risk of hypoxemia and make intraoperative repositioning of the balloon practicable.

Currently, we have treated seven patients, aged 18 months-5 yr, who underwent thoroscopic surgery with the use of this device. In the youngest patient, a 5.0-mm ID inner tube with a 7.0-mm ID outer tube was used. A Fogarty catheter (4-French) was positioned in the

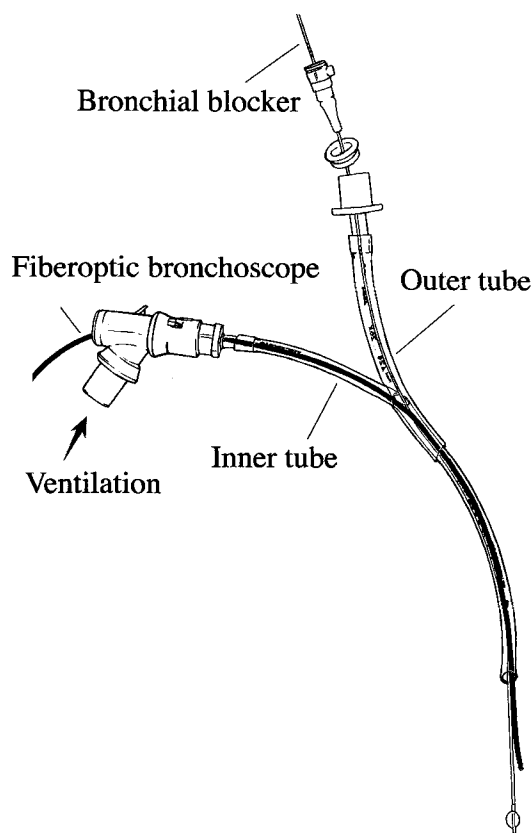


Fig. 1. A double-access-port endotracheal tube. Ventilation is obtained through the inner tube. A bronchial blocker (a Fogarty catheter) is inserted through the outer tube. A fiberoptic bronchoscope passed through the inner tube aids in blocker positioning.

Support was provided solely from institutional and/or departmental sources.

CORRESPONDENCE

appropriate bronchus of each child during fiberoptic vision (Olympus LF-P, 2.2-mm OD, or LF-DP, 3.1-mm OD, passed through the inner tube; Olympus Optical Co., Ltd., Tokyo, Japan). Sufficient ventilation through the inner tube was obtained during the blocker positioning using a rubber-sealed Y connector (Bodai Swivel Y; Sotek Medical Inc., Hingham). Inflation of the balloon established adequate selective lung ventilation as well as excellent surgical access in all cases.

Masahiko Takahashi, M.D.
Lecturer
m-takaha@mail.cc.tohoku.ac.jp
Takashi Horinouchi, M.D.
Assistant Professor
Masato Kato, M.D.
Associate Professor
Yasuhiko Hashimoto, M.D.

Anesthesiology
2000; 93:309-10
© 2000 American Society of Anesthesiologists, Inc.
Lippincott Williams & Wilkins, Inc.

Professor and Chairman
Department of Anesthesiology
Tohoku University Postgraduate Medical School
Sendai 980-8574, Japan

References

1. Marraro G: Selective endobronchial intubation in paediatrics: The Marraro paediatric bilumen tube. *Paediatr Anaesth* 1994; 4:255-8
2. Vale R: Selective bronchial blocking in a small child. *Br J Anaesth* 1969; 41:453-4
3. A blocking vs. selective intubation. *ANESTHESIOLOGY* 1982; 55: 555-6

(Accepted for publication March 8, 2000.)

A Versatile Alternative to Standard Laryngoscopy

To the Editor:—Conventional laryngoscopy may be difficult for the operator with weakness in the upper extremity used for manipulating the laryngoscope. I recently developed left-sided suprascapular nerve palsy, resulting in atrophy of the infraspinatus muscle. Having no power to perform laryngoscopy with my left arm, I began using an alternative method for tracheal intubation.

Standing along the patient's right side, I hold the laryngoscope in the right hand, with the blade end of the handle between my thumb and index finger and the blade pointing toward the patient. After induction of anesthesia, the blade is gently inserted into the patient's mouth, the laryngoscope tip is directed to the base of the tongue, and force is applied to the jaw with a pulling motion that aligns the oropharyngeal and laryngeal axes vertically. Thus, the oropharyngeal axis is pulled to a position anterior to the glottis, and the glottis is viewed by looking directly downward. Because the tube is inserted along a vertical line, I call this technique vertical intubation (fig. 1). This method may also provide a mechanical advantage over standard laryngoscopy because one uses very large muscle groups to lift of the jaw.

A similar method, named "inverse intubation" by Guertner,¹ has been described for emergency intubations in the field with the rescuer standing or kneeling over or next to the patient. Hilker *et al.*² reported several cases with limited access to the patient or difficult patient positioning in which the technique provided some advantage over standard laryngoscopy.

Vertical intubation offers excellent exposure of the airway in many patients and may be a useful backup to standard laryngoscopy.

Guy L. Weinberg, M.D.
Associate Professor
University of Illinois at Chicago College of Medicine

Supported by the Department of Anesthesiology, Chicago VA Hospital, Westside Division, Chicago, Illinois.

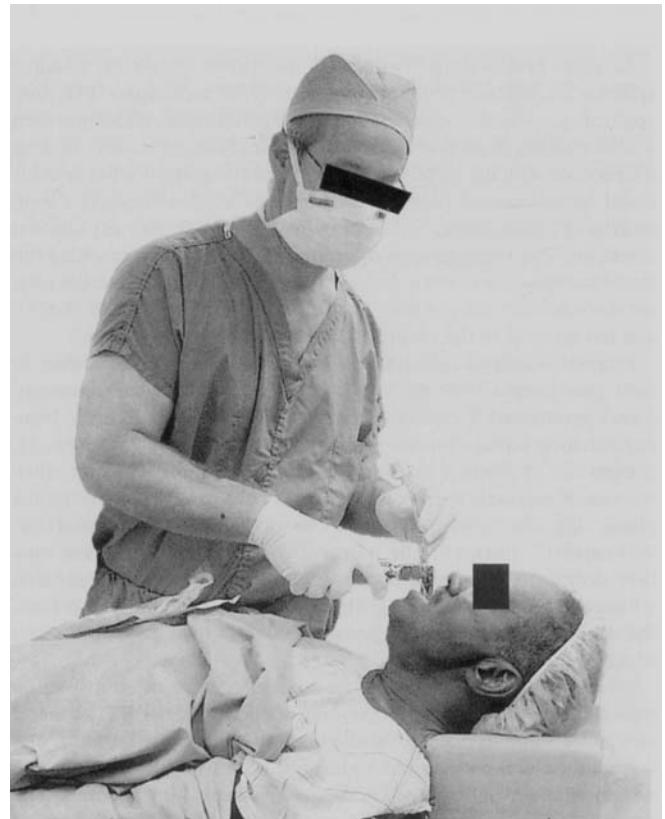


Fig. 1. Note the direction of insertion of the tracheal tube. Photo courtesy of Dr. Miguel Teresi, Chief of General Surgery, Chicago VA Hospital, Westside Division, Chicago, Illinois.