

CORRESPONDENCE

Anesthesiology
2000; 92:1855-6
© 2000 American Society of Anesthesiologists, Inc.
Lippincott Williams & Wilkins, Inc.

The McCoy Laryngoscope Expands the Laryngeal Aperture in Patients with Difficult Intubation

To the Editor:—The McCoy levering laryngoscope is a useful device,¹⁻³ but does not uniformly improve the view in some cases of difficult laryngoscopy.^{2,3} We report a case in which the McCoy laryngoscope did not improve the direct view of the larynx, but instead lifted the epiglottis and expanded structures around the laryngeal aperture (LA), thereby facilitating “blind” tracheal intubation.

A 72-yr-old woman (155 cm, 55 kg) with femoral neck fracture was scheduled to undergo surgical repair. At the preoperative visit, the patient's airway could not be evaluated because she had senile dementia and could not respond to verbal commands. Anesthesia was induced with fentanyl 50 µg and thiopental 225 mg, and vecuronium 6 mg was administered. The patient's lungs were easily ventilated through a face mask. At laryngoscopy with a Macintosh 3 blade (Welch Allyn, NY), only the epiglottis could be seen despite the application of optimal external laryngeal manipulation.⁴ Three attempts at intubation with a stylet by blind probing failed. After several additional minutes of mask ventilation, an assistant nasally inserted a fiber-optic bronchoscope (FOB) (BF-P30; Olympus, Tokyo) into the laryngopharynx to

assess the area of the LA during laryngoscopy.⁵ With the FOB still in place, laryngoscopy using the Macintosh 3 blade was reattempted. Fiberscopy revealed that the epiglottis was close to the posterior pharyngeal wall, that the laryngoscope did not expand the structures around the LA, and that the LA area was very small. A McCoy levering laryngoscope (Penlon, Abingdon, UK) was used to reattempt a fiber-optic assessment of the LA area. With the blade in the neutral position, the direct view and the fiber-optic view were similar to those obtained during Macintosh laryngoscopy (fig. 1A). When the tip of the levered blade was elevated, only the slightly lifted epiglottis could be seen under direct vision; however, fiberscopy showed that the epiglottis was lifted, that the LA was markedly expanded, and that the glottis was clearly visible through the FOB (fig. 1B). The FOB was removed and an endotracheal tube with the curved stylet was readily inserted into the trachea by blind probing with the levering laryngoscope blade in the elevated position. Successful placement of the endotracheal tube was confirmed by capnography and auscultation.

Our case illustrates that even if the McCoy laryngoscope does not

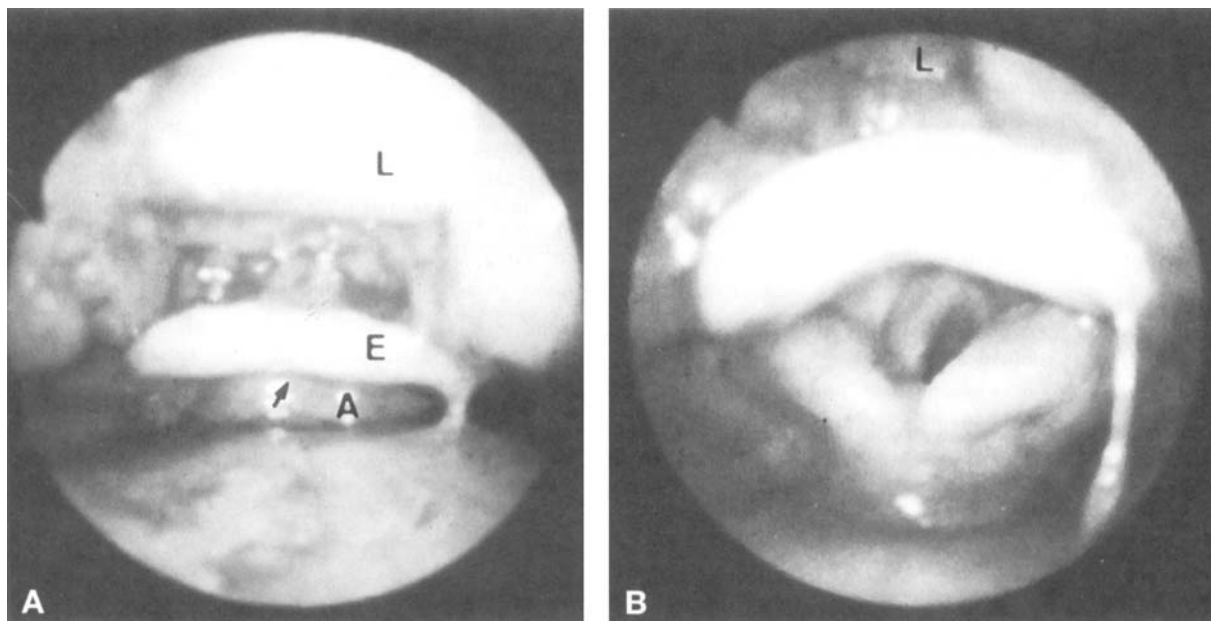


Fig. 1. (A) Fiber-optic view of the larynx during laryngoscopy using the McCoy laryngoscope in a patient with difficult intubation, with the blade in the neutral position. Although the blade tip is correctly placed in the vallecula, the epiglottis is close to the posterior pharyngeal wall, the laryngeal aperture (arrow) is not expanded, and the area is small. The fiber-optic view was similar to that seen during a Macintosh laryngoscopy. Only the epiglottis was visible under direct vision. L = laryngoscope; E = epiglottis; A = arytenoid. (B) Fiber-optic view of the larynx during laryngoscopy using the McCoy laryngoscope in a patient with difficult intubation, with the blade in the elevated position. When the levered tip of the blade is elevated, the epiglottis is lifted, the laryngeal aperture is expanded, and the glottis is clearly visible through the fiberscope. The laryngeal aperture area seen fiberoptically is markedly expanded by the levered tip of the McCoy blade. Note that only the epiglottis could be seen directly.

improve the direct view of the larynx, the likelihood of successful intubation by blind probing can be increased by expanding the target for intubation. In a previous study,⁵ we demonstrated that the LA area provided by a laryngoscope, assessed by fiberoptic, was an important determinant of the degree of intubation difficulty in patients with difficult laryngoscopy. Even when only the epiglottis can be seen under direct vision, if a laryngoscope can lift the relaxed epiglottis and expand the collapse of soft tissues around the LA caused by general anesthesia and muscle relaxation,^{6,7} the LA area provided by the laryngoscope (the target for intubation) is large and tracheal intubation by blind probing is relatively easy (*i.e.*, difficult laryngoscopy, but easy intubation).^{5,8} However, when the LA is not visible and a laryngoscope cannot lift the epiglottis or expand the LA collapse, the LA area is small and intubation is difficult (*i.e.*, difficult laryngoscopy, difficult intubation).^{5,8} In our case, the LA area provided by the Macintosh laryngoscope was small, and intubation was difficult. In contrast, elevating the tip of the blade of the McCoy laryngoscope lifted the epiglottis and expanded the collapse of the LA, which facilitated blind tracheal intubation, though it could not improve the direct view of the larynx. The levered tip of the McCoy laryngoscope could apply force in an effective direction, though the Macintosh laryngoscope could not.

In this case, we used the FOB only to assess the LA area, and introduced an endotracheal tube into the trachea by blind probing because the endotracheal tube had been equipped with a stylet and was not prepared for fiberoptic-guided intubation. Blind intubation using the McCoy laryngoscope can be useful even without fiber-optic evaluation of the LA, because this method does not require a special technique and only the levering maneuver can increase the likelihood of successful intubation; however, multiple attempts should be avoided. Further studies are needed to establish the usefulness of this technique. A McCoy laryngoscope can also help to intubate the trachea by video-visual control⁹ or by a FOB-guided technique combined with a laryngoscope, because the laryngoscope facilitates the view of the glottis through the FOB and the passage of the endotracheal tube through the glottis.¹⁰ We have experienced several cases of difficult intubation in which the McCoy laryngoscope lifts the epiglottis and expands the LA, thereby facilitating tracheal intubation by blind probing, by video-visual control,⁹ or by the fiberoptic-guided technique, despite the lack of improvement in the direct view of the larynx.

Kazuyoshi Aoyama, M.D.
Chief Anesthesiologist

Etsuko Nagaoka, M.D.
Staff Anesthesiologist
Department of Anesthesia
Moji Rosai Hospital
Ichiro Takenaka, M.D.
Staff Anesthesiologist
Tatsuo Kadoya, M.D.
Chief Anesthesiologist
Department of Anesthesia
Nippon Steel Yawata Memorial Hospital
Kitakyushu, Japan

References

1. McCoy EP, Mirakhor RK: The levering laryngoscope. *Anaesthesia* 1993; 48:516-9
2. Tuckey JP, Cook TM, Render CA: An evaluation of the levering laryngoscope. *Anaesthesia* 1996; 51:71-3
3. Chisholm DG, Calder I: Experience with the McCoy laryngoscope in difficult laryngoscopy. *Anaesthesia* 1997; 52:896-913
4. Benumof JL: Conventional (laryngoscopic) orotracheal and nasotracheal intubation (single-lumen tube). *Airway Management: Principles and Practice*. Edited by Benumof JL. St. Louis, Mosby, 1995, pp 266-8
5. Takenaka I, Aoyama K, Tatsuo K, Sata T, Shigematsu A: Fiberoptic assessment of laryngeal aperture in patients with difficult laryngoscopy. *Can J Anesth* 1999; 46:226-31
6. Benumof JL: Management of the difficult adult airway: With special emphasis on awake tracheal intubation. *ANESTHESIOLOGY* 1991; 75:1087-110
7. Murashima K, Fukutome T: Effect of jaw-thrust manoeuvre on the laryngeal inlet. *Anaesthesia* 1998; 53:203-4
8. Aoyama K, Takenaka I: Difficult laryngoscopy and difficult intubation. *Anaesthesia* 1999; 54:811-2
9. Aoyama K, Takenaka I, Sata T, Shigematsu A: Use of the fiberoptic-video camera system for difficult tracheal intubation. *Br J Anaesth* 1996; 77:662-4
10. Asai T, Matsumoto S, Shingu K: Use of the McCoy laryngoscope or fingers to facilitate fiberoptic-aided tracheal intubation. *Anaesthesia* 1998; 53:903-9

(Accepted for publication January 26, 2000.)