

Epileptiform Electroencephalogram during Mask Induction of Anesthesia with Sevoflurane

Arvi Yli-Hankala, M.D., Ph.D.,* Anne Vakkuri, M.D.,† Mika Särkelä, M.Sc.,‡ Leena Lindgren, M.D., Ph.D.,§ Kari Korttila, M.D., Ph.D.,|| Ville Jäntti, M.D., Ph.D.¶

Background: Sevoflurane is suggested as a suitable anesthetic agent for mask induction in adults. The authors recently found that hyperventilation during sevoflurane-nitrous oxide-oxygen mask induction is associated with cardiovascular hyperdynamic response. We tested the hypothesis that the hyperdynamic response can be explained by electroencephalography (EEG) findings.

Methods: Thirty women were randomly allocated to receive sevoflurane-nitrous oxygen-oxygen mask induction using a single-breath method, followed by either spontaneous breathing ($n = 15$) or controlled hyperventilation ($n = 15$) for 6 min. EEG was recorded. Blood pressure and heart rate were recorded at 1-min intervals.

Results: Epileptiform EEG activity (spikes or polyspikes) was seen in all patients with controlled hyperventilation, and in seven patients with spontaneous breathing ($P < 0.01$). Jerking movements were seen in three patients with con-

trolled hyperventilation. In the controlled hyperventilation group, heart rate increased 54% from baseline at 4 min after induction ($P < 0.001$). Mean arterial pressure increased 17% ($P < 0.05$), peaking at 3 min. In the spontaneous breathing group, heart rate showed no change, and mean arterial pressure decreased by 14% ($P < 0.01$) at 6 min. Heart rate and mean arterial pressure differed significantly between the groups from 2 min after beginning of the induction to the end of the trial. An increase in heart rate of more than 30% from baseline always was associated with epileptiform EEG activity.

Conclusions: Sevoflurane mask induction elicits epileptiform EEG patterns. These are associated with an increase in heart rate in patients with controlled hyperventilation and also during spontaneous breathing of sevoflurane. (Key words: Anesthetic induction; electroencephalogram; human; ventilation mode.)

This article is featured in "This Month in Anesthesiology." Please see this issue of ANESTHESIOLOGY, page 7A.

* Associate Professor of Anesthesia, Department of Obstetrics and Gynecology, Helsinki University Central Hospital.

† Staff Anesthesiologist, Department of Obstetrics and Gynecology, Helsinki University Central Hospital.

‡ Research Scientist, Department of Anesthesiology, Oulu University Hospital, Oulu, Finland.

§ Associate Professor of Anesthesia, IV Department of Surgery, Helsinki University Central Hospital.

|| Professor of Anesthesia and Critical Care, Department of Obstetrics and Gynecology, Helsinki University Central Hospital.

¶ Associate Professor of Clinical Neurophysiology, Department of Clinical Neurophysiology, Oulu University Hospital, Oulu, Finland.

Received from the Department of Obstetrics and Gynecology and the Department of Surgery, Helsinki University Central Hospital, Helsinki, Finland. Submitted for publication March 1, 1999. Accepted for publication June 3, 1999. Supported by Helsinki University Central Hospital Research Fund No. TYH9242 from Helsinki University Central Hospital, Helsinki, Finland.

Address reprint requests to Dr. Yli-Hankala: Anesthesia Research Group, Department of Obstetrics and Gynecology, Helsinki University Central Hospital, P. O. Box 140, FIN-00029 HYKS, Finland. Address electronic mail to: arvi.yli-hankala@huch.fi

SEVOFLURANE is a nonpungent, ultra-short-acting volatile anesthetic. Clinical trials have confirmed its suitability for mask induction in adults.¹ Sevoflurane is well-tolerated, and rapid changes in inhaled concentrations during normoventilation usually are not associated with hyperdynamic responses, contrary to isoflurane² or desflurane.³

We recently reported that controlled hyperventilation during sevoflurane-nitrous oxide-oxygen mask induction is associated with a transient hyperdynamic response not seen in patients who breathe spontaneously during sevoflurane mask induction.⁴ In that study, two of the hyperventilated patients also expressed jerking movements of the shoulders and upper arms during the trial, resembling motor signs of epileptic activity. Sevoflurane has been associated in some anecdotal reports with epileptiform electroencephalogram (EEG) activity.^{5,6} We previously had shown an association between EEG burst suppression and heart rate in isoflurane⁷ and enflurane⁸ anesthesia. In the current randomized, controlled study we tested the hypothesis that the hyperdynamic response is associated with, and may in part be explained by, electroencephalographic findings during sevoflurane mask induction.

Table 1. Demographic Data

	Spontaneous Breathing	Controlled Hyperventilation
n	15	15
Age (yr)	40 ± 6	38 ± 7
Weight (kg)	69 ± 9	65 ± 8
Height (cm)	167 ± 6	165 ± 5

Age, weight, and height expressed as mean ± SD. No significant differences were noted.

Materials and Methods

After obtaining institutional approval and written individual informed consent, 30 patients, American Society of Anesthesiologists physical status I or II, undergoing elective gynecologic surgery participated in the study (table 1). Exclusion criteria were history of cardiac, pulmonary, or neurologic disease; body mass index > 28 kg/m²; history of esophageal reflux; alcohol or drug abuse; and age older than 50 yr or younger than 18 yr.

Patients fasted for at least 8 h before anesthesia. They were premedicated with 5 mg oral diazepam, 60 min before anesthesia. At arrival in the operating room, infusion of Ringer's lactate solution was started. Routine monitoring during anesthesia consisted of heart rate, electrocardiography, and measurement of pulse oximetry, end-tidal carbon dioxide pressure, end-tidal sevoflurane concentration, and blood pressure. Ventilatory and gas measurements were performed from the ventilatory circuit at the connecting piece close to the face mask. These measures, together with ventilatory frequency and ventilation minute volume, were recorded at 1-min intervals. These data were collected using the Datex-Ohmeda AS/3 Anesthesia Monitor (Datex-Ohmeda Division, Instrumentarium, Helsinki, Finland).

To collect the EEG data, eight Zipprep electrodes (Aspect Medical Systems, Natick, MA) were positioned on both mastoid bones: at F7, F8, Fp1, and Fp2 (International 10-20 System)⁹ and at Fpz.¹⁰ A ground electrode was placed on the forehead. The electroencephalographic signal was band-pass filtered (1.0–50 Hz), amplified, and displayed (Aspect A-1000 EEG Monitor; Aspect Medical Systems) from four bipolar electrode pairs: Fp1–left mastoid, Fp2–right mastoid, Fpz–F7, and Fpz–F8. EEG data were digitized and stored on a computer for later analyses.

Patients were allocated according to computer-generated random numbers into two groups: spontaneous breathing and controlled hyperventilation groups. In the latter, we aimed at an end-tidal pressure of carbon dioxide of 26 mmHg. All patients breathed oxygen *via* a clear

face mask for 2 min before anesthetic induction. Baseline values for heart rate, mean arterial pressure (MAP), and pulse oximetry were measured. Sevoflurane anesthesia was induced *via* a face mask with a semiclosed anesthesia system primed with a fresh gas flow of 10 l/min (N₂O: 5 l/min; O₂: 5 l/min) and a sevoflurane vaporizer (Sevoflurane Abbott Vapor 19.3; Draegerwerk AG, Lübeck, Germany) set at a maximum of 8%. The patients were asked to exhale to the residual volume, followed by a vital-capacity breath with a face mask placed tightly over the nose and the mouth, and then to hold their breaths as long as possible. Thereafter, the patients were asked to breathe normally. A stopwatch was started when the patients took the first breath from the face mask. After they became unresponsive to verbal commands, manually controlled ventilation was started in the controlled hyperventilation group by squeezing of the anesthesia bag. End-tidal carbon dioxide pressure was observed and maintained at approximately 26 mmHg. The patients in the group breathing spontaneously did so throughout the study.

The sevoflurane–nitrous oxide–oxygen mask anesthetic induction with 8% inspired sevoflurane lasted for 6 min. At the end of this induction period, blood-gas analysis was performed for all patients using a blood sample collected from the radial artery by a single-puncture method. After collection of the arterial blood sample, the trial was complete. It was followed by tracheal intubation, facilitated with rocuronium. Thereafter, patients were treated according to the clinical requirements of their operations.

The study design was double-blind: Patients were not aware of their treatments, and EEGs were classified by a single neurophysiologist (V.J.) familiar with anesthesia EEGs but blinded to the patients' ventilation modes. The electroencephalographic phenomena were classified as blink (last eye blink), fast activity (> 13 Hz), slow activity (< 8 Hz), delta activity (< 4 Hz), slow delta activity (< 2 Hz), delta monophasic activity, slow delta monophasic activity with spikes, burst suppression, burst suppression with spikes, polyspikes, and rhythmic polyspikes (table 2, fig. 1). In this terminology, *delta monophasic activity* refers to waveform activity in the delta range without any variability in frequency; *polyspike* refers to a spike with more than two negative and positive deflections; and *rhythmic polyspikes* refers to polyspikes appearing at regular intervals. To differentiate between epileptiform electroencephalographic activity and artifacts, only phenomena occurring simulta-

Table 2. Occurrence of Classified EEG Features

	Spontaneous Breathing [n (%)]	Controlled Hyperventilation [n (%)]	Result
Fast activity	15 (100)	15 (100)	NS
Slow activity	15 (100)	15 (100)	NS
δ Activity	14 (93)	14 (93)	NS
Slow δ activity	12 (80)	10 (67)	NS
δ Monophasic activity	9 (60)	13 (87)	NS
Slow δ monophasic activity with spikes	4 (27)	5 (33)	NS
Burst suppression	2 (13)	0	NS
Burst suppression with spikes	0	3 (20)	NS
Polyspikes	6 (40)	13 (87)	$P = 0.011$
Rhythmic polyspikes	1 (7)	13 (87)	$P = 0.00001$

EEG = electroencephalogram; NS = no significant difference.

neously, even if not totally symmetrically in all four EEG channels, were classified.

Statistical Analysis

The parametric data were analyzed using analysis of variance for repeated measures, followed by paired and unpaired *t* tests as *post hoc* tests. The chi-square test and Fisher exact test, if appropriate, were used for nonparametric data. Statistics were analyzed using GB-Stat V6.5 for Windows (Dynamic Microsystems, Silver Spring, MD) or Statistical Package for the Social Sciences, Windows version 6.0.1 (SPSS, Chicago, IL). $P < 0.05$ was considered statistically significant. Parametric data are expressed as the mean \pm SD.

Results

Demographic characteristics of those patients breathing spontaneously and those who underwent controlled hyperventilation were similar (table 1). The hemodynamic profiles before anesthesia in these two groups were similar. The trial was completed without complications in any patients. No patient was excluded from the study.

The evolution of EEG findings during anesthetic induction with a sevoflurane-nitrous oxide-oxygen mask typically started with changes in eye movements: the slowing of saccadic eye movements and ending of blinks, followed by slow-rolling eye movements. This was accompanied by an increase in beta-range (> 13 Hz) activity and very rapidly also with an increase in slow (< 8 Hz) activity and delta activity (figs. 1 and 2). At this point, the EEG recordings between the two study groups started to differ. In most patients breathing spontaneously, mixed EEG activity or monophasic slow delta activity with or without spikes continued to the end of

the study (tables 2 and 3, fig. 2). Rhythmic polyspikes were seen in one patient with spontaneous breathing. In that patient, heart rate increased from 62 to 88 beats/min 3 min after beginning of induction.

The EEGs of all the patients undergoing controlled hyperventilation showed periods of polyspikes or rhythmic polyspikes (tables 2 and 3, fig. 3). In 11 patients, periods of rhythmic polyspikes were associated with EEG suppressions. Burst suppression with spikes was recorded in three patients (tables 2 and 3, fig. 1). Movements were seen in four patients undergoing hyperventilation. Three of these expressed jerking movements of the shoulders, biceps, or arms, and bilateral plantar flexion was seen in one patient. Movements began at 60–120 s after the first inhalation of sevoflurane and were associated with slow delta EEG activity with or without spikes. Polyspikes or rhythmic polyspikes were seen later in all the patients experiencing movement. Heart rate reached its maximum (121–145 beats/min) 0–60 s after the end of such movement. No generalized EEG discharges were recorded in any patient. An EEG recording of a patient showing jerking movements is presented in figure 3.

In patients breathing spontaneously, delta monophasic activity persisted longer than in patients undergoing controlled hyperventilation. In patients undergoing hyperventilation, polyspikes occurred earlier. Otherwise, the time of appearance or duration of EEG features did not differ between the two groups (table 3).

Heart rate and MAP started to differ between the two groups 2 min after beginning of induction (figs. 4 and 5). Patients breathing spontaneously showed no change in heart rate. In patients undergoing controlled hyperventilation, the heart rate increased from 78 ± 14 to 121 ± 18 beats/min ($P < 0.001$) at 4 min after induction and remained at that elevated level to the end of the trial.

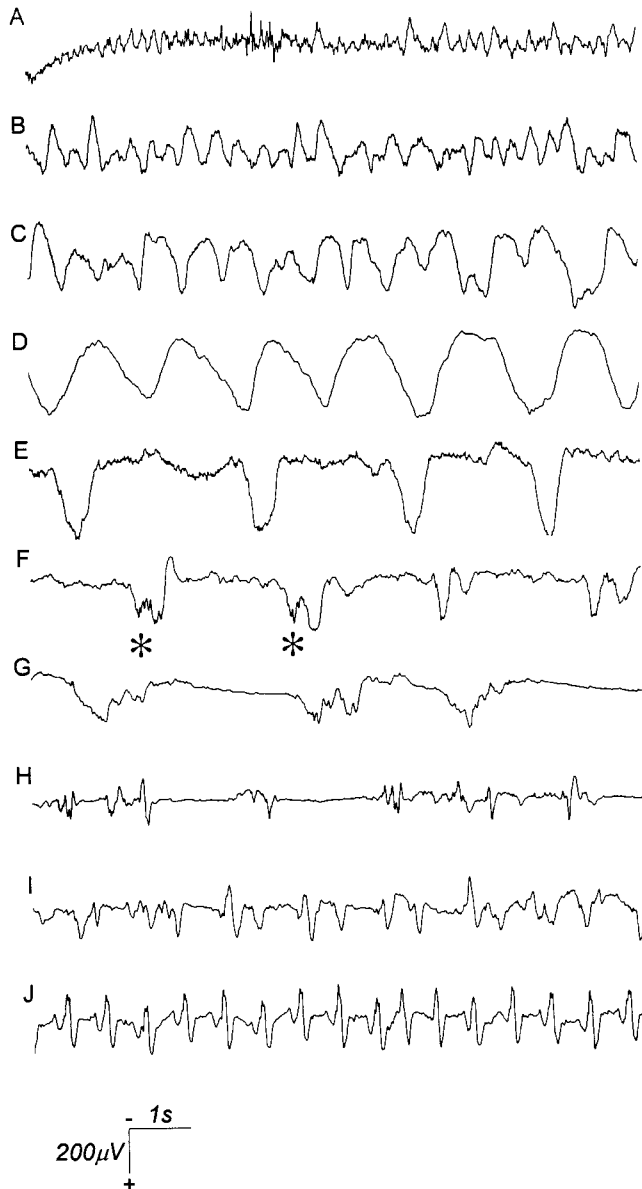


Fig. 1. Classified electroencephalogram phenomena. Fast (A), slow (B), delta (C), and slow delta (D) activity, delta monophasic activity (E), slow delta monophasic activity with spikes (F), burst suppression (G), burst suppression with spikes (H), polyspikes (I), and rhythmic polyspikes (J) are presented. Spikes are indicated with asterisks in trace F. Electroencephalography was filtered with band-pass 1.0–50 Hz.

Mean arterial pressures between the two groups differed from 2 min after induction to the end of the study. In hyperventilated patients, MAP increased, whereas, in patients breathing spontaneously, it decreased.

In eight patients, no epileptiform EEG activity (spikes, polyspikes, or rhythmic polyspikes) was recorded dur-

ing the trial. All these patients were in the spontaneous breathing group ($P < 0.01$ between the study groups). A more than 30% increase in heart rate always was associated with epileptiform EEG activity (fig. 6). No such connection was seen between EEG and MAP. In patients showing epileptiform EEG, MAP increased by 8% from baseline at 3 min after beginning of induction. In patients showing no epileptiform EEG, MAP decreased by 9% (not significant).

Blood-gas analyses of arterial blood at 6 min after anesthetic induction showed mild respiratory alkalosis in patients undergoing controlled hyperventilation, and mild respiratory acidosis in those patients breathing spontaneously (table 4).

Discussion

Our hypothesis was confirmed. The increase in heart rate was associated with EEG findings of spikes, polyspikes, and rhythmic polyspikes. These findings were more commonly recorded in patients undergoing controlled hyperventilation, although they were also seen in patients allowed to breathe spontaneously.

Jerking movements were seen in three of our patients. These movements did not occur, however, in conjunction with EEG spikes or polyspikes, which are considered to be epileptiform phenomena.¹¹ Instead, the movements were observed before the epileptiform EEG activity began. Heart rate and, in some patients, blood pressure also began to increase during delta activity in EEG; that is, before epileptiform spikes or polyspikes occurred. This does not rule out an epileptic nature of the hemodynamic activity and jerking movements seen in the hyperventilated patients. Subcortical discharges can be recorded with the use of depth EEG electrodes without any signs of epileptic activity in scalp EEG.¹² In our previous enflurane study,⁸ a generalized epileptic seizure with motor activity occurred in a patient during a burst suppression EEG pattern. In that patient, similar to our current jerking patients, heart rate started to rise 1 min before spikes or cortical seizure activity were seen. In the current study, heart rate reached its maximum in all three jerking patients shortly after their movement responses, suggesting activation of the sympathetic nervous system. Rhythmic polyspikes were recorded in 13 of 15 patients undergoing hyperventilation; in 11, rhythmic polyspikes were seen during otherwise total EEG suppression. Generalized epileptic EEG discharges can occur during suppression, when EEG is

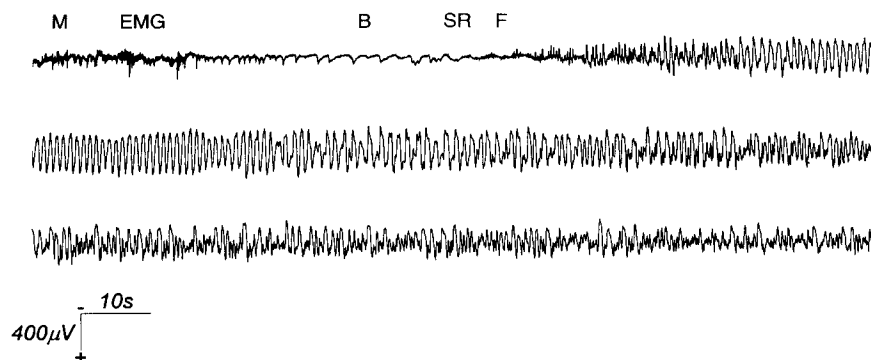


Fig. 2. Electroencephalogram (EEG) during anesthetic induction in a patient without epileptiform activity. Six minutes of electroencephalography (EEG) are presented in three 2-min sections. EEG is recorded with the Fp1–left mastoid electrode pair. Electromyogram and movement artifacts are followed by eye blinks, slow-rolling eye movement, and fast activity. The rhythmic slow activity, followed by mixed frequency slow activity, lasts until the end of the trial. B = eye blinks; EMG = electromyographic activity; F = fast EEG activity; M = movement artifact; SR = slow-rolling eye movement.

recorded on the scalp.¹³ We suggest subcortically induced transient epileptiform activity in those patients who have an unexpected increase in heart rate or blood pressure during sevoflurane mask induction. This activity can rapidly turn into motor activity, or it can be seen as rhythmic polyspikes in EEG recorded on the scalp. In all our patients this activity disappeared rapidly.

Therefore, our current findings may support in part the previous anecdotal reports of the clinically observed^{4,14} and the EEG-verified^{5,6} epileptic discharges during sevoflurane anesthesia. The rhythmic polyspikes associated with tachycardia seen here resemble very closely, both in shape and frequency, those polyspikes presented in an early enflurane study by Rosén and Söderberg.¹⁵ In their study of healthy, hyperventilated children, the rhythmic polyspikes changed to generalized epileptic discharges. Although we registered epileptiform EEG patterns, especially during hyperventilation, polyspikes were seen also in patients breathing spontaneously. We did not, however, record generalized EEG discharges in this study. Therefore, further studies are

needed to elucidate the possible relation of our findings with true epileptic activity.

The explanation for the occurrence of epileptiform EEG activity during anesthetic induction with sevoflurane mask is not clear. One possibility is the speed of the anesthetic induction, which may change the balance of neuronal synaptic inhibition and excitation in the central nervous system. These rapid changes at the target site have been suggested as an explanation for the seizures associated with propofol anesthesia,¹⁶ and the same mechanism can also play a role with sevoflurane. However, desflurane is an even faster anesthetic, yet it is not known to cause epileptiform activity.

Another possible mechanism explaining the differences in EEG is the ventilation mode itself. In patients breathing spontaneously, mean arterial carbon dioxide tension at 6 min after anesthetic induction was 52 mmHg, which probably caused cerebrovascular vasodilatation. Hyperventilation decreased the mean tension to 31 mmHg, which is sufficient to induce cerebrovascular vasoconstriction¹⁷ and alkalosis. Theoretically, this vaso-

Table 3. Time Interval (s from Beginning of Sevoflurane Inhalation) to the Appearance and Duration (s) of EEG Events during Induction of Anesthesia with Sevoflurane

	Spontaneous Breathing		Controlled Hyperventilation	
	Appearance	Duration	Appearance	Duration
δ Activity	78 ± 20	58 ± 67	66 ± 30	30 ± 14
Slow δ activity	99 ± 31	102 ± 87	97 ± 37	44 ± 25
δ Monophasic activity	139 ± 62	103 ± 53*	113 ± 28	50 ± 17
Slow δ monophasic activity with spikes	184 ± 91	47 ± 30	132 ± 17	50 ± 17
Burst suppression	255 ± 58†	76 ± 54	—	—
Burst suppression with spikes	—	—	298 ± 49	66 ± 49
Polyspikes	224 ± 41*	124 ± 46	190 ± 23	82 ± 45
Rhythmic polyspikes	281‡	79	248 ± 49	99 ± 57

Data are mean ± SD.

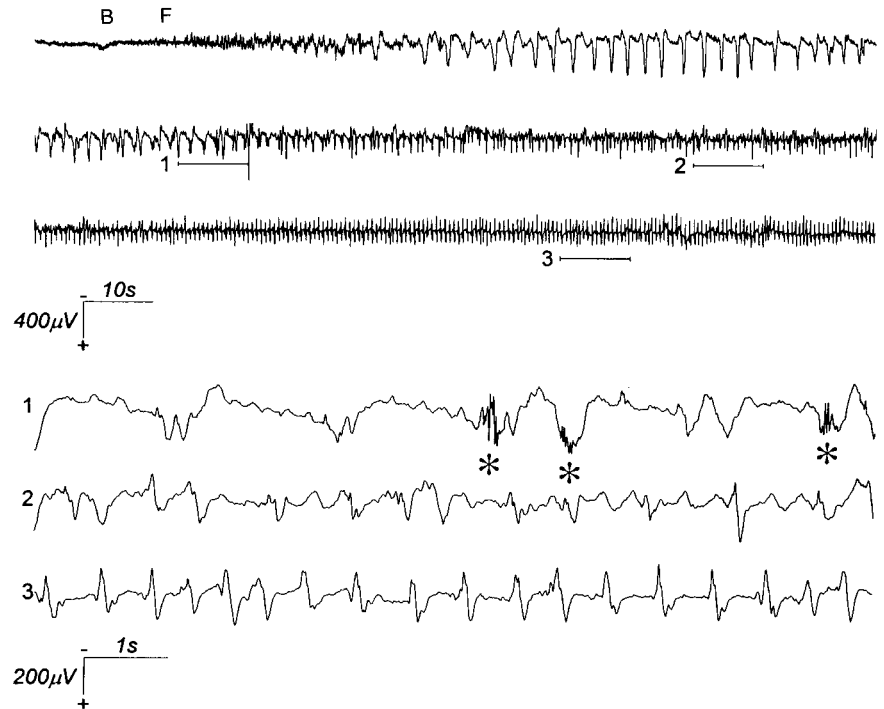
* Differences between groups significant at $P < 0.05$.

† Two observations.

‡ One observation.

EEG = electroencephalography.

Fig. 3. Electroencephalogram (EEG) during anesthetic induction in a patient with epileptiform EEG and jerking movements of the left shoulder area. Six minutes of electroencephalography (EEG) are presented in three 2-min sections. Three 10-s samples of EEG data, indicated with horizontal bars, are presented below with the corresponding number. EEG is recorded with the Fp2-right mastoid electrode pair. After an eye blink and fast activity, monophasic delta waves (first 2-min section) are seen. High-frequency polyspikes appear on top of these waves (second 2-min section, sample 1, asterisks). They are followed by arrhythmic mixed-frequency activity with low-frequency polyspikes (second 2-min section, sample 2), and rhythmic polyspike activity (third 2-min section, sample 3). Jerking movements occurred at 90–120 s (the latter half of the first 2-min section), corresponding with maximal increases in heart rate (from baseline, 84 to 121 beats/min) and MAP (from 98 to 126 mmHg). B = eye blink; F = fast EEG activity.



constriction and alkalosis, together with sevoflurane, may activate epileptiform EEG patterns. In our patients, the spikes occurred within 1.5 min of the beginning of hyperventilation, probably more quickly than the vasoconstrictive or pH effects of decreased carbon dioxide in

the brain. Furthermore, although the epileptiform EEG patterns in our study were more common in hyperventilated patients, they were also seen in 7 of 15 subjects not undergoing hyperventilation. Thus, ventilation mode

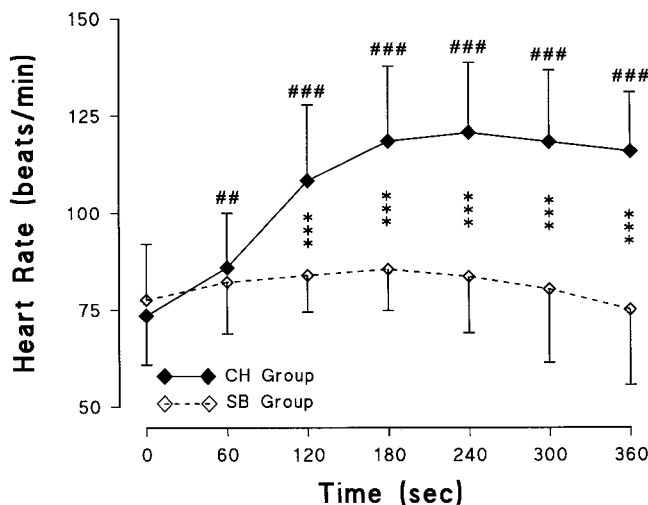


Fig. 4. Heart rate (beats/min) during the trial in patients with controlled hyperventilation (CH, closed diamond) and spontaneous breathing (SB, open diamond). Data are expressed as the mean \pm SD. # and ## = differences from the reference value in controlled hyperventilation group, at $P < 0.01$ and 0.001 , respectively. *** $P < 0.001$.

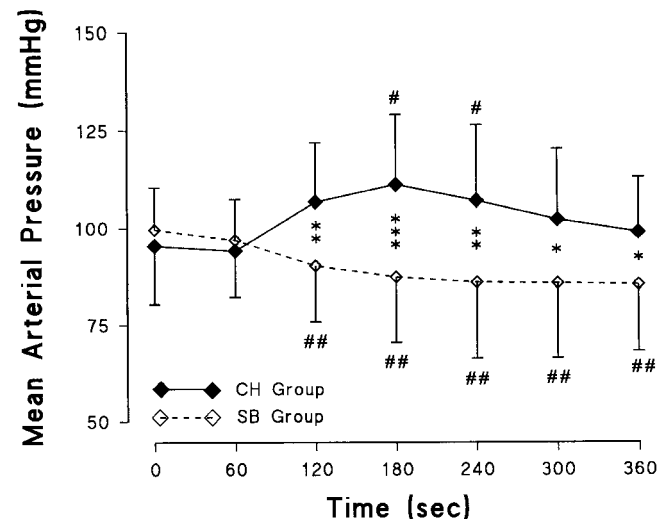


Fig. 5. Mean arterial pressure (mmHg) during the trial in patients with controlled hyperventilation (CH, closed diamond) and spontaneous breathing (SB, open diamond). Data are expressed as the mean \pm SD. # and ## = differences from the corresponding reference value, at $P < 0.05$ and 0.01 , respectively. * $P < 0.05$. ** $P < 0.01$. *** $P < 0.001$.

may provoke epileptiform EEG, but it cannot totally explain our current findings.

The monophasic sharp waves seen here resemble the K complex seen in EEG during physiologic sleep, as described by Amzica and Steriade.¹⁸ They showed that the K complex is a rhythmic waveform resulting from oscillations of excitation and inhibition, which has a frequency of 0.5–0.7 Hz. Maximal cellular activity coincided with the sharp positive peaks of this waveform. Interestingly, epileptiform spikes in our patients coincided with peaks in this monophasic waveform (fig. 3). Conversely, in some patients, this monophasic wave resembled the triphasic waveform also seen occasionally in epileptic conditions.¹¹ Oscillation activity similar to K complexes has also been described during anesthesia.¹⁹ Therefore, the K complexes and spikes shown in our study may share a common mechanism at the cellular level, and the decreased inhibition may produce the epileptiform spikes during anesthesia, particularly when cellular activity is maximal during positive sharp waves. Recent studies have shown that isoflurane, enflurane, or sevoflurane each causes an increase in cortical somatosensory evoked potentials.^{20,21} This can be explained by the stronger suppressive effect of these anesthetics on γ -aminobutyric acid adrenergic inhibitory activity than on thalamocortical excitatory activity, and this further supports the view of inhibitory–excitatory imbalance in our patients.

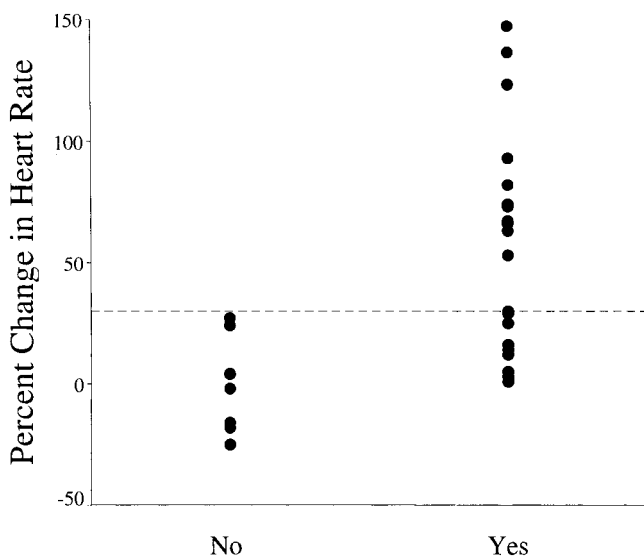


Fig. 6. Change (percentages from baseline to 4 min) in heart rate in patients without (No) and with (Yes) epileptiform electroencephalographic activity. Dotted line indicates a more than 30% change level used in the Fisher exact test. $P < 0.01$ between the groups.

Table 4. Arterial Blood-Gas Analysis 6 min after Beginning of Sevoflurane Inhalation

	Spontaneous Breathing	Controlled Hyperventilation	Result
pH	7.32 \pm 0.02	7.46 \pm 0.05	$P = 0.0001$
P _{O₂} (mmHg)	152 \pm 38	200 \pm 56	$P = 0.013$
P _{CO₂} (mmHg)	52.1 \pm 3.7	31.5 \pm 5.2	$P = 0.0001$
BE (mm)	-0.27 \pm 1.26	-0.63 \pm 1.16	$P = 0.442$

Data are mean \pm SD.

An increase in heart rate was not accompanied by any significant increase in blood pressure in patients showing an epileptiform EEG. This is partly explained by the decreasing effect of sevoflurane on total peripheral resistance.²² Because no effect of hyperventilation on hemodynamics was seen in our previous study,⁴ it is unlikely that the ventilation mode itself had any major effect on hemodynamics.

In conclusion, we have shown an association between heart rate and epileptiform EEG during anesthetic induction with the sevoflurane–nitrous oxide–oxygen mask in healthy adults. Epileptiform EEG phenomena were registered in patients undergoing controlled hyperventilation and also during spontaneous breathing of sevoflurane. The increase in heart rate of more than 30% during sevoflurane mask induction indicated epileptiform EEG activity.

References

1. Thwaites A, Edmonds S, Smith I: Inhalation induction with sevoflurane: A double-blind comparison with propofol. *Br J Anaesth* 1997; 78:356–61
2. Yli-Hankala A, Randell T, Seppälä T, Lindgren L: Increases in hemodynamic variables and catecholamine levels after rapid increase in isoflurane concentration. *ANESTHESIOLOGY* 1993; 78:266–71
3. Weiskopf RB, Moore MA, Eger EI II, Noorani M, McKay L, Chortkoff B, Hart PS, Damask M: Rapid increase in desflurane concentration is associated with greater transient cardiovascular stimulation than with rapid increase in isoflurane concentration in humans. *ANESTHESIOLOGY* 1994; 80:1035–45
4. Vakkuri AP, Lindgren L, Korttila KT, Yli-Hankala AM: Transient hyperdynamic response associated with controlled hypocapnic hyperventilation during sevoflurane–nitrous oxide mask induction in adults. *Anesth Analg* 1999; 88:1384–8
5. Komatsu H, Taie S, Endo S, Fukuda K, Ueki M, Nogaya J, Ogli K: Electrical seizures during sevoflurane anesthesia in two pediatric patients with epilepsy. *ANESTHESIOLOGY* 1994; 81:1535–7
6. Woodforth IJ, Hicks RG, Crawford MR, Stephen JPH, Burke DJ: Electroencephalographic evidence of seizure activity under deep sevoflurane anesthesia in a nonepileptic patient. *ANESTHESIOLOGY* 1997; 87:1579–82
7. Yli-Hankala A, Jäntti V: EEG burst-suppression pattern correlates

SEVOFLURANE AND EEG

with the instantaneous heart rate under isoflurane anaesthesia. *Acta Anaesthesiol Scand* 1990; 34:665-8

8. Jäntti V, Yli-Hankala A: Correlation of instantaneous heart rate and EEG suppression during enflurane anaesthesia: Synchronous inhibition of heart rate and cortical electrical activity? *Electroencephalogr Clin Neurophysiol* 1990; 76:476-9

9. Jasper H: Report of committee on methods of clinical exam in EEG. *Electroencephalogr Clin Neurophysiol* 1958; 10:370-5

10. American EEG Society: Guideline thirteen: Guidelines for standard electrode position nomenclature. *J Clin Neurophysiol* 1994; 11: 111-3

11. Blume WT, Kaibara M: *Atlas of Adult Electroencephalography*. New York, Raven Press, 1995

12. Ajmone-Marsan C: Chronic intracranial recording and electrocorticography, *Current Practice of Clinical Electroencephalography*, 2nd edition. Edited by Daly DD, Pedley TA. New York, Raven Press, 1990, pp 535-60

13. Jäntti V, Eriksson K, Hartikainen K, Baer GA: Epileptic EEG discharges during burst suppression. *Neuropediatrics* 1994; 24:271-3

14. Adachi M, Ikemoto Y, Kubo K, Takuma C: Seizure-like movements during induction of anaesthesia with sevoflurane. *Br J Anaesth* 1992; 68:214-5

15. Rosén I, Söderberg M: Electroencephalographic activity in chil-

dren under enflurane anaesthesia. *Acta Anaesthesiol Scand* 1975; 19: 361-9

16. Mäkelä JP, Iivanainen M, Pieninkeroinen IP, Waltimo O, Lahdensuu M: Seizures associated with propofol anaesthesia. *Epilepsia* 1993; 34:832-5

17. Madden JA: The effect of carbon dioxide on cerebral arteries. *Pharmacol Ther* 1993; 59:229-50

18. Amzica F, Steriade M: The K-complex: Its slow (<1-Hz) rhythmicity and relation to delta waves. *Neurology* 1997; 49:952-9

19. Daube JR, Harper M, Litchy WJ, Sharbrough FW: Intraoperative monitoring, *Current Practice of Clinical Electroencephalography*, 2nd edition. Edited by Daly DD, Pedley TA. New York, Raven Press, 1990, pp 739-79

20. Vandesteene A, Nogueira MC, Mavroudakakis N, Defevfumont M, Brunko E, Zegers de Beyl D: Synaptic effects of halogenated anesthetics on short-latency SEP. *Neurology* 1991; 41:913-8

21. Jäntti V, Sonkajärvi E, Mustola S, Rytty S, Kiiski P, Suominen K: Single-sweep cortical somatosensory evoked potentials: N20 and evoked bursts in sevoflurane anaesthesia. *Electroencephalogr Clin Neurophysiol* 1998; 108:320-4

22. Eger EI II: New inhaled anesthetics. *ANESTHESIOLOGY* 1994; 80: 906-22