

## CORRESPONDENCE

Anesthesiology  
1999; 91:1176  
© 1999 American Society of Anesthesiologists, Inc.  
Lippincott Williams & Wilkins, Inc.

### Questions Use of Nasal Cannula for Oxygen Supplementation during Cataract Surgery

*To the Editor:*—Williams and Tomlin<sup>1</sup> evaluated a device combining a Bitegard (Gensia Automedics, Inc., San Diego, CA) and a bilateral nasal cannula in patients undergoing cataract surgery.

Although bilateral nasal cannula oxygen supplementation is commonly used during cataract surgery, there is little need for this technique. During eye surgery, drapes are sealed around the eye and cover the patient. The drapes are impenetrable and confine gases completely. If oxygen is insufflated at 2–4 l/min at any point under the tented drapes, the concentration will increase to 30–50% throughout the confined atmosphere. Nasal cannulae will only create facial irritation and additional expense.

Cataract surgery with regional or topical anesthesia should be pain free. Modest sedation is appropriate. The problem is not hypoxia, but build-up of exhaled carbon dioxide under the drapes and rebreathing thereof. Ventilation is needed to dilute the carbon

dioxide, and this can be provided by insufflation of oxygen or compressed air, or by applying suction at any point under the tented drapes.

**Martin Livingston, M.D.**  
Honorary Attending Anesthesiologist  
New York Eye and Ear Infirmary  
New York, New York

#### Reference

1. Williams AR, Tomlin K: The modified Bitegard: a method for administering supplemental oxygen and measuring carbon dioxide (letter). *ANESTHESIOLOGY* 1999; 90:338–9

(Accepted for publication June 1, 1999.)

Anesthesiology  
1999; 91:1176  
© 1999 American Society of Anesthesiologists, Inc.  
Lippincott Williams & Wilkins, Inc.

*In Reply:*—We appreciate and thank Dr. Livingston for his comments regarding the use of the Bitegard as a method for administering supplemental oxygen during cataract surgery necessitating monitored anesthesia care. In our study, the modified Bitegard and nasal cannulae were used to supplement oxygen to patients undergoing cataract surgery and to monitor end-tidal carbon dioxide ( $ET_{CO_2}$ ). You are correct that the build-up of exhaled carbon dioxide under the impenetrable surgical drapes can occur. This is rarely problematic in cataract surgery because of the short duration of the surgical case. However, use of the modified Bitegard provides the anesthesiologist another alternative to the nasal cannula for the

monitoring of  $ET_{CO_2}$  and respiratory rate in patients undergoing monitored anesthesia care.

**Andrea R. Williams, M.D.**  
**Keith Tomlin, M.D.**  
Department of Anesthesia and Perioperative Medicine  
Medical University of South Carolina  
Charleston, South Carolina

(Accepted for publication June 1, 1999.)

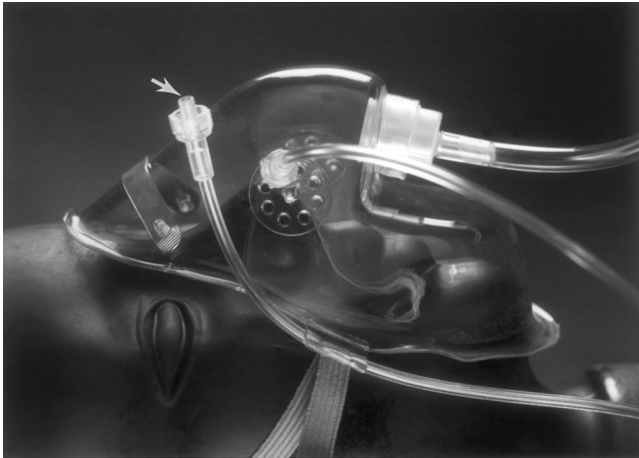Anesthesiology  
1999; 91:1176–7  
© 1999 American Society of Anesthesiologists, Inc.  
Lippincott Williams & Wilkins, Inc.

### Cost-efficient End-tidal Carbon Dioxide Monitoring via Hudson-style Mask

*To the Editor:*—End-tidal carbon dioxide ( $ET_{CO_2}$ ) monitoring during spontaneous respiration is desirable.<sup>1</sup> I had been previously using intravenous cannulae to attach carbon dioxide monitoring tubing to

Hudson-style masks during cases involving intravenous sedation. The cannula cost \$.53 and required scissors to cut off the excessive lengths, which protruded into the masks and “tickled” noses. Re-

## CORRESPONDENCE



**Fig. 1.** The gas analysis line is shown in place on the Hudson mask on the mannequin. The 4-mm "male" protrusion is also shown (arrow) on separate tubing.

cently, the Intertech Gas sampling lines (order No. 225-3421-800; Smith Industries Medical Systems, Fort Meyers, FL) have become standard in our operating rooms (fig. 1). These lines have Luer-lock hubs with an internal 4-mm long and 4-mm diameter "male" protrusion. The hub can be twisted into and quickly secured within a vent hole of standard Hudson-style (Hudson Respiratory Care, Temecula, CA) oxygen masks when counterpressure is applied from inside the mask. In this way, the additional costs are eliminated to

secure carbon dioxide monitoring devices onto standard masks as is the need to carry scissors to trim intravenous catheters. I recommend this method, which allows inexpensive and hygienic  $ET_{CO_2}$  sampling, directly at the site of expired gas egress. Because the Hudson mask collects expired gases from both the mouth and the nose, this type of monitoring device is very effective in detecting carbon dioxide, irrespective of whether "mouth" or "nose" breathers are encountered. I also recommend looping the carbon dioxide sampling line under the Hudson mask strap to prevent inadvertent dislodgement of the line from the Hudson mask *via* incidental traction on the sampling line. This facilitates secure intraoperative placement and rapid removal at the end of the case.

**Paul Kempen, M.D., Ph.D.**

Associate Professor  
Department of Anesthesiology  
University of Pittsburgh School of Medicine  
Montefiore University Hospital  
Pittsburgh, Pennsylvania 15213  
Pkempe@POL.NET

## Reference

1. Lake CL: Monitoring: History and philosophy, *Clinical Monitoring for Anesthesia and Critical Care*, 2nd edition. Edited by Lake C. Philadelphia, WB Saunders, 1994 pp 2-10

(Accepted for publication April 21, 1999.)

Anesthesiology  
1999; 91:1177-8  
© 1999 American Society of Anesthesiologists, Inc.  
Lippincott Williams & Wilkins, Inc.

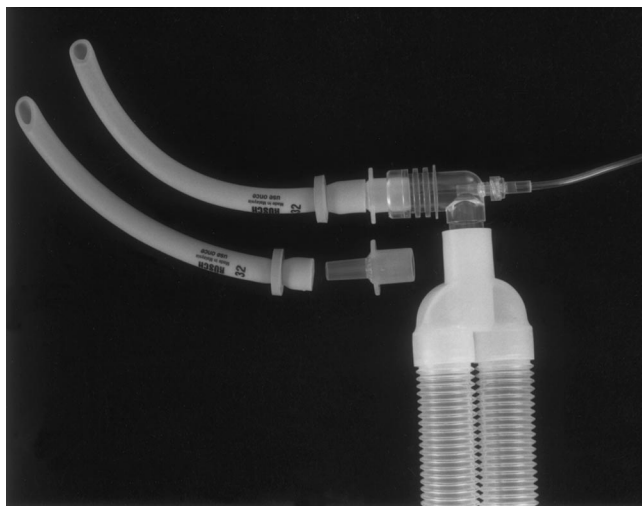
## Carbon Dioxide Monitoring during Deep Conscious Sedation Using Nasopharyngeal Airways

*To the Editor:*—Ever since Goldman<sup>1</sup> described a method for monitoring end-tidal carbon dioxide ( $ET_{CO_2}$ ) using modified nasal cannulae in sedated patients, there have been a number of articles that report variations to the original method (e.g., Shah and Epstein<sup>2</sup> and Kempen<sup>3</sup>). Patients under deep sedation, however, have varying degrees of upper airway obstruction.

The following method permits carbon dioxide monitoring while it relieves upper airway obstruction in deeply sedated, spontaneously breathing patients. An appropriately sized, soft, rubber nasopharyngeal airway (Rusch, Duluth, GA) is coupled to a

15-mm endotracheal tube connector (Kendall Co., Mansfield, MA). After preparation of the nasal passages and insertion, this modified nasopharyngeal airway is connected to an anesthesia breathing circuit with a gas sampling line (Sims Portex Inc., Fort Myers, FL; fig. 1). Similar to the carbon dioxide-sampling nasal cannulae, this system permits respiratory rate and monitoring of  $ET_{CO_2}$  trends.

I have used this modified nasopharyngeal airway system on several occasions and have found it to be an improvement over the nasal cannulae carbon dioxide sampling techniques used in sedated patients



**Fig. 1. (Top)** Nasopharyngeal airway connected to an anesthesia breathing circuit with a gas sampling line. **(Bottom)** Soft rubber airway and 15-mm endotracheal tube connector.

Anesthesiology  
1999; 91:1178-9  
© 1999 American Society of Anesthesiologists, Inc.  
Lippincott Williams & Wilkins, Inc.

with signs of upper airway obstruction. Moreover, the system is configured easily from equipment that is readily available in most anesthetic locations.

**Eric Dominguez, M.D., L.C.D.R., M.C., U.S.N.R.**  
Department of Anesthesiology  
Naval Medical Center  
Portsmouth, Virginia 23708

## References

1. Goldman JM: A simple, easy, and inexpensive method for monitoring  $ET_{CO_2}$  through nasal cannulae (letter). *ANESTHESIOLOGY* 1987; 67:606
2. Shah MG, Epstein L: Measurement of carbon dioxide at both nares and mouth using standard nasal cannula. *ANESTHESIOLOGY* 1994; 81: 779-80
3. Kempem P: Cost effective carbon dioxide monitoring via nasal cannula. *ANESTHESIOLOGY* 1999; 90:633-4

(Accepted for publication May 3, 1999.)

## Inflation of the Endotracheal Tube Cuff in the Pharynx for Ventilation of Paralyzed Patients with Unanticipated Difficult Airway

**To the Editor:**—Airway management is essential to anesthesia practice. Despite several predictors of difficult intubation, patients with unexpectedly difficult airways are sometimes encountered, and an unforeseen grade III-IV laryngoscopy in a paralyzed patient is still a potentially dangerous situation. Several techniques and devices can be used in the face of an unplanned difficult intubation,<sup>1</sup> such as the laryngeal mask airway, the Combitube, COPA, and light wand. However, there are situations in which these techniques and devices may not be available.

There is a simple technique that will allow ventilation of the paralyzed patient for several minutes until help or alternative methods arrive. The technique involves the placement of an endotracheal tube into the pharynx, with its tip just below the epiglottis, followed by inflation of the cuff with a large volume of air. Ventilation is then performed *via* the endotracheal tube.

To confirm the usefulness of this method, we conducted a clinical study in 50 patients with American Society of Anesthesiologists physical status I-II (27 men) undergoing general anesthesia. The hospital ethical committee approved the study, and informed consent was obtained from the participants. Exclusion criteria were age < 18 yr or > 70 yr, last oral intake less than 8 h, and hiatal hernia or gastroesophageal reflux. The patients all had normal airways on examination (Mallampati class I-II, normal neck extension, hyomental distance of >

6 cm). After induction of anesthesia and neuromuscular blockade, a laryngoscope was inserted until only the tip of the epiglottis was observed. An endotracheal tube with a 7.5-8 mm internal diameter (Mallinckrodt) with Murphy eye was introduced, placing the tip under the epiglottis with the cuff of the tube remaining in full view. In this position, the cuff was inflated with 50-60 ml of air by an assistant. We connected the tube to the circuit, and the patients were manually ventilated at a rate of approximately 25 breaths per minute. We checked appropriate ventilation by noting the movement of the chest and the presence of expired  $CO_2$ , and by auscultation of the lungs and epigastrium. The hyperinflated cuff produces an oropharyngeal seal. After 3 min of ventilation, the cuff was deflated, the tube was removed, and a new endotracheal tube was placed through the cords for subsequent ventilation. We were able to ventilate all patients without difficulty, although the endotracheal tube occasionally needed to be withdrawn slightly to correct an air leak. Oxygen saturation as measured by pulse oximetry ( $Sp_{O_2}$ ) was maintained at > 95% in all patients. No patients complained of sore throat in the postoperative period.

During the study period, two additional patients who were not involved in the study were discovered to have an unexpectedly difficult laryngoscopy after anesthetic induction. We used the described method successfully in both cases. We also passed a flexible fiberoptic laryngoscope through the tubes. After partially deflating the cuff, we

## CORRESPONDENCE

saw the glottic opening, and the fiberoptic laryngoscope was introduced easily.

Endotracheal-tube cuff inflation in the oropharynx has been described previously as an aid to blind nasotracheal intubation with spontaneous ventilation, both in normal patients<sup>2-3</sup> and in those with altered anatomy.<sup>4</sup> The currently described technique could be used in the setting of the unanticipated difficult airway, when other means of establishing a patent airway are not available.

**Alfredo Panadero, M.D., Ph.D.**

**Pablo Monedero, M.D., Ph.D.**

pmonedero@unav.es

**Isidro Olavide, M.D., Ph.D.**

**Ignacio Fernández-Liesa, M.D., Ph.D.**

**Jose Manuel Mendieta, M.D., Ph.D.**

**Antonio Macías, M.D.**

Department of Anesthesia and Critical Care

Clínica Universitaria de Navarra

School of Medicine

University of Navarra

Pamplona, Spain

Anesthesiology

1999; 91:1179-80

© 1999 American Society of Anesthesiologists, Inc.

Lippincott Williams & Wilkins, Inc.

## References

1. Practice guidelines for management of the difficult airway. A report by the American Society of Anesthesiologists Task Force on Management of the Difficult Airway. *ANESTHESIOLOGY* 1993; 78:597-602
2. Van Elstraete AC, Mamie JC, Mehdaoui H: Nasotracheal intubation in patients with immobilized cervical spine: A comparison of tracheal tube cuff inflation and fiberoptic bronchoscopy. *Anesth Analg* 1998; 87:400-2
3. Gorback MS: Inflation of the endotracheal tube cuff as an aid to blind nasal endotracheal intubation. *Anesth Analg* 1987; 66: 916-7
4. Casals-Caus P, Mayoral-Rojals V, Canales MA, Ruiz-Tamarit V, Casals-Castells A, Cochs-Cristia J: Inflation of the endotracheal tube cuff as an aid for blind nasotracheal intubation in patients with predicted difficult laryngoscopy. *Rev Esp Anestesiol Reanim* 1997; 44:302-4

(Accepted for publication June 1, 1999.)

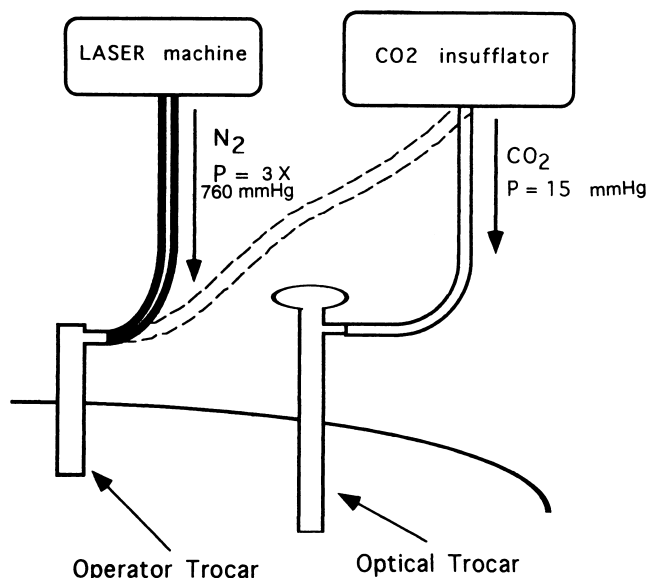
## Life-threatening Bilateral Pneumothorax Caused by Misconnection of the Laser Lens Cooling System during Gynecologic Laparoscopy

**To the Editor:**—Laparoscopy is commonly used for diagnosis and therapeutic purposes during gynecologic surgery. We recently encountered a case of a life-threatening bilateral pneumothorax that occurred during an anesthetic procedure for the laser treatment of endometriosis. This major adverse event was caused by a misconnection of the laser lens cooling system (Sharplan 1040). Rapid diagnosis and treatment led to an uneventful postoperative course.

A 27-yr-old woman with American Society of Anesthesiologists physical status 1 was scheduled for laparoscopy for exploration of infertility. Shortly after induction of anesthesia, intraperitoneal CO<sub>2</sub> insufflation was initiated through an optical trocar. Peritoneal endometriosis was diagnosed, laser treatment was decided upon, and an operator trocar was inserted. When the laser started to fire, a sudden decrease in systolic blood pressure (60 mmHg) associated with bradycardia was observed. At that time, intraperitoneal pressure was noted to be 55 mmHg. The patient rapidly developed subcutaneous emphysema, and pneumothorax was suspected. Surgery was resumed immediately, the peritoneal cavity was exsufflated, and bilateral tension pneumothorax was diagnosed on chest radiograph. Bilateral chest tubes were quickly inserted, and rapid restoration of respiratory and hemodynamic stability was obtained. The patient's course was uneventful, and she was discharged from the hospital. Chest tomodensitometry did not show the presence of emphysema blebs.

The peritoneal and pleural cavities develop from a common sac that is separated by the diaphragm, and residual communications such as congenital diaphragmatic defects may persist after birth.<sup>1,2</sup> Passage of CO<sub>2</sub> *via* the esophageal aortic or Bochdalek gap has been implicated in the development of bilateral pneumothorax occurring during gynecologic laparoscopy.<sup>3,4</sup> However, in such circumstances, pneumothorax usually quickly resolves because of the high CO<sub>2</sub> solubility. In the present case, passage of N<sub>2</sub> from the peritoneum to the pleura because of intraperitoneal insufflation of N<sub>2</sub> under high pressure was the more-likely mechanism of the pneumothorax.

The laser machine had a line delivering N<sub>2</sub> at 3 × 760 mmHg for cooling of the optical lens. In this device, N<sub>2</sub> flows to cool the lens only when the laser fires, and the N<sub>2</sub> line must be used only during external treatment (during internal use, the lens is cooled by CO<sub>2</sub>). Normally, the CO<sub>2</sub> line, not the N<sub>2</sub> line, is connected to the operator trocar, and the apparatus delivering the CO<sub>2</sub> limits the pressure to safe levels. In the present case, the N<sub>2</sub> line, instead of the CO<sub>2</sub> line, was inadvertently connected to the trocar (fig. 1). Consequently, when the laser started to fire, N<sub>2</sub> was insufflated into the peritoneal cavity under extremely high pressure (instead of the appropriate insufflation pressure of 15 mmHg), resulting in 55-mmHg tension pneumoperitoneum followed immediately by bilateral tension



**Fig. 1.** Schematic representation of the laser machine showing the misconnection between the line delivering  $N_2$  and the operator trocar. The adequate connection that should have been used is represented by the dotted line. When the laser fired,  $N_2$  was insufflated into the peritoneal cavity at a pressure of  $3 \times 760$  mmHg.

pneumothorax, hypotension, and bradycardia. It can also be speculated that the inadvertent use of  $N_2$  to cool the laser resulted in longer-lasting pneumothorax than that which would be expected with  $CO_2$ .

It is important to respect the procedures for the use of laparoscopic devices to prevent the occurrence of such life-threatening events caused by technical errors.

**Gildas Gueret, M.D.**

Staff Anesthesiologist

**Frédérique Guischard, M.D.**

Staff Anesthesiologist

**Jean-Louis Dumoulin, M.D.**

Staff Anesthesiologist

**Jean-François Oury, M.D.**

Professor of Gynecology and Obstetrics

Hospital Robert Debré

Paris, France

**Jean Mantz, M.D., Ph.D.**

Professor of Anesthesiology and Critical Care

jean.mantz@bch.ap-hop-paris.fr

**Jean-Marie Desmonts, M.D.**

Professor of Anesthesiology and Critical Care

Hospital Bichat

Paris, France

## References

1. Batra MS, Driscoll JJ, Coburn WA, Marks WM: Evanescent nitrous oxide pneumothorax after laparoscopy. *Anesth Analg* 1983; 62:1121-3
2. Childers JM, Caplinger P: Spontaneous pneumothorax during operative laparoscopy secondary to congenital diaphragmatic defects. *J Reprod Med* 1995; 40:151-3
3. Gabott DA, Dunkley AB, Roberts FL: Carbon dioxide pneumothorax occurring during laparoscopic cholecystectomy. *Anaesthesia* 1992; 47:587-8
4. Doctor NH, Hussain Z: Bilateral pneumothorax associated with laparoscopy: A case report of a rare hazard and review of literature. *Anaesthesia* 1973; 28:75-81

(Accepted for publication June 8, 1999.)