

## Clinical Assessment of a Plastic Optical Fiber Stylet for Human Tracheal Intubation

Dietrich Gravenstein, M.D.,\* Richard J. Melker, M.D., Ph.D.,† Samsun Lampotang, Ph.D.‡

**Background:** The authors compared the performance of a prototype intubation aid that incorporated plastic illumination and image guides into a stylet with fiberoptic bronchoscopy and direct laryngoscopy for tracheal intubation by novice users.

**Methods:** In a randomized, nonblinded design, patients were assigned to direct laryngoscopy, fiberoptic bronchoscopy, or imaging stylet intubation groups. The quality of laryngeal view and ease with which it was attained for each intubation was graded by the laryngoscopist. Time to intubation was measured in 1-min increments. A sore-throat severity grade was obtained after operation.

**Results:** There were no differences in demographic, physical examination, or surgical course characteristics among the groups. The laryngoscope produced an adequate laryngeal view more easily than did the imaging stylet or bronchoscope ( $P = 0.001$ ) but caused the highest incidence of postoperative sore throat ( $P < 0.05$ ). Although the time to intubation for direct laryngoscopy was shorter than for imaging stylet, which was shorter than fiberoptic bronchoscopy ( $P < 0.05$ ), the quality of laryngeal view with the imaging stylet was inferior to both

direct laryngoscopy and fiberoptic bronchoscopy techniques ( $P < 0.05$ ).

**Conclusions:** Novices using the imaging stylet produce fewer cases of sore throat (compared with direct laryngoscopy) and can intubate faster than when using a bronchoscope in anesthetized adult patients. The imaging stylet may be a useful aid for tracheal intubation, especially for those unable to maintain skills with a bronchoscope. (Key words: Bronchoscope; fiberoptic laryngoscope; novice.)

THE newest devices for airway management incorporate flexible imaging optics into the stylet and thereby rework concepts first introduced 20 yr ago.<sup>1</sup> The resurgence of interest in the clinical potential of an optical stylet stems from advances in technology and from the continued and presumably preventable complications associated with airway management.<sup>2</sup> The Aeroview (Imagyn Medical Technologies, Newport Beach, CA), Flexguide (Scientific Sales International, Kalamazoo, MI), Fiberview (Anesthesia Medical Specialties, Sante Fe Springs, CA), Nanoscope (Nanoptics, Gainesville, FL), and Video-Optical Intubation Stylet<sup>3</sup> (Volpi AG, Schlieren, Switzerland), have a flexible fiberoptic image guide in the stylet and generate a view from the center of the distal end of the endotracheal tube (ETT).

We report the findings of a clinical study that compared the performance of a prototype optical stylet with that of a fiberoptic bronchoscope (FOB) and direct suspension laryngoscope for tracheal intubation of anesthetized adult patients when used by novices. The prototype system, a so-called imaging stylet (Nanoptics), is comprised of two plastic optical fiber bundles.<sup>4</sup> One bundle (Optiplast; Nanoptics) serves as an image guide and has approximately a 3,000-pixel resolution, whereas the second carries light to illuminate the field of view. Both bundles are imbedded into a 37-cm-long malleable intubating stylet with an outer diameter of 6 mm. The fibers extend from the distal stylet tip to 60 cm beyond the proximal stylet end, where they quick-connect to a camera and light source. The image is displayed on a 5-inch color television monitor that is situated near the patient's head (fig. 1).

\* Assistant Professor, Department of Anesthesiology, University of Florida College of Medicine, University of Florida Brain Institute.

† Professor, Department of Anesthesiology and Pediatrics, University of Florida, College of Medicine, University of Florida Brain Institute.

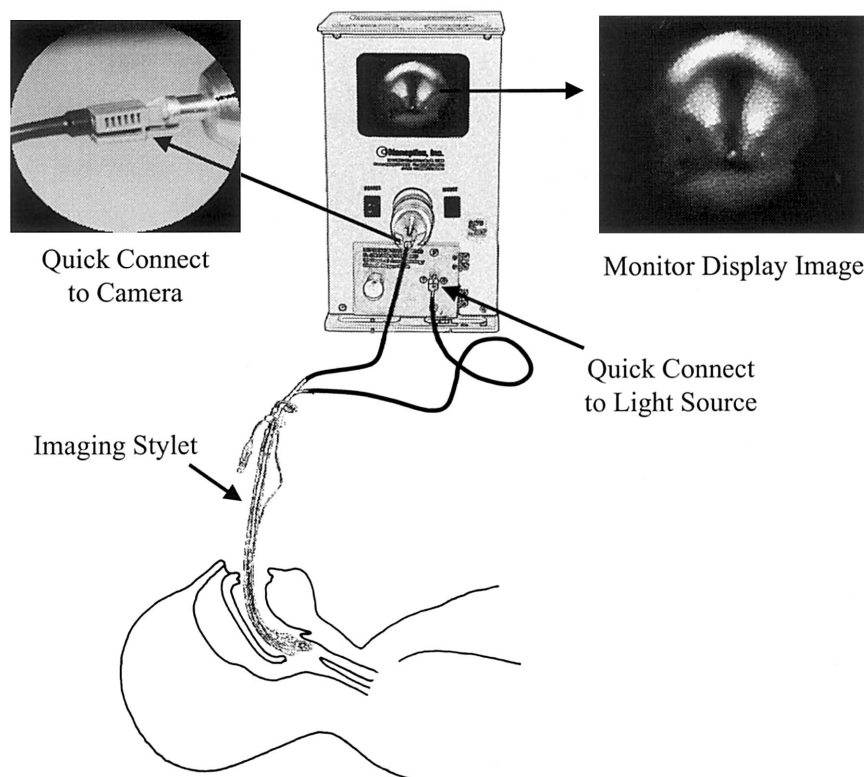
‡ Assistant Professor, Department of Anesthesiology, University of Florida, College of Medicine; and Affiliate Assistant Professor, Departments of Mechanical Engineering and Electrical and Computer Engineering, College of Engineering, University of Florida, Gainesville, and University of Florida Brain Institute.

Received from the Department of Anesthesiology, University of Florida, Gainesville, Florida. Submitted for publication November 18, 1998. Accepted for publication April 13, 1999. Support was provided solely from institutional and/or departmental sources. Nanoptics provided the imaging stylets and a monitor. Presented in part at the annual meeting of the American Society of Anesthesiologists, San Diego, California, October 18–22, 1997; the 51st PGA Annual Meeting of the New York State Society of Anesthesiologists, New York, New York, December 13–15, 1997; the annual meeting of the Society for Technology in Anesthesia, Tucson, Arizona, January 15–17, 1998; the 72nd International Anesthesia Research Society, Orlando, Florida, March 7–11, 1998; and the annual meeting of the American Society of Anesthesiologists, Orlando, Florida, October 18–22, 1998.

Address reprint requests to Dr. Gravenstein: Department of Anesthesiology, P.O. Box 100254, Gainesville, Florida 32610-0254. Address electronic mail to: didi@anest4.anest.ufl.edu

## CLINICAL ASSESSMENT OF A PLASTIC OPTICAL FIBER STYLET

**Fig. 1.** Stylized depiction of the imaging stylet within an endotracheal tube that is being positioned for tracheal insertion. The plastic optical fibers of the imaging stylet are quick-connected to a camera and light source housed together with a 5-inch color television monitor that is positioned near the patient's head and displays an image of the vocal cords.



Incorporating imaging optics into a stylet has intuitive appeal because the stylet-fitted ETT and its positioning into the trachea are familiar to all who manage airways. The bronchoscope is held with two hands and requires adjustments of the tip angulation lever to bring the desired structures into view. It takes 18 bronchoscope intubations to become efficient with this device and approximately 45 to achieve expert skill status.<sup>5</sup> The manipulations necessary to view the larynx through the imaging stylet (IS) are direct and accomplished without intervening controls. Thus, we hypothesized that novices would find the IS easier to use and would accomplish tracheal intubation more rapidly than when using the FOB.

## Materials and Methods

After we received approval by the institutional review board and informed patient consent, 81 adult patients scheduled for operations under general anesthesia were assigned to one of three groups to undergo tracheal intubation under general anesthesia either with the help of direct laryngoscopy (DL), an FOB, or an IS. As part of the preoperative anesthesia evaluation, all study partici-

pants underwent an airway examination in the sitting position. Mouth opening and mentum-to-hyoid distance were measured in fingerbreadths. Exclusion criteria included a history of frank reflux, known difficult tracheal intubation, American Society of Anesthesiologists physical status  $>3$ , and a Mallampati airway class score<sup>6</sup> of 4, as modified by Samsoon and Young.<sup>7</sup> Randomization was changed after study of the ninth patient was completed, when it became evident that some patients were being confused during the consent procedure by the discussion of three possible methods of intubation. Thus, subsequent patients were randomly assigned to one group before any chart review or examination. The patient was then interviewed, informed of the randomization, and asked to give consent on the assigned technique. Neither the investigators nor the laryngoscopists were blinded to the intubation method used.

The anesthesiology resident, certified registered nurse anesthetist (in his first postgraduate year of employment), or attending anesthesiologist assigned to provide anesthesia for the selected case was the "novice" approached to perform the tracheal intubation by the selected method. With the exception of one attending anesthesiologist with extensive experience, all FOB in-

tubations were performed by an anesthesia resident or certified registered nurse anesthetist with experience of fewer than 12 bronchoscope intubations. All IS intubations were performed by residents or attendings with fewer than five IS intubations as their experience. Only residents or certified registered nurse anesthetists intubated patients in the DL group, none with more than 3 yr of clinical experience performing intubations. Every patient was premedicated with 0.3 mg glycopyrrolate and had general anesthesia induced with a hypnotic, narcotic, and muscle relaxant.

Before induction of anesthesia, the IS was treated with an antifog agent, lubricated, and then inserted into the ETT so that the distal end of the IS was at the bevel of the ETT, just distal to the Murphy eye. The ETT-IS assembly was connected to its light source and camera, then sharply bent to 90° just proximal to the cuff to provide the desired "hockey stick" configuration. Bending the IS was sufficient to fix the position of the IS tip relative to the ETT tip. In all but two IS cases, the patient was positioned with the head in a neutral position (*i.e.*, not in a sniffing position and without neck extension).

Maneuvering the IS in an anesthetized patient can be aided with the concurrent use of a laryngoscope to elevate the tongue. Only one resident and one attending chose to use a laryngoscope, while still guiding the intubation from the image of the larynx displayed on the monitor, during their first use of the IS. In the remaining IS cases, the nondominant hand was used to grasp the mandible and elevate the jaw and tongue while the IS-ETT assembly in the other hand was placed slowly along the midline into the pharynx until the epiglottis and vocal cords were visualized. The IS was then steered between the cords; when tracheal rings became visible, the ETT was advanced into position, whereupon auscultation and capnography confirmed correct placement.

Laryngoscopy in the DL group was performed with either a Macintosh (size 3 or 4) or Miller (size 2 or 3) blade.

The patients in the FOB group had tracheal intubation with a 4-mm outer diameter Olympus LF-2 (Olympus, Lake Success, NY) FOB that had been treated with lubricant and an antifog agent. A Williams Airway Intubator (Anesthesia Associates, San Marcos, CA) was used during intubation in all but two cases (in which a jaw thrust was chosen instead) and then immediately removed.

The laryngoscopist graded the quality of laryngeal view (on a scale of 0 to 10, with 10 being ideal) and ease of use (on a scale of 0 to 10, with 10 being the easiest) for each method of intubation using an 11-point verbal rat-

ing score. Time to intubation was measured in 1-min increments and was defined as the elapsed time from the moment the airway device was introduced into the mouth to confirmation of successful intubation, rounded to the next minute. A failure to intubate was recorded when the intubation by that method was abandoned and the airway was secured by an alternative method. The ETT size was recorded and an esophageal temperature probe and gauze bite-block were inserted for all patients.

An 11-point verbal rating score for severity of sore throat (0 to 10, with 10 being the most severe) was obtained from patients within the first postoperative day. A 0 grade represented a normal and not sore throat, whereas a grade of 10 represented throat soreness that prohibited swallowing. The duration of surgery, use of nitrous oxide, and whether a gastric tube was placed orally or nasally was established through a retrospective review of charts. Endotracheal tube sizes were normalized to the height of each patient. All ISs were cleaned with soap after use and sterilized with ethylene oxide before they were used again.

### Statistical Analysis

The groups were compared for significant differences using a one-way analysis of variance (for age, height, weight, normalized ETT size) or Kruskal-Wallis one-way analysis of variance on ranks test (American Society of Anesthesiologists physical status, airway examination, image quality, ease-of-use, sore throat verbal rating score, and time to intubation; SigmaStat, SPSS Inc., Chicago, IL). A chi-square test (SigmaStat) was used to determine distribution differences among the groups for sex, years of clinical experience of the laryngoscopist, intraoperative use of nitrous oxide and gastric sump tubes, and failure-to-intubate rates.

## Results

Twenty-five patients were enrolled in the DL group, whereas 29 and 27 participants were enrolled in the FOB and IS groups, respectively. Of these 81 patients, we removed 5 from the analysis because of failure to intubate by the selected method. Intubation with the FOB was abandoned three times because of compromised viewing and one time because of an inability to direct the scope as desired. The prototype IS failed once when blood on the lens obscured the user's view.

In one patient on whom the IS was being used without a laryngoscope, only tissue color appeared on the mon-

## CLINICAL ASSESSMENT OF A PLASTIC OPTICAL FIBER STYLET

**Table 1. Patient Age and Physical Examination Data**

	FOB	IS	DL	P
Age (yr)	48 ± 15.2	45 ± 14.8	45 ± 14.2	NS
Height (in)	68 ± 4.1	68 ± 4.0	68 ± 3.6	NS
Weight (kg)	81 ± 25.6	85 ± 27.5	86 ± 16.8	NS
Gender (M/F)	11/14	14/11	14/11	NS
ASA PS	2 (2, 2)	2 (2, 2.25)	2 (2, 2)	NS
Class airway	2 (1, 2)	2 (1, 2)	2 (1, 2)	NS
Mouth opening				
(finger				
breadths)	3 (3, 3)	3 (3, 3)	3 (3, 3)	NS
Mentum-hyoid				
(finger				
breadths)	3 (3, 3)	3 (3, 3)	3 (3, 3)	NS

Age, height, and weight data are mean ± SD. Gender is number of patients by sex. ASA PS, class airway, mouth opening, and mentum-hyoid distance as median (25%, 75%).

FOB = fiberoptic bronchoscope; IS = imaging stylet, DL = direct laryngoscopy; ASA PS = American Society of Anesthesiologists physical status; NS = not significant ( $P \geq 0.05$ ).

itor screen. When the attending anesthesiologist performed vigorous laryngoscopy with a size 3 Miller blade, only the tip of the epiglottis was visualized. Under direct vision, the IS was then placed behind the epiglottis tip, whereupon the monitor displayed the vocal cords and the patient was quickly intubated.

Demographics and physical examination characteristics (age, height, weight, sex, mouth opening, mentum-to-hyoid distance, airway class, and American Society of Anesthesiologists physical status) of the remaining 25 patients in each group were not significantly different among the groups (table 1). The number of different faculty ( $n = 1, 3, 0$ ) and housestaff or certified registered nurse anesthetists ( $n = 18, 16, 17$ ) and the median number of years experience of the laryngoscopist ( $n = 3, 3, 2$ ) ( $P = 0.26$ ) for the FOB, IS, and DL groups, respectively, were not statistically different among the groups. Table 2 shows the distribution of clinical years of experience between the intubators in each group and the median time to intubation. Intubation by DL was significantly faster than by IS, which was significantly faster than by FOB ( $P < 0.05$ ).

Table 3 shows the ease of use, quality of laryngeal view, failure rates, and sore throat scores for each intubation method. The DL technique was the easiest to use

( $P < 0.05$ ), whereas the FOB and IS methods were not statistically different from one another. Quality of laryngeal view was best with the DL and FOB techniques, which were not significantly different from one another but were both better than with the IS ( $P < 0.05$ ). The failure rate was not statistically different among the groups ( $P = 0.089$ ). The IS produced significantly less sore throat than did DL ( $P < 0.05$ ) but not less than FOB. There were no significant differences in height-adjusted ETT size ( $P = 0.295$ ), length of surgery ( $P = 0.557$ ), use of nitrous oxide ( $P = 0.765$ ), or placement of gastric sump among the groups ( $P = 0.57$ ).

## Discussion

The residents and two nurse anesthetists in this study had experience with laryngoscopic intubations but were novices in both the FOB and IS techniques. Comparison of the time to intubation among the techniques suggests that operation of, and intubation with, the IS is simpler than with the FOB technique. Unfortunately, we set out to find gross differences between techniques and did not design the study to distinguish differences of seconds in time to intubation. Because time to intubation was measured in minute increments, reported times to intubation are longer than actual intubation times. The FOB time to intubation may seem long, with a median time of 3 min, but is consistent with the time required by novices learning fiberoptic techniques.<sup>5</sup>

The prototype IS device did not produce an image of the quality and resolution typically seen with the bronchoscope. The most relevant reason for this difference is that the bronchoscope has a 10,000-pixel image, whereas the prototype IS that we used had an image of 3,000 pixels. In addition, the brightness of an image guide contributes to its image quality. In contrast to glass image guides found in bronchoscopes, plastic image guides absorb more light, so the image brightness decreases rapidly as the length of the image guide increases. The prototype IS devices we used in this study also had many dark pixels. These were presumably caused by gas or particle impurities introduced into the plastic optic fiber during manufacturing and not as result of breakage, because repeated cleaning, ethylene oxide sterilization, and reuse of the devices produced no noticeable pixel dropout.

The inferior image quality may not be the only factor contributing to low ease-of-use scores for the IS. The quick-connector attached to the camera would some-

§ Wang Y, Brennan AB, Frost G, Tymiansky JR, Walker JR: Plastic fiberoptic image guides for endoscopes. Conference Proceedings of the Society of Plastics Engineers, Boston, Massachusetts, May 7-11, 1995, p 3367.



**Table 2. Number of Intubations Performed by Level of Clinical Experience between Groups and Time to Intubate**

	PGY 1	CA 1	CA 2	CA 3	CRNA	AT	Total	Time (min)
FOB	1 (1)	6 (6)	4 (3)	10 (6)	3 (1)	1 (1)	25 (18)	3 (2.0, 4.25)*
IS	3 (2)	3 (2)	5 (5)	8 (4)	0 (0)	7 (3)	26 (16)	2 (1.0, 3.0)*
DL	3 (2)	7 (5)	5 (4)	9 (5)	1 (1)	0 (0)	25 (17)	1 (1.0, 1.0)*

Values are given as number of intubations (number of intubators), except time [median (25%, 75%)].

FOB = fiberoptic bronchoscope; IS = imaging stylet; DL = direct laryngoscopy; PGY1 = postgraduate year 1; CA1, CA2, CA3 = clinical anesthesia years 1, 2, and 3, respectively; CRNA = certified registered nurse anesthetist in first year of postgraduate employment; AT = attending physician.

\* Significantly different ( $P < 0.05$ ) from other groups.

times slip, and the displayed image rotated during tracheal intubation. The lens on the stylet tip was slightly recessed and sometimes would trap secretions or blood, which required removal of the stylet and cleaning. In the patient in whom blood caused a failure of the IS, the blood could not be cleaned expeditiously from the recessed lens, which led us to abandon the IS technique. These negative features of the prototype IS must have been offset by other positive factors, such as simplicity of use, because novices were able to intubate more quickly when using the IS compared with the FOB.

The severity of postoperative sore throat has been attributed to the extent of pharyngeal trauma.<sup>8,9</sup> Eliminating the need for suspension laryngoscopy may substantially reduce pharyngeal trauma and thereby explain the significant reduction in the severity of postoperative sore throat observed in the IS group.

All intubators had by far the greatest experience with DL and most, but not all, had done fiberoptic intubations before. This study did not evaluate the effect of learning on performance with any of the intubation techniques. Regardless, not much opportu-

nity existed for learning, because the highest number of intubations performed by a single resident within the study protocol was five for FOB and four for IS methods. The second highest number of repetitions performed by a single resident was two and three intubations for the FOB and IS methods, respectively. Although residents and anesthetists may have continued to perform and practice intubation using laryngoscopes and bronchoscopes on other patients who were not part of the protocol during this study, the IS was used exclusively on patients participating in the study. Considering that a novice may need to do 20 intubations with a laryngoscope before reaching a 95% success rate,<sup>10</sup> it is noteworthy that the 16 persons using the IS nevertheless intubated patients successfully in 26 of 27 (96%) uses. The success rate and acceptable time-to-intubation novices had when using the IS suggests that this approach may provide an alternative aid for tracheal intubation, especially for those unable to maintain their skills with an FOB.

In conclusion, this clinical study on humans of tracheal intubation with an IS shows that the technique is associated with less morbidity than laryngoscopy and can be performed more quickly than bronchoscope intubations under general anesthesia by those not skilled in IS or bronchoscopy. How the IS will perform in awake or asleep patients with anticipated or known difficult airways, its durability, and the estimated cost per use are the subjects of on-going investigations.

The authors thank Kelly Spaulding for assistance with research and the preparation of the manuscript.

## References

1. Katz RL, Berci G: The optical stylet—A new intubation technique for adults and children with specific reference to teaching. *ANESTHESIOLOGY* 1979; 51:251–4
2. Caplan RA, Posner KL, Ward RJ, Cheney FW: Adverse respiratory

**Table 3. Comparison of Ease of Use, Quality of Laryngeal View, Success to Failure Rate, and Sore Throat Scores Between Methods**

	Ease of Use	Quality of View	Success/ Failure	Sore Throat
FOB	8 (6.75, 8.25)	10 (9.0, 10.0)	25/4	2 (0.25, 4.0)
IS	8 (6.0, 9.0)	8 (5.0, 8.0)*	26/1	1 (0.0, 2.0)†
DL	9 (9.0, 10.0)*	10 (9.5, 10.0)	25/0	3.0 (1.0, 5.0)

Ease of use, quality of view, and sore throat scores are median (25%, 75%). Success/failure rates are by count.

FOB = fiberoptic bronchoscope; IS = imaging stylet; DL = direct laryngoscopy.

\* Significantly different ( $P < 0.05$ ) from other groups.

† Significantly different ( $P < 0.05$ ) from DL.

## CLINICAL ASSESSMENT OF A PLASTIC OPTICAL FIBER STYLET

events in anesthesia: A closed claims analysis. *ANESTHESIOLOGY* 1990; 72:828-33

3. Weiss M: Management of difficult tracheal intubation with a video-optically modified Schroeder intubation stylet [letter]. *Anesth Analg* 1997; 85:1181-2

4. Gravenstein D, Lampotang S, Melker R, Doviak R: Performance of a plastic optical fiber stylet for tracheal intubation of a dog. *J Clin Monit* 1998; 14:271-4

5. Smith JE, Jackson APF, Hurdley J, Clifton PJM: Learning curves for fiberoptic nasotracheal intubation when using the endoscopic video camera. *Anaesthesia* 1997; 52:101-6

6. Mallampati SR, Gatt SP, Gugino LD, Desai SP, Waraksa B, Freiburger D, Liu PL: A clinical sign to predict difficult tra-

cheal intubation: A prospective study. *Can Anaesth Soc J* 1985; 32:429-34

7. Samsoon GLT, Young JRB: Difficult tracheal intubation: A retrospective study. *Anaesthesia* 1987; 42:487-90

8. Friedman PG, Rosenberg MK, Lebenbom-Mansour M: A comparison of light wand and suspension laryngoscopic intubation techniques in outpatients. *Anesth Analg* 1997; 85:578-82

9. Monroe MC, Gravenstein N, Saga-Rumley S: Postoperative sore throat: Effect of oropharyngeal airway in orotracheally intubated patients. *Anesth Analg* 1990; 70:512-6

10. Mulcaster JT, Hung OR, Law A, Pytko S, Alexiadis P: Evaluation of proficiency of laryngoscopic intubation by novice intubators (abstract). *ANESTHESIOLOGY* 1998; 89(3A):A77