

CLINICAL CONCEPTS AND COMMENTARY

Richard B. Weiskopf, M.D., Editor

Anesthesiology
1999; 91:299-302
© 1999 American Society of Anesthesiologists, Inc.
Lippincott Williams & Wilkins, Inc.

Combined Spinal–Epidural Analgesia in Obstetrics

James C. Eisenach, M.D.*

REDISCOVERY 20 yr ago of spinal opioid receptors mediating analgesia led to the clinical introduction of spinal opioids for analgesia. For obstetric analgesia, however, spinal morphine was relatively ineffective and plagued with side effects, and thus it was abandoned rapidly. Approximately 10 yr ago, spinal opioid injection was “revisited” by Leighton *et al.*,¹ this time with a mixture of morphine and fentanyl, with more encouraging results, particularly because they showed that the morphine component was unnecessary and could be eliminated. Since then, clinical interest in the use and possible advantages of spinal opioids for labor analgesia has been considerable. The combination of spinal opioids with subsequent epidural analgesia has been suggested to provide the best of both techniques: rapid onset of analgesia with a minimal drug dose, followed by great flexibility of continuous analgesia. This review focuses on the spinal injection of opioids in this combined technique for labor analgesia.

Combined spinal–epidural analgesia (CSE) most commonly involves insertion of an epidural needle into the lumbar epidural space, passage of the tip of a spinal

needle through this epidural “introducer,” spinal injection, and withdrawal of the needle, and then the insertion of an epidural catheter through the epidural needle for use after the spinal analgesia wanes (fig. 1). Dissimilar to the single-injection spinal technique, this technique involves a large conduit to the epidural space, thereby removing the normal negative epidural space pressure. We could imagine that the dura therefore could be more easily deformed inward with pressure from the blunt, pencil-point spinal needle, and perhaps for this reason, the spinal needle must be long enough to extend 1 cm beyond the tip of the epidural needle to puncture the dura reliably (fig. 1). The hole produced by spinal needles typically used (usually #27 or smaller) is unlikely to allow passage of the subsequently inserted epidural catheter into the intrathecal space or result in exaggerated spread of subsequently administered epidural local anesthetics or opioids.

Initially, opioids without local anesthetics were administered through the spinal injection of CSE.² Sufentanil, approved for epidural use in labor, was evaluated most commonly in the earliest studies. Spinal injection of sufentanil or fentanyl results in rapid (5 min) and nearly complete pain relief in the first stage of labor and lasts approximately 90 min. Sufentanil is approximately five times more potent than fentanyl for spinal or epidural analgesia, and the most commonly used doses are 5–10 mg sufentanil or 20–35 mg fentanyl. Meperidine, which has a local anesthetic-like action, is associated with hypotension after spinal injection and rarely is used. Pain relief from these doses of sufentanil and fentanyl is complete or nearly complete in more than 90% of women in early first-stage labor and lasts 90 min. As women approach complete cervical dilatation, the failure rate increases to 25–30% and the duration decreases to 60 min or less.³

Local anesthetics and α_2 -adrenergic agonists have been combined with opioids for spinal analgesia with CSE in

This article is accompanied by an Editorial View. Please see: Weiskopf RB: Clinical concepts and commentary. ANESTHESIOLOGY 1999; 91:6–7.

* F. M. James III Professor of Anesthesiology.

Received from Wake Forest University School of Medicine, Winston-Salem, North Carolina. Accepted for publication October 14, 1998. Dr. Eisenach is a consultant to Roxane Laboratories, which markets clonidine for epidural injection.

Address reprint requests to Dr. Eisenach: Wake Forest University School of Medicine, Medical Center Boulevard, Winston-Salem, North Carolina 27157-1009. Address electronic mail to: eisenach@wfubmc.edu

Key words: Intrathecal; opioids; pain; respiratory depression.

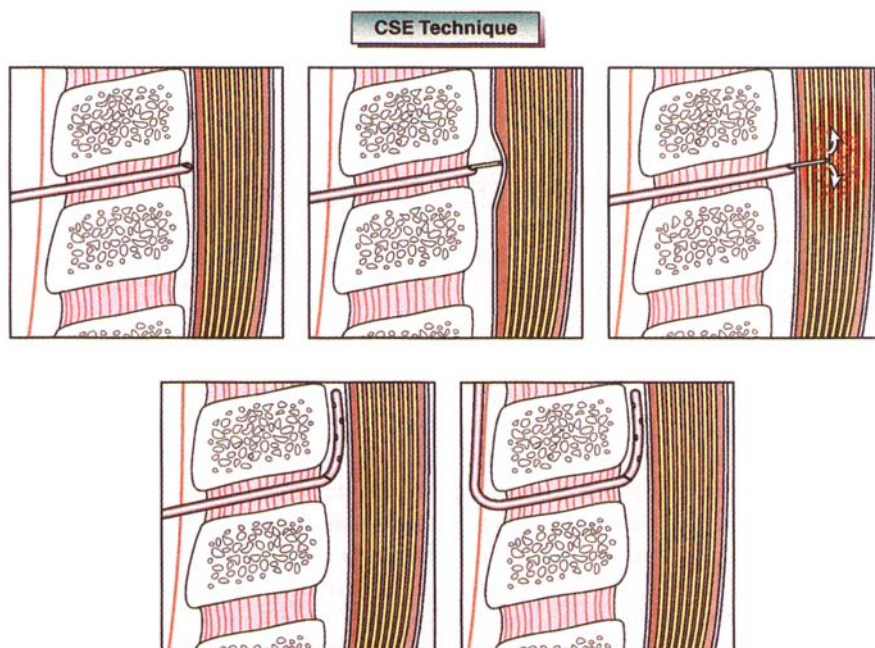


Fig. 1. The combined spinal-epidural technique. Typically, an epidural needle is inserted in the epidural space (*top left*) and a spinal needle is inserted through it (*top middle*). Because of the presence of air in the epidural space, the pencil-point spinal needle may deform the dura considerably before puncturing it (*top right*). After injection through the spinal needle, it is withdrawn, an epidural catheter is inserted (*bottom left*), and the epidural needle is withdrawn (*bottom right*).

labor. Bupivacaine, in a dose of 2.5 mg, prolongs the duration of opioid analgesia by 30 min and decreases the failure rate in women in late labor. Whether smaller doses would be equally effective is not known. Epinephrine, in a dose of 200 μ g, further prolongs the duration of this bupivacaine-opioid mixture by an additional 30 min,⁴ as does clonidine, 50 μ g. Because of concern about contamination or error from mixing multiple drugs and of side effects (muscle spasms and increased motor block with epinephrine or sedation and hypotension with clonidine), spinal epinephrine or clonidine are not administered routinely at most centers.

Spinal opioids, used alone or with bupivacaine, have been associated with a high incidence (> 80%) of pruritus and three major side effects: hypotension (20%), fetal bradycardia (5%), and maternal respiratory depression (0.1%; fig. 2). Injection in a hyperbaric solution and elevating the head of the bed does not decrease reliably the chance of these side effects, but these measures do diminish the extent of analgesia.

Hypotension

Whether reductions in blood pressure after spinal injection of opioids alone represents more than that caused by pain relief (perhaps a minor degree of sympatholysis) is controversial, although several authors report fetal heart rate changes associated with this reduction in

blood pressure that cease after treatment with ephedrine. The addition of even a small dose of local anesthetic can produce sympathetic block and severe hypotension in some women. Hypotension after CSE analgesia is evident within 15 min of injection.

Fetal Bradycardia

Several studies report an association between spinal opioid injection and transient fetal bradycardia in the absence of hypotension, although some authors argue that this is no different than an epidural technique. It has been proposed that the rapid onset of pain relief after spinal opioid injection results in an abrupt decrease in circulating epinephrine concentrations, and that this decrease removes a β -adrenergic "break" in uterine activity. Some investigators argue that for a few minutes, until a new equilibrium is reached, uterine contractions are more frequent and intense, resulting in a mild "stress test" to the fetus. This theory corresponds with observations of fetal bradycardia after CSE that is rapid in onset (occurring within 15 min of injection), transient (< 30 min), and accompanied by an increased frequency or intensity of contractions. The role of tocolytics in this situation is controversial. The fetal heart rate should be monitored after CSE injection.

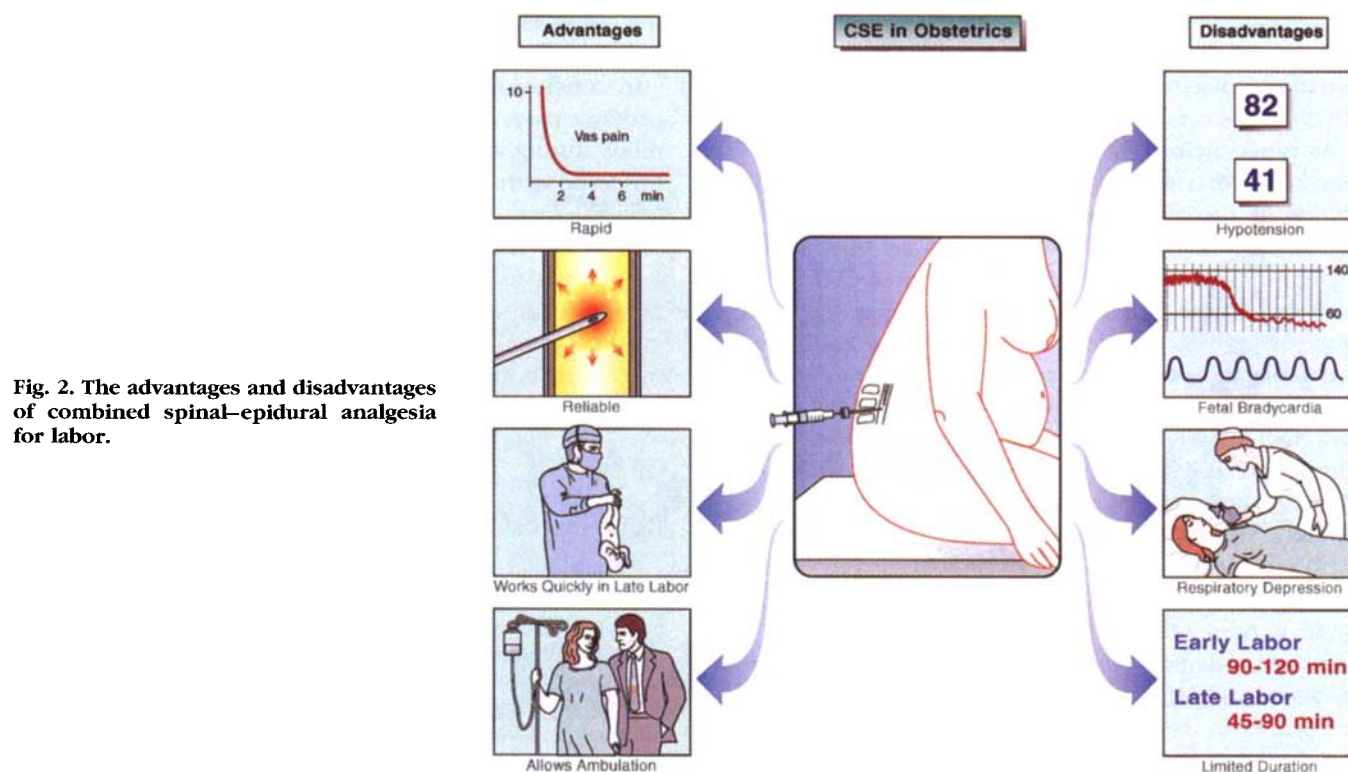


Fig. 2. The advantages and disadvantages of combined spinal-epidural analgesia for labor.

Respiratory Depression

Dissimilar to morphine, respiratory depression associated with spinal injection of sufentanil or fentanyl occurs rapidly, within 20 min of injection. It is estimated to occur with an incidence of approximately 0.01% to 0.1% and can be life threatening. Clinically significant respiratory depression has not been reported in the absence of intense sedation, and most authors suggest personal observation for signs of intense sedation and depressed respiratory rate during this 20-min period rather than reliance on electronic monitors. Rapid onset of respiratory depression coincides with the rapid spread of fentanyl and sufentanil in CSF to high cervical levels, which can be observed in pharmacokinetic study and inferred from rapid spread of cutaneous hypalgesia to upper thoracic or cervical dermatomes after spinal lumbar opioid injection.

Several advantages have been cited for CSE compared with standard epidural analgesia for labor (fig. 2). First, it is more rapid in onset. Although this is true from the time of injection, this difference is small (< 15 min) and is further reduced if more preparation time is required to obtain controlled substances from locked areas and to retrieve a special equipment tray. Second, CSE is more

reliable. Certainly it is difficult to obtain a unilateral effect with a spinal injection. However, the failure rate of the technique in experienced hands ($< 5\%$) is minimally different than that for epidural analgesia. Third, CSE is effective in late, rapidly moving labor. Few would argue that, if delivery occurs within 20 min of preparing the back for an injection, success with a spinal injection of opioid plus local anesthetic is more likely to be achieved than with an epidural technique. Fourth, CSE produces minimal motor block and allows ambulation in early labor. Whether this is truly different from various ultra-low-dose epidural techniques, or whether ambulation truly affects patient satisfaction or labor outcome are questions being actively investigated. Thus, CSE may be particularly appropriate when analgesia must be achieved rapidly (late, rapid labor in multiparous women) or with minimal motor block (ambulation during labor).

When effective means of labor analgesia are readily available, they are used by 60–80% of women. In contrast, aside from a very few, primarily academic centers, the use of spinal opioids rarely exceeds 20% of the total epidural plus spinal techniques for labor analgesia, and many centers avoid spinal injections entirely. Thus, al-

though spinal injections followed by epidural analgesia to treat labor pain are no longer experimental, neither are they replacing wholesale standard epidural methods. There are several reasons for this.

As noted before, many of the advantages commonly cited for CSE compared with plain epidural analgesia are minor or can be debated. Combined spinal-epidural analgesia is a more invasive technique than epidural analgesia, and reports of meningitis after CSE in labor may indicate an increased risk for this feared complication (or perhaps simply the ease of publishing a case of a complication associated with a new technique). Combined spinal-epidural analgesia probably increases the risk for headache compared with epidural analgesia alone, because the CSE technique is used only when there is no evidence of a dural puncture when the epidural needle is placed, and this subgroup of women who receive epidural analgesia should have a very low incidence of headache. Combined spinal-epidural analgesia is used with drugs not approved for spinal use (fentanyl, sufentanil) or warned against for this use (bupivacaine, 0.25%; clonidine), which might increase medicolegal risks. Finally, CSE delays the identification of a poorly functioning epidural catheter, which might require replacement. For this reason, many avoid the CSE technique when they want to determine rapidly the efficacy of the epidural catheter: in women with severe preeclampsia and decreasing platelet count, morbidly obese women, stress patterns on the fetal heart rate

tracing, concern that an emergent cesarean section may be necessary, and so forth.

In conclusion, CSE represents an elegant approach to produce easy, rapid, reliable selective and complete pain relief during labor.⁵ Side effects are similar to those observed with epidural analgesia, although they typically occur earlier. A single-injection spinal, at least with current drugs, will not replace epidural analgesia for labor: its effect is too short-lived, and it does not possess the flexibility for use for subsequent prolonged labor, instrumental vaginal delivery, or cesarean section. Current use of CSE, although not investigational, appears to be restricted to a few specific settings in the parturient.

References

1. Leighton BL, DeSimone CA, Norris MC, Ben-David B: Intrathecal narcotics for labor revisited: The combination of fentanyl and morphine intrathecally provides rapid onset of profound, prolonged analgesia. *Anesth Analg* 1989; 69:122-5
2. Honet JE, Arkoosh VA, Norris MC, Huffnagle HJ, Silverman NS, Leighton BL: Comparison among intrathecal fentanyl, meperidine, and sufentanil for labor analgesia. *Anesth Analg* 1992; 75:734-9
3. Viscomi CM, Rathmell JP, Pace NL: Duration of intrathecal labor analgesia: Early versus advanced labor. *Anesth Analg* 1997; 84:1108-12
4. Campbell DC, Banner R, Crone LA, Gore-Hickman W, Yip RW: Addition of epinephrine to intrathecal bupivacaine and sufentanil for ambulatory labor analgesia. *ANESTHESIOLOGY* 1997; 86:525-31
5. Rawal N, van Zundert A, Holmstrom B, Crowhurst JA: Combined spinal-epidural technique. *Reg Anesth* 1997; 22:406-23