

Dose Response of Intravenous Heparin on Markers of Thrombosis during Primary Total Hip Replacement

Nigel E. Sharrock, M.B., Ch.B.,* George Go, B.S.,† Thomas P. Sculco, M.D.,‡ Eduardo A. Salvati, M.D.,‡ Geoffrey H. Westrich, M.D.,§ Peter C. Harpel, M.D.||

Background: Thrombogenesis in total hip replacement (THR) begins during surgery on the femur. This study assesses the effect of two doses of unfractionated intravenous heparin administered before femoral preparation during THR on circulating markers of thrombosis.

Methods: Seventy-five patients undergoing hybrid primary THR were randomly assigned to receive blinded intravenous injection of either saline or 10 or 20 U/kg of unfractionated heparin after insertion of the acetabular component. Central venous blood samples were assayed for prothrombin F1+2 (F1+2), thrombin-antithrombin complexes (TAT), fibrinopeptide A (FPA), and D-dimer.

Results: No changes in the markers of thrombosis were noted after insertion of the acetabular component. During surgery on the femur, significant increases in all markers were noted in the saline group ($P < 0.0001$). Heparin did not affect D-dimer or TAT. Twenty units per kilogram of heparin significantly reduced the increase of F1+2 after relocation of the hip joint ($P < 0.001$). Administration of both 10 and 20 U/kg significantly reduced the increase in FPA during implantation of the femoral component ($P < 0.0001$). A fourfold increase in FPA was noted in 6 of 25 patients receiving 10 U/kg of heparin but in none

receiving 20 U/kg ($P = 0.03$). Intraoperative heparin did not affect intra- or postoperative blood loss, postoperative hematocrit, or surgeon's subjective assessments of bleeding. No bleeding complications were noted.

Conclusions: This study demonstrates that 20 U/kg of heparin administered before surgery on the femur suppresses fibrin formation during primary THR. This finding provides the pathophysiologic basis for the clinical use of intraoperative heparin during THR. (Key words: Epidural anesthesia; epinephrine; fibrin generation.)

PULMONARY embolism (PE) remains the most common cause of death after total hip replacement (THR).¹ Postoperative anticoagulants decrease the risk of thromboembolism, but they are associated with an increased risk of wound hematoma or other bleeding complications.^{2,3} Furthermore, low molecular weight heparin is associated with epidural hematoma, especially in orthopedic patients receiving epidural anesthesia.⁴ Pneumatic compression boots⁵ or foot pumps⁶ can be effective, but compliance can be poor.^{7,8} A reliable means of decreasing the risk of thromboembolism and PE after THR, which also does not increase the risk of bleeding, would be beneficial.

During THR, there is minimal activation of thrombogenesis on the acetabulum, but an immediate activation of thrombosis occurs during surgery on the femur.^{9,10} The increase in thrombogenesis is more pronounced using cemented rather than cementless femoral components and was related to time that the leg was held in flexion, adduction, and internal rotation, a position known to occlude the femoral vein.⁹ We subsequently demonstrated that an intravenous injection of 1,000 U heparin significantly suppressed the increase in one of the markers of thrombosis—fibrinopeptide A (FPA). FPA levels were not suppressed in 3 of the 12 patients who received 1,000 U heparin,⁹ suggesting that a higher dose may be needed in some patients.

In this study, a single intravenous bolus of heparin was administered on a weight-adjusted basis using two dosage regimens (10 and 20 U/kg) to determine which

* Senior Scientist and Attending Anesthesiologist, Department of Anesthesiology, The Hospital for Special Surgery.

† Research Assistant, Department of Anesthesiology, The Hospital for Special Surgery.

‡ Professor of Surgery, Department of Orthopaedic Surgery, The Hospital for Special Surgery.

§ Associate Professor of Surgery, Department of Orthopaedic Surgery, The Hospital for Special Surgery.

|| Professor of Medicine, Division of Hematology, Mt. Sinai Hospital.

Received from the Departments of Anesthesiology and Orthopaedic Surgery, The Hospital for Special Surgery, Cornell University Medical College, and from the Division of Hematology, Mt. Sinai Hospital, Mt. Sinai School of Medicine, New York, New York. Submitted for publication June 17, 1998. Accepted for publication November 19, 1998. Supported by The Hospital for Special Surgery, Anesthesia Research Fund. Patient samples were collected at the Hospital for Special Surgery, and laboratory assays were performed at Mt. Sinai Hospital. Presented at the XVIth Congress of the International Society on Thrombosis and Haemostasis, Florence, Italy, June 6-12, 1997.

Address reprint requests to Dr. Sharrock: Department of Anesthesiology, The Hospital for Special Surgery, 535 East 70th Street, New York, New York 10021. Address electronic mail to: goelot@aol.com

provides the most effective suppression of fibrin and, therefore, thrombus formation.

Materials and Methods

After Institutional Review Board approval, 75 patients undergoing primary hybrid THR signed informed consent forms to participate in the study protocol. Patients were randomly allocated into three groups to receive: (1) normal saline or (2) heparin in a dose of either 10 U/kg or (3) 20 U/kg, intravenously. The study medication had been prepared in the hospital pharmacy, the ampules identified by case number only, and the code was broken on completion of the study, facilitating a double-blinded study protocol.

All patients received hypotensive epidural anesthesia (HEA) as previously described.¹¹ Patients were monitored with electrocardiography and pulse oximetry. Arterial pressure and central venous pressures (CVP) were monitored *via* radial artery and internal jugular catheters, respectively. CVP was maintained at 2–5 mmHg and mean arterial pressure (MAP) at 45–55 mmHg throughout surgery. Epidural anesthesia was performed at the L1–L2 interspace using 20–25 ml of 0.75% bupivacaine. Sedation was maintained with midazolam and fentanyl, as required to maintain patients comfortable but arousable. All patients breathed nasal oxygen, 3 l/min, spontaneously throughout surgery.

All surgical procedures were performed in the lateral decubitus position *via* the posterior approach. After femoral osteotomy, the acetabulum was reamed, and a cementless cup was inserted. Immediately thereafter, saline or heparin was administered. The leg was then flexed and internally rotated, the canal reamed, a trial prosthesis inserted and removed, and a cement restrictor placed. The canal was cleaned using pulsatile lavage and dried. Methylmethacrylate was injected into the canal in a retrograde fashion *via* a syringe, and then the femoral component was inserted. After hardening of the cement, the hip was relocated, and the wound was closed.

Five blood samples were taken at specific times during surgery: Sample 1—baseline, before epidural injection; Sample 2—immediately after insertion of acetabulum; Sample 3—five minutes after insertion of femoral prosthesis; Sample 4—two minutes after hip relocation; Sample 5—thirty minutes after surgery. Blood samples were drawn from the central venous cannula in the following manner: 4 ml of blood was withdrawn *via* a stopcock as a discard, and 8 ml of blood was withdrawn into a 10-ml

syringe. Samples for prothrombin F1+2 (F1+2), thrombin-antithrombin complexes (TAT), and D-dimer were placed into citrated tube (0.13 M sodium citrate, 9:1 volume to volume), and samples for fibrinopeptide A (FPA) quantification were collected in tubes containing an anticoagulant solution, provided with the Asserachrom (Diagnostica Stago, Franconville, France) fibrinopeptide A kit. The blood was then centrifuged at 2000g for 15 min at 4°C. Plasma samples were immediately stored at –70°C until ready for assay. Plasma samples for FPA were treated with bentonite twice before performing the assay. F1+2 was measured by enzyme-linked immunosorbent assay using the Enzygnost F1+2 kit (Behring Diagnostics Inc., Somerville, NJ). FPA, TAT, and D-dimer were measured by enzyme-linked immunosorbent assay using the respective Asserachrom kits (Diagnostica Stago). Patients did not receive blood during the observation period for markers of thrombosis.

To determine whether the doses of heparin had any effect on bleeding, the operating surgeons were asked to rank subjectively the degree of bleeding: during incision, with exposure of the hip joint, and while reaming the acetabulum and femur. "Bleeding" was ranked subjectively as less than expected, normal, or excessive. The volume of intravenous fluid infused, the intraoperative blood loss (by weighing sponges), and postoperative hemovac drainage were measured. Pre- and postoperative hematocrits were measured, and the number of units of autologous or allogenic blood infused was recorded. All wounds were inspected daily for evidence of wound hematoma.

Statistical Analysis

The alpha is set to 0.05 for each variable: F1+2, TAT, FPA, and D-dimer. No correction has been applied for these four variables, which are probably not independent of one another. A repeated measures analysis of variance (ANOVA) over time with heparin dose as an independent factor was done for each variable. A Bonferroni correction was applied for the within factor of time. Contrasts were used to compare saline to the 10-U/kg dose and the 10-U/kg to the 20-U/kg dose overall, and simple effects models were used at each time point. To render the data compatible with the underlying hypothesis of a normal distribution, the FPA and D-dimer data were transformed using the natural logarithm of the observed value, and for TAT, the square root of the observed value was used. Differences in blood loss were measured by 2 × 2 Mann-Whitney test. Transfusion requirements were analyzed using Fisher exact test, and

INTRAVENOUS HEPARIN DURING TOTAL HIP REPLACEMENT

Table 1. Patient Demographics, iv Fluids, and Duration of Surgery between Groups

	Saline	10 units/kg	20 units/kg
Gender (F/M)	15/10	14/11	6/19
Age (range) (yr)	66 (50-78)	65 (54-77)	63 (51-74)
Height (cm) (mean \pm SD)	167 \pm 8	168 \pm 10	174 \pm 7
Weight (kg) (mean \pm SD)	76 \pm 14	77 \pm 19	83 \pm 13
ASA			
I	4	4	4
II	11	17	19
III	10	4	2
iv fluids (ml) (mean \pm SD)	1,552 \pm 420	1,583 \pm 398	1,739 \pm 523
Duration of surgery (min) (mean \pm SD)	77 \pm 12	80 \pm 15	72 \pm 10

the ranking of bleeding was analyzed with the Kruskal-Wallis test.

Results

All patients completed the study protocol. There were no significant differences in patient demographic variables, volumes of intravenous fluid administered, or the duration of surgery between groups (table 1).

Indexes of bleeding were similar between groups. Pre- and postoperative values of hematocrit, intraoperative blood loss, and postoperative drainage were similar (table 2). There was no difference in transfusion requirements between groups. There were no wound hematomas, and no patients returned to the operating room to explore the joint for hematoma or infection, nor were there any significant bleeding complications from other sites.

The surgeon's assessment of bleeding demonstrated no differences between groups (table 3).

Blood levels of the four markers—F1+2, TAT, FPA, and D-dimer—are shown in figures 1, 2, 3 and 4, respectively.

Prothrombin F1+2 (fig. 1) levels did not increase after insertion of the cup in any of the three groups. There-

after, values increased in all groups ($P < 0.0001$). F1+2 was significantly lower in the 20-U/kg group compared with the saline group at each point thereafter ($P = 0.03$, 0.001, and 0.04 at samples 3, 4, and 5, respectively). There were no differences between the 10- and 20-U/kg groups.

There was no significant increase in TAT (fig. 2) after insertion of the acetabulum in any of the three groups. Thereafter, values increased in all groups ($P < 0.0001$). There were no significant differences between groups at any sample point.

There was no significant increase in FPA (fig. 3) after insertion of the cup in any of the three groups. With insertion of the femoral component, FPA increased sevenfold from 10.8 to 73 ng/ml (samples 2-4) in patients receiving saline; FPA increased twofold from 9.6 to 22.2 ng/ml (samples 2-4) in patients receiving 10 U/kg heparin but did not increase in patients receiving 20 U/kg heparin (samples 2-4). FPA levels at samples 3 and 4 were significantly lower in both groups receiving 10 and 20 U/kg heparin compared with the saline group ($P < 0.0001$). FPA at the end of surgery was similar in all groups.

Examination of individual responses demonstrated that FPA levels increased to a variable extent during insertion

Table 2. Estimated Blood Loss, Postoperative Wound Drainage, and Mean Perioperative Values of Hemoglobin, and Platelet Count

	Saline	10 units/kg	20 units/kg
Estimated blood loss during surgery (ml)	141 \pm 57	166 \pm 40	159 \pm 66
Postoperative wound drainage (ml)	351 \pm 203	350 \pm 141	414 \pm 216
Hemoglobin (g/dl)			
Preoperative	12.2 \pm 1.0	12.1 \pm 1.3	13.4 \pm 1.4
Postoperative day 1	10.4 \pm 1.0	10.2 \pm 1.1	11.3 \pm 1.2
Postoperative day 2	10.5 \pm 1.2	10.1 \pm 1.2	11.3 \pm 1.2
Platelet (1,000/ μ l)			
Preoperative	313 \pm 87	270 \pm 73	262 \pm 51
Postoperative day 1	226 \pm 51	208 \pm 63	200 \pm 37
Postoperative day 2	222 \pm 62	200 \pm 59	189 \pm 46

Values are mean \pm SD.

Table 3. Surgeon's Assessment of Bleeding During Specific Surgical Maneuvers between Groups

Surgical Maneuvers	Saline			10 units/kg			20 units/kg		
	Less	Normal	Excessive	Less	Normal	Excessive	Less	Normal	Excessive
Skin incision	12	10	3	5	9	11	14	8	3
Incision of capsule	10	12	3	12	9	4	12	8	5
Reaming of acetabulum	13	10	2	10	12	3	11	11	3
Reaming of femur*	14	7	4	9	15	1	14	10	1

* Heparin or saline was administered following reaming of the acetabulum and insertion of the cup.

of the femoral component in patients receiving heparin (fig. 5). A fourfold increase in FPA was noted during insertion of the femoral component in 6 of 25 patients receiving 10 U/kg heparin but in none of those receiving 20 U/kg ($P = 0.03$).

D-dimer (fig. 4) did not increase after insertion of the acetabulum in any of the three groups. With insertion of the femoral component, D-dimer progressively increased ($P < 0.0001$). There were no significant differences between groups at any of the observation points.

Discussion

In this study, heparin was administered as a single intravenous dose after implantation of the cup. Heparin was to provide anticoagulation during surgery on the femur because during this phase of the operation thrombogenesis may occur.⁹ There was no activation of thrombin formation during surgery on the acetabulum. This protocol has two potential advantages: (1) there is a time delay between inserting the epidural catheter and administering heparin, and (2) the initial phase of the operation can be performed without anticoagulation. In previous studies, we used heparin either throughout surgery¹² or at two points in time.¹³

These data demonstrate statistically significant suppression of fibrin formation (as demonstrated by FPA

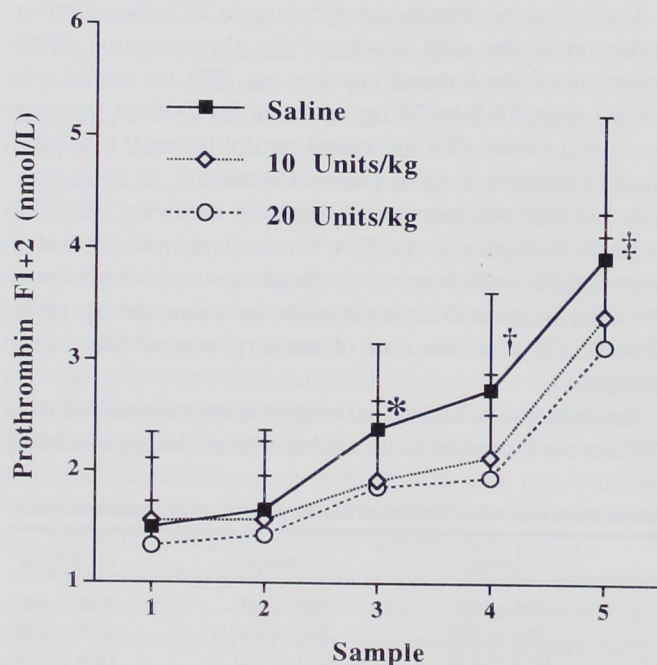


Fig. 1. Blood levels of prothrombin F1+2 (F1+2) during hybrid total hip replacement. Significant increases in F1+2 occurred during surgery on the femur. Values for F1+2 were significantly lower in the 20-U/kg heparin group than the saline group during surgery on the femur. Values are mean \pm SD. * $P = 0.03$ compared with 20 U/kg. † $P = 0.001$ compared with 20 U/kg. ‡ $P = 0.04$ compared with 20 U/kg.

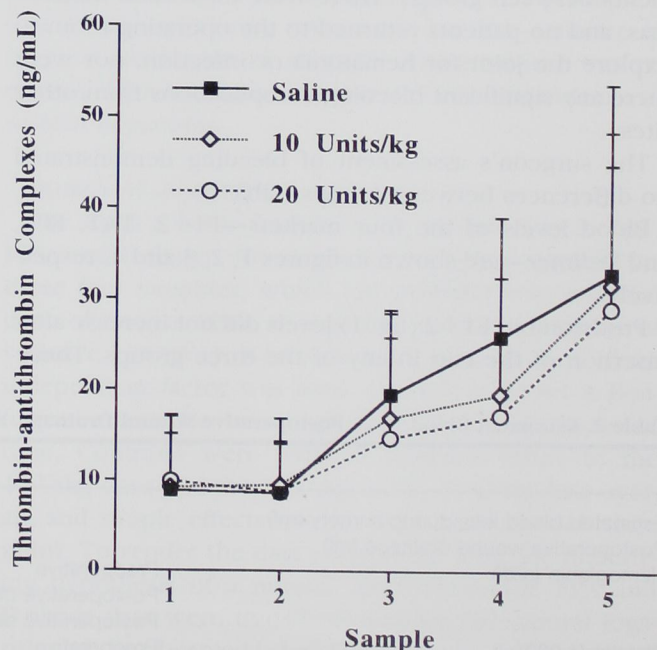


Fig. 2. Blood levels of thrombin-antithrombin complexes (TAT) during hybrid total hip replacement. Significant increases occurred during surgery on the femur in all groups. Values are mean \pm SD.

INTRAVENOUS HEPARIN DURING TOTAL HIP REPLACEMENT

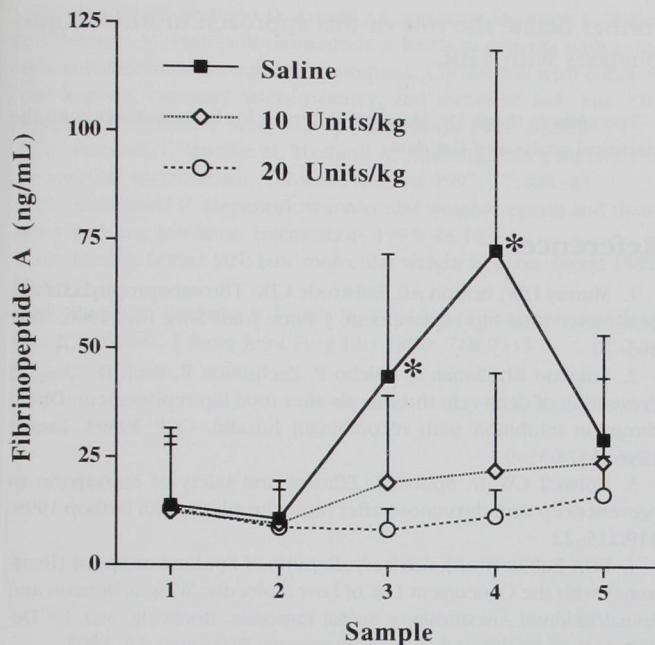


Fig. 3. Blood levels of fibrinopeptide A (FPA) during hybrid total hip replacement. Note the increase in FPA in the saline group and the significant suppression in the 10-U/kg and 20-U/kg heparin groups during insertion of the femoral component. Values are mean \pm SD. * $P = 0.0001$ compared with 10 and 20 U/kg.

levels) during insertion of the cemented femoral component with doses of 10 and 20 U/kg heparin used as a single intravenous bolus after implantation of the cup. Twenty units per kilogram suppressed FPA increases in all 25 patients, whereas of those given 10 U/kg, 6 of 25 patients exhibited a fourfold increase in FPA, suggesting incomplete thrombin inhibition in one fourth of the patients.

The clinically effective dose of heparin has been studied in *in vitro* models and in clinical practice.^{13,14} Minimal increases in activated partial thromboplastin time (aPTT) are usually sufficient to prevent venous thrombosis.¹⁴ In a previous study, we demonstrated that 1,000 and 1,500 U heparin increased the activated clotting time by about 30% or 50%, respectively.¹³ In the present study, we demonstrated that 10 U/kg heparin suppressed increases in FPA, but not as reliably as 20 U/kg. FPA is a more precise index of heparin action than aPTT because FPA measures the degree of inhibition of fibrin formation directly.¹⁵ The aPTT was not measured in this study.

Unfractionated heparin is known to act at multiple sites to prevent coagulation.¹⁴ There was some suppression of F1+2 and TAT levels, suggesting that the heparin

may have suppressed factor Xa activity to some extent. This could be caused by either a direct inhibitory action on factor Xa or possibly by suppressing factor VII activation through heparin's effect on tissue factor pathway inhibitor.^{16,17} The predominant mechanism of action of unfractionated heparin in this study, however, appears to be by functioning as a thrombin inhibitor, as FPA formation was significantly suppressed, especially with the 20-U/kg dose. By contrast, low molecular weight heparin is believed to act primarily as an Xa inhibitor.¹⁸

In these low doses, heparin has a short biological effect. We previously measured indexes of heparin action and noted resolution of the heparin effect in 20–30 min.¹³ Thus, if the surgery on the femur is completed within 30 min, effective prophylaxis can be achieved. To minimize the risk of developing venous thrombosis, the duration of potential femoral venous occlusion should be kept to a minimum.^{9,19} *In vitro* studies have demonstrated that 10 min of complete venous obstruction with a thrombogenic stimulus is sufficient to initiate thrombosis.^{20,21} In a previous study, we noted that the increase in F1+2 was related to the duration of femoral venous occlusion.⁹ Thus, we believe that expeditious surgery facilitates the efficacy of heparin.

There was no evidence that the doses of heparin used increased intra- or postoperative bleeding. Intraoperative bleeding was assessed subjectively by asking the operating surgeon to rank the degree of bleeding during

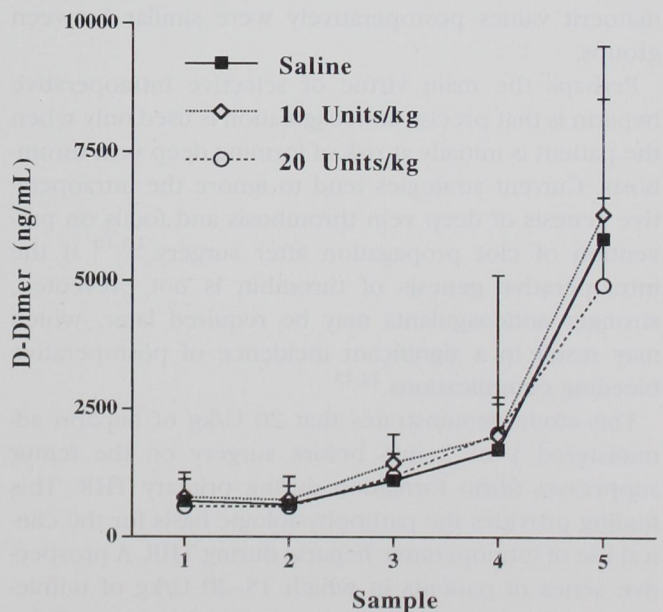


Fig. 4. Blood levels of D-dimer during hybrid total hip replacement. Significant increases occurred during surgery on the femur in all groups. Values are mean \pm SD.

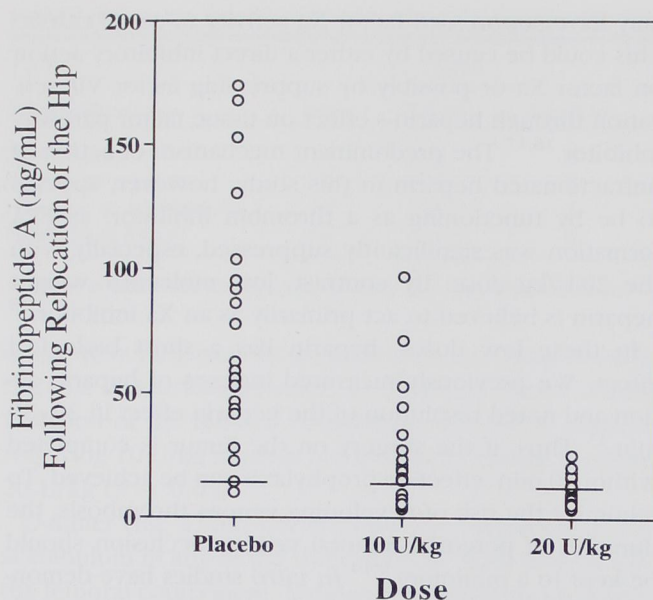


Fig. 5. Blood levels of fibrinopeptide A (FPA) after relocation of the hip joint after inserting a cemented femoral component (Sample 4). Note the range in response in the saline and 10-U/kg heparin groups, whereas there is uniform suppression in the 20-U/kg heparin group. The horizontal bar is the mean value of FPA at baseline for each group.

four separate phases of surgery and by measuring the blood loss intraoperatively. Postoperative bleeding was measured by wound drainage. None of these variables were altered by intraoperative heparin. Finally, the hematocrit values postoperatively were similar between groups.

Perhaps the main virtue of selective intraoperative heparin is that precise anticoagulation is used only when the patient is initially at risk of forming deep vein thrombosis. Current strategies tend to ignore the intraoperative genesis of deep vein thrombosis and focus on prevention of clot propagation after surgery.^{2,3,10} If the intraoperative genesis of thrombin is not prevented, stronger anticoagulants may be required later, which may result in a significant incidence of postoperative bleeding complications.^{22,23}

This study demonstrates that 20 U/kg of heparin administered 1 or 2 min before surgery on the femur suppresses fibrin formation during primary THR. This finding provides the pathophysiologic basis for the clinical use of intraoperative heparin during THR. A prospective series of patients in which 15–20 U/kg of unfractionated heparin is administered after insertion of the acetabulum is currently being performed. Clinical PE and evidence of clinical bleeding are being measured to

further define the role of this approach to thromboprophylaxis with THR.

The authors thank Dr. Margaret Peterson for her assistance with the statistical analysis of the data.

References

1. Murray DW, Britton AR, Bulstrode CJK: Thromboprophylaxis and death after total hip replacement. *J Bone Joint Surg [Br]* 1996; 78B: 863–70
2. Eriksson BI, Ekman S, Kälebo P, Zachrisson B, Bach D, Close P: Prevention of deep-vein thrombosis after total hip replacement: Direct thrombin inhibition with recombinant hirudin, CGP 39393. *Lancet* 1996; 347:635–9
3. Colwell CW Jr, Spiro TE: Efficacy and safety of enoxaparin to prevent deep vein thrombosis after hip arthroplasty. *Clin Orthop* 1995; 319:215–22
4. FDA Public Health Advisory: Reports of Epidural or Spinal Hematomas with the Concurrent Use of Low Molecular Weight Heparin and Spinal/Epidural Anesthesia or Spinal Puncture. Rockville, MD, US Department of Health and Human Resources, December 15, 1997
5. Woolson ST, Watt JM: Intermittent pneumatic compression to prevent proximal deep venous thrombosis during and after total hip replacement. A prospective randomized study of compression alone, compression and aspirin, and compression and low-dose warfarin. *J Bone Joint Surg [Am]* 1991; 73A:507–12
6. Santori FS, Vitullo A, Stopponi N, Santori N, Ghera S: Prophylaxis against deep-vein thrombosis in total hip replacement. Comparison of heparin and foot impulse pump. *J Bone Joint Surg [Br]* 1994; 76B: 579–83
7. Westrich GH, Sculco TP: Prophylaxis against deep venous thrombosis after total knee arthroplasty. Pneumatic plantar compression and aspirin compared with aspirin alone. *J Bone Joint Surg [Am]* 1996; 78A:826–34
8. Comerota AJ, Katz ML, White JV: Why does prophylaxis with external pneumatic compression for deep vein thrombosis fail? *Am J Surg* 1992; 164:265–8
9. Sharrock NE, Go G, Harpel PC, Ranawat CS, Sculco TP, Salvati EA: Thrombogenesis during total hip replacement. *Clin Orthop* 1995; 319: 16–27
10. Dahl OE, Andreassen G, Aspelin T, Müller C, Mathiessen P, Nyhus S, Abdelnoor M, Solhaug J-H, Arnessen H: Prolonged thromboprophylaxis following hip replacement surgery—Results of a double-blind, prospective, randomised, placebo-controlled study with dalteparin (Fragmin®). *Thromb Haemost* 1997; 77:26–31
11. Sharrock NE, Salvati EA: Hypotensive epidural anesthesia for total hip arthroplasty. *Acta Orthop Scand* 1996; 67:91–107
12. Sharrock NE, Brien WW, Salvati EA, Mineo R, Garvin K, Sculco TP: The effect of intravenous fixed-dose heparin during total hip arthroplasty on the incidence of deep-vein thrombosis. A randomized, double-blind trial in patients operated on with epidural anesthesia and controlled hypotension. *J Bone Joint Surg [Am]* 1990; 72A:1456–61
13. Huo MH, Salvati EA, Sharrock NE, Brien WW, Sculco TP, Pellici PM, Mineo R, Go G: Intraoperative heparin thromboembolic prophylaxis in primary total hip arthroplasty. A prospective, randomized, controlled, clinical trial. *Clin Orthop* 1992; 274:35–46
14. Hirsh J: Heparin. *N Engl J Med* 1991; 324:1565–74

INTRAVENOUS HEPARIN DURING TOTAL HIP REPLACEMENT

15. Rapold HJ, de Bono D, Arnold AE, Arnout J, De Cock F, Collen D, Verstraete M: Plasma fibrinopeptide A levels in patients with acute myocardial infarction treated with alteplase. Correlation with concomitant heparin, coronary artery patency, and recurrent ischemia. The European Cooperative Study Group. *Circulation* 1992; 85:928-34
16. Bombeli T, Mueller M, Haerberli A: Anticoagulant properties of the vascular endothelium. *Thromb Haemost* 1997; 77:408-23
17. Abildgaard U: Heparin/low molecular weight heparin and tissue factor pathway inhibitor. *Haemostasis* 1993; 23:103-6
18. Hirsh J, Levine MN: Low molecular weight heparin. *Blood* 1992; 79:1-17
19. Planès A, Vochelle N, Fagola M: Total hip replacement and deep vein thrombosis. *J Bone Joint Surg [Br]* 1990; 72B:9-13
20. Stewart GJ: Neutrophils and deep venous thrombosis. *Haemostasis* 1993; 23 (Suppl 1):127-40
21. Wessler S: Thrombosis in the presence of vascular stasis. *Am J Med* 1962; 33:648-66
22. Pellegrini VD Jr, Totterman S, Ayers DC, Johanson N, Stulberg BN, Rosenberg A, Kessler C, Francis C: Comparison of a low molecular weight heparin and warfarin in prevention of deep vein thrombosis after total hip arthroplasty. *Orthop Trans* 1997; 21:124
23. Colwell CW Jr, Collis D, Paulson R, McCutchen J, Bigler G, Hardwick M, Hernandez R, Lutz S: Enoxaparin versus warfarin: Hospital management for prevention of DVT following total hip arthroplasty with inpatient and three month evaluation. *Orthop Trans* 1997; 21:125