

CASE REPORTS

References

1. Moss J, Rosow CE: Histamine release by narcotics and muscle relaxants in humans. *ANESTHESIOLOGY* 1983; 59:330-9
2. Laxenaire MC, Moneret-Vautrin DA, Widmer S, Monton C: Substances anesthésiques responsables de chocs anaphylactiques. Enquête multicentrique française. *Ann Fr Anesth Réanim* 1990; 9:501-6
3. Kaplan AP, Gray L, Shaff RE, Horokova Z, Beaven MA: In vivo studies of mediator release in cold urticaria and cholinergic urticaria. *J Allergy Clin Immunol* 1975; 55:394-402
4. Capulonc MC, Tomikawa M, Tahara K, Akasawa A, Iikura Y: Cold stimulation test and histamine release in primary acquired cold urticaria. *Int Arch Allergy Immunol* 1997; 114:400-3
5. Fisher MM, Baldo BA: The incidence and clinical features of anaphylactic reactions during anaesthesia in Australia. *Ann Fr Anesth Réanim* 1993; 12:97-104
6. Wanderer AA: Cold urticaria syndromes. *J Allergy Clin Immunol* 1990; 85:965-81
7. Kotou—Fili K, Borici—Mazi R, Kapp A, Matjevic LJ, Mitchel FB: Physical urticaria: Classification and diagnosis guidelines. *Allergy* 1997; 52:504-13
8. Bourdon H: Note sur l'urticaire intermittente. *Bull Mem Soc Med Hop Paris* 1866; 3:259-62
9. Horton BT, Brown GE, Roth GM: Hypersensitiveness to cold with local and systemic manifestations of a histamine-like character: Its amenability to treatment. *JAMA* 1936; 107:1263-9
10. Lockhart CH, Brownrigg JC: Anesthetic hazards of cold urticaria. *ANESTHESIOLOGY* 1973; 38:96-7
11. Burton Bentley II: Cold induced urticaria and angioedema: Diagnosis and management. *Am J Emerg Med* 1993; 11:43-6
12. Wanderer AA, Maselli R, Ellis EF, Ishizaka K: Immunologic characterization of serum factors responsible for cold urticaria. *J Allergy* 1971; 48:13-22
13. Houser DD, Arbesman CE, Ito K, Wicher K: Cold urticaria: Immunologic studies. *Am J Med* 1970; 49:23-33
14. Greaves MW, O'Donnell BF: Not all chronic urticaria is "idiopathic." *Exp Dermatol* 1998; 7:11-13
15. Gruber BL, Baeza ML, Marchese MJ, Aguello V, Kaplan AP: Autoantibodies in urticarial syndromes. *J Invest Dermatol* 1988; 90:213-7
16. Johnston WE, Moss J, Philbin DM, Guiney TE, Sisson JH, Buckley MJ, Lowenstein E: Management of cold urticaria during hypothermic cardiopulmonary bypass. *N Engl J Med* 1982; 306:219-21

Anesthesiology

1999; 90:909-11

© 1999 American Society of Anesthesiologists, Inc.

Lippincott Williams & Wilkins, Inc.

Hemofiltration in Parallel to the Venovenous Bypass Circuit for Oliguric Hypervolemia during Liver Transplantation

Mitchell David Tobias, M.D.,* Christopher S. Jobes, B.S., C.C.P.,† Stanley J. Aukburg, M.D.‡

PATIENTS undergoing liver transplantation often require blood components perioperatively for the treatment of coagulation factor deficiencies, thrombocytopenia, and anemia. Preexisting hypervolemia may limit this therapy,

particularly when oliguric renal failure complicates end-stage liver disease. Intravascular volume reduction is then often accomplished with continuous arteriovenous hemodialysis (CAVHD), continuous arteriovenous hemofiltration (CAVH) or continuous venovenous hemofiltration (CVVH). This report concerns intraoperative CVVH, in parallel to the venovenous bypass (VVB) system, without anticoagulants during liver transplantation. With this CVVH technique, transmembrane pressure gradients and ultrafiltration rates resemble that of CAVH.

* Assistant Professor of Anesthesia, University of Pennsylvania School of Medicine.

† Perfusionist, University of Pennsylvania Medical Center.

‡ Associate Professor of Anesthesia, University of Pennsylvania School of Medicine.

Received from the Department of Anesthesia of the University of Pennsylvania School of Medicine, Philadelphia, Pennsylvania. Submitted for publication March 9, 1998. Accepted for publication November 12, 1998. Funding was provided by the Department of Anesthesia of the University of Pennsylvania School of Medicine.

Address reprint requests to Dr. Tobias: Department of Anesthesia, 1107 Penn Tower, 3400 Spruce Street, Philadelphia, Pennsylvania 19102. Address electronic mail to: mtobias@mail.med.upenn.edu

Key words: Hypervolemia; liver failure; pressure gradient; renal failure.

Case Report

A 38-yr-old man was awaiting liver transplantation for the treatment of cirrhosis secondary to chronic hepatitis C virus infection. Spontaneous retroperitoneal and gastrointestinal hemorrhages had previously developed in the patient and he had received more than 50 units of packed red blood cells and fresh frozen plasma (FFP), in the medical intensive care unit over 5 days. Encephalopathy, shortness of breath and hypoxemia ensued, requiring tracheal intubation and mechanical ventilation. Serial

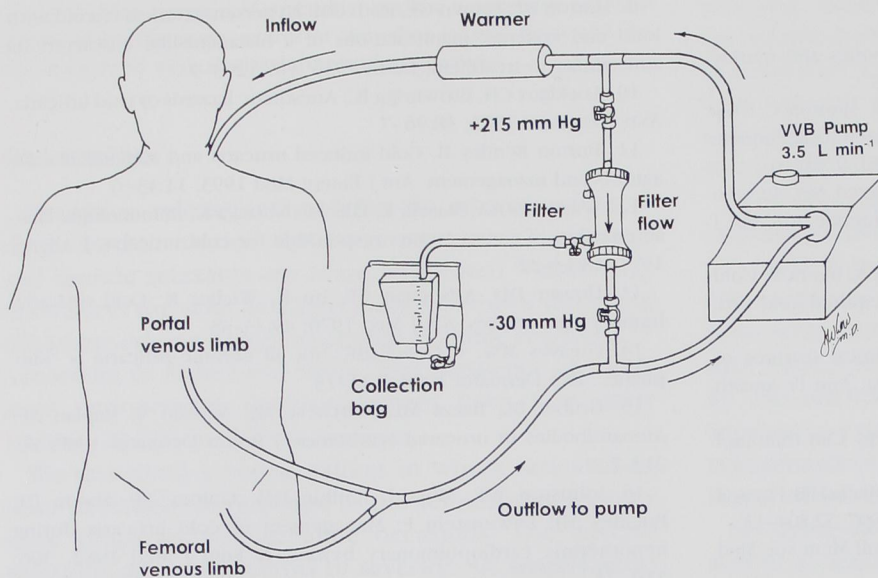


Fig. 1. The hemofilter in parallel to the liver transplant recipient on venovenous bypass (VVB). The pressure gradient across the filter in part governs the rate of hemofiltration. The rate of hemofiltration removal can also be altered by applying positive or negative pressure to the collection tubing. Pressures were electromechanically transduced from either side of the filter. The negative outflow pressure, was produced by the Bernoulli effect of the VVB flow. A pressure-flow nomogram for the filter indicates that the blood flow through the filter was approximately 400 ml/min.

chest radiography showed congestive heart failure with pulmonary edema. Oliguria developed and the patient's serum creatinine level increased from 1.3–3.1 over 2 days. He underwent dialysis *via* a double-lumen venous catheter placed in his right femoral vein. A donor liver was identified for him after 7 days.

Immediately preoperatively, the patient's arterial oxygen tension (P_{aO_2}) was 63 mmHg (intermittent mandatory ventilation (IMV) = 8; fractional inspired oxygen tension [FI_{O_2}] = 0.7; tidal volume (TV) = 800 ml; and positive end expiratory pressure (PEEP) = 5 cm H_2O). The patient exhibited gross ascites, anasarca, and a peak inspiratory pressure of 44 cm H_2O . He had produced only 80 ml of urine during the preceding 24 h, despite administration of 200 mg furosemide. The venovenous dialysis catheter was still in place in the right groin, but the hemofilter had been discarded. At arrival to the operating room, the patient was mechanically ventilated with an FI_{O_2} of 1.0 and the PEEP was increased to 10 mmHg. Oxygen saturation measure by pulse oximeter (Sp_{O_2}) increased from 93–95%, P_{aO_2} increased to 78 mmHg. Bumetanide, 5 mg, was administered intravenously. Immediate preoperative hemoglobin level was 7.8 gm/dl, platelet count was 35,000 μ l, prothrombin time/partial thromboplastin time (PT/PTT) was 18.0/36.8, and the international normalized ratio (INR) was 2.3. Fibrinogen was 151 mg/dl and fibrin degradation products were 27 μ g/ml. A pulmonary artery occlusion catheter was placed *via* his right internal jugular (IJ) vein. Central venous pressure (CVP) was 29 mmHg, pulmonary artery (PA) diastolic pressure was 27 mmHg, and the pulmonary artery occlusion pressure was 27 mmHg. A 16-French right internal jugular (IJ) venous catheter was then also placed percutaneously to provide for the VVB inflow. The right groin dialysis double-lumen venous catheter was dedicated to transfusion.

The patient required intravascular volume reduction to facilitate administration of blood component products. CAVH was considered, but placement of a large arterial catheter was deferred because of the history of coagulopathic bleeding. It was decided to institute hemoconcentration by a technique similar to that performed on heparinized cardiopulmonary bypass pumps.¹ The risk of thrombosis within the hemoconcentration filter was judged to be low in this hypo-coagulable patient. The filter (Renal Systems, Minneapolis, MN) was placed across the inflow and outflow limbs of the VVB pump, as shown in figure 1. At the start of surgery, partial VVB (femoral-jugular) was

instituted, and the hemofilter was placed to gravity drainage. Hemofiltrate (1400 ml) was removed in the first 20 min. The patient's central venous pressure decreased to 19 mmHg, despite the transfusion of 12 units platelets, 1 unit packed red blood cells and 2 units fresh frozen plasma. The hemofiltration drainage tubing was then partially clamped to decrease the rate of production to 40 ml/min. During this period, the abdominal incision was also made and 6,500 ml of ascitic fluid was acutely drained. These combined factors caused a decrease in venous pressures that permitted the administration of intravenous mannitol, 0.5 gm/kg. During the 2 h of VVB, a total of 4 l hemofiltrate and 1,200 ml urine were obtained from the patient. CVVH ended at discontinuation of VVB. The patient continued to produce approximately 400 ml/h urine. A total of 4 units PRBCs were transfused. The hemoglobin level at the end of the case was 9.2 gm/dl.

Discussion

Although this is technically CVVH, the rate of hemofiltration achievable across the VVB pump is closer to that associated with CAVH.

This hemofiltration entails some considerations and risk for the patient. When VVB is discontinued after liver transplantation, this technique must also end. In this case, there was no need for further hemofiltration after transplantation. Opioids and protein-unbound "middle molecules" are filtered in a fashion that may necessitate readministration.^{2,3} The filter's polysulfone fibers may be thrombogenic. In this case, no blood clotting was observed within the filter, despite the lack of exogenous anticoagulation. Some fibrinous material was visible on the filter fibers after flushing the system with saline. Bellomo *et al.*⁴ suggested periodic visual inspection of the filter and maintaining the patient's activated coagulation time (ACT) more than 150 s.

CASE REPORTS

A massive fibrinous clot would be visible through the filter's plastic surface, but smaller thrombi would probably pass unrecognized. Clotting within the filter represents one reason for diminished hemofiltrate output. Clotting can cause pulmonary embolism, or the acute loss of VVB.

Renal failure occurs in up to 75% of patients dying of cirrhosis.⁵ CAVH and CVVH have been shown to improve pulmonary and hemodynamic function during and after liver transplantation.^{4,6}

Intraoperative hemofiltration was used to help treat hypervolemia. Placement of the hemoconcentration filter across the VVB circuit in parallel to the patient provided transmembranal pressure gradients and hemofiltrate flow rates associated with CAVH without cannulation of the arterial circulation. There is also no need for venous cannulation beyond that required for VVB. The technique can effect a rapid decrease in intravascular volume and may be performed in selected patients without systemic anticoagulants.

References

1. Joffe D, Silvey G: The use of microfiltration in cardiopulmonary bypass. *J Cardiothorac Vasc Anesth* 1994; 8(6):685-92
2. Terada Y, Mitsui T, Mihara W, Tanaka M: Ventricular tachycardia after hemofiltration during cardiopulmonary bypass. *Ann Thorac Surg* 1997; 63(4):1215-6
3. Golper TA, Wedel SK, Kaplan AA, Saad AM, Donta ST, Paganini EP: Drug removal during continuous arteriovenous hemofiltration: Theory and clinical observations. *Int J Artif Organs* 1985; 8(6):307-12
4. Bellomo R, Harris C, Kang Y-G, Daniel E, Fung JJ, Bronsther O: Combined veno-venous bypass and high volume hemofiltration during orthotopic liver transplantation. *ASAIO J* 1993; 39(4):954-6
5. Epstein M: Renal sodium handling. *The Kidney in Liver Disease*, 3rd Edition. Edited by Epstein M. Baltimore, Williams & Wilkins Publishers, 1988, pp 238-55
6. Tuman KJ, Speiss BD, McCarthy RJ, Logas WG, Williams JW, Sankary HN: Effects of continuous arteriovenous hemofiltration on cardiopulmonary abnormalities during anesthesia for orthotopic liver transplantation. *Anesth Analg* 1988; 67:363-9

Anesthesiology
1999; 90:911-3

© 1999 American Society of Anesthesiologists, Inc.
Lippincott Williams & Wilkins, Inc.

Respiratory Compromise and Dramatic Chest X-ray Changes during General Anesthesia in a Patient with a Bronchogenic Cyst

Takeyoshi Sata, M.D.,* Yosuke Shiga, M.D.,† Ryoichi Nakanishi, M.D.,‡ Kosei Yasumoto, M.D.,§ Akio Shigematsu, M.D.||

BRONCHOGENIC cysts are rare congenital anomalies that may cause obstructive emphysema. We present the

case of an infant in whom acute respiratory distress was caused by a bronchogenic cyst. Dramatic changes in the chest radiograms, from hyperinflation of the left lung and atelectasis of the right lung to hyperinflation of the right and atelectasis of the left, were observed within a short period of time during general anesthesia. Surgical excision provided complete relief.

* Associate Professor, Department of Anesthesiology.

† Instructor, Department of Anesthesiology.

‡ Assistant Professor, Second Department of Surgery.

§ Professor, Second Department of Surgery.

|| Professor, Department of Anesthesiology.

Received from the University of Occupational and Environmental Health, Iseigaoka Yahata-Nishiku Kitakyushu, Japan. Submitted for publication June 18, 1998. Accepted for publication November 13, 1998. Support was provided solely from institutional and/or departmental sources.

Address reprint requests to Dr. Sata: Department of Anesthesiology, School of Medicine, University of Occupational and Environmental Health, Japan, 1-1 Iseigaoka Yahata-Nishiku Kitakyushu 807-8555, Japan.

Key words: Atelectasis; blood gases; deterioration; hyperinflation of the lung; positive pressure ventilation; ventilation.

Case Report

An 8-month-old, 8-kg boy was admitted to a nearby hospital with a 4-week history of a croupy cough, wheezing, and fever. He was the full-term product of an uncomplicated pregnancy and delivery. He had similar symptoms when he was 5 months old and was treated for asthma and pneumonia for 1 month. At admission, he was tachypneic (60-70 breaths/min) with marked inspiratory stridor unaffected by posture. There were faint breath sounds on the left side of the chest and slight wheezing was heard on the right side. Oxygen saturation measured by pulse oximetry (SpO₂) was 74% and did not respond to