

CORRESPONDENCE

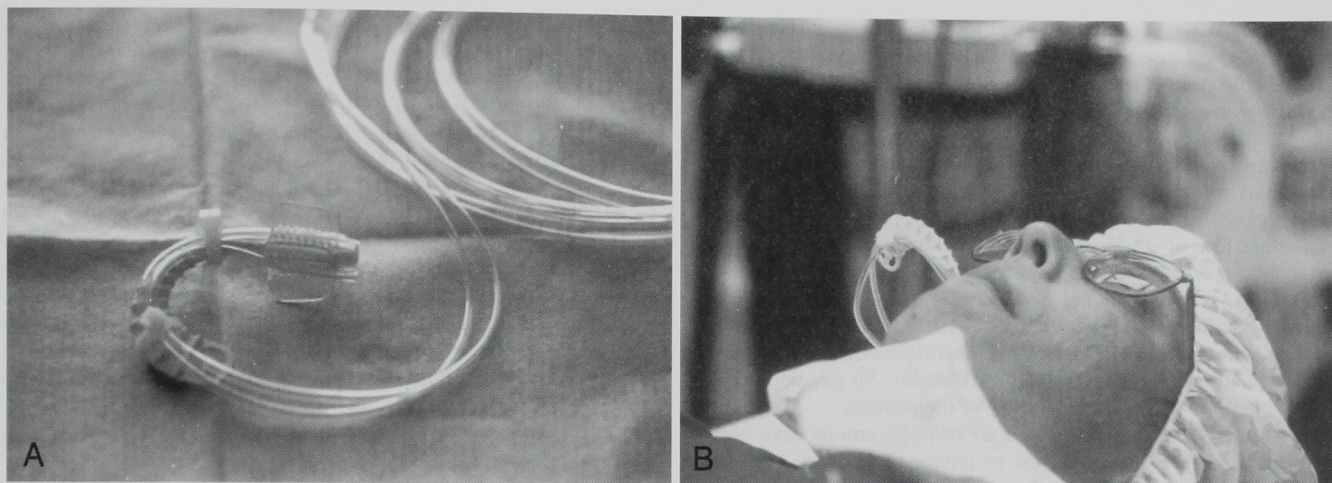


Fig. 1. (A) Modified BiteGard. (B) Modified Bitegard demonstration by the author.

lines are separated. The lines are then glued to the lateral grooves of the bite block (the nonbiting surface) with sterile medical adhesive. Special consideration must be taken to ensure proper placement of the ET_{CO_2} line because it is a suctioning sample line and may become occluded by adjacent tissue or saliva. The ET_{CO_2} line should be placed on the tongue side of the Bitegard because this line may become occluded if it is placed adjacent to the cheek. In addition, the ET_{CO_2} line should be secured at the most proximal portion of the bite block to ensure that saliva does not occlude the sample line. The oxygen and ET_{CO_2} lines are then fastened to the arm of the Bitegard with plastic chest-tube bands and secured with a chest-tube banding gun (fig. 1A). The modified Bitegard is placed directly into the patient's mouth with the plastic hook of the modified Bitegard turned to the patient's cheek side. Alternatively, the modified Bitegard may be turned on its side and placed in the patient's mouth with the plastic hook turned to the patient's chin. Mouth breathing should be encouraged once the modified Bitegard is in place.

We used this device on 10 patients scheduled for outpatient ophthalmic procedures, after approval of the protocol by the institutional review board of human experimentation. Six of the patients receiving the modified Bitegard observed having a dry mouth after their 30-min procedure and two patients stated that the device was tolerable but mildly uncomfortable. Three patients experienced no discomfort or dry mouth. ET_{CO_2} waveform was present in two

patients throughout their procedures without any occlusion. Five patients showed intermittent ET_{CO_2} waveform and therefore experienced periodic sample-line occlusion or nasal breathing. Three patients showed no ET_{CO_2} waveform. In every case, the modified Bitegard did not interfere with the surgical field, and the surgeons were satisfied with the oxygen technique. The oxygen saturation in all patients increased from the patient's baseline to 99% with an oxygen flow rate of 2 l/min. All patients tolerated the modified Bitegard without complication. In certain patients, the modified Bitegard may be an acceptable alternative to nasal cannula oxygen supplementation because it does not interfere with the surgical field during facial or ocular surgery. In addition, this device easily inserts into the patient's mouth (fig. 1B).

We have found the modified Bitegard to be easy to prepare, tolerable for the patient, and a simple alternative to nasal cannula oxygen supplementation and monitoring of ET_{CO_2} in patients undergoing monitored anesthesia care.

Andrea R. Williams, M.D.

Keith Tomlin, M.D.

Department of Anesthesia and Perioperative Medicine
Medical University of South Carolina
Charleston, South Carolina

(Accepted for publication August 27, 1998.)

Anesthesiology

1999; 90:339-40

© 1999 American Society of Anesthesiologists, Inc.

Lippincott Williams & Wilkins

Tuohy Needle and Loss of Resistance Technique: A Safer Approach for Thoracentesis

To the Editor:—One complication of thoracentesis is a pneumothorax.¹ This is a particular concern in patients being mechanically ventilated. In an effort to reduce this risk, we have recently been using Tuohy needles² for this procedure, rather than the standard short-bevel

needles included in our standard kits. We have now performed thoracentesis in eight mechanically ventilated patients, each receiving PEEP ranging from 5 to 10 cm of water. Surgical intensive care unit residents under the direct supervision of a single attending physician performed

thoracentesis. After skin cleansing and local anesthesia, an 18-gauge Tuohy needle was inserted with the bevel directed cephalad and was advanced until contact was established with the seventh rib. The stylet was withdrawn and a well-lubricated glass syringe with 2 ml of air was attached. The needle was then redirected and advanced above the rib margin until a distinct loss of resistance was encountered. Aspiration of pleural fluid confirmed the presence of the tip of the needle in the pleural space.

A distinct loss of resistance to air occurred in all eight patients. Pleural fluid was immediately aspirated through the needle in six patients. In two other patients, no fluid could be aspirated. In these patients a 20-gauge epidural catheter was passed through the Tuohy needle and advanced 25 cm posteriorly. In both patients we were then able to aspirate pleural fluid through the catheter. No pneumothorax or other complications occurred in any of the patients.

Complications and technical problems of thoracentesis have been quite well described.³ However, the technique of using an 18-gauge Tuohy needle and the ability to detect the loss of resistance during entry into the pleural space have not been described for the purpose of thoracentesis. The 18-gauge Tuohy needle has a blunt, curved tip that should decrease accidental dural/pleural puncture and facilitate the detection of the loss of resistance. The incidence of pneumothorax after thoracentesis with this technique is unknown. The reported incidence of pneumothorax for interpleural analgesia averages 2% when using the loss-of-resistance technique with a Tuohy needle, compared to 12% with the thoracentesis needle.^{3,4} We believe that the most common cause for unintentional lung puncture during thoracentesis is the occurrence of "dry tap," which may lead to further advancement or unnecessary manipulation of the needle in the pleural space, or both. In the technique described herein, the capability to easily insert the epidural catheter and aspirate pleural fluid adds to the safety of this procedure.

We believe that the Tuohy needle and the loss-of-resistance technique described herein is a safer approach for diagnostic/therapeutic thoracentesis than the short-bevel needles and traditional method.⁵

Arjang Khorasani, M.D.

Chairman

Division of Critical Care Anesthesiology

Department of Anesthesiology & Pain Management

Cook County Hospital

Chicago, Illinois

Assistant Professor

Department of Anesthesiology

Anesthesiology

1999; 90:340-1

© 1999 American Society of Anesthesiologists, Inc.

Lippincott Williams & Wilkins

Perioperative Extrapyramidal Reactions Associated with Ondansetron

To the Editor:—Ondansetron is a selective serotonin, 5-HT₃, receptor antagonist antiemetic and has been considered to have few extrapyramidal side effects. During the past several years, however, five cases of

dystonia¹⁻⁵ and two cases of psychiatric complications (*i.e.*, dysphoria-depression and a panic attack)^{6,7} were reported during ondansetron treatment of chemotherapy-induced emesis. We would like to describe

Rush-Presbyterian-St. Luke's Medical Center
Chicago, Illinois

arjangk@SPHK.com

Samuel K. Appavu, M.D.

Chairman

Division of Surgical Critical Care

Cook County Hospital

Chicago, Illinois

Assistant Professor

Department of Surgery

University of Illinois College of Medicine at Chicago

Chicago, Illinois

Antoun M. Nader, M.D.

Fellow in Pain Management

Department of Anesthesiology & Pain Management

Cook County Hospital

Chicago, Illinois

Simin Saatee, M.D.

Attending Anesthesiologist

Department of Anesthesiology & Pain Management

Cook County Hospital

Chicago, Illinois

Assistant Professor

Department of Anesthesiology

Rush-Presbyterian-St. Luke's Medical Center

Chicago, Illinois

References

1. Despars JA, Sassoon CS, Light RW: Significance of iatrogenic pneumothoraces. *Chest* 1994; 105:1147-50
2. Tuohy EB: Continuous spinal anesthesia: A new method utilizing a ureteral catheter. *Surg Clin North Am* 1945; 25:834-40
3. Collins TR, Sahn SA: Thoracentesis: Clinical value, complications, technical problems, and patient experiences. *Chest* 1987; 91:817-22
4. Mulroy MF: Peripheral nerve blockage. *Clinical anesthesia*. Edited by Barash PG, Cullen BF, Stoelting RK. Philadelphia, JB Lippincott, 1997; 669-97
5. Sokolowski JW, Burgher LW, Jones FL, Patterson JR, Selecky PA. Guidelines for thoracentesis and needle biopsy of the pleura. *Am Rev Respir Dis* 1989; 140:257-8

(Accepted for publication August 31, 1998.)