

Anesthesiology
1999; 90:302-4
© 1999 American Society of Anesthesiologists, Inc.
Lippincott Williams & Wilkins

Dual Capnography Facilitates Detection of a Critical Perfusion Defect in an Individual Lung

K. Bhavani Shankar, M.D.,* Roger Russell, M.D.,† Lishon Aklog, M.D.,* Phillip S. Mushlin, M.D., Ph.D.,‡

THE commonly used method for monitoring end-tidal carbon dioxide tension (P_{ETCO_2}) during two-lung ventilation *via* a double-lumen endotracheal tube (DLT) involves sampling of mixed expired gases of both lungs. This approach may not always help to localize a pathophysiologic defect in an individual lung. Dual capnography circumvents this limitation by allowing carbon dioxide P_{ETCO_2} to be continuously monitored from each lumen of DLT during two-lung ventilation.^{1,2} The current report describes a situation wherein dual capnography helped us to detect a critical perfusion defect in the putatively normal left lung of a patient scheduled for right pneumonectomy.

Case Report

A 71-yr-old, 80-kg man with a mesothelioma of the right lung was scheduled to undergo elective right extrapleural pneumonectomy. A ventilation/perfusion (V/Q) scan performed 10 days before surgery showed a normal left lung and a reduced, but matched, perfusion and ventilation defect in the right lung (% of total pulmonary activity: left lung V = 93%; Q = 88%; right lung V = 7%; Q = 12%). Two days before surgery, the patient was admitted to the hospital because of progressive dyspnea. Chest radiography showed complete opacification of the right hemithorax and a leftward shift of the mediastinum. Arterial blood gases with the patient breathing room air showed arte-

rial oxygen tension (P_{aO_2}) = 71 mmHg, pH = 7.46, P_{aCO_2} = 41 mmHg. Hematocrit concentration was 24% (*versus* 37% three days earlier). A right-sided hemothorax was suspected and was presumed to have resulted from tumor necrosis and bleeding. The surgeons opted to perform an urgent right-side thoracotomy and pneumonectomy. Oxygen saturation (Sp_{O_2}) at arrival in the operating room ranged from 93-96% while breathing oxygen 8 l/min *via* face mask. General anesthesia was induced with etomidate, followed by succinylcholine, and maintained with isoflurane. A single-lumen endotracheal tube was placed to facilitate fiberoptic bronchoscopy (FOB) and then replaced with a Rusch 39 left-sided DLT (Willy Rusch AG, Kernan, Germany).

The patient was placed in the left lateral position and proper DLT position was verified *via* FOB. The patient was ventilated with a tidal volume of 800 ml and a respiratory rate of 10 breaths/min (fractional inspired oxygen tension [$F_{I_{O_2}}$] = 100%). P_{ETCO_2} was 28 mmHg.

As left-lung ventilation was initiated in preparation for the operative procedure, Sp_{O_2} decreased to 82%. Bilateral ventilation was resumed, and Sp_{O_2} increased to 98%. The FOB showed the DLT to be in proper position. With reinitiation of left-lung ventilation, Sp_{O_2} again decreased. Five centimeters of water continuous positive airway pressure applied to the upper lung increased Sp_{O_2} to approximately 90%. The P_{ETCO_2} during left-lung ventilation was 22 mmHg. After 7 min of left-lung ventilation, P_{aO_2} = 68 mmHg, pH = 7.25, and P_{aCO_2} = 68 mmHg. Three minutes after returning to two-lung ventilation, P_{ETCO_2} was 28 mmHg, P_{aO_2} was 236 mmHg, pH was 7.26, and P_{aCO_2} was 65 mmHg.

The persistence of the large P_{aCO_2} - P_{ETCO_2} gradient and hypoxemia encountered during left-lung ventilation prompted us to estimate the alveolar dead space of each lung. Because the patient was unable to tolerate left-lung ventilation, we used a dual-capnography setup (see fig. 1) to measure P_{ETCO_2} values from the individual lungs without interrupting two-lung ventilation. P_{ETCO_2} of the right lung (47 mmHg) was unexpectedly higher than that of the left lung (22 mmHg). The capnograms of individual lungs were normal in shape and differed only in height of the alveolar plateau (phase III). The P_{aCO_2} - P_{ETCO_2} gradient was more than two-fold greater in the left than in the right lung (43 *versus* 18 mmHg; table 1). The surgeons drained the right-side hemothorax (2.5 l blood), but the P_{ETCO_2} and P_{aCO_2} - P_{ETCO_2} values of each lung remained unchanged, and hypoxemia again occurred during left-lung ventilation. Therefore, the operation was limited to right-side pleurectomy.

The patient was transferred to the intensive care unit with a single-lumen endotracheal tube in place. Respiratory acidosis persisted, the patient progressively became hypoxemic (P_{aO_2} = 62 mmHg, pH = 7.27, P_{aCO_2} = 60 mmHg, $F_{I_{O_2}}$ = 100%, minute ventilation = 9 l/min), and pharmacologic therapy was required for hypotension. A transthoracic echocardiogram showed an echogenic density in the left pulmonary artery (PA). Pulmonary angiography confirmed the presence of a

* Instructor, Department of Anesthesia.

† Instructor, Department of Anesthesia.

‡ Clinical Fellow, Department of Thoracic Surgery.

‡ Associate Professor, Department of Anesthesia.

Received from the Departments of Anesthesia and Thoracic Surgery, Brigham and Women's Hospital, Harvard Medical School, Boston, Massachusetts. Submitted for publication January 21, 1998. Accepted for publication August 6, 1998.

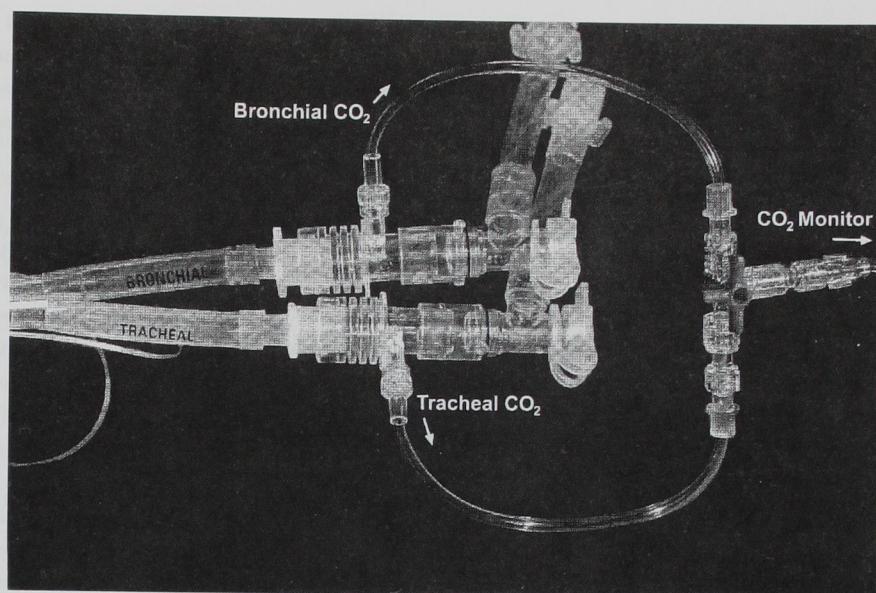
Address reprint requests to Dr. Shankar: Department of Anesthesia, Brigham and Women's Hospital, Harvard Medical School, 75 Francis Street, Boston, Massachusetts 02115. Address electronic mail to: bskodali@bics.bwh.harvard.edu

Key words: Carbon dioxide monitoring; double-lumen endotracheal tubes; pulmonary embolism.

Downloaded from http://ajphaphysiology.physiology.org/ at National Institute of Health on April 18, 2014

CASE REPORTS

Fig. 1. The setup used for dual capnography has a three-way stopcock, with connections to the two carbon dioxide sampling adapters that are interposed between each lumen and its corresponding limb on the Y double-lumen tube adapter. This allows direction into the capnograph of the expired gases of either individual lung, or of the two lungs simultaneously.



large thrombus in the left PA with subtotal occlusions of multiple vessels in the left upper lobe and lingula. The interventional radiologists removed the large clots *via* aspiration, which resulted in an immediate increase in oxygen saturation and improved hemodynamic stability. A venacaval filter was inserted into the infrarenal portion of inferior vena cava. During the next 24 h, the respiratory acidosis resolved and hemodynamic support was withdrawn.

We reevaluated the Pa_{CO_2} - PET_{CO_2} gradient of the left lung. Sequential PET_{CO_2} samples were obtained from each lung *via* the suction port of an adult fiberoptic bronchoscope placed approximately 1 cm from the origin of each upper-lobe bronchus. The Pa_{CO_2} - PET_{CO_2} gradient was 5 mmHg in the left lung and 10 mmHg in the right lung (table 1). The patient made an uneventful recovery after embolectomy and was discharged home 2 weeks later.

Discussion

Dual capnography allows carbon dioxide waveforms to be obtained from individual lungs without interrupt-

Table 1. Pa_{CO_2} , PET_{CO_2} , and $\text{Pa}_{\text{CO}_2} - \text{PET}_{\text{CO}_2}$ of the Left and the Right Lung and Both Lungs Together during Two Lung Ventilation in the Intraoperative (Preembolectomy) and the Postoperative (Postembolectomy) Periods

	Intraoperative/ Preembolectomy ($\text{Pa}_{\text{CO}_2} = 65$ mmHg)		Postoperative/ Postembolectomy ($\text{Pa}_{\text{CO}_2} = 32$ mmHg)	
	PET_{CO_2} (mmHg)	$\text{Pa}_{\text{CO}_2} - \text{PET}_{\text{CO}_2}$ (mmHg)	PET_{CO_2} (mmHg)	$\text{Pa}_{\text{CO}_2} - \text{PET}_{\text{CO}_2}$ (mmHg)
Two lung ventilation	28	37	26	6
Left lung ventilation	22	43	27	5
Right lung ventilation	47	18	22	10

ing two-lung ventilation.^{1,2} It has been suggested that such capnographic data can be used to confirm correct DLT placement and to detect malposition, unilateral obstruction, or accidental displacement of a DLT.¹ Our case report suggests that dual capnography may also be useful for the rapid estimation of alveolar dead-space ventilation of an individual lung in situations in which ventilation or oxygenation is impaired.

The differential diagnosis of a large Pa_{CO_2} - PET_{CO_2} gradient (37 mmHg) during two-lung ventilation includes obstructive airway diseases and disorders associated with major reductions of pulmonary blood flow, such as low cardiac output states (hypovolemia, pericardial effusion, tumor-related obstruction of venous return), pulmonary vascular compression (tumor, large hemothorax), and thromboembolism of pulmonary arteries.³ We excluded the former cause, because our patient did not have clinical or capnographic evidence of airway obstruction.³ We also excluded low cardiac output as a cause of pulmonary hypoperfusion because a low-output state would have produced bilateral pulmonary hypoperfusion accompanied by similar increases in the Pa_{CO_2} - PET_{CO_2} gradients of the two lungs. Because hypoxemia during one-lung ventilation is not an infrequent occurrence,⁴⁻⁹ our conclusion that a major impairment of perfusion to the left lung existed was based primarily on the marked unilateral differences in carbon dioxide gradients (left > right). It was initially unclear, however, whether the impairment was caused by extrinsic compression (tumor) or internal obstruction (thromboembolism) of the left pulmonary artery. In either case, an

intraoperative transesophageal echocardiography could have helped to make the definitive diagnosis.

As with dual capnography, the standard method of P_{ETCO_2} sampling *via* a DLT (capnograms of individual lung obtained *via* interruption of ventilation to contralateral lung) can also reveal the type of problem encountered in our patient. However, dual capnography was our preferred approach, because it allows one to assess the V/Q status of each lung in individuals who cannot tolerate one-lung ventilation long enough to reach a new steady state. Also, the critical perfusion defect in our patient could have been diagnosed on the basis of the low P_{ETCO_2} of the left lung compared to that of the right, without measurement of P_{aCO_2} . By computing the $P_{aCO_2} - P_{ETCO_2}$ gradient, however, we were able to obtain a more direct estimation of the alveolar dead space of each lung.

In the absence of a DLT, we used an FOB to obtain P_{ETCO_2} samples from each lung. Our technique allowed us to detect a rapid decrease in the alveolar dead-space ventilation of the left lung after aspiration of large thromboemboli from the left PA. We acknowledge that there are no published comparisons of our approach and standard dual capnographic techniques. Nonetheless, this method, at least theoretically, may be useful to determine the P_{ETCO_2} of expired gases from each lung. It is possible that bronchial sampling *via* FOB from one lung could be contaminated with expired gases from the contralateral lung, particularly when expired flow rate

decreases to less than 150 ml/min (sampling flow rate of capnograph). Such contamination, however, seems unlikely in our case because the capnograms from each lung had normal shapes and differing heights of the alveolar plateau.

In conclusion, dual capnography helped to detect pulmonary emboli and to assess the efficacy of embolectomy therapy. Based on our findings, we suggest that dual capnography may be useful in the evaluation of ventilation or perfusion abnormalities associated with a variety of pulmonary diseases.

References

1. Shafieha MJ, Sit J, Kartha R, Sabnis L, Hajianpour B, Pappas AL, Yu E, Elam J, Balagot RC: End-tidal CO_2 analyzers in proper positioning of the double-lumen tubes. *ANESTHESIOLOGY* 1986; 64:844-5
2. Shankar KB, Moseley H, Kumar AY: Dual end-tidal CO_2 monitoring and double-lumen tubes. *Can J Anaesth* 1992; 39:100-1
3. Bhavani Shankar KB, Moseley H, Kumar AY, Delph Y: Capnometry and anaesthesia. *Can J Anaesth* 1992; 39:6:617-32
4. Capan LM, Turndorf H, Patel C, Ramanathan S, Acinapura A, Chalon J: Optimization of arterial oxygenation during one-lung anaesthesia. *Anesth Analg* 1980; 59:847-51
5. Khanam T, Branthwaite MA: Arterial oxygenation during one-lung anaesthesia. II. *Anaesthesia* 1973; 28:280-90
6. Khanam T, Branthwaite MA: Arterial oxygenation during one-lung anaesthesia. I. A study in man. *Anaesthesia* 1973; 28:132-8
7. Shimizu T, Abe K, Kinouchi K, Yoshiya I: Arterial oxygenation during one lung ventilation. *Can J Anaesth* 1997; 44:1162-6