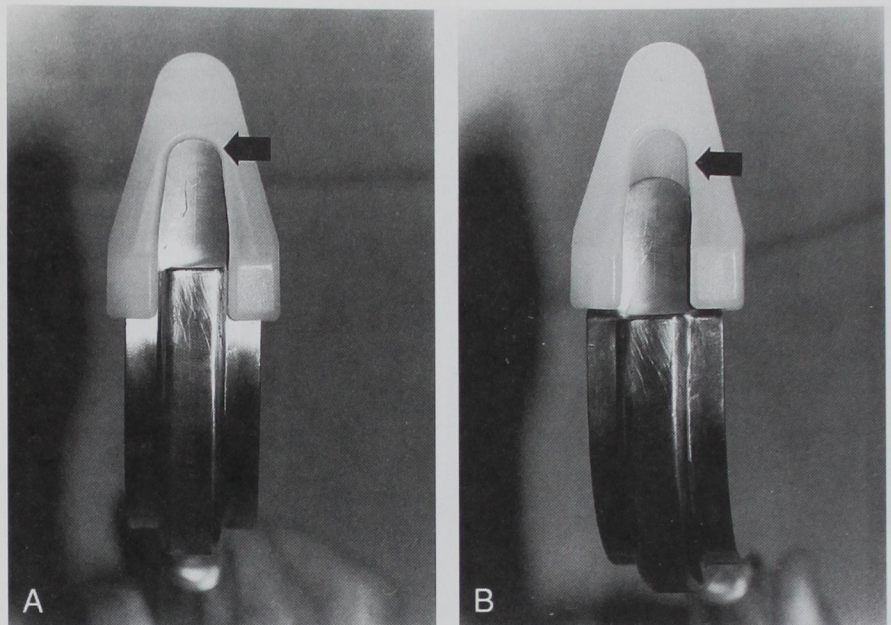


## CORRESPONDENCE

**Fig. 1. (A) Bullard laryngoscope with blade extender in proper position. (B) Bullard laryngoscope with blade extender in improper position.**



This report emphasizes the importance of proper training for safe use of the Bullard laryngoscope and the need for vigilance when using the blade-extender.

**Kenneth A. Marshall, M.D.**  
Senior Consultant  
Department of Anesthesiology

**Christopher F. James, M.D.**  
Senior Associate Consultant  
Department of Anesthesiology  
Mayo Clinic Jacksonville  
Jacksonville, Florida  
marshall.kenneth@mayo.edu

(Accepted for publication July 13, 1998.)

Anesthesiology  
1998; 89:1605-6  
© 1998 American Society of Anesthesiologists, Inc.  
Lippincott Williams & Wilkins

## High-concentration Cisatracurium in Intensive Care Unit Solution

**To the Editor:**—Nimbex™ (cisatracurium) is provided in 5-ml, 10-ml, and 20-ml vials. The 20-ml vial, intended for use in the intensive care unit (ICU) only, contains 10 mg/ml cisatracurium. The 20-ml vial has a similar appearance to the 10-ml operating room (OR) solution, differing in one color and having a notation on the bottom of the box as ICU use only (fig. 1). Recently, this ICU solution was placed by mistake in the OR anesthesia medication refrigerator.

It was used for anesthesia during bilateral urethral implantation in a 38-yr-old patient. This patient was a very muscular 78 kg, with medical history of hypertension and mild renal insufficiency. He was given 100 mg of cisatracurium rather than the intended 20 mg for intubation, without any hemodynamic change. Additional repeat doses of 10 mg (1 ml), 10 mg (1 ml), 10 mg (1 ml), 5 mg (0.5 ml) was given at about 65 min, 2 h, 4 h, and 5 h after the initial dose

with the beginning of the recovery of first twitch out of four. A total of 135 mg cisatracurium was administered during a 5.5-h operation. At the end of the procedure, after the recovery of four out of four twitches, intravenous glycopyrrolate, 0.4 mg, and neostigmine, 2 mg, was given, and the patient was extubated without any residual neuromuscular block symptoms.

We cannot explain why this patient recovered twitch "normally" despite a fivefold overdose. This mistake was discovered only after finishing the case. Only one vial was opened during this case, and it was found to be an ICU vial, 20 ml volume and 10 mg/ml concentration.

All anesthesia personnel were notified of the existence of the ICU solution, and the ICU solution was segregated from the OR solution immediately.



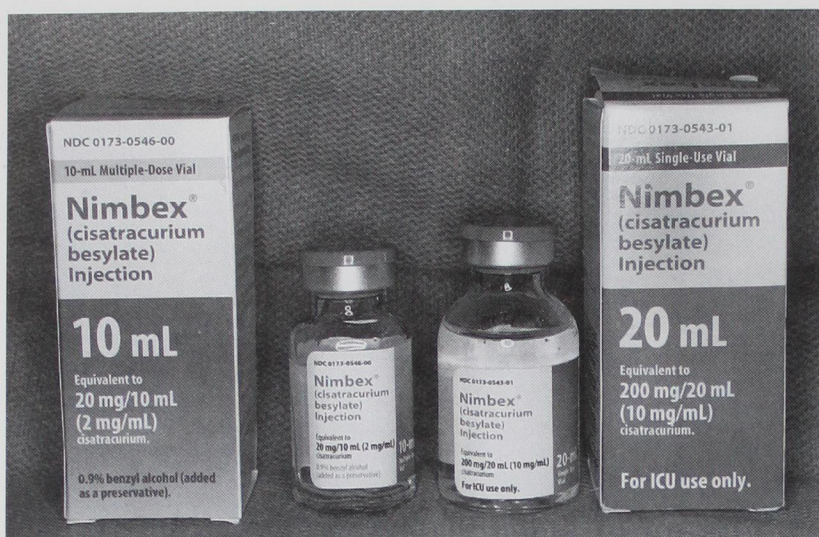

Fig. 1. Cisatracurium OR solution and ICU solution.

**Masako Nishio, M.D.**

Resident

**Chang-Shik Choi, M.D.**

Assistant Professor

**Clifford M. Gevirtz, M.D.**

Associate Professor

Department of Anesthesiology

New York Medical College

Metropolitan Hospital Center

New York, New York

masakonishio@sprintmail.com

## Reference

1. Lepage JY, Malinovsky JM, Malinge M, Lechevalier T, Depuch C, Cozian A, Pinaud M, Souron R: Pharmacodynamic dose-response and safety study of cisatracurium in adult surgical patients during NO-O<sub>2</sub>-opioid anesthesia. *Anesth Analg* 1996; 83(4):823-9

(Accepted for publication July 14, 1998.)

Anesthesiology  
1998; 89:1606-7

© 1998 American Society of Anesthesiologists, Inc.  
Lippincott Williams & Wilkins

## Bowing of the Needle Technique for Nerve Blocks

*To the Editor:*—We have discovered a simple technique for guiding 20- to 22-gauge needles in soft tissue under fluoroscopy. This technique has proven helpful for placing the tip of the needle at the anterolateral aspect of vertebral bodies when performing lumbar sympathetic and celiac plexus blocks. Such blocks are challenging, even under fluoroscopic guidance because the target lies 5–7 inches beneath the skin, making the initial trajectory of the needle critical.

Bowing of the needle allows the tip of the needle to be “walked” into the proper location quickly with minimal trauma to tissues. For

example, if the initial trajectory of the needle during a lumbar sympathetic block is too medial, causing the needle to make contact with the lamina of the vertebral body, the tip of the needle can be easily relocated more laterally. This can be accomplished by withdrawing the needle about 1 inch. Then, as shown in figure 1, a horizontal force (parallel to the surface of the skin) is applied to the shaft of the needle in the medial direction at the surface of the skin. While maintaining this horizontal force on the shaft of the needle, the needle is advanced 1 inch back to its original depth in the tissue. Fluoroscopy confirms that the needle has a slight bow and that the tip of the needle has been moved laterally. This process is repeated until the needle is advanced to the anterolateral aspect of the vertebral body (fig. 2).

Similarly, if the initial trajectory of the needle places the tip of the needle too laterally, cephalically, or caudally to the target region, a horizontal force applied to the shaft of the needle at the surface of the skin, in a direction opposite to the desired direction of the tip of the needle, will result in the displacement of the tip of the needle

Additional material related to this article can be found on the ANESTHESIOLOGY Web Site. Go to the following address, and then scroll down to find the title link for this article.  
<http://www.anesthesiology.org/tocs/v89n6-TOC.cfm>