

CORRESPONDENCE

anesthetic within the subarachnoid space may be associated with this neurologic symptom. Our results indicate that a subsequent injection at the same interspace after a failed spinal anesthesia has the risk of neurologic injury. A subsequent injection should be attempted at a higher interspace to avoid reinforcing the same restricted distribution.² In addition, a combined dose that exceeds the standard recommendation for single-injection spinal anesthesia still has risk of injury, even if a different interspace is used, and hence other modifications, such as altering patient position, using an anesthetic with a different baricity, or straightening the lumbosacral curvature, should be considered.¹

Yoshihiro Hirabayashi, M.D.
Lecturer
yhira@jichi.ac.jp
Ruriko Konishi, M.D.
Instructor

Reiju Shimizu, M.D.
Professor
Department of Anesthesiology
Jichi Medical School
Tochigi, Japan

References

1. Drasner K, Rigler ML: Repeat injection after a "failed spinal." At times, potentially unsafe practice. *ANESTHESIOLOGY* 1991; 75:713-4
2. Abouleish E. How to proceed following a "failed spinal." *ANESTHESIOLOGY* 1992;76:476

(Accepted for publication June 11, 1998.)

Anesthesiology
1998; 89:1295
© 1998 American Society of Anesthesiologists, Inc.
Lippincott Williams & Wilkins

Laryngeal Mask Airway Fitted over a Tracheotomy Orifice: A Mean to Ventilate a Tracheotomized Patient during Induction of Anesthesia

To the Editor:—It is occasionally difficult to ventilate a tracheotomized patient. In such a patient, controlled ventilation through a face mask is difficult. Some patients can easily tolerate topical anesthesia and awake insertion of an endotracheal tube through a tracheotomy orifice, followed by the anesthesia. However, for those who cannot, deep anesthesia and muscle relaxation before tube placement may be preferable.

In such a situation, ventilation using a small laryngeal mask fitted over a stoma has proven to be a reasonable solution (fig. 1). With this method, we can easily ventilate a patient and control the depth of anesthesia.

Ventilation *via* a tracheostomy using a pediatric mask over the stoma has been reported previously.¹ Unfortunately, in some cases, it is difficult to fit a pediatric mask because of a hollow between clavicles, the sternum, and sternocleidomastoid muscles. In such cases, the use of a small laryngeal mask airway may be of value.

Yasuhiro Morita, M.D.
Resident
Makoto Takenoshita, M.D.
Assistant Professor
Department of Anesthesiology
Osaka University Medical School
Osaka, Japan
makoto@anes.med.osaka-u.ac.jp

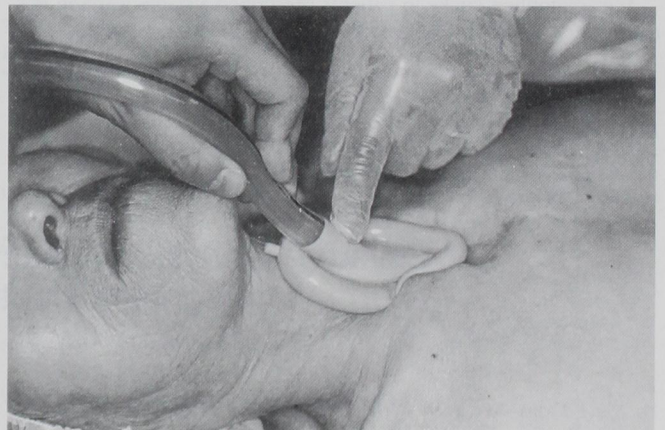


Fig. 1. Laryngeal mask fitted over a tracheotomy orifice.

Reference

1. Raymond J, Hardy JF: Oxygénation par trachéostomie. *Can J Anaesth* 1990; 37:274-5

(Accepted for publication June 11, 1998.)