

## References

1. Fink BR: The etiology and treatment of laryngeal spasm. *ANESTHESIOLOGY* 1956; 17:569-77
2. McGoldrick KE: Otorhinolaryngologic surgery, Ambulatory Anesthesiology, A Problem-Oriented Approach. Edited By McGoldrick KE. Baltimore, Williams & Wilkins, 1995, pp 459-506
3. McGee JP, Vender JS: Nonintubation management of the airway, Clinical Procedures in Anesthesia and Intensive Care. Edited by Benumof JL. Philadelphia, JB Lippincott, 1992, pp 89-114
4. Morgan GE, Mikhail MS: Clinical Anesthesiology. 2nd edition. Stamford, Appleton & Lange, 1996, p 68
5. Stehling LC: Management of the airway, Clinical Anesthesia. 2nd edition. Edited by Barash PG, Cullen BF, Stoelting RK. Philadelphia, Lippincott-Raven, 1992, pp 693-4
6. Brett CM, Zwass MS, France NK: Eyes, ears, nose, throat and

dental surgery, Pediatric Anesthesia. 3rd edition. Edited by Gregory GA. New York, Churchill Livingstone, 1994, pp 657-97

7. Finucane BT, Santora AH: Complications of endotracheal intubation, Principles of Airway Management. 2nd edition. St Louis, Mosby, 1996, pp 227-50
8. Gwartz KH: Management of recovery room complications, Anesthesiology Clinics of North America. Edited by Dierdorf SF. Philadelphia, WB Saunders Company, 1996, pp 307-39
9. Mark LC: Treatment of laryngospasm by digital elevation of tongue. *ANESTHESIOLOGY* 1963; 24:585
10. Larsell O: The nervous system, Morris' Human Anatomy. 11th edition. Edited by Schaeffer JP. New York, The Blakiston Company, 1953, pp 1107-10

(Accepted for publication June 11, 1998.)

Anesthesiology  
1998; 89:1294-5

© 1998 American Society of Anesthesiologists, Inc.  
Lippincott Williams & Wilkins

## Neurologic Symptom Associated with a Repeated Injection after Failed Spinal Anesthesia

*To the Editor:*—A repeated single-injection spinal anesthetic after failed spinal anesthesia has been proposed to be potentially harmful.<sup>1</sup> We present a patient in whom neurologic symptoms developed associated with repeated single injection after failed spinal anesthesia. In this patient, dibucaine was repeatedly injected into the subarachnoid space. Although this is an agent virtually never used in the United States, the clinical course of the patient may provide important issues from a theoretical point of view when clinicians deal with failed spinal anesthesia. A 33-yr-old woman with no medical history was scheduled to undergo conization. The patient was placed in the right lateral position on a horizontal operating table. A 25-gauge Quincke needle was introduced into the subarachnoid space at the L<sub>3</sub>-L<sub>4</sub> interspace on the first attempt, and clear cerebrospinal fluid (CSF) flowed freely. Hyperbaric dibucaine, 7.5 mg, was injected, commercially prepared as Percamin S (Teikoku Kagaku, Tokyo, Japan; 0.3% dibucaine in 5% sodium chloride solution, specific gravity 1.037). Clear CSF was aspirated immediately before and after the injection. There were no signs of pain or paresthesia during insertion of the needle or during injection. The patient then was turned to the supine position on a horizontal operating table. Because she could flex fully both knees and feet 15 min after the spinal injection, we decided to repeat the lumbar puncture. At this time, we failed to test for a block by an evaluation of the sacral dermatomes. The second dural puncture was performed on the first attempt with a 25-gauge Quincke needle at the L<sub>3</sub>-L<sub>4</sub> interspace, with the patient in the right lateral position on a horizontal operating table. The CSF that flowed out of the needle still was clear. Six milligrams of the same anesthetic was injected into the subarachnoid space. Clear CSF was aspirated immediately before and after the injection. Neither pain nor paresthesia was elicited during placement of the needle or drug injection. The

patient was turned to the supine position on a horizontal operating table, and sensory analgesia to pin-prick was reached at S<sub>1</sub> 10 min after the subsequent spinal injection. After the patient was placed in the lithotomy position, the gynecologic procedure was uneventful and lasted 25 min. When the operation was terminated, a pin-prick test revealed the sensory analgesia to be L<sub>1</sub>, and a Foley urinary catheter was inserted into the bladder. On the morning of the first postoperative day, the patient first noted the loss of sensation in the buttocks and was unable to void. A urinary catheter was used before noon. At this time, the patient started to complain of numbness in bilateral S<sub>2</sub>-S<sub>3</sub> dermatomes. She needed an indwelling urinary catheter until the seventh postoperative day, and thereafter she could urinate in an interrupted stream with the help of considerable straining. There was no bowel dysfunction or motor weakness. Magnetic resonance imaging performed at the twentieth postoperative day showed no abnormality in the lumbosacral spine. Urinary difficulties completely resolved within 4 weeks. The numbness in the buttocks gradually subsided but continued for 6 weeks.

The neurologic symptom observed in this patient may not be associated with trauma because there were no signs of pain or paresthesia during insertion of the needle or during injection. Clear CSF was aspirated before and after the injection, both in the initial and the subsequent punctures. Consequently, the combined dose of hyperbaric local anesthetic most likely was delivered into the subarachnoid space. In the current patient, the total dose of dibucaine from the two injections exceeded that recommended for single-injection spinal anesthesia. In addition, we repeated lumbar puncture at the L<sub>3</sub>-L<sub>4</sub> interspace at which the initial puncture was performed. The restricted sacral distribution indicates that the combined dose was not diluted by CSF, resulting in the regional concentration to be neurotoxic. Maldistribution of hyperbaric local



## CORRESPONDENCE

anesthetic within the subarachnoid space may be associated with this neurologic symptom. Our results indicate that a subsequent injection at the same interspace after a failed spinal anesthesia has the risk of neurologic injury. A subsequent injection should be attempted at a higher interspace to avoid reinforcing the same restricted distribution.<sup>2</sup> In addition, a combined dose that exceeds the standard recommendation for single-injection spinal anesthesia still has risk of injury, even if a different interspace is used, and hence other modifications, such as altering patient position, using an anesthetic with a different baricity, or straightening the lumbosacral curvature, should be considered.<sup>1</sup>

**Yoshihiro Hirabayashi, M.D.**  
Lecturer  
yhira@jichi.ac.jp  
**Ruriko Konishi, M.D.**  
Instructor

**Reiju Shimizu, M.D.**  
Professor  
Department of Anesthesiology  
Jichi Medical School  
Tochigi, Japan

## References

1. Drasner K, Rigler ML: Repeat injection after a "failed spinal:" At times, potentially unsafe practice. *ANESTHESIOLOGY* 1991; 75:713-4
2. Abouleish E. How to proceed following a "failed spinal." *ANESTHESIOLOGY* 1992;76:476

(Accepted for publication June 11, 1998.)

Anesthesiology  
1998; 89:1295

© 1998 American Society of Anesthesiologists, Inc.  
Lippincott Williams & Wilkins

## Laryngeal Mask Airway Fitted over a Tracheotomy Orifice: A Mean to Ventilate a Tracheotomized Patient during Induction of Anesthesia

*To the Editor:*—It is occasionally difficult to ventilate a tracheotomized patient. In such a patient, controlled ventilation through a face mask is difficult. Some patients can easily tolerate topical anesthesia and awake insertion of an endotracheal tube through a tracheotomy orifice, followed by the anesthesia. However, for those who cannot, deep anesthesia and muscle relaxation before tube placement may be preferable.

In such a situation, ventilation using a small laryngeal mask fitted over a stoma has proven to be a reasonable solution (fig. 1). With this method, we can easily ventilate a patient and control the depth of anesthesia.

Ventilation *via* a tracheostomy using a pediatric mask over the stoma has been reported previously.<sup>1</sup> Unfortunately, in some cases, it is difficult to fit a pediatric mask because of a hollow between clavicles, the sternum, and sternocleidomastoid muscles. In such cases, the use of a small laryngeal mask airway may be of value.

**Yasuhiro Morita, M.D.**  
Resident  
**Makoto Takenoshita, M.D.**  
Assistant Professor  
Department of Anesthesiology  
Osaka University Medical School  
Osaka, Japan  
makoto@anes.med.osaka-u.ac.jp

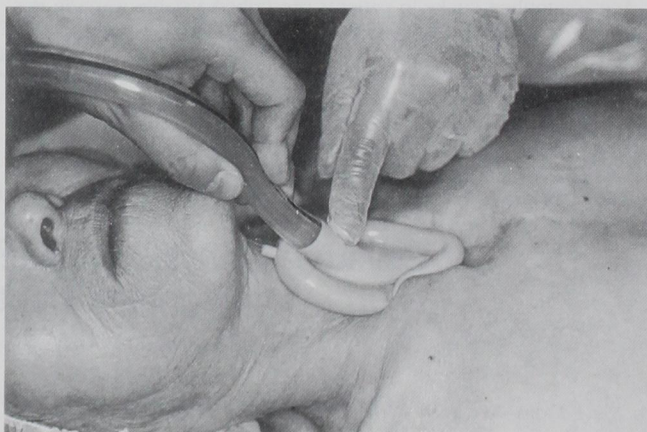


Fig. 1. Laryngeal mask fitted over a tracheotomy orifice.

## Reference

1. Raymond J, Hardy JF: Oxygénation par trachéostomie. *Can J Anaesth* 1990; 37:274-5

(Accepted for publication June 11, 1998.)