

CORRESPONDENCE

nioplasty) and the supine position of the patient. Although we agree that the incidence of pulmonary embolism during cranioplasty with methylmethacrylate should be very low, as compared to cemented total hip replacement, its occurrence cannot be excluded. Furthermore, pulmonary embolism has been reported in the supine position, although its incidence is lower than in the sitting position.⁸ It may occur as long as a negative gradient as small as 5 cm exists between the surgical site and the heart.

Fourth, the rapid resolution of bronchospasm in this patient could be attributed to the size of the emboli and the timely administration of therapeutic maneuvers.

Finally, had air been the cause of pulmonary embolism, the use of mass spectrometry would have indicated the presence of end-tidal nitrogen.

**Usharani Nimmagadda, M.D.
M. Ramez Salem, M.D.**

Department of Anesthesiology
Illinois Masonic Medical Center
Chicago, Illinois
ninosj@aol.com

References

1. Wong HY, Vidovich MI: Acute bronchospasm associated with polymethylmethacrylate cement. *ANESTHESIOLOGY* 1997; 87:696-8

Anesthesiology

1998; 89:1291-2

© 1998 American Society of Anesthesiologists, Inc.

Lippincott Williams & Wilkins

Sumatriptan Was Effective in Electroconvulsive Therapy (ECT) Headache

To the Editor:—We would like to draw attention to the benefit of sumatriptan on a 35-yr-old woman with chronic depression who was scheduled for a course of electroconvulsive therapy (ECT) during general anesthesia. We were able to find only one reference of this subject.¹ After her initial ECT sessions, the patient complained of severe headache. This appeared just after emergence from the anesthetic and lasted for several hours. After trying different analgesics with only partial or no relief, we decided to try 6 mg sumatriptan administered subcutaneously just after the ECT was performed. The patient had a history of migraine, and she described her ECT headache pain to be similar.

The patient was headache free after the first ECT in which she received sumatriptan. Except for one instance in which she experienced a pressure-tingling sensation, the patient continued to be headache free for the remainder of the final four ECT sessions of a 12-treatment series.

Sumatriptan is a selective 5-hydroxytryptamine (5-HT) receptor agonist² used for the acute treatment of migraine and cluster headache. The pain of migraine appears to involve the vessels of the pia and dura mater and the trigeminal nerve, which innervates these vessels. Specifically, activated trigeminovascular axons produce pain and result in the local release of vasoactive neuropeptides, which produce vasodilation.³ This "neurogenic inflammation" is thought to be the mechanism underlying the pain of migraine. Sumatriptan appears to work *via* specific serotonin receptors

2. Marek T, EdmÉ JL, Boulenguez C, Shirali P, Haguenoer JM: Bronchial symptoms and respiratory function in workers exposed to methylmethacrylate. *Br J Ind Med* 1993; 50:894-7

3. Lozewicz S, Davison AG, Hopkirk A, Burge PS, Boldy D, Riordan JF, McGivern DV, Platts BW, Davies D, Newman Taylor, AJ: Occupational asthma due to methyl methacrylate and cyanoacrylates. *Thorax* 1985; 40:836-9

4. Gurewicz V, Thomas D, Stein M, Wessler S: Bronchospasm in the presence of pulmonary embolism. *Circulation* 1963; 27:339-45

5. Salem MR, Baraka A, Rattenborg C, Holaday DA: Bronchospasm: An early manifestation of pulmonary embolism during and after anesthesia. *Anesth Analg* 1968; 47:103-7

6. Severinghaus JW, Swenson EW, Finley TN, Lategola MT, Williams J: Unilateral hypoventilation produced in dogs by occluding one pulmonary artery. *J Appl Physiol* 1961; 16:53-60

7. Swenson EW, Finley TN, Guzman SV: Unilateral hypoventilation in man during temporary occlusion of one pulmonary artery. *J Clin Invest* 1961; 40:828-35

8. Albin MS, Carroll RG, Maroon JC: Clinical considerations concerning detection of venous air embolism. *Neurosurgery* 1978; 3:380-4

(Accepted for publication June 23, 1998.)

(5-HT 1B and 5-HT 1D) to mediate selective vasoconstriction within the cranial vasculature and to prevent the release of inflammatory mediators from trigeminal nerve terminals. Headache is a well-known side effect of ECT.⁴ Although the exact mechanism is not known, it is possible that 5-HT receptors are involved and also that the pain can take the form of migraine.⁵ Electroconvulsive therapy acts as well on 5-HT receptors and also on postsynaptic 5-HT receptors.⁶

Angel Oms, M.D., D.A., F.A., F.R.C.S.E.
7701aot@comb.es

Emilio Miro, M.D.

Jose-Emilio Rojo, M.D.

Departments of Anesthetics and Psychiatry
Hospital de Bellvitge
Feixa Llarga, Barcelona, Spain

References

1. DeBattista C, et al: Sumatriptan prophylaxis for postelectroconvulsive therapy headaches. *Headache* 1995; 35(8):502-3
2. Buzzi MG, Moskowitz MA: The antimigraine drug, sumatriptan,

CORRESPONDENCE

selectively blocks neurogenic plasma extravasation from blood vessels in dura mater. *Br J Pharmacol* 1990; 99(1):202-6

3. Moskowitz MA: Neurogenic inflammation in the pathophysiology and treatment of migraine. *Neurology* 1993; 43(6 suppl 3): 16-20

4. Weiner SJ, Ward TN, Ravaris CL: Headache and electroconvulsive therapy. *Headache* 1994; 34(3):155-9

5. Weinstein RM: Migraine occurring as sequela of electroconvulsive therapy (letter). *Headache* 1993; 33(1):45

6. Coppen A, Rama-Rao VA, Bishop M, et al: Neuroendocrine studies in affective disorders: Plasma prolactin response to THR in affective disorders: Effect of ECT. *J Affect Dis* 1980; 2:311-5

(Accepted for publication April 24, 1998.)

Anesthesiology
1998; 89:1292

© 1998 American Society of Anesthesiologists, Inc.
Lippincott Williams & Wilkins

Defeating Proprietary Technology

To the Editor:—Use of needleless intravenous access systems, such as the Baxter InterLink (Baxter Healthcare Corporation, Round Lake, IL), have been advocated to reduce needle-stick injuries. We were recently confronted with a perplexing situation. During a rapid sequence intravenous induction it was noted that the intravenous infusion appeared to be obstructed without obvious indication of tubing occlusion or crimping. There was excellent blood return during aspiration and little resistance to injection at the intravenous injection site most proximal to the patient. The intravenous piggyback antibiotics flowed freely through a distal injection site. Finding no obvious cause for occlusion, the entire intravenous access system was quickly replaced, and the remainder of the case proceeded uneventfully.

At closer inspection of the faulty InterLink intravenous access system, it became apparent that the distal injection site had been accessed for a piggyback antibiotic infusion, using a Monoject 16 gauge blunt needle (Sherwood Medical, St. Louis, MO). The blunt needle had pushed the self-sealing rubber septum of the injection site into the lumen of the intravenous tubing, causing the unexplained occlusion (fig. 1), permitting the free flow of the intravenous antibiotics but occlusion to more distal infusion. The InterLink intravenous access system uses a proprietary plastic cannula with a blunt, beveled tip to access the pre-slit injection sites; use of a nonspecific blunt tip needle may incapacitate the intravenous access system. This case report again shows the dangers of improvisation.

Jeremy L. Krock, D.O., F.A.O.C.A.

Gurpreet S. Padda, M.D.

paddag@slucare1.sluh.edu

Assistant Professor

Department of Anesthesiology and Pediatrics
Saint Louis University Medical Center

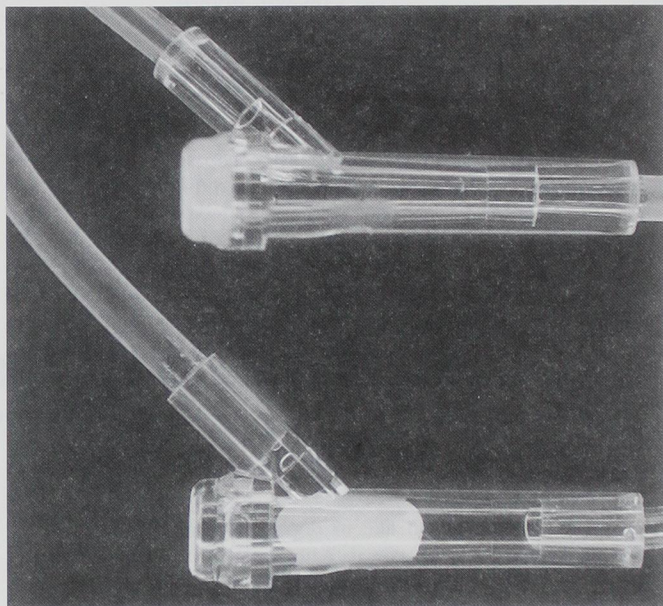


Fig. 1. Upper injection site normal. Lower injection site shows displaced intraluminal rubber septum.

Cardinal Glennon Children's Hospital
St. Louis, Missouri

Hani F. Gabriel, MD

Resident Physician

Department of Anesthesiology

Saint Louis University Medical Center

St. Louis, Missouri

(Accepted for publication June 10, 1998.)