

Anesthesiology
1998; 89:907-912
© 1998 American Society of Anesthesiologists, Inc.
Lippincott Williams & Wilkins

Prospective, Randomized Comparison of Deep or Superficial Cervical Plexus Block for Carotid Endarterectomy Surgery

Mark D. Stoneham, M.A., F.R.C.A.,* Anthony R. Doyle, B.Sc., F.R.C.A.,* John D. Knighton, M.R.C.P., F.R.C.A.,* Pema Dorje, F.R.C.A.,† James C. Stanley, M.D.‡

Background: Carotid endarterectomy may be performed under cervical plexus block with local anesthetic supplementation by the surgeon as necessary during surgery. It is unclear, however, whether deep or superficial cervical plexus block offers the best operating conditions or patient satisfaction. Therefore, the authors compared the two in patients undergoing carotid endarterectomy.

Methods: Forty patients undergoing carotid endarterectomy were randomized to receive either a superficial or a deep cervical plexus block with 20 ml bupivacaine, 0.375%. Outcomes subjected to statistical analysis included supplemental anesthetic supplementation with lidocaine, 1%, by the surgeon, dermatomes affected by the block, paresthesia during block placement, postoperative pain scores, and analgesic requirements.

Results: Median supplemental lidocaine requirements were 6 ml (range, 0.5 to 20 ml) in the deep block group and 6 ml (range, 0 to 20 ml) in the superficial block group ($P = 0.7323$). Patients in the deep block group who reported paresthesia during block placement required less lidocaine supplementation (median, 2; range, 0.5 to 20 ml) than the 9.5 ml (range, 6 to 15.5 ml) required by those who did not experience paresthesia ($P = 0.0113$). Compared with patients in the superficial block group, those in the deep block group were less likely to need analgesia in the first 24 h after operation ($P = 0.047$), and those who required analgesia received it later (6.6 ± 4.1 vs. 3.9 ± 1.4 h after operation; Student's t test, $P = 0.02$). One patient in each group expressed dissatisfaction with the technique.

Conclusions: Carotid endarterectomy may be performed satisfactorily during superficial or deep cervical plexus block placement with no differences in terms of supplemental local

anesthetic requirements, although this is influenced by whether paresthesia is elicited during placement of the deep block. Therefore, the clinician's decision to use one block rather than another need not be based on any assumed superiority of one block based on intraoperative conditions or patient satisfaction. (Key words: Analgesia; postoperative; regional anesthetic techniques; vascular surgery.)

REGIONAL block has been the standard anesthetic technique used for carotid endarterectomy (CEA) for more than a decade at the University of Michigan. It necessitates blockade of cervical nerves C1-C4, which may be performed typically using a cervical plexus block. This is most commonly a deep cervical plexus block¹⁻³ or a combination of deep and superficial cervical plexus blocks.⁴⁻¹¹ Techniques for placement of these blocks have been well described.^{12,13} A single-injection technique at C4 is used by the authors for deep cervical plexus block placement.¹ There are, however, few descriptions in the literature of the use of superficial block alone for carotid surgery. Indeed, a theoretical drawback of superficial block alone may be a lack of muscle relaxation in the neck, which can make surgery on deep structures more difficult.^{13,14}

Placement of deep cervical plexus block is technically more challenging to perform than placement of superficial block, necessitating localization of the cervical transverse processes, which may be difficult in obese patients. The purpose of this investigation was to identify any differences in terms of anesthetic effectiveness and patient satisfaction between deep and superficial cervical plexus blocks for CEA.

Materials and Methods

Forty patients undergoing elective CEA during regional anesthesia were observed using a protocol approved by the institutional review board of the University of Mich-

* Visiting Instructor in Anesthesiology.

† Assistant Professor of Anesthesiology.

‡ Professor and Head, Section of Vascular Surgery.

Received from the Departments of Anesthesiology and Surgery, University of Michigan, Ann Arbor, Michigan. Submitted for publication December 30, 1997. Accepted for publication June 11, 1998. Presented in part at the 72nd Annual Meeting of the International Anesthesia Research Society, March 8-11, 1998, Orlando, Florida.

Address reprint requests to Dr. Stoneham: Nuffield Department of Anaesthesia, John Radcliffe Hospital, Oxford, OX3 9DU, United Kingdom. Address electronic mail to: mark.stoneham@clara.net

igan. Patients with known bleeding diathesis; a history of allergy to local anesthetic agents, local sepsis, chronic pulmonary disease; or known diaphragmatic motion abnormalities were excluded from the study. A 20-gauge cannula was placed in the contralateral radial artery to facilitate continuous monitoring of blood pressure. In addition, noninvasive blood pressure, five-lead electrocardiography (leads II and V5), and pulse oximetry were monitored before placement of the cervical block and continued until discharge from the postanesthesia care unit.

Patients were randomized to two groups according to a computer-generated random numbers table. Placement of cervical plexus blocks were performed by one of four attending anesthesiologists, all of whom were experienced in these techniques. Patients in the first group received a deep cervical plexus block using a single-injection technique at the C4 level.¹ Briefly, while the patient was supine with head turned away, the cervical transverse processes were palpated manually approximately 1 cm posterior to the posterior border of sternocleidomastoid. After intradermal infiltration of 0.25 ml lidocaine, 1%, at the level of the C4 transverse process, a 1-inch 25-gauge needle was introduced at right angles to the skin, but aimed in a slightly caudad direction to prevent intrathecal injection. After location of the transverse process 1 or 2 cm from the skin or after the patient reported paresthesia in the distribution of the cervical plexus, 20 ml plain bupivacaine, 0.375%, was injected.

Patients in the second group underwent superficial cervical plexus block placement.¹³ An intradermal "bleb" of lidocaine, 1%, was raised at the midpoint of the posterior border of sternocleidomastoid. Twenty ml plain bupivacaine, 0.375%, was injected in the subcutaneous plane along the posterior body of the sternocleidomastoid in cranial and caudal directions from this point.

Twenty minutes after the block was placed, skin testing to pinprick and cold was performed according to standard dermatome charts by an anesthesiologist blinded to the group randomization.¹⁵ This provided unbiased documentation of the dermatomes affected by the block. No intravenous opioids were administered during the operative procedure. During insertion of monitoring lines and placement of the block until arrival in the postanesthesia care unit, sufficient sedation with diazepam in 2.5-mg doses was administered to alleviate patient anxiety. In no instance did this interfere with continuous communication with

the patients to assess neurologic status. A Javid shunt was placed if there was a change in neurologic status during carotid cross-clamping.

The surgeons were blinded to the type of block used. Additional local anesthetic (lidocaine, 1%) was administered superficially (into the skin and subcutaneous tissues) or deep (into and around the carotid sheath) by the surgeon in 1-ml aliquots to supplement the block whenever the patient reported discomfort. The surgeons rated the operative exposure in terms of muscle relaxation on a four-point subjective scale (0 = none, 1 = poor, 2 = moderate, 3 = good). Complications such as the need to convert to general anesthesia, development of neurologic complications, and the use of a shunt by the surgeon were noted.

The time of the patient's first request for postoperative analgesia in the postanesthesia care unit was recorded. Orders were written for all patients in the first 24 h after operation for intravenous morphine in 2-mg aliquots or 1,000 mg oral acetaminophen, to be administered by the postanesthesia care unit and ward nurses. These nurses were blinded to the type of block used in the study. After arrival in the postanesthesia care unit, patients also were asked to complete a standard 10-cm visual analog pain score test (0 cm = no pain, 10 cm = worst pain imaginable) that described how much pain they experienced while in the operating room.

The null hypothesis was that the two study groups would require identical doses of supplemental lidocaine in the operating room. It was considered that a difference between the two groups of 40-mg lidocaine (4 ml lidocaine, 1%) would be clinically significant. From a pilot study and the personal experience of the investigators, the standard deviation of the dose of additional local anesthetic administered during these procedures was estimated as ± 40 mg lidocaine. Therefore, to achieve a power of the study of 0.8, at least 17 patients were needed in each group.¹⁶ Statistical analysis of the data included Student's *t* test for repeated measures, as appropriate for continuous parametric data, the Mann-Whitney U test, the Wilcoxon's signed rank test, and chi-squared analysis for nonparametric data.

Results

Patient age, height, weight, and gender sex were similar in the two study groups (table 1). A wider dermatomal area was blocked in patients receiving deep cervical

DEEP OR SUPERFICIAL CERVICAL BLOCK FOR CAROTID SURGERY

Table 1. Patient Characteristics

	Deep (n = 20)	Superficial (n = 20)
Age (yr)	69.5 (7.3)	70.9 (9.8)
Gender	9F:11M	11F:9M
Height (cm)	172.7 (7.8)	169.0 (9.4)
Weight (kg)	77.1 (11.4)	74.5 (16.5)

Data are mean (SD).

plexus block, as assessed 20 min after insertion of the cervical plexus block (fig. 1); 7 of these 20 patients had sensory changes in the C5 dermatome. Supplemental lidocaine requirements were not different between the two groups (Mann-Whitney U test, $P = 0.7323$), although patients receiving deep block required more lidocaine in the skin and subcutaneous tissues, whereas patients receiving superficial block required more lidocaine in and around the carotid sheath (fig. 2). Doses of intravenous diazepam sedation were similar in the two groups (deep block group, 22.3 ± 13 mg; superficial block group, 22.5 ± 17 mg; Student's t test, $P = 0.9579$), which were administered from the time the patient first arrived in the holding room to the end of the procedure (usually at least 4 h).

Postoperative analgesic requirements were more in patients receiving superficial block (table 2). More patients receiving superficial block required analgesia in the first 24 h after operation, and, of those who were administered analgesia, patients receiving superficial block tended to be administered morphine rather than acetaminophen and requested analgesia earlier than did patients in the deep block group. Visual analog pain scores were higher in patients receiving superficial block (table 2).

Paresthesia occurring during deep cervical plexus block placement made the block more effective in terms of needing less supplemental local anesthetic (table 3). If paresthesia was elicited, there was a trend toward less analgesia requested and administered, although this was not statistically significant.

One perioperative neurologic event occurred. A patient randomized to receive deep block immediately before surgery experienced a transient ischemic attack, but this resolved completely within 1 h, and the CEA was allowed to proceed. Intraoperative carotid shunting was used in two patients in the deep block group and in three patients in the superficial block group (overall incidence = 5 of 40, or 12.5%). Neurologic changes developed in all of these patients during carotid cross-clamping, which reversed after the shunt was inserted. All patients were neurologically intact after operation. One patient in the deep block group required conversion to general anesthesia 2 h after incision because of anxiety and intolerance to the ongoing procedure, although the vascular dissection was complete by this time and arteriotomy was already achieved.

There were no differences between the two groups in terms of the surgeon's subjective assessment of the operative exposure (deep block group median score, 3 [range, 2-3]; superficial block group median score, 3 [range, 1-3] by the Wilcoxon's signed rank test, $P = 0.1797$). One patient in each group expressed dissatisfaction with the technique and said they would be reluctant to undergo similar surgery during regional anesthesia in the future. The other patients all said they would be willing to repeat the experience.

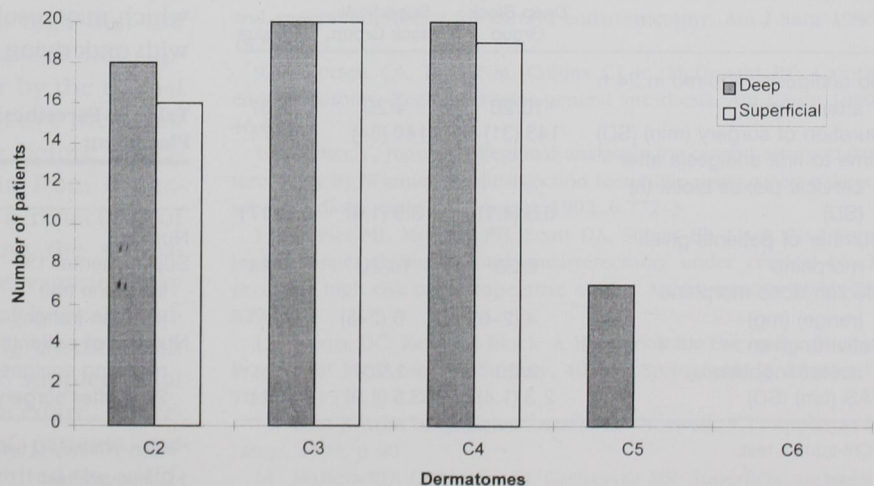


Fig. 1. Dermatomes affected by deep and superficial blocks.

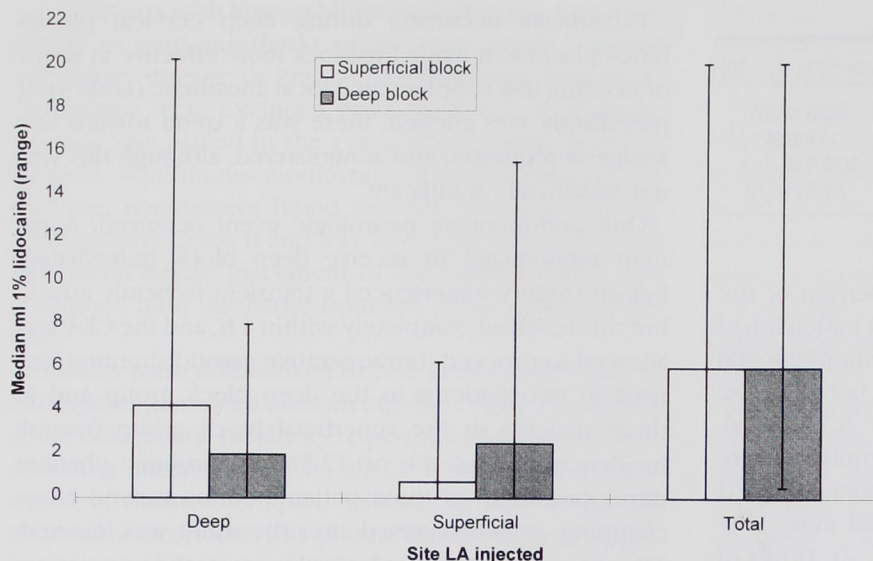


Fig. 2. Supplementary lidocaine requirements during carotid endarterectomy. Data are given as medians (range).

Discussion

This study reported that anesthesia for CEA may be accomplished successfully using either deep or superficial cervical plexus block placement combined with sedation and local infiltration by the surgeon. There were no differences in the amounts of local anesthetic supplementation necessary between the two groups, although this was influenced by whether paresthesia was elicited during placement of the deep block. Fewer patients receiving deep cervical plexus block requested analgesia in the first 24 h after surgery.

In addition to the effectiveness of the anesthetic block,

other factors must be considered when a particular local anesthetic technique is selected. Such factors include the difficulties in performing the block placement, the overall dose of local anesthetic used (which may be very high when combined deep and superficial blocks are used^{17,18}), and the potential complications that might occur after placement of the block. However, we did not directly evaluate these issues, and therefore, it is not possible to draw any firm additional conclusions based on this study.

Complications are associated with both of the regional blocks used in this study, although more have been described with deep cervical plexus block than with superficial block.¹⁴ Deep block has been reported to cause diaphragmatic dysfunction in 61% of patients,⁶ which may result in respiratory compromise in patients with underlying respiratory impairment.¹⁹ Conversely, it

Table 2. Postoperative Assessment

	Deep Block Group	Superficial Block Group	P Value
No analgesia required in 24 h after surgery	10/20	4/20	0.0467*
Duration of surgery (min) (SD)	143 (31)	140 (34)	0.7471
Time to first analgesia after cervical plexus block (h) (SD)	6.6 (4.1)	3.9 (1.4)	0.0217†
Number of patients given morphine	6/20	14/20	0.0114*
Median dose morphine (range) (mg)	4 (2-6)	6 (2-8)	
Patients given acetaminophen	3/20	1/20	
VAS (cm) (SD)	2.3 (1.4)	3.5 (1.9)	0.031†

* Chi-square test.

† t test.

Table 3. Paresthesia Occurring during Deep Cervical Block Placement

	Paresthesia	No Paresthesia	P Value
Number	12/20	8/20	—
Supplemental 1% lidocaine (ml) [median (range)]	2 (0.5-20)	9.5 (6-15.5)	0.011*
Number of patients not requiring analgesia in 24 h after surgery	8/12	2/8	0.1709†

* Mann-Whitney U test.

† Chi-square test.

DEEP OR SUPERFICIAL CERVICAL BLOCK FOR CAROTID SURGERY

is also possible that phrenic nerve blockade may occur as a result of local anesthetic supplementation of deep structures, as was needed in our superficial block group. We have no information about the incidence of phrenic dysfunction with supplemented superficial blocks. Epidural or subarachnoid injections also may occur with deep blocks, as can local anesthetic injection into the vertebral artery. However, the incidences of such events are defined poorly and are very low, particularly when experienced anesthesiologists perform the block placement. Therefore, these factors are difficult to incorporate into any cost-benefit assessment.

Controversy persists about whether paresthesia should be sought actively during placement of a regional block. Some authors have condemned techniques in which paresthesia is sought because this may lead to postoperative dysesthesia.²⁰ However, this view recently was challenged on the basis that no creditable data exist to support the abandonment of such techniques.²¹ Furthermore, techniques that elicit paresthesia have been shown to make axillary brachial plexus blockade more effective than other techniques.²² In the current study, deep cervical block with paresthesia was more effective in that less additional local anesthetic was necessary. Our unpublished observations (January 1996–April 1997) suggest that paresthesia is reported by 40–60% of patients undergoing deep cervical block placement. Additional studies will determine whether the dermatome where paresthesia is elicited is important in determining the effectiveness of the cervical block, or whether analgesic requirements are reduced when paresthesia is elicited during placement of the block.

This study, similar to others, was limited by the wide variability of patients undergoing CEA. In some patients, the carotid disease extended so high that the incision needed to be extended into tissues not supplied by the cervical plexus, but rather by the cranial nerves. In addition, no matter how effective the block was, as tested by analgesia-to-pinprick before operation, patients sometimes reported pain from dissection around the artery. This may be a reflection of additional afferent fibers accompanying the sympathetic innervation of the vessel. These vagaries may explain the wide range of supplemental lidocaine administered in both groups of patients (fig. 2), although some patients in both groups needed no supplemental lidocaine throughout the operative procedure. Therefore, differences in pain thresholds of patients and differing levels of sedation may have limited the valid-

ity of this study, although the effect of these factors should have been reduced because intravenous opioids were avoided.

Carotid endarterectomy can be performed successfully during placement of deep or superficial cervical plexus blocks with surgical supplementation. Deep block is superior in terms of less postoperative pain. The effectiveness of deep cervical plexus block is increased if paresthesia is elicited during block placement.

References

1. Winnie AP, Ramamurthy S, Durrani Z, Radonjic R: Interscalene cervical plexus block: A single-injection technic. *Anesth Analg* 1975; 54:370–5
2. Takolander R, Bergqvist D, Hulthen UL, Johansson A, Katzman PL: Carotid artery surgery. Local versus general anaesthesia as related to sympathetic activity and cardiovascular effects. *Eur J Vasc Surg* 1990; 4:265–70
3. Forsell C, Takolander R, Bergqvist D, Johansson A, Persson NH: Local versus general anaesthesia in carotid surgery. A prospective, randomised study. *Eur J Vasc Surg* 1989; 3:503–9
4. Allen BT, Anderson CB, Rubin BG, Thompson RW, Flye MW, Young-Beyer P, Frisella P, Sicard GA: The influence of anesthetic technique on perioperative complications after carotid endarterectomy. *J Vasc Surg* 1994; 19:834–42
5. Davies MJ, Murrell GC, Cronin KD, Meads AC, Dawson A: Carotid endarterectomy under cervical plexus block—A prospective clinical audit. *Anaesth Intensive Care* 1990; 18:219–23
6. Castresana MR, Masters RD, Castresana EJ, Stefansson S, Shaker IJ, Newman WH: Incidence and clinical significance of hemidiaphragmatic paresis in patients undergoing carotid endarterectomy during cervical plexus block anesthesia. *J Neurosurg Anesthesiol* 1994; 6:21–3
7. Godin MS, Bell WH 3rd, Schwedler M, Kerstein MD: Cost effectiveness of regional anesthesia in carotid endarterectomy. *Am J Surg* 1989; 55:656–9
8. Muskett A, McGreevy J, Miller M: Detailed comparison of regional and general anesthesia for carotid endarterectomy. *Am J Surg* 1986; 152:691–4
9. Andersen CA, Rich NM, Collins GJ Jr, McDonald PT: Carotid endarterectomy: Regional versus general anesthesia. *Am J Surg* 1980; 46:323–7
10. Mehta Y, Juneja R: Regional analgesia for carotid artery endarterectomy by Winnie's single-injection technique using a nerve detector. *J Cardiothoracic Vasc Anesth* 1992; 6:772–3
11. Davies MJ, Mooney PH, Scott DA, Silbert BS, Cook RJ: Neurologic changes during carotid endarterectomy under cervical block predict a high risk of postoperative stroke. *ANESTHESIOLOGY* 1993; 78: 829–33
12. Moore DC: *Regional Block: A Handbook for Use in the Clinical Practice of Medicine and Surgery*, 4th ed. Springfield, IL, Charles C Thomas, 1978, p 112
13. Katz J. *Atlas of Regional Anesthesia*. Norwalk, CT, Appleton & Lange, 1994, p 40
14. Masters RD, Castresana EJ, Castresana MR: Superficial and deep

cervical plexus block: Technical considerations. *AANA Journal* 1995; 63:235-43

15. Lofstrom B, Eriksson E, eds. *Cervical nerve block, Illustrated Handbook in Local Anaesthesia*, 2nd ed. London: Lloyd-Luke, 1979, pp 77-8

16. Glantz SA: *Primer of Biostatistics*. New York: McGraw-Hill, 1992, p 155

17. Goldberg MJ: Complication of cervical plexus block or fugue state? *Anesth Analg* 1995; 81:1108-9

18. Tissot S, Frering B, Gagnieu M, Vallon J, Motin J: Plasma concentrations of lidocaine and bupivacaine after cervical plexus block for carotid surgery. *Anesth Analg* 1997; 84:1377-9

19. Stoneham MD, Wakefield TW: Acute respiratory distress following deep cervical plexus block. *J Cardiothoracic Vasc Anesth* 1998; 12:197-8

20. Selander D, Edshage S, Wolff T: Paresthesiae or no paresthesiae? Nerve lesions after axillary blocks. *Acta Anaesthesiologica Scandinavica* 1979; 23:27-33

21. Moore DC, Mulroy MF, Thompson GE: Peripheral nerve damage and regional anaesthesia. *Br J Anaesth* 1994; 73:435-6

22. Schroeder LE, Horlocker TT, Schroeder DR: The efficacy of axillary block for surgical procedures about the elbow. *Anesth Analg* 1996; 83:747-51