

CASE REPORTS

Anesthesiology
1998; 89:785-7
© 1998 American Society of Anesthesiologists, Inc.
Lippincott Williams & Wilkins

Vocal Cordal Bowing as a Cause of Long-lasting Hoarseness after a Few Hours of Tracheal Intubation

Takeshi Shimokojin, M.D.,* Makoto Takenoshita, M.D.,† Toshiko Sakai, M.D.,‡ Kiyoshi Yoshikawa, M.D.

HOARSENESS is one complication of tracheal intubation. The causes include laryngeal edema, laryngeal nerve paralysis, vocal cord granuloma, vocal cord polyp, vocal cord adhesion, and laryngotracheal membranous stricture.^{1,2} Laryngofibrosis also is a rare but severe sequela of tracheal intubation in which symptoms occur 45-60 days after extubation.³

We report three patients in which hoarseness occurred soon after periods of tracheal intubation that lasted 2-6 h and appeared to be caused by persistent vocal cord deformation. In each patient, hoarseness was noticed by a nurse and was reported to the anesthesia department within 1 to 4 days after surgery. In all three patients, bilateral vocal cord deformation was the only abnormal finding revealed by laryngeal fiberoptic evaluation.

* Staff Anesthetist, Department of Anesthesia, Toyonaka City Hospital, Toyonaka, Japan.

† Assistant Professor, Department of Anesthesiology, Osaka University Medical School, Osaka, Japan.

‡ Chief Anesthetist, Department of Anesthesia, Osaka Medical Center of Cancer and Cardiovascular Diseases, Osaka, Japan.

§ Director, Department of Anesthesia, Osaka Medical Center of Cancer and Cardiovascular Diseases, Osaka, 553, Japan.

Received from the Osaka Medical Center of Cancer and Cardiovascular Diseases, Osaka, 553, Japan. Submitted for publication November 18, 1997. Accepted for publication May 6, 1998. Presented in part in Japanese at the oral session of the 38th Annual Anesthesiologists' Meeting of Osaka Region, Osaka, Japan, September 19, 1992.

Address reprint requests to Dr. Takenoshita: Department of Anesthesiology, Osaka University Medical School, 2-2, Yamadaoka, Suita, Osaka, 565-0871, Japan. Address electronic mail to: makoto@anes.med.osaka-u.ac.jp

Key words: Complication; laryngeal fiberoptic; mechanical deformation

Case Report

Case 1

A 58-yr-old man (weight, 60 kg; height, 164 cm) was scheduled to undergo sigmoidectomy. Medical history and laboratory evaluations were unremarkable. General anesthesia was induced using thiopental and vecuronium. The trachea was intubated with an 8.5-mm internal diameter, low-pressure cuffed endotracheal tube without difficulty. Anesthesia was maintained with nitrous oxide in oxygen, sevoflurane, and epidural lidocaine. The endotracheal tube was removed immediately after completion of the surgery. Tracheal intubation duration was 2 h, 20 min. Several hours after extubation, the patient complained of breathy hoarseness. One week later, he was still hoarse, and laryngeal fiberoptic evaluation was performed by an otolaryngologist (fig. 1). There was no edema nor paralysis of the vocal cords, but the cords could not close completely while vocalizing a vowel, such as "a" or "i." The cords were deformed into an symmetrically arched shape. Twenty two days after surgery, the hoarseness existed still, and the vocal cord deformity still was observed during fiberoptic laryngoscopy. The hoarseness disappeared 1 month after surgery; medication was not administered. Years later, the patient's vocal cords were reevaluated laryngoscopically. No deformity was found.

Case 2

A 54-yr-old man (weight, 69 kg; height 162 cm) with gastric cancer was scheduled to undergo distal gastrectomy. Medical history and laboratory evaluations were unremarkable. General anesthesia was induced using thiopental and vecuronium. The trachea was intubated with an 8.5-mm internal diameter, low-pressure cuffed endotracheal tube without difficulty. Anesthesia was maintained using nitrous oxide in oxygen, sevoflurane, and epidural lidocaine. The endotracheal tube was removed immediately after surgery. Tracheal intubation duration was 3 h, 25 min. Soon after the patient's arrival at the recovery room, moderate hoarseness was recognized by a nurse. Hoarseness continued, and, 1 week after surgery, laryngeal fiberoptic evaluation was performed by an otolaryngologist. Findings were the same as in case 1: the patients vocal cords were deformed into an arched shape, and they did not close tightly. There was no edema and no paralysis. To increase blood flow and augment tissue metabolism, adenosine triphosphate disodium (20 mg, orally, three times a day) and vitamin B₁₂ (cyanocobalamin, 0.5 mg, orally, three times a day) were administered. The hoarseness disappeared after 1 month.

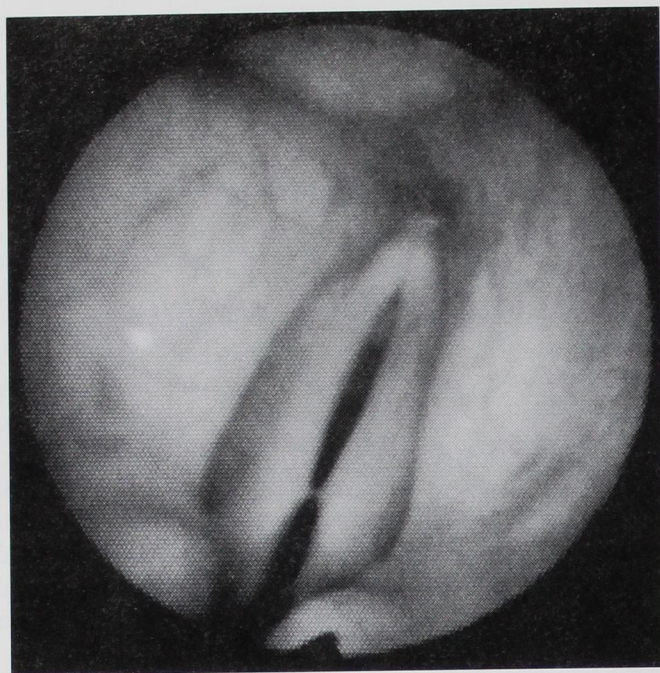


Fig. 1. Laryngeal fiberoptic photograph of a 58-yr-old man 1 week after tracheal intubation. The vocal cord is in the closed state. It is spindle shaped and could not close completely. It shows no edematous change.

Case 3

A 52-yr-old man (weight, 56 kg; height, 154 cm) was scheduled to undergo sigmoidectomy. Medical history and laboratory evaluations were unremarkable. General anesthesia was induced using thiopental and vecuronium. The trachea was intubated without difficulty using an 8.0-mm internal diameter, low-pressure cuffed endotracheal tube. Anesthesia was maintained as noted above. The endotracheal tube was removed immediately after surgery. Tracheal intubation duration was 5 h, 40 min. In the recovery room, breathy hoarseness was noticed. Laryngofiberscopically, the same deformation of the vocal cord was observed. The medication administered was the same as in case 2. The hoarseness disappeared after 1 month.

Discussion

We report these three cases of tracheal-intubation-induced hoarseness for two reasons: long duration of hoarseness and its cause. Baron and Kahlmoos¹ (1951) reported that 42% of intubated patients had dysphonia with congestion and edema of the vocal cords, and this laryngitis disappeared without treatment in 2 to 3 days. In the three patients presented, hoarseness lasted for approximately 1 month. Laryngeal fiberoptic evaluation, performed 1 week after extubation, revealed no edematous changes and no paralysis of the vocal cords but showed bowing of the vocal-fold

edge on both sides, spindle-shaped glottic gaps, and air leakage during phonation (fig. 1). Postintubation cordal bowing has been reported as a cause of hoarseness before, but only after prolonged (2 weeks' duration) intubation.⁴ Clinical manifestations of these three cases resemble the clinical features of vocal-fold atrophy (sulcus vocalis), except the latter does not disappear within 1 month.^{5,6}

The cause of vocal cord bowing with intact movement is not known. Stiffness or atrophy of the mucous membrane of the vocal fold of certain people may play a role. The size of the endotracheal tube might be important. An oversized endotracheal tube could press the membranous portion of the vocal cord and may cause ischemic or pressure damage of laryngeal mucosa, with subsequent deformation and dysfunction. A large endotracheal tube could distort the thyroarytenoid muscle (musculus vocalis) and the surrounding structure, paralyzing peripheral branches of the recurrent nerve innervating the muscle at the vicinity of entering, in some vulnerable patients. Paralysis of the inferior laryngeal nerve branch at the vulnerable zone under the vocal cord should result in impaired movement of the vocal cord, but this regional paralysis (restricted to thyroarytenoid muscle) of the recurrent nerve could explain the vocal cord bowing with intact movement. Nevertheless, in all three patients, approximately 1 month was needed to recover from hoarseness, which seems more consistent with nerve palsy than with mere compression or damage of the tissue. The tubes used in the current cases might be too big in the United States, even though it is well within the range of recommended size in Japanese anesthesia textbooks. Insufficient vocal cord paralysis or vocal cord movement during the intubated period might be a precipitating factor, although muscle relaxants were fully administered during surgery in the current patients.

The incidence of the vocal cord bowing is not known. The three cases reported herein occurred within 9 months, and the number of tracheal-intubation anesthesia was approximately 1,500 annually. Therefore, the incidence may be approximately 1 of 500 cases, but we visited only approximately 80% of the anesthetized patients 1 week after anesthesia administration, it is hard to define the exact incidence. Nonetheless, because we requested that the personnel of other departments report episodes of postoperative hoarseness that lasted for more than 3 or 4 days, the incidence estimate listed may be reasonable. In all three patients reported, the hoarse-

CASE REPORTS

ness was recognized before we visited 1 week after surgery.

References

1. Baron SH, Kohlmos HW: Laryngeal sequelae of endotracheal anesthesia. *Ann Otol Rhinol Laryngol* 1951; 60:767-92
2. Wolfson B: Minor laryngeal sequelae of endotracheal intubation. *Br J Anaesth* 1958; 30:326-32
3. Blanc VF, Trembray N: The complications of tracheal intubation: a new classification with a review of the literature. *Anesth Analg* 1974; 53:202-13
4. Feder R: Early recognition and treatment of postintubation dysphonia. *Laryngoscope* 1983; 93:1070-2
5. Arnold GE: Dysplastic dysphonia: Minor anomalies of the vocal cords causing persistent hoarseness. *Laryngoscope* 1958; 68:142-58
6. Bouchayer M, Cornut G, Witzig E, Lorie R, Roch JB, Bastian RW: Epidermoid cysts, sulci, and mucosal bridges of the true vocal cord: A report of 157 cases. *Laryngoscope* 1985; 95:1087-94