

## Heart Rate Variability during Chemical Thoracic Sympathectomy

Munetaka Hirose, M.D.,\* Hiroto Imai, M.D.,† Misako Ohmori, M.D.,‡ Yasunori Matsumoto, M.D.,‡ Fumimasa Amaya, M.D.,‡ Toyoshi Hosokawa, M.D.,§ Yoshifumi Tanaka, M.D.||

**Background:** Chemical thoracic sympathectomy (CTS) resulted in profound bradycardia in a patient with severe post-therapeutic neuralgia. To clarify the cause of this bradycardia, the authors evaluated heart rate variability using a Poincaré plot, which is a scatter diagram of the current R-R interval plotted against the R-R interval immediately preceding it, in this patient and in others scheduled for CTS or mandibular block (MB).

**Methods:** Twenty-three patients were scheduled for CTS ( $n = 13$ , CTS group) and for MB ( $n = 10$ , MB group). Heart rate and the SD of the R-R interval variabilities spreading along the x axis ( $SD_{RR}$ ) and perpendicularly along the diagonal line of the Poincaré plot ( $SD_{\theta RR}$ ) were evaluated before, just after, and 1 h after the block.

**Results:** Neither group had significant changes in heart rate. The MB group showed no significant change in the  $SD_{RR}:SD_{\theta RR}$  ratio. In the CTS group, however, the  $SD_{RR}:SD_{\theta RR}$  ratio decreased significantly from  $1.72 \pm 0.20$  to  $1.23 \pm 0.11$  just after CTS. The previous patient, who had a high  $SD_{RR}:SD_{\theta RR}$  ratio of 3.45 before CTS, exhibited severe bradycardia (22 beats/min).

**Conclusions:** The  $SD_{RR}:SD_{\theta RR}$  ratio decreased after CTS without any significant concomitant change in heart rate. The decrease in the  $SD_{RR}:SD_{\theta RR}$  ratio indicates a reduction of cardiac sympathetic activity. However, CTS in patients having high  $SD_{RR}:SD_{\theta RR}$  ratios can result in profound bradycardia. (Key words: Cardiovascular; pain; sympathetic; sympathetically maintained pain.)

CHEMICAL thoracic sympathectomy can be used to treat sympathetically maintained pain in patients who have the complex regional pain syndrome type I (reflex sympathetic dystrophy) or post-herpetic neuralgia of an upper limb and the chest.<sup>1</sup> This sympathectomy is usually performed with alcohol injection at either the right or the left side of the thoracic sympathetic ganglia (T2, T3, T4, or T5), which are involved in sympathetic cardiac innervation.<sup>2</sup> Blood pressure and heart rate are generally stable during the chemical thoracic sympathectomy, and few effects on autonomic function have been reported.

Recently we encountered a patient in whom an alcohol block of T4 on the right side resulted in profound bradycardia. In an effort to better understand the cause of this event, we assessed the sympathetic nervous system in this patient during a second block and also in 13 other patients undergoing a similar procedure. We used an analysis of heart rate variability, displayed as a Poincaré plot.<sup>3</sup>

A 68-yr-old woman with post-herpetic neuralgia over the right T4 and T5 dermatome levels was scheduled to undergo a right chemical thoracic sympathectomy at the right T4 and T5 levels. Pain relief was obtained after the thoracic epidural blockade with 0.5% mepivacaine. No antidepressant or anticonvulsive drugs had been prescribed. She had no cardiopulmonary disorders.

The patient was transferred to the fluoroscopic room, and an intravenous catheter was inserted. With the patient in the prone position, we made a skin wheal with 1% lidocaine 4 cm right and lateral to the T4 spinous process and introduced an 8-cm, 21-gauge needle along the right lateral side of the T4 vertebral body. We injected 1 ml radiopaque contrast media (64.71% iohexol) dissolved in 1 ml 2% lidocaine and verified proper needle positioning. Fifteen minutes after we confirmed that there were no signs of intercostal nerve block or Horner's syndrome, 1.5 ml 99.5% alcohol was injected during a period of 1 min. Her heart rate decreased to 20-30 beats/min just after the alcohol injection and then subsided after an intravenous injection of 0.5 mg atropine

\* Instructor of Anesthesiology. Current address: Department of Anesthesia and Critical Care, Massachusetts General Hospital, Boston, Massachusetts 02114.

† Fellow, Department of Anesthesiology.

‡ Graduate Student, Department of Anesthesiology.

§ Associate Professor of Anesthesiology.

|| Professor of Anesthesiology.

Received from the Department of Anesthesiology, Kyoto Prefectural University of Medicine, Kyoto, Japan. Submitted for publication January 6, 1998. Accepted for publication May 8, 1998. Supported in part by Grants-in-Aid for Scientific Research from the Ministry of Education, Science and Culture of Japan.

Address reprint requests to Dr. Hirose: Department of Anesthesiology, Kyoto Prefectural University of Medicine, Kamigyoku, Kyoto 602-0841, Japan. Address electronic mail to: hirose@koto.kpu-m.ac.jp



## POINCARÉ PLOT AND CHEMICAL THORACIC SYMPATHECTOMY

sulfate and 5 mg etilefrine hydrochloride (a mixed  $\alpha$  plus  $\beta_1$  agonist).<sup>4</sup> We abandoned the right T5 block and discharged her after she had rested for 2 h. Blood pressure and heart rate were stable both in the supine and upright positions. She noted a warm sensation over her right chest, and her pain was reduced compared with that before the block.

Six months later, her chest pain gradually reappeared, and she requested a second thoracic sympathectomy. To avoid bradycardia, we performed a chemical lesion only at the right T5 level, because T3 and T4 were reported to induce the most substantial cardiac effect.<sup>2</sup>

## Materials and Methods

### Patients

The study was approved by the ethics committee of our institution, and all patients gave informed consent before agreeing to participate in the study. To evaluate the effect of the chemical thoracic sympathectomy on cardiac autonomic function, we analyzed heart rate variability in 13 patients (age, 30–70 yr; eight men, five women) who had complex regional pain syndrome type I or post-herpetic neuralgia and were scheduled for a two-level sympathectomy at T2, T3, or T4 (the thoracic sympathectomy group). Right sympathectomy was performed in eight patients, and left sympathectomy was done in five patients. The procedure of the block was the same as described above. We injected 99.5% alcohol (1.2–1.8 ml) at each ganglion. The completion of sympathectomy was identified with the appearance of patient's warm sensation at the upper limb or at the chest after the alcohol injection.

Because emotional stress during the nerve block may affect cardiac autonomic function, we also analyzed autonomic function in 10 patients (age, 44–79 yr; three men, seven women) who had trigeminal neuralgia and were scheduled for mandibular block, which has no direct effect on the cardiac sympathetic activity (the mandibular block group). Right mandibular block was performed in 7 patients, and left mandibular block was done in three patients. An 8-cm, 22-gauge needle was introduced at a point just inferior to the midpoint of the zygomatic arch and was advanced to the foramen ovale under fluoroscopic guidance until paresthesia of the mandibular nerve was encountered.<sup>5</sup> After confirming anesthesia of the mandibular nerve with the injection of 0.2 ml 2% lidocaine, we injected 0.2 ml 99.5% alcohol during a period of 10 s. All patients rested for 1–2 h on

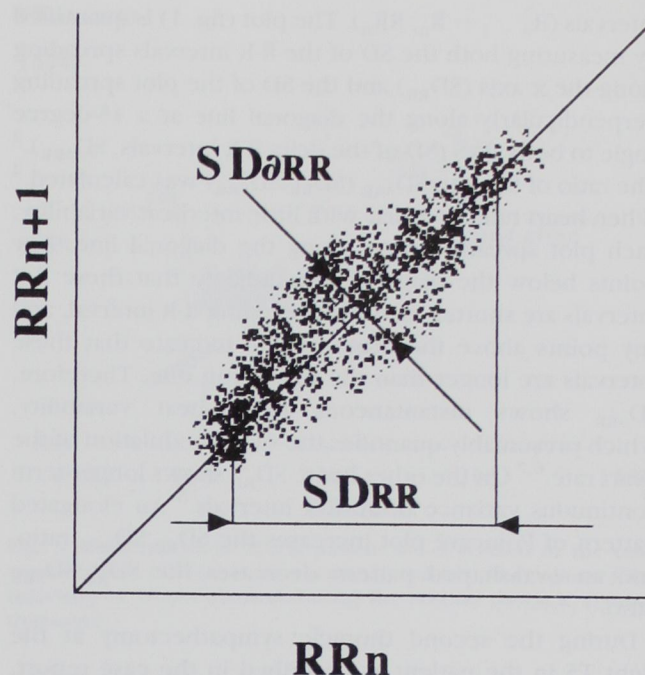


Fig. 1. A quantitative analysis of the Poincaré plots. We calculated the ratio of the standard deviation of the R-R interval ( $SD_{RR}$ ) to the standard deviation of the R-R interval spreading perpendicularly along the diagonal line ( $SD_{\theta RR}$ ).

the bed in a consultation room after the block and then were released.

One of two post-herpetic neuralgia patients had taken antidepressant, anticonvulsive, and antihypertensive drugs. One of the 11 complex regional pain syndrome patients had taken an antihypertensive drug. All trigeminal neuralgia patients had taken carbamazepine as an anticonvulsive drug.

### The Poincaré Plot

We recorded the electrocardiogram continuously using an analog data recorder (model MR-30 cassette data recorder; TEAC, Tokyo, Japan) in all patients throughout the procedure. Indirect blood pressure and heart rate were also monitored (model BP-508; Colin, Komaki, Japan). Heart rate variability was evaluated using a computer software Poincaré plot (Chart Extensions, MacLab version 3.5; ADInstruments, Castle Hill, Australia) and applying 3 min of electrocardiogram data obtained at three points: before the injection of alcohol, just after the injection of 99.5% alcohol, and 1 h after the injection. The Poincaré plot is a scatter plot of each R-R interval ( $R_n - R_{n+1}$ ;  $RR_{n+1}$ ) versus the previous R-R



intervals ( $R_{n-1} - R_n; RR_n$ ). The plot (fig. 1) is quantified by measuring both the SD of the R-R intervals spreading along the x axis ( $SD_{RR}$ ) and the SD of the plot spreading perpendicularly along the diagonal line at a 45-degree angle to both axes ( $SD_{\Delta RR}$ ).<sup>2</sup> The ratio of  $SD_{RR}$  to  $SD_{\Delta RR}$  ( $SD_{RR}:SD_{\Delta RR}$ ) was calculated.<sup>2</sup> When heart rate is regular with little interbeat variability, each plot spreads closely along the diagonal line. Any points below the diagonal line indicate that these R-R intervals are shorter than the preceding R-R interval, and any points above the diagonal line indicate that these intervals are longer than the preceding one. Therefore,  $SD_{\Delta RR}$  shows instantaneous beat-to-beat variability, which presumably quantifies the vagal modulation of the heart rate.<sup>6,7</sup> On the other hand,  $SD_{RR}$  shows longer-term continuous variance of all R-R intervals.<sup>6</sup> An elongated pattern of Poincaré plot increases the  $SD_{RR}:SD_{\Delta RR}$  ratio, and an oval-shaped pattern decreases the  $SD_{RR}:SD_{\Delta RR}$  ratio.

During the second thoracic sympathectomy at the right T5 in the patient as described in the case report, indirect blood pressure, heart rate, and the  $SD_{RR}:SD_{\Delta RR}$  ratio were also monitored. Although severe bradycardia reappeared just after the alcohol injection, the data for the calculation of  $SD_{RR}:SD_{\Delta RR}$  ratio just after the alcohol injection were obtained for 3 min before the injection of atropine sulfate.

### Statistics

Within- and between-group evaluations of each variable were conducted using one-way analysis of variance. Thereafter, Fisher's least-significant difference test was used to identify significant differences in various pairs of comparisons. The null hypothesis was rejected when  $P < 0.05$ . To compare each variable of the presented case with that of the thoracic sympathectomy group, we calculated the 95% confidence intervals of each variable in the group. All values are reported as mean  $\pm$  SD.

## Results

### Thoracic Sympathectomy and Mandibular Block Groups

There were no differences in heart rate recorded during the three measurement points in the two groups. Systolic blood pressure decreased significantly 1 h after the injection in both groups (fig. 2). The 95% confidence intervals of heart rate were 77.1 to 98.3, 70.6 to 90.4, and 74.8 to 84.5 beats/min before, just after, and 1 h

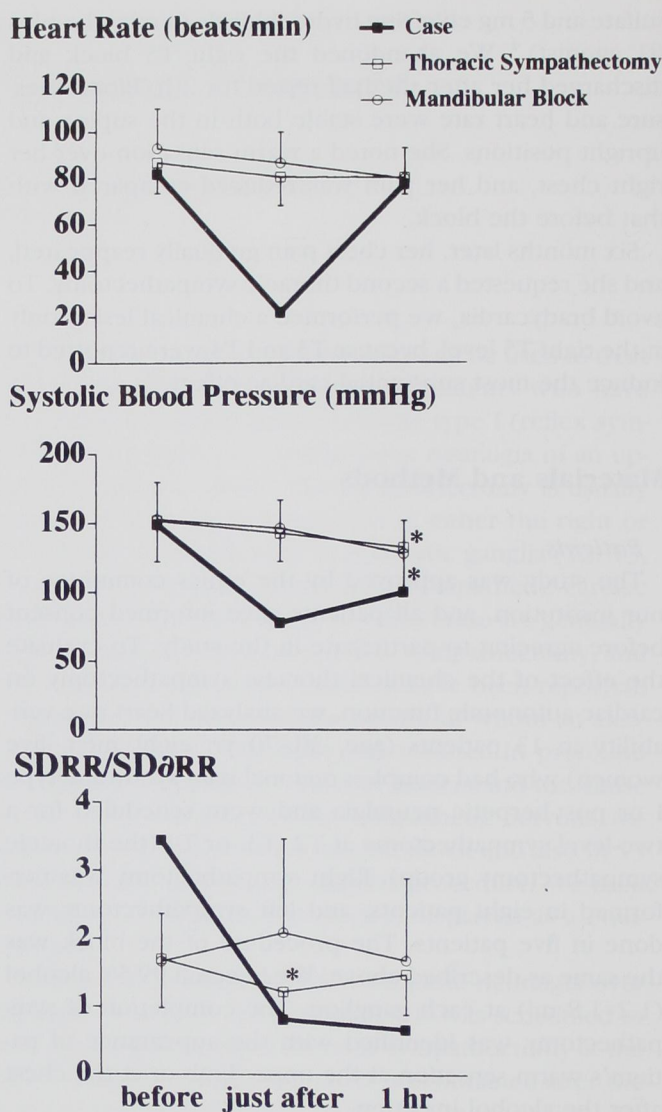


Fig. 2. Heart rate, systolic blood pressure, and the ratio of the SD of the R-R interval to the SD of the R-R interval spreading perpendicularly along the diagonal line ( $SD_{RR}:SD_{\Delta RR}$ ) before, just after, and 1 h after injection of 99.5% alcohol. A heavy solid line shows these values in the patient we describe. The lighter solid line indicates these values for other patients who underwent chemical thoracic sympathectomy ( $n = 13$ ) or mandibular block ( $n = 10$ ). The systolic blood pressure decreased significantly 1 h after the injection in both the thoracic sympathectomy and mandibular block groups. The  $SD_{RR}:SD_{\Delta RR}$  ratio showed a significant decrease just after the injection only in the thoracic sympathectomy group. \* $P < 0.05$  versus the value before the alcohol injection. Values are mean  $\pm$  SD.

after the thoracic sympathectomy, respectively. In addition, the 95% confidence intervals of systolic blood pressure were 129.8 to 178.2, 120.6 to 162, and 99.6 to 166.4 mmHg, respectively.



## POINCARÉ PLOT AND CHEMICAL THORACIC SYMPATHECTOMY

The  $SD_{RR}:SD_{\sigma RR}$  ratios were  $1.72 \pm 0.20$ ,  $1.23 \pm 0.11$ , and  $1.48 \pm 0.16$  before, just after, and 1 h after the thoracic sympathectomy, respectively. It decreased significantly just after the thoracic sympathectomy, but 1 h after the block it returned to the same level as before the block. The mandibular block, however, induced no significant change in the  $SD_{RR}:SD_{\sigma RR}$  ratio (fig. 2). The 95% confidence intervals of the  $SD_{RR}:SD_{\sigma RR}$  ratios were 1.03 to 2.17, 0.98 to 1.57, and 1.10 to 1.86, respectively, in the thoracic sympathectomy group.

There were no significant differences in heart rate, systolic blood pressure, and the  $SD_{RR}:SD_{\sigma RR}$  ratio between the right and the left thoracic sympathectomies.

#### Second Sympathectomy in the Index Case

After injection of 1.5 ml 99.5% alcohol, the heart rate decreased suddenly from 82 to 22 beats/min just after the injection and then gradually increased. The systolic blood pressure decreased from 149 to 73 mmHg (fig. 2). We injected 0.5 mg atropine sulfate 3 min after the alcohol injection and transferred the patient into the consultation room. Heart rate and systolic blood pressure returned to 77 beats/min and 100 mmHg, respectively, 1 h after the injection. She was discharged 2 h later after we confirmed the stabilization of her blood pressure and heart rate in both the supine and upright positions. She had a warm sensation at her right chest again, and her chest pain was reduced.

The  $SD_{RR}:SD_{\sigma RR}$  ratio of the patient decreased from 3.45 to 0.83 just after the alcohol injection, and the decrease was kept to 0.67 even 1 h after the injection (fig. 2). The  $SD_{RR}:SD_{\sigma RR}$  ratio before the injection was above the 95% confidence intervals in the thoracic sympathectomy group, and both values of the  $SD_{RR}:SD_{\sigma RR}$  ratios just before and 1 h after the injection were less than the 95% confidence intervals. Heart rate and systolic blood pressure in the patient were less than the 95% confidence intervals only just after the injection.

Figure 3 shows the Poincaré patterns of the patient we described here. The Poincaré plot assumed an elongated pattern before the alcohol injection, and it assumed an oval-shaped pattern just before and 1 h after the injection.

#### Discussion

In a traditional technique of power spectrum analysis of heart rate variability, the presence of ectopic beats can introduce mathematical artifacts and prevents accu-

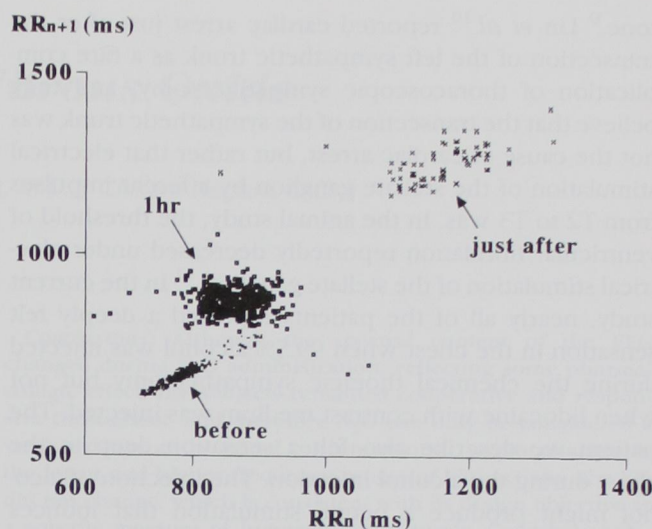


Fig. 3. Poincaré plots of the patient we described in the case report before (dot), just after (cross), and 1 h after (square) the injection of 99.5% alcohol during the second thoracic sympathectomy.

rate determination of heart rate variability.<sup>3</sup> Analysis of heart rate variability using a Poincaré plot is more resistant to the influence of ectopic beats and other arrhythmias,<sup>3</sup> so we used it to evaluate cardiac autonomic function during severe bradycardia in the patient we described. The increase in the  $SD_{RR}:SD_{\sigma RR}$  ratio is a quantified value of an elongated Poincaré plot pattern, which has been observed in patients with heart failure and high sympathetic tone,<sup>8</sup> and it has also been observed after intravenous atropine injection in healthy humans, which induces a predominant cardiac sympathetic activity over cardiac parasympathetic activity.<sup>6</sup> In the current study, thoracic sympathectomy decreased the  $SD_{RR}:SD_{\sigma RR}$  ratio, but mandibular block did not. We suppose that a high  $SD_{RR}:SD_{\sigma RR}$  ratio in the reported case might indicate high cardiac sympathetic activity before the sympathectomy.

Bradycardia occurred in our patient after the alcohol injection but not after a previous thoracic epidural anesthetic or after the injection of lidocaine with radiopaque contrast medium. Furthermore, heart rate 1 h after the injection in our patient was within the 95% confidence intervals of the thoracic sympathectomy group, although the  $SD_{RR}:SD_{\sigma RR}$  ratio at that time was less than the 95% confidence intervals. Therefore, sympathetic block was not the primary cause of bradycardia.

Bilateral thoroscopic sympathectomy of T2, T3, or T4 is an effective treatment for essential hyperhidrosis and also causes the reduction of cardiac sympathetic



tone.<sup>9</sup> Lin *et al.*<sup>10</sup> reported cardiac arrest just after the transection of the left sympathetic trunk as a rare complication of thoracoscopic sympathicotomy, and they believe that the transection of the sympathetic trunk was not the cause of cardiac arrest, but rather that electrical stimulation of the stellate ganglion by afferent impulses from T2 to T3 was. In the animal study, the threshold of ventricular fibrillation reportedly decreased under electrical stimulation of the stellate ganglion.<sup>11</sup> In the current study, nearly all of the patients reported a deeply felt sensation in the chest when 99.5% alcohol was injected during the chemical thoracic sympathectomy but not when lidocaine with contrast medium was injected. The patient we describe also felt a sensation deep in the chest during the alcohol injection. The injection of alcohol might produce a neural stimulation that induces profound bradycardia.

There were no significant differences in heart rate, systolic blood pressure, and the  $SD_{RR}:SD_{\Delta RR}$  ratio between the right and left thoracic sympathectomies. Lown and Verrier<sup>11</sup> reported that the threshold of ventricular fibrillation after the stimulation of the right stellate ganglion was the same as that of the left stellate ganglion in a canine study. On the other hand, other investigators reported that right and left cardiac sympathetic nerves had different effects on cardiac excitability in a canine study.<sup>12</sup>

In conclusion, we tried to determine the cause of severe bradycardia after chemical thoracic sympathectomy in a patient with post-herpetic neuralgia using the Poincaré diagram to plot heart rate variability. We suggest that high cardiac sympathetic tone before chemical thoracic sympathectomy is a predictive sign of bradycardia just after the injection of 99.5% alcohol. Although cardiovascular function is usually stable during and after chemical thoracic sympathectomy, the possibility of se-

vere bradycardia should be considered when chemical thoracic sympathectomy is performed.

## References

1. Tingle L: Thoracic sympathetic block, *Decision Making in Pain Management*. Edited by S Ramamurthy, JN Rogers. St. Louis, Mosby Year Book, 1993, pp 244-5
2. Ellison JP, Williams TH: Sympathetic nerve pathways to the human heart, and their variations. *Am J Anat* 1969; 124:149-62
3. Kamen PW, Tonkin AM: Application of the Poincaré plot to heart rate variability: A new measure of functional status in heart failure. *Aust N Z J Med* 1995; 25:18-26
4. Stanton-Hicks M, Höck A, Stühmeier K-D, Arndt JO: Venoconstrictor agents mobilize blood from different sources and increase intrathoracic filling during epidural anesthesia in supine humans. *ANESTHESIOLOGY* 1987; 66:317-22
5. Harn MB: Distributions of the trigeminal nerve, *Regional Anesthesia: An Atlas of Anatomy and Techniques*. Edited by Harn MB, McQuillan PM, Sheplock GJ. St. Louis, Mosby, 1996, pp 45-52
6. Tulppo MP, Mäkilä TH, Takala TES, Seppänen T, Huikuri HV: Quantitative beat-to-beat analysis of heart rate dynamics during exercise. *Am J Physiol* 1996; 271:H244-52
7. Malik M, Camm AJ: Components of heart rate variability—What they really mean and what we really measure. *Am J Cardiol* 1993; 72:821-2
8. Woo MA, Stevenson WG, Moser DK, Trelease RB, Harper RM: Patterns of beat-to-beat heart rate variability in advanced heart failure. *Am Heart J* 1992; 123:704-10
9. Noppen M, Dendale P, Hagers Y, Herregodts P, Vincken W, D'Haens JD: Changes in cardiocirculatory autonomic function after thoracoscopic upper dorsal sympathicotomy for essential hyperhidrosis. *J Auton Nerv Syst* 1996; 60:115-20
10. Lin C-C, Mo L-R, Hwang M-H: Intraoperative cardiac arrest: A rare complication of T2,3-sympathicotomy for treatment of hyperhidrosis palmaris. *Eur J Surg* 1994; 152(suppl):43-5
11. Lown B, Verrier RL: Neural activity and ventricular fibrillation. *N Engl J Med* 1976; 294:1165-71
12. Schwartz PJ, Snebold NG, Brown AM: Effects of unilateral cardiac sympathetic denervation on the ventricular fibrillation threshold. *Am J Cardiol* 1976; 37:1034-40