

CASE REPORTS

45 min for the pupillary dilation to take place. Microdrops could be used in infants to provide a lower risk of systemic action with comparable local effectiveness.^{13,14} All this would help to avoid an absolute overdosage of a substance whose systemic absorption is often underestimated and can never be predicted exactly.

References

1. Adler AG, McElwain GE, Merli GJ, Martin JM: Systemic effects of eye drops. *Arch Intern Med* 1982; 142:2293-4
2. Palmer EA: How safe are ocular drugs in pediatrics? *Ophthalmology* 1986; 93:1038-40
3. Rosales T, Isenberg S, Leake R, Everett S: Systemic effects of mydriatics in low weight infants. *J Pediatr Ophthalmol Strabismus* 1981; 18:42-4
4. Heath P: Neosynephrine hydrochloride, some uses and effects in ophthalmology. *Arch Ophthalmol* 1936; 16:839-46
5. VanDerSpek AFL, Hantler CB: Phenylephrine eyedrops and anesthesia. *ANESTHESIOLOGY* 1986; 64:812-4
6. Singh PP, Dimich I, Shamsi A: Intraoperative pulmonary oedema in a young cocaine smoker. *Can J Anaesth* 1994; 41:961-4
7. Miller SA, Mieler WF: Systemic reaction to subconjunctival phenylephrine. *Can J Ophthalmol* 1978; 13(4):290-3
8. Ferrari W, Baggio G, Guarini S: Studies on epinephrine-induced lung edema in the rat. I. Selective alpha 1-adrenoceptor involvement. *Arch Int Pharmacodyn Ther* 1986; 281(1):89-99
9. Tajima K, Sato S, Miyabe M: A case of acute pulmonary edema and bulbar paralysis after local epinephrine infiltration. *J Clin Anesth* 1997; 9(3):236-8
10. Clifford C, Choy M: Cardiomyopathy induced by phenylpropanolamine. *J Pediatr* 1993; 123:825-7
11. Salminen L: Review: systemic absorption of topically applied ocular drugs in humans. *J Ocul Pharmacol* 1990; 6(3):243-9
12. Gilman AG, Goodman LS, Gilman A: *The Pharmacological Basis of Therapeutics*, 9th Edition. New York, McGraw-Hill 1996, pp 1625-8
13. Wheatcroft S, Sharma A, McAllister J: Reduction in mydriatic drop size in premature infants. *Br J Ophthalmol* 1993; 77(6):364-5
14. Gray RH: The influence of drop size on pupil dilatation. *Eye* 1991; 5(5):615-9

Anesthesiology
1998; 88:1396-9

© 1998 American Society of Anesthesiologists, Inc.
Lippincott-Raven Publishers

Endovascular Aortic Balloon Clamp Malposition during Minimally Invasive Cardiac Surgery: Detection by Transcranial Doppler Monitoring

Hilary P. Grocott, M.D., F.R.C.P.C.,* Mark Stafford Smith, M.D., F.R.C.P.C.,† Donald D. Glower, M.D.,‡
Fiona M. Clements, M.D.§

MINIMALLY invasive cardiac surgery for coronary artery bypass grafting (CABG) and cardiac valve repair or replacement is a rapidly expanding field in cardiothoracic surgery.¹⁻³ Although it offers potential advantages to the patient and the health-care system, including improved

cosmetic results, reduced pain, shorter hospital stays, and an earlier return to normal activity,⁴ it is not without its own risks.

We report a case of a temporary reduction in cerebral perfusion, detected by transcranial Doppler (TCD), resulting from endovascular aortic balloon clamp malposition during minimally invasive mitral valve surgery. Monitoring strategies to detect endoaortic clamp malposition are discussed.

Case Report

A 51-yr-old man, with preserved left ventricular function and severe mitral regurgitation resulting from myxomatous degeneration, was scheduled to undergo mitral valve repair using a minimally invasive port-access system.

The use of a catheter-based endovascular cardiopulmonary bypass (CPB) system (EndoCPB system; Heartport Inc., Redwood City, CA)

* Associate, Department of Anesthesiology.

† Assistant Professor, Department of Anesthesiology.

‡ Associate Professor, Department of Surgery.

§ Associate Professor, Department of Anesthesiology.

Received from the Duke Heart Center, Duke University Medical Center, Durham, North Carolina. Submitted for publication September 3, 1997. Accepted for publication December 29, 1997.

Address reprint requests to Dr. Grocott: Department of Anesthesiology, Box 3094, Duke University Medical Center, Durham, North Carolina, 27710. Address electronic mail to: groco001@mc.duke.edu

Key words: Cerebral perfusion; complication; port access.

CASE REPORTS

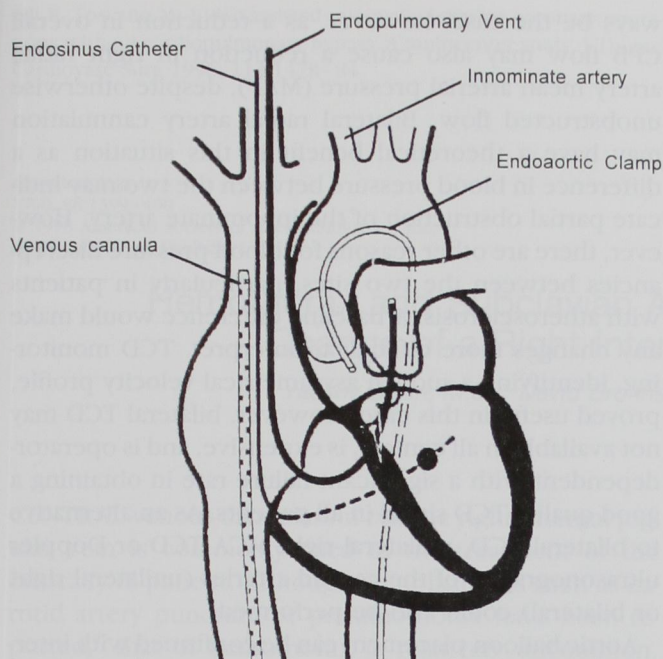


Fig. 1. Diagram of the endocardiopulmonary bypass system identifying, in addition to the various intracardiac catheters, the ascending aorta and arch showing the normal position of the endoaortic clamp. In this case report, distal migration of the aortic balloon clamp partially obstructed the innominate artery, causing a reduction in transcranial Doppler blood flow velocity in the right middle cerebral artery. (Reprinted from Siegel *et al.*⁸, with permission.)

was planned for closed-chest CPB. This system (fig. 1) consists of a set of catheters, including femoral arterial (endoarterial return cannula), venous, coronary sinus (endosinus catheter), pulmonary artery vent (endopulmonary vent), and aortic balloon occlusion clamp (endoaortic clamp), and allows complete femoral bypass, aortic clamping, and antegrade (*via* a port on the aortic balloon clamp) and retrograde (*via* the coronary sinus catheter) cardioplegia. Venous drainage is increased using a centrifugal pump and additionally assisted with a multiorificated pulmonary artery vent.

After establishment of intravenous access and placement of a right radial arterial cannula, anesthesia was induced, and endotracheal intubation was achieved using a No. 39 left-sided, double-lumen endotracheal tube. Under fluoroscopic and transesophageal echocardiographic (TEE) guidance, the coronary sinus catheter and pulmonary artery vents were positioned. Bilateral TCD monitoring (Neurogard; Medasonics Inc., Fremont, CA) was established using two 2-MHz, pulsed-wave TCD probes with 18-mm sample lengths, gated at constant depths (range, 45–55 mm) secured to the head with a circumferential harness. TCD insonation of the left and right middle cerebral arteries (MCA), which is routinely used on our port-access heart surgery patients, demonstrated pulsatile flow of equivalent magnitude.

Surgery proceeded with a right anterolateral minithoracotomy to expose the heart and cutdowns for the placement of the femoral CPB cannula. After CPB commenced, the endoaortic clamp was advanced into the ascending aorta and positioned using fluoroscopic

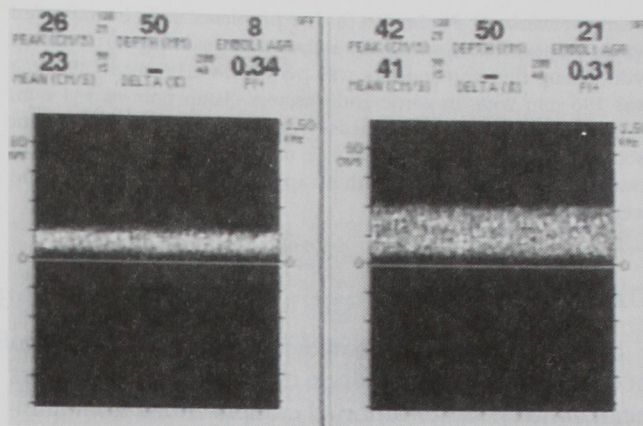


Fig. 2. Transcranial Doppler image of right and left middle cerebral arteries showing asymmetric blood flow velocity. The peak and mean velocities in the right middle cerebral artery are substantially reduced compared with the left caused by a reduction in perfusion as a result of the endovascular aortic balloon clamp partially occluding the innominate artery.

and TEE guidance. Non-pulsatile hypothermic (28°C) CPB was used with flows of 1.9–2.4 l·min⁻¹·m⁻². Arterial blood gases were managed using α -stat methodology (PaO₂, 148–187 mmHg; PaCO₂, 37–41 mmHg).

Before cardioplegic arrest, the CPB flow was briefly decreased, and the endoaortic clamp was inflated. On restoration of normal CPB flow, the right radial arterial pressure remained low (less than 30 mmHg), and the TCD monitor demonstrated an asymmetric pattern (fig. 2) with a marked reduction in right middle cerebral artery blood flow velocity (V_{mca}). TEE imaging confirmed a malposition of the endovascular aortic balloon clamp with obstruction of the innominate artery. CPB flow was again briefly decreased, and the balloon clamp deflated, repositioned (advanced slightly toward the aortic valve), and reinflated, with restoration of a normal right V_{mca} when full CPB flow resumed (fig. 3). The duration of reduced right V_{mca}

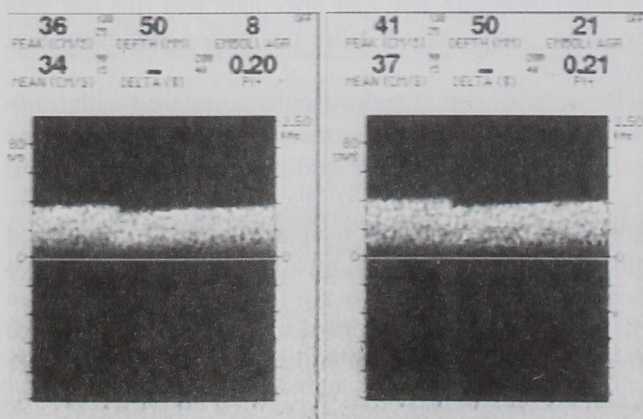


Fig. 3. Normal transcranial Doppler image showing symmetrical flow through both middle cerebral arteries after the aortic balloon clamp was repositioned (moved proximally).

CASE REPORTS

was approximately 2 min. No further problems were encountered during surgery, and a successful mitral valve quadrangular resection with sliding ring annuloplasty was performed. The total CPB time was 196 min with an aortic endovascular clamp time of 134 min. Cardiopulmonary bypass was easily discontinued, and the patient was transferred to the intensive care unit after surgery. The patient awakened 4 h after surgery with no apparent neurologic deficit and recovered uneventfully.

Discussion

This case outlines a potentially serious complication of endovascular aortic balloon clamp use for port-access heart surgery. Other reported complications from minimal access cardiac surgery have included wound infection,⁵ pulmonary complications,⁵ early recurrent ischemia caused by anastomotic stenosis or other vascular obstruction,⁶ sinus node dysfunction,⁴ and low postoperative cardiac output.⁷ This is the first full description of endovascular aortic balloon clamp migration leading to temporary obstruction of cerebral blood vessels (although it is briefly mentioned as a complication in a recent article describing this procedure).⁸

Prompt detection with TCD (by a sudden reduction in V_{mca}) alerted us to this potentially serious problem. TEE imaging helped confirm the catheter malposition. TEE, however, may have difficulty identifying the position of the catheter in relationship to the aortic arch vessels because of imaging artifacts resulting from the interposition of the left mainstem bronchus between the esophagus and aortic arch. The use of combined monitoring modalities (TCD and TEE) allowed quick correction and rapid assessment of cerebral perfusion. Although it is unclear in this case whether temporary obstruction of the aortic arch vessels resulted in any cerebral ischemia, one may speculate that this risk was possible, particularly if more prolonged occlusion had occurred.

The relative risk of endovascular compared with traditional externally applied aortic clamping has yet to be defined. The risks of the endovascular balloon clamp may not only be limited to vascular malposition, as the potential for embolization of aortic plaque dislodged during balloon placement, inflation, and deflation is also possible.

As minimally invasive cardiac surgery continues to increase in popularity, monitoring practice guidelines will be developed.⁸ Several monitoring combinations could allow diagnosis of potential problems. The use of a right radial arterial cannula should facilitate detection of innominate artery obstruction. This may not al-

ways be the case, however, as a reduction in overall CPB flow may also cause a reduction in right radial artery mean arterial pressure (MAP), despite otherwise unobstructed flow. Bilateral radial artery cannulation may have a theoretical benefit in this situation as a difference in blood pressure between the two may indicate partial obstruction of the innominate artery. However, there are other reasons for blood pressure discrepancies between the two sites, particularly in patients with atherosclerosis. A baseline difference would make any changes more difficult to interpret. TCD monitoring, identifying a sudden asymmetrical velocity profile, proved useful in this case. However, bilateral TCD may not be available in all centers, is expensive, and is operator-dependent with a significant failure rate in obtaining a good quality TCD signal in all patients. As an alternative to bilateral TCD, unilateral right MCA TCD or Doppler ultrasonography of the carotid arteries (unilateral right or bilateral) could also be performed.

Aortic balloon placement can be confirmed with intermittent TEE or fluoroscopy. The combined use of fluoroscopy, TEE, TCD/carotid Doppler, and right (or bilateral) radial arterial cannula may allow early detection of malposition or migration with possible prevention of cerebral ischemia. Electroencephalography (EEG) might also be used to identify arterial obstruction with the onset of a cerebral ischemic EEG changes. However, availability and the need for qualified interpretation limit its usefulness. Although several monitoring modalities can be used, alone or in combination, firm recommendations on the best strategies must await prospective evaluations.

References

1. Cosgrove D, Sabik J: Minimally invasive approach for aortic valve operations. *Ann Thorac Surg* 1996; 62:596-7
2. Calafiore A, Angelini G, Bergsland J, Salerno T: Minimally invasive coronary artery bypass grafting. *Ann Thorac Surg* 1996; 62:1545-8
3. Fann J, Reitz B, Burdon T, St. Goar F, Siegel L, Stevens J, Pompili M: Port-access cardiac operations with cardioplegic arrest. *Ann Thorac Surg* 1997; 63(Suppl):S35-9
4. Navia J, Cosgrove D: Minimally invasive mitral valve operations. *Ann Thorac Surg* 1996; 62:1542-4
5. Landreneau R, Mack M, Magovern J, Acuff T, Benckart D, Sakert T, Fetterman L, Griffith B: "Keyhole" coronary artery bypass surgery. *Ann Surg* 1996; 224:453-9
6. Robinson M, Gross D, Zeman W, Stedje-Larsen E: Minimally invasive coronary artery bypass grafting: A new method using an anterior mediastinotomy. *J Card Surg* 1995; 10:529-36
7. Bennetti F, Mariani M, Sani G, Boonstra P, Grandjean J, Giomar-

CASE REPORTS

elli P, Toscano M: Video-assisted minimally invasive coronary operations without cardiopulmonary bypass: A multicenter study. *J Thorac Cardiovasc Surg* 1996; 112:1478-84

8. Siegel L, St. Goar F, Stevens J, Pompili M, Burdon T, Reitz B, Peters W: Monitoring considerations for port-access cardiac surgery. *Circulation* 1997; 96:562-8

Anesthesiology
1998; 88:1399-400
© 1998 American Society of Anesthesiologists, Inc.
Lippincott-Raven Publishers

Hemothorax and Subclavian Artery Laceration during "J" Wire Change of a Right Internal Jugular Vein Catheter

Yaakov Beilin, M.D.,* David Bronheim, M.D.,* Chaim Mandelbaum, M.D.†

CENTRAL venous cannulation *via* the right internal jugular vein is commonly used in the treatment of the critically ill patient. Although complications such as carotid artery puncture or pneumothorax have been reported,¹ that of hemothorax is relatively uncommon. We describe a case of a hemothorax and subclavian artery laceration that was recognized while changing an 8.5-French introducer to a 7.0-French triple-lumen catheter using a "J" wire.

Case Report

A 47-yr-old man presented for emergent cadaveric kidney transplantation. After induction of anesthesia, an arterial cannula was placed in the right radial artery, and the right internal jugular vein was cannulated using the Seldinger technique. The vein was initially located without problem with a 22-gauge "finder" needle at the apex of the triangle formed by the two bellies of the sternocleidomastoid muscle and the clavicle. The vessel was then cannulated with a 2-inch long 18-gauge intravenous catheter. Blood flowing from the 18-gauge intravenous catheter was dark and nonpulsatile. A 0.035-inch "J"-tip guide wire was threaded through the 18-gauge catheter without problem, and an 8.5-French introducer (Arrow®, Reading, PA) was threaded over the wire. To confirm placement, blood was aspirated from the introducer; the blood was nonpulsatile and dark. The

catheter was connected to a pressure transducer and monitor system, and the central venous pressure (CVP) was approximately 11 mmHg with respiratory variation. Although the introducer was mainly used for CVP monitoring, it also was used for the administration of fentanyl and vecuronium for about 30 min after placement. The administration of these drugs led to paralysis of the patient as documented with a neuromuscular blockade monitor, and the patient appeared more deeply anesthetized as noted by a decrease in blood pressure and heart rate. Peak airway pressure of 30 cm H₂O was stable throughout the case. The morphology of the arterial wave form from the arterial line appeared normal and remained the same throughout the case. A hematocrit sampled 1 h before the end of the procedure was 42%.

As the patient had a need for CVP monitoring postoperatively, at the end of the procedure, the 8.5-French introducer was changed to a 7-French triple-lumen catheter (TLC) (Arrow® Reading, PA). The patient was placed in the Trendelenburg position, and a 0.035-inch "J"-tip guide wire, from the 7-French CVP kit, was inserted through the introducer without resistance or arrhythmia, and the introducer was withdrawn. Hemodynamic compromise ensued over a period of 30-60 s with a decrease in arterial blood pressure to 40/30 mmHg, and the end-tidal carbon dioxide tension decreased from 35 to 22 mmHg. He was treated through the peripheral intravenous catheter with fluids and vasopressors, which increased the blood pressure to 100/50 mmHg for a brief period. The TLC was quickly inserted over the guide wire, and neither blood nor air could be aspirated from the TLC. No end-tidal nitrogen was noted by mass spectrometry. Physical examination revealed decreased breath sounds over the right hemithorax to auscultation, and a 16-gauge intravenous catheter was inserted into the second intercostal space to treat a possible tension pneumothorax. Because the hemodynamic status continued to deteriorate, a 30-French chest tube was inserted into the right chest, and 300 cc of blood were drained. A right thoracotomy and sternotomy was performed to identify the source of the bleeding. More than 2000 cc of clotted blood was removed from the right hemithorax. The tip of the TLC was noted in the pleural space, having entered the subclavian artery superiorly and exited inferiorly just lateral to the junction with the carotid artery. Extensive bleeding was noted from the holes in the subclavian artery, both of which were larger than the 7-French TLC. No holes were noticed in either the subclavian vein or superior vena cava. Cardiac arrest ensued requiring chest compressions and cardioversion for ventricular tachycardia along

* Assistant Professor.

† Resident.

Received from the Department of Anesthesiology, Mount Sinai School of Medicine, New York, New York. Submitted for publication October 24, 1997. Accepted for publication December 30, 1997.

Address reprint requests to Dr. Beilin: The Mount Sinai Medical Center, Department of Anesthesiology, Box 1010, One Gustave L. Levy Place, New York, New York 10029-6574. Address electronic mail to: ybeilin@smtplink.mssm.edu

Key words: Central venous cannulation; complications; internal jugular vein.