

## CASE REPORTS

Anesthesiology  
1998; 88:263-5  
© 1998 American Society of Anesthesiologists, Inc.  
Lippincott-Raven Publishers

### Perioperative Severe Rhabdomyolysis Revealing Susceptibility to Malignant Hyperthermia

Lisiane Fierobe, M.D.,\* Yves Nivoche, M.D.,† Jean Mantz, M.D., Ph.D.,‡ Younes Elalaoui, M.D.,§ Benoit Veber, M.D.,\* Jean-Marie Desmots, M.D.‡

SEVERE rhabdomyolysis can lead to life-threatening complications.<sup>1,2</sup> Here, we report the case of a patient aged 26 yr who developed an extremely severe perioperative rhabdomyolysis followed by an uneventful recovery. Subsequent evaluation revealed positive caffeine and halothane contracture tests, suggesting that this event may have been an unusual manifestation of malignant hyperthermia (MH).

#### Case Report

A 26-yr-old man with an accidental amputation of three fingers of the left hand was admitted for emergency surgical reimplantation. At preoperative examination, he appeared to be ASA I physical status, did not take any medication, drank no alcohol, and had never been anesthetized. There was no history of personal or familial disease. After administration of amoxicillin and clavulanic acid (2 g), anesthesia was induced with thiopental (4 mg/kg) and succinylcholine (1 mg/kg), the trachea was orally intubated, and the lungs were mechanically ventilated at 8.4 l/min with an O<sub>2</sub>-N<sub>2</sub>O:40%/60% mixture. Anesthesia was maintained with additional doses of fentanyl (1 μg·kg<sup>-1</sup>·h<sup>-1</sup>) and isoflurane (end-tidal concentration, 0.6-1.1%). Heart rate, noninvasive blood pressure, pulse oximetry, end-tidal CO<sub>2</sub> and isoflurane concentrations, esophageal temperature, capillary hemoglobin concentrations, and urine output were monitored. During the procedure, a tourniquet was applied to the upper part of the left arm and inflated for 35 min and then for 55 min after a 10-min removal. Twenty minutes after intubation, the surgeon noted some rigidity of the left arm. This stiffness was poorly improved by vecuronium (7 mg), which was administered 20 min before the tourniquet inflation. Hypotension (systolic blood pressure of 80 mmHg) and sinus tachycardia (130 beat/min) occurred during the fifth hour of surgery.

\* Assistant Professor of Anesthesiology, Hospital Bichat.

† Professor of Anesthesiology, Hôpital Robert Debré.

‡ Professor of Anesthesiology, Hospital Bichat.

§ Staff Anesthesiologist, Hospital Bichat.

Received from the Department of Anesthesiology and Critical Care, Hospital Bichat and Department of Anesthesiology, Hôpital Robert Debré, Paris, France. Submitted for publication November 19, 1996. Accepted for publication April 9, 1997.

Address reprint requests to Dr. Fierobe: Department of Anesthesiology and Critical Care, Hospital Bichat, 46 rue Henri Huchard, 75018 Paris, France.

Key words: Anesthesia; hyperthermia; massive muscle breakdown.

These symptoms were interpreted as indicative of hypovolemia as a result of substantial blood loss (hemoglobin level of 7 g/dl at this moment of the operation), and the patient received crystalloids (6000 ml), colloids (2000 ml), and packed red cells (6 U). Fresh frozen plasma (5 units) was further administered because of diffuse bleeding occurring during the final part of the operation. Esophageal temperature remained between 36.3 and 37.4°C, end-tidal CO<sub>2</sub> concentrations between 29 and 36 mmHg, and urine output was 200 ml/h. After the surgical procedure (9-h duration), the patient was discharged from the operating room, and the trachea was extubated.

On arrival in the recovery room, the urine was noted to have a red color. The blood hemoglobin level was 10.9 g/dl; the platelet count was at 97,000/mm<sup>3</sup>; the prothrombin time was 64%, and the activated partial thromboplastin time was 39/33 s. The patient complained of severe myalgias of the thighs and was unable to move his legs. Rectal temperature was 38°C. Results of the electrocardiograph and chest radiograph were normal. Investigations revealed the presence of an extremely severe rhabdomyolysis as assessed by the extremely high plasma creatine phosphokinase (CPK) levels performed 8 h after the operation (table 1). The patient was questioned again in detail about his personal and familial history. He had regularly practiced strenuous sport until recently, but he denied having experienced either myoglobinuria or abnormal myalgia. Also, there was no history suggesting neuromuscular disease in the family.

The patient was admitted in the surgical critical care unit and was treated with fluids, sodium bicarbonate for urine alkalinization, and furosemide. The outcome was satisfactory, with a rapid decrease of the blood levels of muscular enzymes (table 1). The patient did not develop renal failure and was discharged from the critical care unit after 1 week.

Three months later, he had a biopsy from the vastus lateralis muscle during local anesthesia. Fresh frozen cross-section of muscle tissue were stained with Hematoxylin and eosin, Gomori trichrome, and Schiff periodic acid, and Sudan black B. sections were also studied for myofibrillar ATPase at routine pH 9.4 for oxidative activity (SDH, succinic dehydrogenase; NADH-TR, NADH tetrazolium-reductase, α-GPD) and for phosphorylase activity. These histologic and histoenzymatic examinations did not show any features supportive of myopathy or metabolic disease. The *in vitro* contracture tests were performed according to the European Malignant Hyperthermia Group protocol.<sup>3</sup> The results showed the presence of MH susceptibility (MHS) as assessed by a significant contracture response to caffeine (2 mm) and halothane (2% and 3%) exposure (fig. 1). The muscle strip of the vastus lateralis exhibited a 0.30 g contracture at 2 mm caffeine and a 0.55 g and 0.9 g contracture at 2% and 3% halothane exposure, respectively. The last muscle strip was exposed directly to a 3% halothane concentration and showed a 0.6 g contracture.

#### Discussion

This observation depicts the case of an extremely severe rhabdomyolysis diagnosed during the early postoperative

## CASE REPORTS

Table 1. Results of Clinical Laboratory Tests

	Normal	Day 1†	Day 3	Day 4	Day 5	Day 6	Day 9	Day 22	3 mo
CPK	<195 IU/L	384,000	217,400	130,900	39,350	9,295	4,056	285	253
ALAT	<56 IU/L	1,000	671	705	544	362	340	152	23
Myoglobinemia	<100 µg/L	55,000	3,100	2,200	1,560	390	160	90	ND
Serum potassium	mM	3.9	3.7	3.9	3.7	4.9	3.7	3.9	ND
Serum creatinine	40–100 µM	112	92	90	75	64	79	90	ND
Myoglobinuria*	0	+++	++	++	+	+	0	0	ND

CPK = serum creatine phosphokinase; ALAT = serum alanine aminotransferase; ND = not done; + = mild; ++ = moderate; +++ = severe.

\* Myoglobinuria is measured using a semi-quantitative method.

† Results on day 1 were obtained 8 h after the operation.

period after a 9-h anesthesia. To our knowledge, such a massive perioperative rhabdomyolysis followed by complete recovery has not been reported previously in an

adult.<sup>1,2,4</sup> Several hypotheses can be proposed to explain the rhabdomyolysis observed in the present case: a crush syndrome cannot be considered because no traumatic lesion was present, and postural complications were prevented in the operating room. Rhabdomyolysis was probably not favored by the tourniquet because it was inflated for only 35 and 55 min, respectively. The patient had taken neither any toxic (cocaine, alcohol) nor medication (antiarrhythmic agent, salicylate, theophyllin, antibiotics) before the operation that could have triggered rhabdomyolysis. Rhabdomyolysis can also be observed in different inherited neuromuscular disorders such as central core disease, Duchenne muscular dystrophy, King-Denborough syndrome, and a deficiency in carnitine palmityl transferase.<sup>5,6</sup> However, the age of the patient, the personal and familial history, the severity of the observed rhabdomyolysis, the subnormal blood levels of CPK 3 months after the episode, and the normal histologic findings at the muscular biopsy do not support the hypothesis of a myopathy.

Several lines of evidence suggest that the diagnosis of susceptibility to MH was the most likely: anesthesia was induced with succinylcholine and maintained with isoflurane, both agents known to trigger a MH crisis in MHS patients. Also, the extreme severity of the rhabdomyolysis with CPK blood levels higher than 20,000 U/l<sup>5</sup> and the unequivocal positivity of the *in vitro* contracture tests support the diagnosis of susceptibility to MH.<sup>3,6,7</sup> Interestingly, in the present case, rhabdomyolysis appeared to be the main symptom revealing MHS. It is worthy to note that neither an abnormal increase in end-tidal CO<sub>2</sub> levels or hyperthermia was observed intraoperatively. According to the grading scale published by Larach *et al.*,<sup>8</sup> the present patient has a 18 score (group 3). This value is based on the association of an unexplained intraoperative tachycardia and a myoglobinuria. Despite the fact that muscle breakdown is a major criterion for the diagnosis of a severe MH crisis,<sup>5,8,9</sup> MHS in this patient was somewhat less than

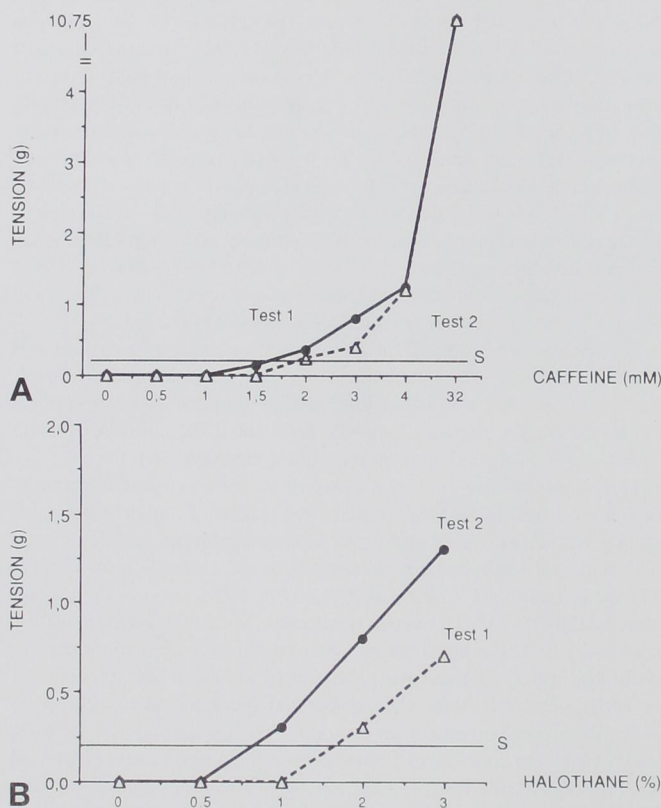


Fig. 1. Results of *in vitro* contracture tests performed according to the European Malignant Hyperthermia protocol. The response is considered to be significantly positive (S) if the muscle strips sustain a contracture of more than 0.2 g above the baseline tension after exposure to 2 mM of caffeine and to 2% halothane. (A) *In vitro* contracture response of two distinct muscle strips to caffeine exposure at 2 mM. (B) *In vitro* contracture response of two distinct muscle strips to 2% and 3% halothane exposure.

## CASE REPORTS

likely.<sup>8</sup> Despite the severity of rhabdomyolysis in the present case, no cardiac dysrhythmia leading to cardiac arrest and no acute renal failure occurred. This result is particularly uncommon because less severe cases of rhabdomyolysis related to MH have been reported to lead to cardiac arrest or to require renal extracorporeal euration.<sup>1,2</sup>

The diagnosis of MHS was suspected in the early postoperative period, and the administration of dantrolene was discussed in the recovery room. Dantrolene decreases the intensity of the contractures of skeletal muscles and reduces hypermetabolism by inhibiting the release of calcium from intracellular stores. The efficacy of dantrolene to lower CPK blood levels has been suggested in children with masseter muscle spasm, but it remains uncertain in adults.<sup>10</sup> Therefore, dantrolene was available but not given immediately to our patient, in the absence of life-threatening cardiac episode or uncontrolled hypermetabolism. In the present case, the prompt diagnosis of myoglobinuria, the early fluid challenge, and the forced diuresis avoided dialysis and cardiac complications.

In summary, this case emphasizes that MHS may be revealed by an almost isolated and extremely severe rhabdomyolysis. Under such circumstances, dantrolene has to be available, and appropriate fluid loading with forced diuresis may be helpful to prevent life-threatening organ failures. In a second step, a patient with perioperative rhabdomyo-

lysis or isolated myoglobinuria needs to be investigated for MHS after full recovery.

## References

1. Acquarone N, Garibotto G, Tegazzin V, Sofia A, Gurreri G: Post-anesthetic myoglobinuric renal failure: An isolated expression of malignant hyperthermia. *Nephrol Dial Transplant* 1994; 9:567-8
2. Schaer H, Steinmann B, Jerusalem S, Maier C: Rhabdomyolysis induced by anaesthesia with intraoperative cardiac arrest. *Br J Anaesth* 1977; 49:495-9
3. European Malignant Hyperpyrexia Group: A protocol for the investigation of malignant hyperpyrexia susceptibility. *Br J Anaesth* 1984; 56:1267-9
4. Birmingham PK, Stevenson GW, Uejima T, Hall SC: Isolated postoperative myoglobinuria in a pediatric outpatient: A case report of malignant hyperthermia. *Anesth Analg* 1989; 69:846-9
5. Rosenberg H: Clinical presentation of malignant hyperthermia. *Br J Anaesth* 1988; 60:268-73
6. Brownell AKW: Malignant hyperthermia: Relationship to other disease. *Br J Anaesth* 1988; 60:303-8
7. Heytens L, Martin JJ, Van De Kelft E, Bossaert LL: In vitro contracture tests in patients with various neuromuscular diseases. *Br J Anaesth* 1992; 68:72-5
8. Larach MG, Localio AR, Allen G, Denborough MA, Ellis FR, Gronert GA, Kaplan RF, Muldoon SM, Nelson TE, Ording H, Rosenberg H, Waud BE, Wedel DJ: A clinical grading scale to predict malignant hyperthermia susceptibility. *ANESTHESIOLOGY* 1994; 80:771-9
9. Harriman DGF: Malignant hyperthermia myopathy. *Br J Anaesth* 1988; 60:309-16
10. Littleford JA, Patel RL, Bose D, Cameron CalB, McKillop C: Masseter Muscle Spasm in Children: Implications of continuing the triggering anesthetic. *Anesth Analg* 1991; 72:151-60

Anesthesiology  
1998; 88:265-8  
© 1998 American Society of Anesthesiologists, Inc.  
Lippincott-Raven Publishers

## Massive Postoperative Rhabdomyolysis after Uneventful Surgery: A Case Report of Subclinical Malignant Hyperthermia

Timothy N. Harwood, M.D.,\* Thomas E. Nelson, Ph.D.†

MALIGNANT hyperthermia (MH) is generally thought of in its fulminant form, manifesting as severe hypercapnia,

uncontrollable hyperthermia, and accompanied by hyperkalemia with cardiac dysrhythmias. We report a case of an adult surgical patient who developed severe postoperative rhabdomyolysis without other symptoms and who was subsequently found by muscle biopsy to be MH susceptible.

\* Assistant Professor, Department of Anesthesia.

† Professor, Department of Anesthesia.

Received from the Department of Anesthesiology, The Bowman Gray School of Medicine of Wake Forest University, Winston-Salem, North Carolina. Submitted for publication January 18, 1997. Accepted for publication May 29, 1997.

Address reprint requests to Dr. Harwood: Department of Anesthesia, Bowman Gray School of Medicine, Medical Center Boulevard, Winston-Salem, North Carolina 27157-1009. Address electronic mail to: tharwood@bgsu.edu

Key words: Inhalational anesthetics; postoperative complications; succinylcholine.

### Case Report

A 50-yr-old, 100-kg male was scheduled for a radical prostatectomy for prostatic adenocarcinoma. Medical history included depression, chronic left upper extremity weakness for 23 yr, and peptic ulcer disease. Surgical and anesthetic history included general anesthesia for cholecystectomy, hemorrhoidectomy, and three procedures on