

high frequency positive pressure ventilation for sleeve pneumonectomy: An alternative technique. *Anesth Analg* 1981; 60:683-6

12. Oliverio R, Ruder CG, Fermon C, et al: Pneumothorax secondary to ball valve obstruction during jet ventilation. *ANESTHESIOLOGY* 1979; 51:255-6

13. Chang JL, Bleyaert A, Bedger R: Unilateral pneumothorax following jet ventilation during general anesthesia. *ANESTHESIOLOGY* 1980; 53:244-6

14. Smith BE: High frequency ventilation: Past, present and future? *Br J Anaesth* 1990; 65:130-8

Anesthesiology  
1997; 87:1574-5

© 1997 American Society of Anesthesiologists, Inc.  
Lippincott-Raven Publishers

## Radiographic Investigation of Unilateral Epidural Block after Single Injection

Tetsushi Fukushima, M.D.,\* Tatsuhiko Kano, M.D.,† Tomomi Sano, M.D.,‡

WE report a case of unilateral epidural block developing after each of three attempts at single injection epidural block and discuss the cause of unilateral epidural block based on radiographic findings.

### Case Report

A 33-yr-old woman, weighing 51 kg and 1.51 m tall, was admitted to our pain clinic for right low back pain. There were no abnormal findings on physical or neurologic examinations except for tenderness in the right lower lumbar paravertebral region. We treated her with single injection epidural block at the L5-S1 interspace using 5 ml of 1% mepivacaine once a week for three consecutive weeks. Each time, the patient complained of sensory and motor disturbance only on the left side. We confirmed unilateral epidural block with cold and pinprick tests. Radiography and magnetic resonance imaging of her lumbar spine did not provide any evidence of the cause of the unilateral epidural block. After obtaining informed consent, we conducted epidurography and computed tomographic (CT) epidurography by injecting nonionic radiographic contrast medium epidurally. After introducing a 22-gauge needle into the epidural space at the L5-S1 interspace in prone position under fluoroscopic control, we injected 4.5 ml of iopamidol mixed with 0.5 ml of 10% lidocaine. Posterior-anterior and lateral epidurography was carried out immedi-

ately after injection and transverse CT epidurography 10 min after injection. The injected contrast medium spread mainly to the left half of the L4-S1 epidural space and distributed mostly in the posterior epidural spaces (Fig. 1A, 1B). CT epidurography disclosed deformation of the dural sac, which showed a contracted inverted triangular shape with the summit pointing toward the laminal direction. Most of the epidurally injected contrast medium was confirmed to distribute to the left posterior part of the epidural space, whereas some also was seen in the right posterior and anterior parts of the epidural space (Fig. 1C). Analgesia developed only on the left side with extension to the L4-S2 dermatomes, as evaluated by pinprick test 25 min after the injection.

One hour after the first epidural injection, we again punctured her epidural space at same level under fluoroscopic control. This time, we intentionally directed the needle to the right side of the epidural space and injected 5 ml of iopamidol only. In contrast to the first epidurography, the second epidurography demonstrated exclusively right lateral distribution in relation to the median in the epidural space.

### Discussion

According to the findings at epidurography and CT epidurography, it is most likely that in our case, the cause of the unilateral epidural block was a unilateral left-sided distribution of local anesthetics. Although a small volume of contrast medium was also seen on the right side, especially on CT epidurography, clinical analgesic effect appeared only on the left side. Presumably, the sensitivity of CT for contrast medium was high, but the concentration of local anesthetics was too small to produce a block.

The lumbar dura is anchored laterally and dorsomedially by each pair of spinal nerve roots and by dorsomedian connective tissue, which was noted by Blomberg *et al.*<sup>1</sup> in their *in vivo* anatomic study using epiduroscopy.

\* Lecturer of Anesthesiology.

† Professor of Anesthesiology.

‡ Assistant Professor of Anesthesiology.

Received from the Department of Anesthesiology, Kurume University School of Medicine, Kurume City, Japan. Submitted for publication January 29, 1997. Accepted for publication August 12, 1997.

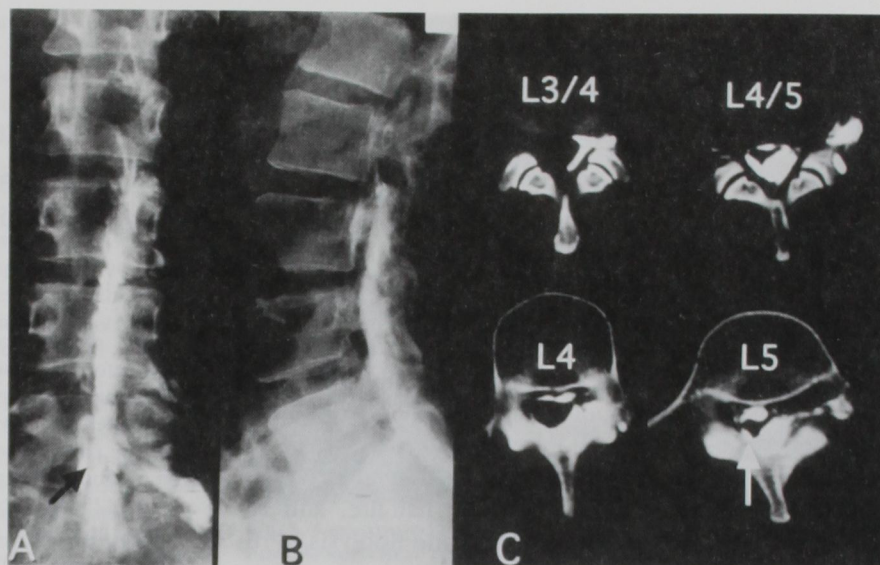
Address reprint requests to Dr. Fukushima: Department of Anesthesiology, Kurume University School of Medicine, 67 Asahi-Mach, Kurume City, Fukuoka 830, Japan.

Key words: Epidural analgesia; single epidural injection; complication; unilateral epidural analgesia.



## CASE REPORTS

Fig. 1. (A) Epidurographic posterior-anterior view. Contrast medium spread mainly to the left half of epidural space. Note the medial translucency line (black arrow). (B) Epidurographic lateral view. Contrast medium spread mainly to the posterior part of epidural space. (C) CT epidurography at different vertebral and discal levels. Contrast medium spreads mainly to the left posterior part of epidural space, although some contrast medium was seen in the right posterior and anterior epidural space at L4 to L5. The shape of the dural sac deformed to an inverted triangular under L4. Note the fine connective tissue (white arrow).



After epidural injection, the ventral and both dorsolateral aspects of the dural sac should be distended so that the sac is molded into a more or less triangular cross-section with the dorsomedian fold.<sup>2</sup> Husemeyer and White<sup>3</sup> confirmed this dural triangle configuration using resin injected into the epidural space, and they also reported that anterior and both dorsolateral compartments of lumbar epidural space appeared not to be free communication with each other and that filling of the various compartments was asymmetric in some cases.<sup>3</sup>

In our case, we suppose that the epidural needle was placed in the left posterior epidural space and that the presence of dorsomedian connective tissue and deformation of the dural sac to a contracted inverted triangle after epidural injection caused the distension of the left posterior epidural space and prevented the spread of local anesthetics to the right side of the epidural space. It also seemed to be responsible for unilateral epidural block.

The dorsal summit of the deformed dural sac on CT epidurography was equal to the line of medial translucency on the posterior-anterior view of epidurogra-

phy. Lewit<sup>4</sup> found the medial translucency only in the lower part (triangular) of the spinal canal. So the mechanism of unilateral epidural block in our case seemed to apply only in the lumbar region.

In summary, it is most likely that the presence of dorsomedian connective tissue in the posterior epidural space and the deformation of the dural sac after epidural injection prevented the spread of the injected local anesthetic throughout entire epidural space, resulting in unilateral epidural block.

## References

1. Blomberg RG, Olsson SS: The lumbar epidural space in patients examined with epiduroscopy. *Anesth Analg* 1989; 68:157-60
2. Luyendijk W, Voorthuisen AE: Contrast examination of the spinal epidural space. *Acta Radiol Diagn* 1966; 5:1051-66
3. Husemeyer RP, White DC: Topography of the lumbar epidural space. A study in cadavers using injected polyester resin. *Anaesthesia* 1980; 35:7-11
4. Lewit K, Sereghy T: Lumbar peridurography with special regard to the anatomy of the lumbar peridural space. *Neuroradiology* 1975; 8:233-40