

Anesthesiology
1997; 87:1335-42
© 1997 American Society of Anesthesiologists, Inc.
Lippincott-Raven Publishers

Comparison of the Bullard and Macintosh Laryngoscopes for Endotracheal Intubation of Patients with a Potential Cervical Spine Injury

Andrew D. J. Watts, F.A.N.Z.C.A.,* Adrian W. Gelb, F.R.C.P.C.,† David B. Bach, F.R.C.P.C.,‡
David M. Pelz, F.R.C.P.C.‡

Background: In the emergency trauma situation, in-line stabilization (ILS) of the cervical spine is used to reduce head and neck extension during laryngoscopy. The Bullard laryngoscope may result in less cervical spine movement than the Macintosh laryngoscope. The aim of this study was to compare cervical spine extension (measured radiographically) and time to intubation with the Bullard and Macintosh laryngoscopes during a simulated emergency with cervical spine precautions taken.

Methods: Twenty-nine patients requiring general anesthesia and endotracheal intubation were studied. Patients were placed on a rigid board and anesthesia was induced. Laryngoscopy was performed on four occasions: with the Bullard and Macintosh laryngoscopes both with and without manual ILS. Cricoid pressure was applied with ILS. To determine cervical spine extension, radiographs were exposed before and during laryngoscopy. Times to intubation and grade view of the larynx were also compared.

Results: Cervical spine extension (occiput-C5) was greatest with the Macintosh laryngoscope ($25.9^\circ \pm 2.8^\circ$). Extension was reduced when using the Macintosh laryngoscope with ILS ($12.9 \pm 2.1^\circ$) and the Bullard laryngoscope without stabilization ($12.6 \pm 1.8^\circ$; $P < 0.05$). Times to intubation were similar for the Macintosh laryngoscope with ILS (20.3 ± 12.8 s) and for the Bullard without ILS (25.6 ± 10.4 s). Manual ILS with the Bullard laryngoscope results in further reduction in cervical spine extension ($5.6 \pm 1.5^\circ$) but prolongs time to intubation (40.3 ± 19.5 s; $P < 0.05$).

Conclusions: Cervical spine extension and time to intuba-

tion are similar for the Macintosh laryngoscope with ILS and the Bullard laryngoscope without ILS. However, time to intubation is significantly prolonged when the Bullard laryngoscope is used in a simulated emergency with cervical spine precautions taken. This suggests that the Bullard laryngoscope may be a useful adjunct to intubation of patients with potential cervical spine injury when time to intubation is not critical. (Key words: Anesthetic technique: tracheal intubation. Equipment: laryngoscope. Spine: cervical; motion).

THE anesthesiologist is frequently involved in the early management and resuscitation of patients who have sustained trauma injuries. They may be responsible for endotracheal intubation for airway protection, for controlled ventilation, or administration of general anesthesia. When cervical spine stability is not in question, anesthesia is induced and the airway is secured by oral endotracheal intubation using direct laryngoscopy and application of cricoid pressure. However, in the emergency trauma situation, when there is potential for cervical spine injury, methods to stabilize the cervical spine are used to reduce cervical spine movement during airway manipulation. Manual in-line stabilization (ILS) is the method advocated in the *Advanced Trauma Life Support Student Manual*.¹ In-line stabilization has been shown to be safe during endotracheal intubation.²⁻⁴

The Bullard laryngoscope is an anatomically shaped, rigid instrument that uses fiberoptic bundles to obtain an indirect view of the larynx. It has been described in detail elsewhere.^{5,6} When using the Bullard laryngoscope, the oral, pharyngeal, and tracheal axes do not have to be aligned to view the larynx and it may result in less extension of the head and cervical spine during laryngoscopy and endotracheal intubation.^{7,8} It has been suggested, therefore, that the Bullard laryngoscope may be the instrument of choice in the emergency trauma situation for patients with suspected injury to the cervical spine.^{9,10}

Potential drawbacks are associated with the use of the Bullard laryngoscope. First, there is a learning curve

* Clinical Fellow, Department of Anesthesia.

† Professor and Chair, Department of Anesthesia.

‡ Associate Professor, Department of Diagnostic Radiology.

Received from the London Health Sciences Centre, London, Ontario, Canada. Submitted for publication March 6, 1997. Accepted for publication July 14, 1997. Supported by intramural funds from the Department of Anaesthesia, London Health Sciences Centre, London, Ontario, Canada. Presented at the 24th Annual Meeting of the Society of Neurosurgical Anesthesia and Critical Care, New Orleans, Louisiana, October 18, 1996.

Address reprint requests to Professor Gelb: Department of Anesthesia, London Health Sciences Centre, 339 Windermere Road, Ontario, N6A 5A5, Canada. Address electronic mail to: agelb@julian.uwo.ca

associated with its use, and more training may be required to use it in a competent manner than is necessary with the Macintosh laryngoscope.⁵ Second, greater time may be required for endotracheal intubation with the Bullard than with the Macintosh laryngoscope either due to lack of experience with the Bullard laryngoscope or difficulty with manipulation of the larger laryngoscope blade in the upper airway. If laryngoscopy is prolonged and intubation of the trachea delayed, the patient may be at risk for hypoxia.⁸

To date, no studies have evaluated the Bullard laryngoscope and its use in the emergency trauma setting when cervical spine injury is suspected. In this situation, the apparent advantage of decreasing cervical spine movement during laryngoscopy with the Bullard laryngoscope may be balanced because the head and neck are routinely stabilized during airway manipulation. Given these observations, we compared the Bullard and Macintosh laryngoscopes in a simulated emergency situation. We determined (1) the amount of head and neck extension during laryngoscopy with both the Bullard and Macintosh laryngoscopes, (2) the time required for intubation, (3) the Cormack and Lehane grade view of the larynx¹¹ at laryngoscopy, and (4) oxygen saturation.

Methods

Approval for the study was obtained from the Review Board for Health and Sciences Research Involving Human Subjects of the University of Western Ontario, London, Ontario. Written and informed consent was obtained from patients classified as American Society of Anesthesiologists physical status I–III, aged 18 years or older, who were undergoing elective surgery requiring general anesthesia with endotracheal intubation. Patient exclusion criteria included a history of (1) known or suspected cervical spine injury or disease, (2) gastroesophageal reflux or risk of pulmonary aspiration, and (3) a previous difficult or failed intubation.

Preoperative clinical assessment of the patients ensured normal head and cervical spine movement. All patients had a grade I Mallampati¹² view of the oropharynx. While awake, the patients were placed on the operating room table with a rigid board under their head, neck, and torso. Patients were placed on this board to simulate the table on which patients involved in trauma are placed in the emergency room.

Anesthesia was induced with 1–2 mg/kg propofol and 2.5 µg/kg fentanyl and then maintained initially

with nitrous oxide, oxygen, and isoflurane. Patients were then ventilated with isoflurane in 100% oxygen for 3 min before laryngoscopy to simulate preoxygenation. Muscle relaxation was achieved with 0.8 mg/kg rocuronium. Once paralysis had occurred, as determined by a peripheral nerve stimulator, the sequence of laryngoscopies was undertaken.

Laryngoscopy and intubation were performed in all patients by one anesthetist (A.D.J.W.) who had performed more than 50 intubations using the Bullard laryngoscope before the study began. Laryngoscopy was performed four times in each patient: with the Bullard laryngoscope (with and without manual ILS) and with the Macintosh laryngoscope (with and without manual ILS). The order in which the laryngoscopes were used was determined by randomization, as was the order of application of ILS or no stabilization. Cricoid pressure was applied with ILS to complete the simulation of the emergency intubation sequence. The aim of ILS was to maintain the patient's head in the neutral position during laryngoscopy by applying a force that was equal and opposite to the forces generated during laryngoscopy.

The Bullard laryngoscope was used as described by Cooper *et al.*¹⁰ with the dedicated, nonmalleable intubating stylet. This stylet is designed specifically for use with the Bullard laryngoscope and must be preloaded with the distal end of the stylet protruding through the Murphy's eye of the endotracheal tube. If the endotracheal tube is not loaded in this manner then it is not possible to see the tip of the tube, which will inhibit intubation.⁵ The Bullard laryngoscope differs from the Macintosh laryngoscope in that the end of the blade is used to retract the epiglottis. In all cases, the plastic extension for the distal tip of the laryngoscope's blade was used to aid in "capturing" the epiglottis. For direct laryngoscopy, a size 3 Macintosh laryngoscope was used in all patients. All male patients were intubated with a 7.5-mm inner diameter endotracheal tube and women with a 7-mm inner diameter endotracheal tube. With laryngoscopy, the glottis was exposed to enable positioning of the endotracheal tube at the vocal cords. After the final laryngoscopy in the above sequence, the trachea was intubated.

Five lateral radiographs of the patients' necks were obtained using a General Electric Stenoscope Image Intensifier (Milwaukee, WI). This fluoroscopic system provides fixed images from which hard copies are generated with a matrix camera. Patients served as their own controls. The first image exposed was a reference image, obtained after the induction of anesthesia and be-

CERVICAL SPINE MOTION DURING SIMULATED SPINE PRECAUTIONS

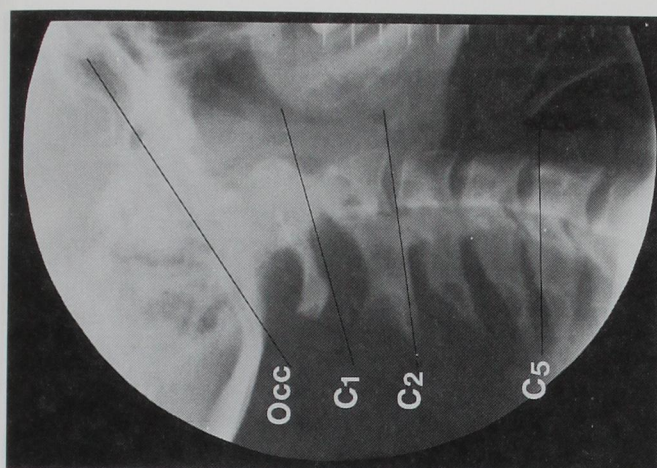


Fig. 1. Representative radiograph showing the reference lines for the base of the skull (C0) and the cervical vertebrae (C1, C2, and C5) used to determine relative movement during laryngoscopy.

fore laryngoscopy and intubation, with the patient positioned in the neutral position on the operating room table. A further four radiographs were exposed, two with the Bullard laryngoscope (with and without stabilization) and two with the Macintosh laryngoscope (with and without stabilization). These images were taken at the time of laryngeal exposure, with the tip of the endotracheal tube positioned at the opening of the larynx.

The radiographs were reviewed by two radiologists who were blinded to the order of the intubation techniques and unfamiliar with the laryngoscopes being studied. They had no knowledge of the other criteria being used to assess laryngoscopy and intubation in the patients.

On each image (five per patient), lines were drawn to mark the relative positions of the cranium (or occiput), the atlas (C1), the axis (C2), and the fifth cervical vertebra (C5) (fig. 1). The reference line of the occiput was a line from the inferior aspect of the sella turcica to the most dorsal and caudal portion of the occiput. For the atlas, the reference line was the tangent between the anterior and posterior arches. The reference line for C2 and C5 was a line drawn from the junction of the anterior aspect of the vertebral body and the superior vertebral plate to the spinous process. The angle between each of these lines and an arbitrary reference line drawn on each radiograph was measured to determine the degree of angulation of C1, C2, and C5 relative to the occiput and to each other. The degree

of angulation between the occiput and C1, C2, and C5 was calculated for each film and compared with the reference radiograph for that patient. Changes in angulation from film to film reflect different degrees of flexion or extension of the cervical spine during laryngoscopy (fig. 2). Extension was recorded as a positive value, as in previous studies.^{7,13,14} Sometimes some of these defined points could not be identified in some of the patients. In these cases, identical and reproducible landmarks that could be identified on all five radiographs for a patient (such as the basal plates of the vertebral bodies in question) were used instead and the appropriate measurements were obtained.

Time to intubation was recorded as the time from when the laryngoscope blade passed the teeth of the patient until the time the endotracheal tube sat at the opening of the larynx. For the Bullard laryngoscope, this meant that the endotracheal tube must have been advanced off the end of the dedicated intubating stylet and the tip of the endotracheal was free and overlying the vocal cords. The time to intubation for the last laryngoscopy in each sequence was the time from when the laryngoscope blade passed the teeth until the trachea was intubated. If the intubation sequence was longer than 120 s, it was deemed a failure and was recorded as such.

The Cormack and Lehane view of the larynx was graded for all patients and oxygen saturation at the time of intubation was recorded.

Demographic data and times to intubation are reported as means \pm SD. Extension of the occiput and cervical spine with laryngoscopy are reported as means \pm SD. Comparison of the times to intubation and cervical spine extension was performed using analysis of variance for repeated measures, followed by multiple comparisons with the Student-Newman-Keuls test. The difference in grade view of the larynx obtained with each laryngoscope with and without ILS was compared using the chi-square test.

Results

Twenty-nine patients were studied, of whom 24 had complete sets of five radiographs. Sixteen patients were women and 13 were men, with a mean age of 38.7 ± 15 yr (range, 19–68 yr). Patients weighed 79 ± 11 kg (range, 60–113 kg). The data for cervical spine extension and time to intubation were distributed normally.

Table 1 shows the mean cervical spine extension from

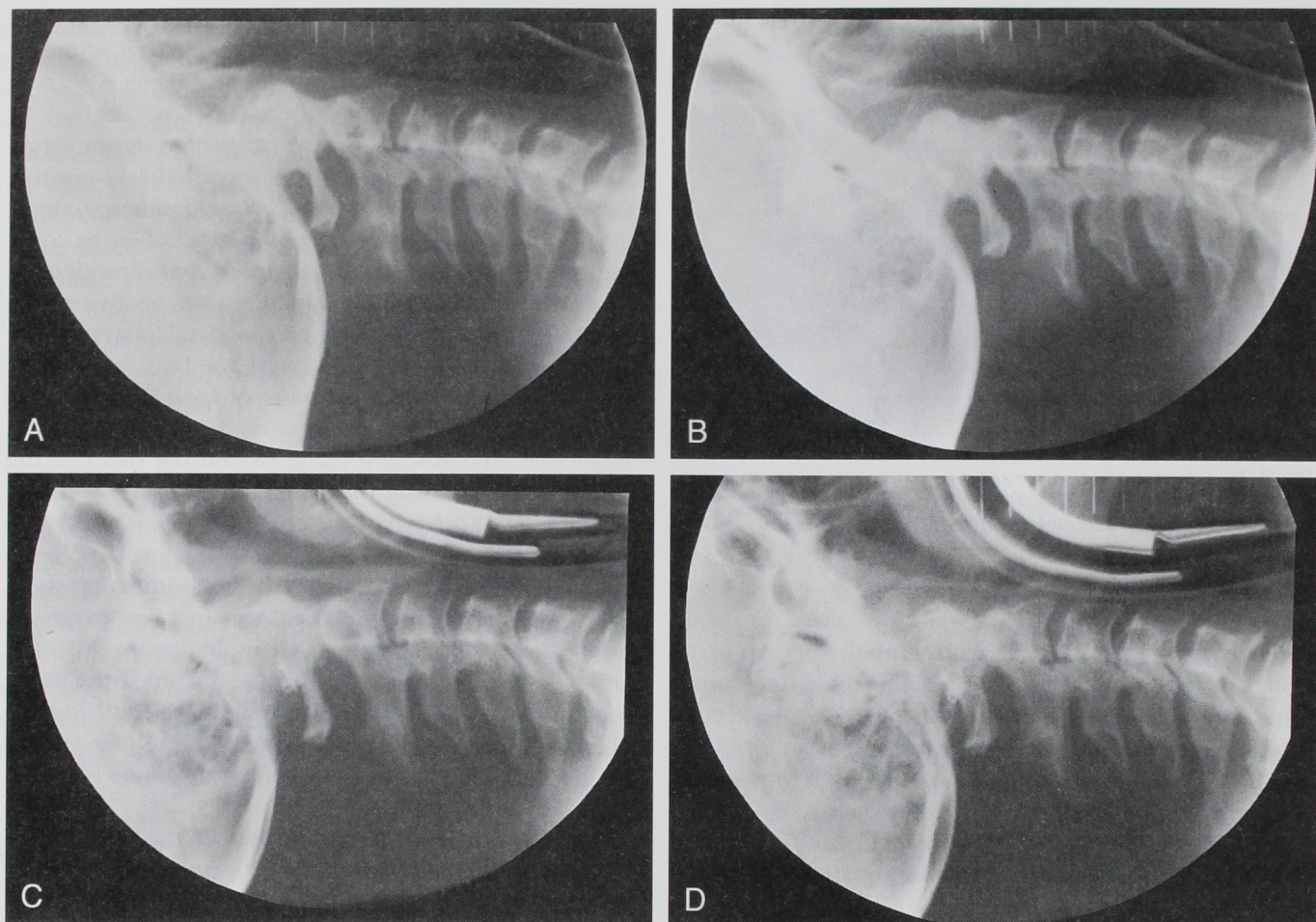


Fig. 2. Radiographs representative of the extension seen during laryngoscopy using the Macintosh and Bullard laryngoscopes with and without manual in-line stabilization (ILS). (A) Macintosh, (B) Macintosh with ILS, (C) Bullard, and (D) Bullard with ILS.

Table 1. Cervical Spine Extension with Laryngoscopy and Intubation

	MAC	MAC-ILS	BUL	BUL-ILS
Occ/C1	11.4 ± 1.6	6.8 ± 1.6	4.5 ± 1.1	3.6 ± 1.4
C1/C2	8.9 ± 1.1	6.2 ± 0.8	4.7 ± 0.7	2.6 ± 0.8
Occ/C2	20.4 ± 2.4	13.1 ± 1.7	9.3 ± 1.6	6.2 ± 1.4
C2/C5	5.5 ± 1.1	-0.2 ± 1.1	3.3 ± 0.8	-0.7 ± 0.9
Occ/C5	25.9 ± 2.8	12.9 ± 2.1	12.6 ± 1.8	5.6 ± 1.5

Values are mean ± SD (°). C-spine extension is greatest at all levels during laryngoscopy with the Macintosh laryngoscope. Comparable extension is seen with the Bullard laryngoscope and the Macintosh laryngoscope with ILS at all levels except Occ/C2. When extension is examined from Occ/C2, the Bullard results in less motion than the Macintosh laryngoscope with ILS. Extension is further reduced by applying ILS with the Bullard laryngoscope.

the baseline reference radiograph. A positive value denotes extension and negative value denotes flexion. Extension is shown between the occiput-atlas and between the atlas-axis. In addition, extensions for the occipitoatlantoaxial complex (occiput-C2), from C2 to C5 and for the cervical spine as a whole from the level of the occiput to C5 (occiput-C5) are shown.

Most of the extension with laryngoscopy and intubation occurs between the occiput and C2. Cervical spine extension (occiput-C1, C1-C2, and occiput-C5) is greatest during laryngoscopy and intubation with the Macintosh laryngoscope. The amount of cervical spine extension (occiput-C5) is similar when comparing the Macintosh-ILS ($12.9 \pm 2.1^\circ$) and the Bullard laryngoscope without stabilization ($12.6 \pm 1.8^\circ$; fig. 3). The extension observed under both of these conditions was less than

CERVICAL SPINE MOTION DURING SIMULATED SPINE PRECAUTIONS

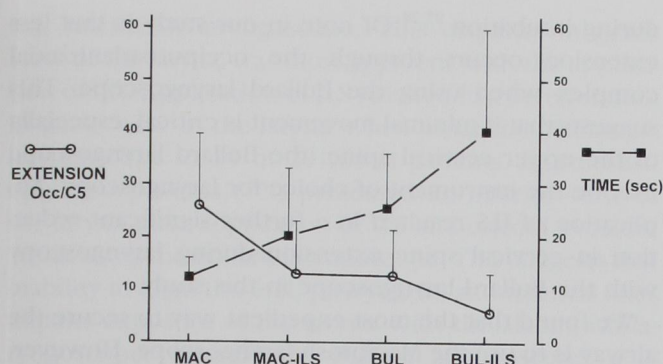


Fig. 3. The cervical spine extension (occiput-C5) and the times to intubation with each of the intubation sequences. Standard error bars are included. Time to intubation is fastest when using the Macintosh laryngoscope without ILS, but cervical spine extension is greatest. The cervical spine extension and times to intubation are similar with the Macintosh laryngoscope with ILS and the Bullard laryngoscope without ILS. The least amount of cervical spine extension is seen when using the Bullard laryngoscope with ILS.

with the Macintosh without ILS ($25.9 \pm 2.8^\circ$; $P < 0.05$). When the occiput-C2 complex is considered, the Bullard laryngoscope ($9.3 \pm 1.6^\circ$) results in less cervical spine extension than does the Macintosh laryngoscope with ILS ($13.1 \pm 1.7^\circ$; $P < 0.05$). The extension that occurs with the Bullard laryngoscope is further reduced when using ILS at both the levels occiput-C2 ($6.2 \pm 1.4^\circ$) and when the cervical spine is considered as a whole ($5.6 \pm 1.5^\circ$). If relative movement of the cervical spine between C2 and C5 is examined, there appears to be a tendency of the assistant to flex the neck with application of ILS. This is illustrated by the negative angles in this segment of the cervical spine with ILS (table 1).

Figures 3 and 4 show the mean times to intubation. The most expedient method for securing the airway was using the Macintosh laryngoscope without ILS (12.3 ± 3.7 s; $P < 0.05$). There was no difference in times to intubation when comparing the Bullard laryngoscope without ILS (25.6 ± 10.4 s) and the Macintosh laryngoscope with ILS (20.3 ± 12.8 s). When the Bullard laryngoscope was used with ILS, the time to intubation (40.3 ± 19.5 s) was significantly longer than all other methods of intubation. There were no failures of intubation (*i.e.*, time longer than 120 s) in any group.

A grade I view of the larynx was obtained in all patients when the Bullard laryngoscope was used without ILS. The view of the larynx deteriorated with application of ILS and cricoid pressure in two of these patients. When we used the Macintosh laryngoscope, a grade II

view of the larynx was obtained in four patients without ILS. The view of the larynx deteriorated in 19 patients with application of ILS and cricoid pressure ($P < 0.05$). A grade III view of the larynx was obtained in four patients when we used the Macintosh laryngoscope with ILS.

All patients had an oxygen saturation of 96% or more at the time of intubation. There were no significant changes in oxygen saturation during the laryngoscopy sequences.

Discussion

This study shows that cervical spine extension during laryngoscopy is greatest when using the Macintosh laryngoscope. This cervical spine extension may be reduced by either applying manual ILS while the Macintosh laryngoscope is used or by using the Bullard laryngoscope. In addition, application of ILS when using the Bullard laryngoscope further reduces extension during laryngoscopy.

Cervical spine injury occurs in as many as 3–10% of all major trauma cases.^{15–17} Direct laryngoscopy is the most expedient way to facilitate endotracheal intubation. However, this requires flexion of the neck and extension at the atlanto-occipital joint to best expose the larynx.¹⁸ In the patient with a cervical spine injury,

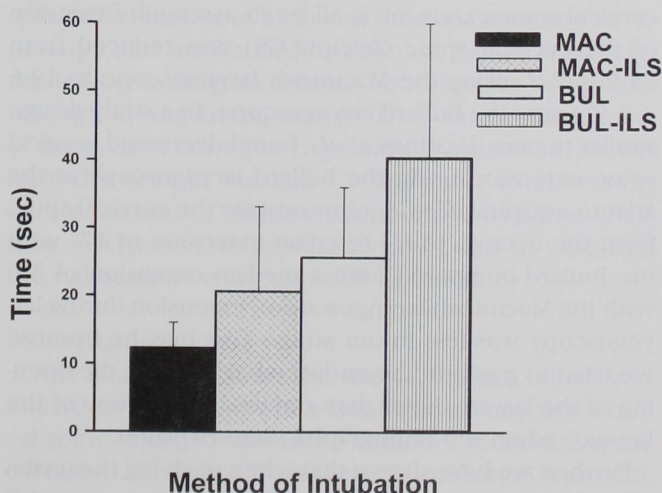


Fig. 4. This histogram shows time to intubation (\pm SD) during each laryngoscopy sequence. The times to intubation are similar when comparing the Bullard without ILS and the Macintosh laryngoscope with ILS. The fastest method of intubation is the Macintosh laryngoscope without ILS and the greatest time to intubation was required when using the Bullard laryngoscope with ILS.

airway manipulations may be associated with spinal cord damage.^{19,20} Thus cervical spine movement during these maneuvers must be minimized to reduce this risk.²¹⁻²³ The safety of laryngoscopy with the application of ILS has been demonstrated.^{2-4,24} We have tried to define a role for the Bullard laryngoscope in the patient with potential cervical spine injury.

In this study, the greatest proportion of extension occurred from the occiput through C2, which would be anticipated based on normal anatomy.²⁵ The degree of extension was similar to previously reported results.^{7,13,14} Fitzgerald *et al.*¹⁴ found in patients studied radiographically during intubation that most of the cervical spine extension occurred between the occiput and C2 and that minimal extension occurred below the level of C3. In a dynamic study of cervical spine movement during laryngoscopy, Sawin *et al.*¹³ found mean extension of 12° between the occiput and C2 at the times of greatest cervical spine motion and that this movement accounted for most of the cervical spine extension during laryngoscopy. These values for extension are less than those determined in our study (mean extension occiput-C2, $20.4 \pm 2.4^\circ$) using the Macintosh laryngoscope. In their study, placement of a foam pad under the occiput may have enabled the intubator to more easily align the oral-pharyngeal-tracheal axes and thus reduce the need to extend the neck to expose the larynx.

Use of the Bullard laryngoscope resulted in reduced cervical spine extension at all levels assessed. Extension of the cervical spine (occiput-C5) was reduced from $25.9 \pm 2.8^\circ$ using the Macintosh laryngoscope to $12.6 \pm 1.8^\circ$ using the Bullard laryngoscope. In a study design similar to ours, Hastings *et al.*⁷ found decreased cervical spine extension using the Bullard laryngoscope at the atlanto-occipital, C3-C4 joints and for the cervical spine from the occiput to C4 (median extension of 17° with the Bullard compared with a median extension of 31° with the Macintosh laryngoscope). Extension during laryngoscopy was less in our study. This may be because we tried to position the endotracheal tube at the opening of the larynx rather than obtain a "best view of the larynx" when the radiographs were exposed.

Further, we have shown that when studying the unstabilized cervical spine (occiput-C5), laryngoscopy with the Bullard laryngoscope results in similar cervical spine extension as the Macintosh laryngoscope and ILS (table 1). In-line stabilization has been shown to reduce head extension during exposure of the larynx²⁶ and to decrease cervical spine motion assessed radiographically

during intubation.^{27,28} Of note in our study is that less extension occurs through the occiputoatlantoaxial complex when using the Bullard laryngoscope. This suggests that if minimal movement is critical, especially of the upper cervical spine, the Bullard laryngoscope may be the instrument of choice for laryngoscopy. Application of ILS resulted in a further significant reduction in cervical spine extension during laryngoscopy with the Bullard laryngoscope in this study.

We found that the most expedient way to secure the airway is to use the Macintosh laryngoscope. However, time required to intubate the trachea is significantly increased when constraints on cervical spine movement are imposed with application of ILS and cricoid pressure (12.3 ± 3.7 vs. 20.3 ± 12.8 s; $P < 0.05$). The times required for intubation with a Macintosh laryngoscope are similar to those found by Sawin *et al.*¹³ In their study, all patients were intubated in less than 15 s. Nolan and Wilson²⁹ assessed times to intubation in patients with a simulated cervical spine injury using both ILS and cricoid pressure and found that when considering all grades of laryngeal view, the median time to intubation was 20 s.

Times to intubation using the Bullard laryngoscope, in this study, are similar to others reported in the literature.^{10,30} In our hands, intubation took 25.6 ± 10.4 s using the Bullard laryngoscope. Twenty-two of 29 patients (76%) were intubated in less than 30 s when using the Bullard laryngoscope under standard conditions. In their study, Cooper *et al.*¹⁰ found 70% of patients were intubated in less than 30 s using the new, dedicated intubating stylet. Time to intubation with the Bullard laryngoscope in the simulated emergency with the use of ILS and cricoid pressure increased to 40.3 ± 19.6 s. Cohn and Zornow³⁰ found in patients with cervical spine injury that although visualization of the larynx may occur relatively quickly, the time required to intubate the trachea still took an average of 46.1 ± 18.98 s. Time to intubation significantly increased with application of ILS and cricoid pressure, and may reflect greater difficulty with insertion and then manipulation of the larger blade of the Bullard laryngoscope under these conditions or distortion of airway anatomy by cricoid pressure. However, it should be noted that application of ILS and cricoid pressure resulted in a similar proportional increase in time to intubation (compared with standard conditions) with both the Macintosh (65%) and the Bullard (57%) laryngoscopes.

This study shows that there is better exposure of the larynx during laryngoscopy with the Bullard than with

CERVICAL SPINE MOTION DURING SIMULATED SPINE PRECAUTIONS

the Macintosh laryngoscope. This disparity in grade view of the larynx was most apparent with the application of ILS. Application of ILS resulted in a deterioration in grade view of the larynx when using the Macintosh laryngoscope in 19 of 29 (65%) patients. In contrast, only two patients (7%) presented an inferior view of the larynx after application of ILS and cricoid pressure when using the Bullard laryngoscope. This suggests that inability to align the oral, pharyngeal, and tracheal axes impairs exposure of the larynx with the Macintosh laryngoscope, whereas the Bullard laryngoscope, a fiberoptic device, depends less on cervical spine extension to expose the larynx. However, despite this improved ability to visualize the larynx with the Bullard laryngoscope, the time to intubation was greater than when using the Macintosh laryngoscope under similar conditions. It is unlikely, in our opinion, that this increased time to intubation with the Bullard laryngoscope reflects inexperience with its use. Rather, the larger and more cumbersome Bullard laryngoscope is relatively more difficult to manipulate in the patient's upper airway.

Study Limitations

This study was performed in the operating room under ideal conditions and thus may underestimate both the degree of cervical spine extension and time to intubation compared with true emergency situations.

All laryngoscopies were performed by one investigator. Given the nature of the study, this investigator could not be blinded to the laryngoscopes used and the intubation sequence. This investigator potentially may have introduced bias that could have resulted in greater cervical spine extension or longer times to intubation with one of the laryngoscopes. However, both the degree of cervical spine extension and the times to intubation of patients were similar to those reported in other studies in the literature. Although the investigator performing the intubations was not blinded to the intubation sequence, the radiologists who examined the radiographs were blinded to both the order in which the laryngoscopes were used and to other criteria used to assess the intubation sequences.

When measuring times to intubation in this study, we defined the time of "intubation" as the time when the tip of the endotracheal tube was positioned at the vocal cords, except for the final intubation in the sequence of four. This definition differed slightly from other studies^{10,29,30} in which intubation time was recorded as when the endotracheal tube was in the trachea. We

believed that it was unethical to intubate each patient on four occasions. For this reason, the patients were only intubated once and the times were recorded as stated in Methods. Although some may argue that this may have reduced times to intubation, particularly with the Bullard laryngoscope, we do not believe this occurred. The investigator performing the intubations was well practiced in the use of the Bullard laryngoscope, and our experience suggests that once the endotracheal tube has been advanced off the intubating stylet, has advanced beyond the right arytenoid cartilage, and overlies the vocal cords, then intubation of the trachea is straightforward.

Other investigators have tried to quantitate head extension or cervical spine motion during laryngoscopy and intubation. We have assessed movement (expressed as extension/flexion) relative to a reference radiograph of the cervical spine. For this to be achieved, identical anatomic points must be identified on each set of radiographs. Although in most patients readily identifiable anatomic landmarks could be used, in some patients these landmarks could not be seen in all five radiographs of each set. We concur with Sawin *et al.*¹³ that it is of no importance which points are used provided identical points can be identified on each of the five radiographs in a single patient.

Our study depended on static images rather than dynamic recordings. These images were acquired at the point of greatest cervical spine extension, when the spinal cord may be at most risk for damage during laryngoscopy and intubation. In contrast, Sawin *et al.*¹³ recorded cervical spine motion continuously using fluoroscopy during laryngoscopy. They showed that most of the motion during laryngoscopy is extension, occurs from the occiput through C2, and most extension occurs at the time of glottic visualization and endotracheal tube insertion. This represents the point in time that the radiographs were exposed in our study.

Conclusions

This study compared the use of the Macintosh and Bullard laryngoscopes in a simulated emergency cervical spine injury. Under these conditions, cervical spine extension (occiput-C5) and time to intubation were similar when comparing the Macintosh laryngoscope with the use of manual ILS and the Bullard laryngoscope without ILS. However, the Bullard laryngoscope resulted in less extension of the occiputatlantoaxial complex during laryngoscopy than did the Macintosh laryngoscope with application of ILS.

Cervical spine extension can be further reduced when using the Bullard laryngoscope by applying ILS. However, the time to securing the airway is significantly longer with the Bullard than with the Macintosh laryngoscope in a simulated emergency scenario with ILS and application of cricoid pressure. These findings suggest that the Bullard laryngoscope may be a useful adjunct to intubate patients with cervical spine injuries in the elective situation when time to intubation is not critical. In the emergency situation when preoxygenation may be less than optimal, when hypercapnia must be avoided, and when time to securing the airway is critical, the Macintosh laryngoscope with the application of ILS and cricoid pressure remains the most appropriate way to intubate the trachea.

The authors thank radiology technologists Connie Rose and Nancy McIntosh for their assistance.

References

1. American College of Surgeons Committee on Trauma: Advanced Trauma Life Support Student Manual. Chicago, American College of Surgeons, 1993, pp 17-46
2. Suderman VS, Crosby ET, Lui A: Elective oral tracheal intubation in cervical spine-injured adults. *Can J Anaesth* 1991; 38:785-9
3. Criswell JC, Parr MJA: Emergency airway management in patients with cervical spine injuries. *Anaesthesia* 1994; 49:900-3
4. Rhee KJ, Green W, Holcroft JW, Mangili JAA: Oral intubation in the multiply injured patient: The risk of exacerbating spinal cord damage. *Ann Emerg Med* 1990; 19:511-4
5. Gorbach MS: Management of the challenging airway with the Bullard laryngoscope. *J Clin Anesth* 1991; 3:473-7
6. Midttun M, Laerkholm Hansen C, Jensen K, Pederson T: The Bullard laryngoscope: Reports of two cases of difficult intubation. *Acta Anaesthesiol Scand* 1994; 38:300-2
7. Hastings RH, Vigil AC, Hanna R, Yang BY, Sartoris DJ: Cervical spine movement during laryngoscopy with the Bullard, Macintosh, and Miller laryngoscopes. *ANESTHESIOLOGY* 1995; 82:859-69
8. Borland LM, Casselbrant M: The Bullard laryngoscope: A new indirect oral laryngoscope (pediatric version). *Anesth Analg* 1990; 70:105-8
9. Abrams KJ, Desai N, Katsnelson T: Bullard laryngoscopy for trauma airway management in suspected cervical spine injuries. *Anesth Analg* 1992; 74:619-23
10. Cooper SD, Benumof JL, Ozaki GT: Evaluation of the Bullard laryngoscope using the new intubating stylet: Comparison with conventional laryngoscopy. *Anesth Analg* 1994; 79:965-70
11. Cormack RS, Lehane J: Difficult tracheal intubation in obstetrics. *Anaesthesia* 1984; 39:1105-11
12. Mallampati SR, Gugino LD, Desai SP, Freiburger D: A clinical sign to predict difficult tracheal intubation: A prospective study. *Can J Anaesth* 1985; 32:429-34
13. Sawin PD, Todd MM, Traynelis VC, Farrell SB, Nader A, Sato Y, Clausen JD, Goel VK: Cervical spine motion with direct laryngoscopy and orotracheal intubation. *ANESTHESIOLOGY* 1996; 85:26-36
14. Fitzgerald RD, Krafft P, Skrbensky G, Pernerstorfer T, Steiner E, Kapral S, Weistabl C: Excursions of the cervical spine during tracheal intubation: blind oral intubation compared with direct laryngoscopy. *Anaesthesia* 1994; 49:111-5
15. Cohn SM, Lyle WG, Linden CH, Lancey RA: Exclusion of cervical spine injury: A prospective study. *J Trauma* 1991; 31:570-4
16. Hastings RH, Marks JD: Airway management for trauma patients with potential cervical spine injuries. *Anesth Analg* 1991; 73:471-82
17. Bivins HG, Ford S, Bezmalinovic Z, Price HM, Williams JL: The effect of axial traction during orotracheal intubation of the trauma victim with an unstable cervical spine. *Ann Emerg Med* 1988; 17:25-9
18. Benumof JL: *Airway Management: Principles and Practice*. St. Louis, Mosby, 1996, pp 261-76
19. Hastings RH, Kelley SD: Neurologic deterioration associated with airway management in a cervical spine-injured patient. *ANESTHESIOLOGY* 1993; 3:580-3
20. Salathe M, Johr M: Unsuspected cervical fractures: A common problem in ankylosing spondylitis. *ANESTHESIOLOGY* 1989; 70:869-70
21. Crosby ET: Tracheal intubation in the cervical spine-injured patient. *Can J Anaesth* 1992; 39:105-9
22. Reid DC, Henderson R, Saboe L, Miller JDR: Etiology and clinical course of missed spine fractures. *J Trauma* 1987; 27:980-6
23. Grande CM, Stene JK, Bernhard WN: Airway management: Considerations in the trauma patient. *Crit Care Clin* 1990; 6:37-59
24. Holley J, Jorden R: Airway management in patients with unstable cervical spine fractures. *Ann Emerg Med* 1989; 18:1237-9
25. Penning L: Normal movements of the cervical spine. *AJR Am J Roentgenol* 1978; 130:317-26
26. Hastings RH, Wood PR: Head extension and laryngeal view during laryngoscopy with cervical spine maneuvers. *ANESTHESIOLOGY* 1994; 80:825-31
27. Majernick TG, Bieniek R, Houston JB, Hughes HG: Cervical spine movement during orotracheal intubation. *Ann Emerg Med* 1986; 15:417-20
28. Donaldson WF, Towers JD, Doctor A, Brand A, Donaldson VP: A methodology to evaluate motion of the unstable spine during intubation techniques. *Spine* 1993; 18:2020-3
29. Nolan JP, Wilson ME: Orotracheal intubation in patients with potential cervical spine injuries. *Anaesthesia* 1993; 48:630-3
30. Cohn AI, Zornow MH: Awake endotracheal intubation in patients with cervical spine disease: A comparison of the Bullard laryngoscope and the fiberoptic bronchoscope. *Anesth Analg* 1995; 81:1283-6