

CASE REPORTS

Anesthesiology
1997; 87:993-5
© 1997 American Society of Anesthesiologists, Inc.
Lippincott-Raven Publishers

Management of Massive Grain Aspiration

Peter Slinger, M.D., F.R.C.P.C.,* Peter E. Blundell, M.D., F.R.C.S.C.,†
Ian R. Metcalf, M.B., B.S., F.F.A.R.A.C.S., F.R.C.P.C., F.A.N.Z.C.A.‡

MASSIVE aspiration of grain is rare, and its management is not described. We report the successful salvage of a boy after an accidental fall into a grain transport wagon. The extreme levels of hypercapnia (PaCO_2 , 501 mmHg) in this case are the highest recorded in association with survival and emphasize the minimal toxicity of hypercapnia in the absence of hypoxia.¹

Case Report

While working, a previously healthy 16-yr-old, 65-kg boy fell into a 3-m deep transport wagon being filled with whole wheat grain and was immediately submersed. Efforts to rescue him required approximately 5-7 min. He was unresponsive, cyanotic, and making spontaneous respiratory efforts on removal. During transfer by ambulance to a peripheral hospital, ventilation was attempted with oxygen *via* a self-inflating bag and mask, but there was no obvious gas exchange due to the extreme lack of compliance of his respiratory system. On arrival 40 min after the accident, he was unresponsive with equal pupils (approximately 4-5 mm diameter) that reacted slowly to light. Pulse was 120 beats/min; blood pressure was 170/80 mmHg, and he was making shallow respiratory efforts at a rate of 25-30 breaths/min. An intravenous catheter was placed, and the patient was intubated with a 7.5-mm endotracheal tube (ETT) after his mouth and pharynx were cleared of large amounts of packed grain by manual extraction, suction, and forceps during direct laryngoscopy. It was possible to advance the cuff of the ETT to just below the level of the vocal cords, but the ETT would not pass further probably due to impacted grain in the trachea. Ventilation was attempted with oxygen using a self-inflating bag *via* the ETT, but no effective tidal volumes

could be detected by auscultation or inspection during positive pressure ventilation. Arterial blood gases (ABG) at that time revealed a severe hypercapnia and a mixed respiratory and metabolic acidosis (table 1). He received intravenous hydrocortisone, 1 g, and sodium bicarbonate, 88 mEq, and was transferred to the university hospital by ambulance.

On arrival in the emergency department 2 h 40 min after the accident, his neurologic status was unchanged; blood pressure was 140/80; pulse was 110 beats/min; saturation by pulse oximetry (SpO_2) was 98%, and he was making shallow gasping respiratory efforts. Subcutaneous emphysema was noticed in the supraclavicular areas bilaterally. He was treated with a bolus of intravenous sodium thiopental, 300 mg, for possible cerebral protection in case of subsequent hypoxemia during bronchoscopy. Pancuronium, 5 mg, was administered intravenously; albuterol, 400 μg , was administered *via* the ETT using a metered dose inhaler, and the ETT was changed to a 9.0-mm inner diameter tube. A blood sample showed extreme hypercapnia and acidosis (see table 1). Manual ventilation remained extremely difficult, requiring high inspiratory pressures that generated almost no detectable tidal volumes.

The Thoracic Surgery service was called, and an attempt was made at rigid bronchoscopy in the emergency room. A 9-mm rigid ventilating bronchoscope (Karl Storz GmbH and Co., Tuttlingen, Germany) was passed into the trachea, which was found to be packed with grains of wheat. The patient desaturated rapidly to 75% SpO_2 . Ventilation with oxygen during rigid bronchoscopy was attempted by manual ventilation *via* the lumen of the bronchoscope and by Sanders jet ventilation *via* the lumen of the bronchoscope,² but oxygenation could not be maintained. The patient was reintubated, and the SpO_2 returned to 98% after 5 min of manual self-inflating bag ventilation. Rigid bronchoscopy was repeated using apneic oxygenation three times during the next 30 min. Each time 5-10 wheat seeds were removed using alligator-grasping forceps. Each time, the patient desaturated precipitously and required reintubation and 5-10 min of manual ventilation to restore the saturation. It became obvious that there was so much grain in the tracheobronchial tree that this bronchoscopic technique was not feasible, and a decision was made to perform the rigid bronchoscopy while using femoral-femoral cardiopulmonary bypass for oxygenation. The patient was transferred to the operating room where noninvasive blood pressure, electrocardiograph (ECG), and SpO_2 monitors were applied. Intravenous sufentanil, 200 μg , and midazolam, 4 mg, were administered. The end-tidal CO_2 concentration was > 100 mmHg, which exceeded the limits of the end-tidal CO_2 monitor (Nellcor, N-1000 Nellcor Inc., Hayward, CA). Due to the high airway resistance, it was impossible to maintain the SpO_2 > 85% despite an FiO_2 of 1.0 using the ventilator on the anesthetic machine (Nuffield-400, Penlon Inc., Abingdon, UK) or the manual anesthetic ventilation circuit, which have high airway

* Associate Professor, Department of Anaesthesia, University of Toronto, The Toronto Hospital.

† Professor of Surgery, Department of Cardiothoracic Surgery, McGill University, The Montreal General Hospital.

‡ Associate Professor, Department of Anaesthesia, McGill University, The Montreal General Hospital.

Received from University of Toronto and The Toronto Hospital, Toronto, Ontario, and from McGill University and The Montreal General Hospital, Montreal, Quebec, Canada. Submitted for publication November 18, 1996. Accepted for publication May 30, 1997.

Address reprint requests to Dr. Slinger: Department of Anaesthesia, The Toronto Hospital, 200 Elizabeth Street, Toronto, Ontario, Canada M5G 2C4. Address electronic mail to: pslinger@torhosp.toronto.on.ca

CASE REPORTS

Table 1. Arterial Blood Gases

	Day 1 (time)					Day 2 (time)			Day 7 (time; 09:00)
	13:55	16:00	16:50	18:00	21:30	03:00	09:40	17:00	
Place	ER 1	ER 2	OR	OR	ICU	ICU	ICU	ICU	Ward
Ventilation	IPPV	IPPV	IPPV	Rigid	IMV, ETT	IMV, ETT	Spontaneous	Spontaneous	Spontaneous
	bag/mask	bag/ETT	bag/ETT	bronchoscope Venturi			mask	mask	
FiO ₂	1.0	1.0	1.0	1.0*	1.0	0.4	0.4	0.4	0.21
PaO ₂ (mmHg)	86	76	300	74	356	166	79	102	72
pH	6.59	6.62	6.73	7.29	7.35	7.44	7.34	7.38	7.46
PaCO ₂ (mmHg)	146	501	344	59	52	36	51	44	39
Bicarbonate (mm)	14	51	46	28	29	24	28	26	28

ER 1 = emergency room of community hospital; ER 2 = emergency room of university hospital; OR = operating room; ICU = intensive care unit; IPPV = intermittent positive pressure manual ventilation; IMV = intermittent mechanical ventilation.

* Ventilation with Sanders jet injector at FiO₂ = 1.0. Due to entrapment of air, the actual FiO₂ delivered is not certain during rigid bronchoscopy.

pressure release valves preset at 60 cm H₂O. Satisfactory SpO₂ levels (> 90%) were restored only with self-inflating bag ventilation with oxygen using extremely forceful manual compressions.

Before the proposed emergency cardiopulmonary bypass, a radial arterial line and a 8.5-French subclavian central venous catheter were placed for monitoring and vascular access. When the patient was placed in the Trendelenburg position for central line placement, it was noted that after each positive pressure inflation, several grain seeds would fall to the proximal end (now the most dependent portion) of the ETT during expiration.

It became evident that the more vigorous the manual inflation efforts, the more seeds fell into the ETT. These could then be removed by disconnecting the bag from the ETT and shaking the proximal end of the ETT. It was then discovered that manual percussion (clapping) of the patient's chest caused even more grain to be dislodged with each breath. During the subsequent 20 min, the surgeon performed manual chest percussions as the patient was moved alternately from supine to lateral and prone positions. An estimated 200 ml of wheat grain was removed by this method. Clinically, ventilation became progressively easier. After removal of all possible grain by this method, it was then possible to perform rigid bronchoscopy and maintain SpO₂ with Sanders jet ventilation while the trachea and major bronchi were cleared of grain with alligator forceps.

Finally, all visible grains were removed from the subsegmental bronchi with suction extraction using a 6-mm fiberoptic bronchoscope (FOB; fig. 1) via a 9.0-mm ETT with swivel adapter. This procedure required direct application of the distal end of the FOB to each wheat grain. Approximately 150 further grains of wheat were removed by this method. Total operating room time was 4 h.

The patient was transferred to the SICU intubated and initially ventilated with FiO₂, 1.0; tidal volume, 500 ml; respiratory rate, 12 breaths/min; and peak airway pressure, 28 cm H₂O. He was unresponsive with bilateral constricted pupils; blood pressure was 95/50, and pulse was 110 beats/min. Air entry was adequate bilaterally with mild expiratory rhonchi. The extent of subcutaneous emphysema at the base of the neck was unchanged from the time of admission. Chest radiograph at this time showed mild diffuse parenchymal disease in the right lower lobe, left lingula, and left lower lobe. Pneumomediastinum and pneumoperitoneum were also evident. During the next 6 h, the patient's level of consciousness gradually improved, and by the following morning, he was alert, oriented, and had no residual

neurologic defect. A repeat FOB revealed swollen erythematous tracheobronchial mucosa but no wheat grains. The patient was then extubated. Tachypnea gradually resolved over the next 72 h, and his gas exchange improved progressively. He was observed in the SICU for 48 h, then transferred to the thoracic surgical ward. He continued to intermittently cough up wheat grains for the next 7 days. He was discharged from hospital 10 days after admission; at that time, pulmonary function tests showed a moderate restrictive pattern: FEV₁/FVC = 1.96/2.37l (predicted = 3.40/3.96) with no response to bronchodilators and a borderline abnormal diffusing capacity for carbon monoxide (D_{CO}) 79% predicted. At a follow-up visit in the clinic 9 months after discharge, the patient had no residual neurologic or respiratory signs or symptoms, and pulmonary function tests had returned to normal: FEV₁/FVC = 3.57/4.29, D_{CO} = 102% predicted.

Discussion

This patient survived severe prolonged hypercapnia and acidosis due to massive aspiration of foreign bodies

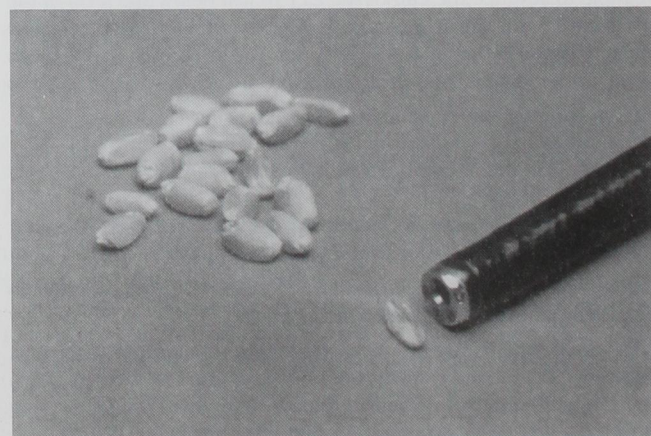


Fig. 1. An enlarged photograph showing several of the wheat grains that were removed by bronchoscopy and the distal end of the 6.0-mm diameter fiberoptic bronchoscope.

CASE REPORTS

(wheat grain) without sequelae. The most important management lesson learned from this case is the usefulness of external physical methods: positioning and chest percussion (clapping) as an aid in clearing the airways after massive aspiration of grain. It is clear in retrospect, that these external physical methods could have been used to evacuate much of the grain and thus improve ventilation at the primary hospital and at the scene of the accident.

The fortunate outcome of this case is most likely due to the unusual nature of the airway obstruction caused by massive grain aspiration. Although the proximal tracheobronchial tree became obstructed, the size of the grains (approximately $5 \times 2 \times 2$ mm) would not permit them to pass into the respiratory bronchioles³ because the small subsegmental bronchi of the fifth to eleventh generations have diameters from 1–3 mm. Interstitial spaces between the impacted grains allowed for diffusion and some clinically undetectable mass movement of gases.

The other lesson learned from this case is the seemingly benign nature of hypercapnia and acidosis if cardiovascular function is maintained and provided that the patient is not at risk for increased intracranial pressure. The physiology of hypercapnia is currently relevant to anesthesia practice because of the recent interest in permissive hypercapnia as part of the treatment of patients with adult respiratory distress syndrome and asthma.^{4,5} Resuscitation from a PaCO_2 of this level (501 mmHg) has not been reported. However, successful treatment of a patient with a postoperative PaCO_2 of 375 mmHg has been described after prolonged mask anesthesia.¹ The automated blood gas analyzer used for the arterial gases in this case was only calibrated for routine daily use to a PaCO_2 of approximately 150 mmHg and generates linear extrapolations for results outside the usual clinical range.

Carbon dioxide is known to have a dose-related sedative effect on the central nervous system due to neuronal intracellular pH changes particularly in the reticulo-activating system. Anesthesia from extreme hypercapnia may also be due in part to an inert gas narcotic effect of CO_2 . The use of CO_2 as an anesthetic in humans may be complicated by convulsions in the dose range (200 mmHg) required for loss of consciousness.⁶ In dogs, it has been shown that this epileptogenic effect of hypercapnia decreases as the PaCO_2 increases above 250 mmHg. Animal models also suggest that hypercapnia may be well tolerated when there is no hypoxia

and no hemodynamic compromise because intracellular ATPase-dependent proton extrusion and buffering tend to limit the decrease in intracellular pH to less than that of the arterial pH.⁷

We theorize that with an extremely increased airflow resistance from grain in the airways, only by applying high manual ventilation pressures in the proximal airway, using a self-inflating bag and ETT, could sufficient distal airways pressure be transmitted to maintain the patient's functional residual capacity and prevent desaturation. During rigid bronchoscopy, it was not possible to sustain high proximal airway pressures, and oxygenation could not be maintained. This high airway pressure contributed to the development of pneumomediastinum, pneumoperitoneum, and subcutaneous emphysema. However, these resolved without sequelae.

This case illustrates two major points. First, physical means to clear the airways such as chest percussion and positioning are important first-line therapy in the management of massive grain aspiration before bronchoscopy. These maneuvers should be carried out at the scene of the accident and at the primary treatment center as part of the initial resuscitation. Second, severe hypercapnia can be very benign. It is possible to survive extreme levels of respiratory acidosis without sequelae if oxygenation and circulation are maintained.

The authors thank Drs. F. Carli and J. F. Nunn for their review of the manuscript and advice. We would also like to thank Erin McGowan for her secretarial assistance.

References

1. Potkin RT, Swenson ER: Resuscitation from severe acute hypercapnia. Determinants of tolerance and survival. *Chest* 1992; 102:1742–5
2. Giesecke AH, Gerbershagen HU, Dortman C, Lee D: Comparison of the ventilating and injection bronchoscopes. *ANESTHESIOLOGY* 1978; 38:279–303
3. Nunn JF: *Nunn's Applied Respiratory Physiology*, Fourth Edition. Oxford: Butterworth, Heinemann, 1993, pp 19
4. McIntyre RC Jr, Haenel JB, Read RR, Burch JM, Moore EE: Cardiopulmonary effects of permissive hypercapnia in the management of adult respiratory distress syndrome. *J Trauma* 1994; 37:433–8
5. Tuxen DV: Permissive hypercapnic ventilation. *Am J Respir Crit Care Med* 1994; 150:870–4
6. Nunn JF: *Nunn's Applied Respiratory Physiology*, Fourth Edition. Oxford: Butterworth, Heinemann, 1993, pp 519–28
7. Litt L, Gonzalez-Mendez R, Severinghaus JW, Hamilton WK, Shulesko J, Murphy-Boesch J, James TL: Cerebral intracellular change during supercarbia: An in vivo ^{31}P nuclear magnetic resonance study in rats. *J Cereb Blood Flow Metab* 1985; 5:537–44