

CASE REPORTS

Anesthesiology

1997; 87:699-700

© 1997 American Society of Anesthesiologists, Inc.

Lippincott-Raven Publishers

Temporary Severe Vertigo Associated with Mandibular Nerve Block with Absolute Alcohol for Treatment of Trigeminal Neuralgia

Ruriko Konishi, M.D.,* Hiromasa Mitsuhashi, M.D., Ph.D.,† Satoshi Akazawa, M.D., Ph.D.,‡ Reiju Shimizu, M.D., Ph.D.§

Neurolytic block of the mandibular nerve has been used for the diagnosis and therapy of trigeminal neuralgia and cancer pain. Although complications of this therapy, including alcohol neuritis, facial and oculomotor palsy, and total sensory loss in the distribution of the Gasserian ganglion, have been reported,¹ neurolytic block of the mandibular nerve offers great potential for pain control in patients with severe neuralgia involving this branch and is thought to be associated with fewer complications than maxillary nerve block. We describe the rare complication of temporary severe vertigo after the injection of absolute alcohol into the infratemporal fossa in an attempt to achieve mandibular nerve block.

Case Report

An alcohol block was being performed after a diagnostic local anesthetic block on a 79-yr-old man who had refused surgery despite severe right facial pain that had been refractory to other treatments. His medical history was unremarkable except for hypertension, which had been managed with nifedipine and captopril for the previous 5 yr.

The patient received no premedication. We used surface anatomic landmarks, but neither radiography nor fluoroscopic guidance was used. He was placed in the supine position with his head in the right profile position. After 3 ml of mepivacaine, 1%, was infiltrated into the skin and subcutaneous tissue at the midpoint of the inferior border of the right zygomatic arch, an 8-cm, 23-gauge block needle with a movable marker was inserted perpendicular to the skin. The needle was advanced to the lateral pterygoid plate to a depth of 4.5

cm, after which the direction was adjusted to pass the posterior border of the pterygoid plate. When the needle reached a depth of 5.5 cm, the patient complained of discomfort deep to the right ear. The needle was immediately withdrawn and redirected slightly posteriorly, and it passed the pterygoid plate at a depth of 5.0 cm. When the needle was carefully advanced 0.5 cm farther, the patient reported paresthesia of the skin over the right mandible. A diagnostic block, with injection of 0.5 ml of mepivacaine, 2%, was performed at that site. Five minutes after injection of the local anesthetic, analgesia was obtained in the right lower lip, the right anterior part of the tongue, and the skin over the right mandible. Twenty minutes later, 0.3 ml of absolute alcohol was injected at the same site. Unusually high resistance was noted during the injection of absolute alcohol. Neither blood nor cerebrospinal fluid was aspirated during these procedures.

About 10 min after alcohol injection, the patient complained of generalized discomfort and feeling that the ceiling was spinning, which was followed by severe nausea and vomiting. The vertigo was not associated with any changes in hearing. Blood pressure was 200/100 mmHg, and horizontal nystagmus from left to right was observed. Because of the vertigo, he complained of difficulty keeping his eyes open. Lactated Ringer's solution was infused intravenously, and 4 mg of nicardipine was injected intravenously to control hypertension. Although a single intravenous dose of 10 mg of metoclopramide was not effective in suppressing nausea and vomiting, 30 mg of domperidone alleviated vomiting. Nystagmus was observed for more than 6 h, and nausea continued for almost 18 h; these complications completely resolved by 24 h after the block with absolute alcohol. The patient's presenting complaint of neuralgia was satisfactorily controlled on the following morning.

Discussion

Based on the anatomic relationships between the mandibular nerve and the auditory canal, it is possible to inadvertently advance a block needle directed at the mandibular nerve too deep, piercing the auditory canal (fig. 1). Should this occur, the injection of drugs into the auditory canal may have several consequences. The occurrence of temporal vertigo immediately after the accidental injection of local anesthetics into the auditory canal is known to be a possible complication during diagnostic block of the mandibular nerve. If and when this occurs, subsequent neurolytic block with neurolytic agents should be suspended to avoid further complications.

* Clinical Assistant.

† Lecturer.

‡ Associate Professor.

§ Professor and Chair.

Received from the Department of Anesthesiology, Jichi Medical School, Tochigi, Japan. Submitted for publication October 11, 1996. Accepted for publication April 25, 1997.

Address reprint requests to Dr. Konishi: Department of Anesthesiology, Jichi Medical School, 3311-1 Yakushiji, Minamikawachi-machi, Kawachi-gun, Tochigi 329-04, Japan.

Key words: Block, mandibular. Complications: vertigo.

CASE REPORTS

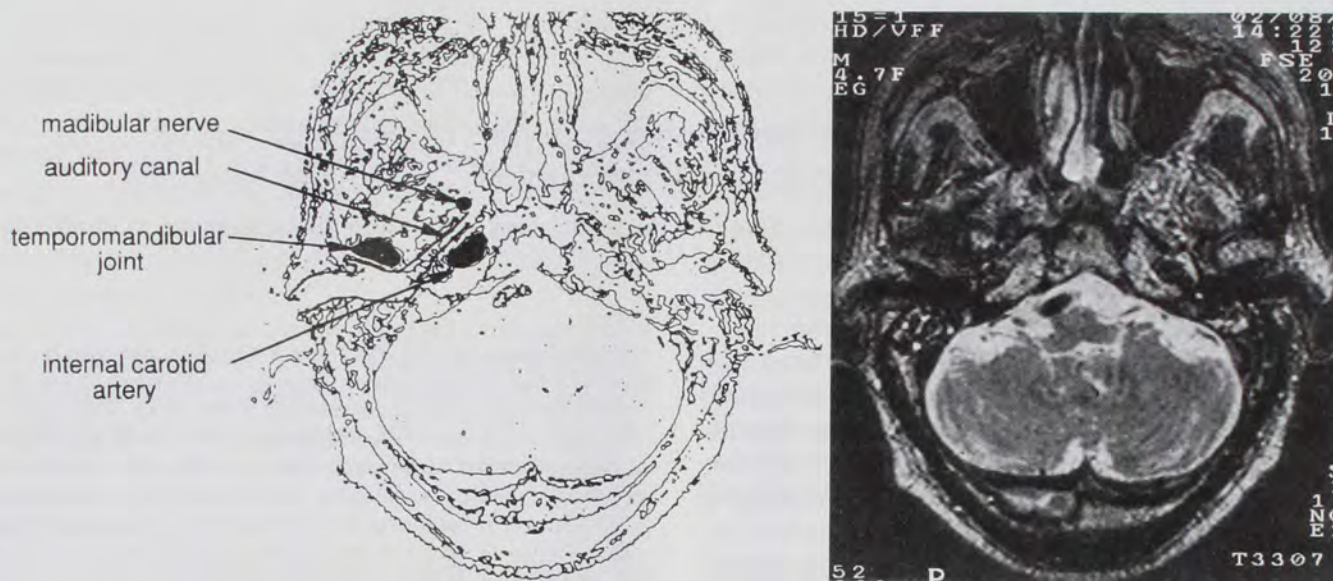


Fig. 1. Left, A figure directly constructed from the magnetic resonance image. Right, Magnetic resonance image shows the anatomic relationship between the mandibular nerve and the auditory canal.

Our patient had no history of vertigo. The diagnostic block with mepivacaine, 2%, elicited no symptoms associated with irritation of the auditory canal. Further, all of the patient's symptoms were of longer duration than would be expected in response to local anesthetics. Hence, we hypothesize that the patient's vertigo was caused by the absolute alcohol with or without the admixture of mepivacaine. There are several factors to consider in this patient as to how the absolute alcohol could have irritated the auditory canal or the vestibule. First, because the patient had undergone frequent neurolytic blocks during a 7-yr period, these neurolytic blocks may have induced inflammatory reactions, resulting in the development of adhesions in the tissues surrounding the nerve.² Second, the patient complained of discomfort deep to the right ear when the block needle was inserted in the initial attempt to elicit paresthesia. Finally, the absolute alcohol was injected against abnormal resistance. We presume that the block needle may have injured the chondral part of the auditory canal, which may have resulted in the formation of a route there. Then, when the absolute alcohol, which is a more irritative agent than local anesthetic, was injected against the resistance, a small amount may have entered the auditory canal *via* this iatrogenically created route, irritating the auditory canal, or may have reached the vestibule, resulting from a phenomenon of capillarity.

In patients who have undergone repeated blocks with neurolytic agents, abnormal degeneration in the tissues surrounding the nerve should be considered,² and thus any agents should be injected slowly to avoid infiltration into surrounding tissues. When there is a possibility of injury to the auditory canal, as in the present case, it may be advisable to suspend further blockade using absolute alcohol even when diagnostic block using local anesthetics is performed without complications. The patient should be closely observed for at least 1 h after block when absolute alcohol is used because stimulation of the vestibular apparatus may be delayed.

In summary, we described a patient who developed temporary severe vertigo after neurolytic block of the mandibular nerve with absolute alcohol. We conclude that repeated neurolytic procedures of mandibular nerve could be associated with an increased potential for complications.

References

1. Fujita Y, Nakazaki, K: Complications of alcohol injection into the mandibular nerve. Gasserian palsy and oculomotor palsy. *Reg Anesth* 1982; 5:39-41
2. Labat G: *Regional Anesthesia. Technique and Clinical Applications*, 3rd Edition. Philadelphia, WB Saunders, 1967, pp 48-97