

## CORRESPONDENCE

Anesthesiology  
1997; 86:1011  
© 1997 American Society of Anesthesiologists, Inc.  
Lippincott-Raven Publishers

*In Reply:*—We agree with Dr. Rigg *et al.* that large multicenter randomized trials are required to address most clinical outcome questions and that selection of “high-risk” patients will improve the power of such studies. We choose to study our peripheral vascular surgery patients because they were considered to be “high risk.” In our study, 85% of the patients were diabetic, 69% had hypertension, and 36% had a history of previous myocardial infarction.<sup>1</sup> In another prospective study conducted at our institution, 100 consecutive diabetic patients scheduled for vascular surgery received thallium imaging studies before surgery. Eighty percent of these patients had thallium defects, with an average of 1.8 reversible defects per patient.<sup>2</sup> We would have had to perform additional preoperative cardiac testing, such as persantine thallium or dobutamine stress echocardiography, on all enrolled patients to select an even higher risk subset, which by itself would have represented a major financial and logistical challenge.

Rigg *et al.* suggest that a multicenter trial with sufficient power to determine if choice of anesthesia has any influence on cardiac morbidity and mortality in peripheral vascular surgical patients is a “realistic and achievable” goal. We respectfully disagree. First, as discussed previously, it would be difficult to cost-effectively select a substantially higher risk group. Second, there are relatively few centers in the industrialized world that have the volume of high-risk peripheral vascular patients seen at our hospital. Third, if our study could be considered a pilot, it offers little encouragement to those investigators willing to undertake a larger study in hope of demonstrating any differences.

We also would like to correct a statement made by Rigg *et al.* They stated that postoperative epidural analgesia was not used

in our study. As we previously have reported, 40% of the patients in the epidural group had epidural morphine, and there was a trend toward a higher myocardial infarction rate in that subgroup.<sup>3</sup>

**Robert H. Bode, M.D.**

Associate Anesthetist-in-chief

**Eric T. Pierce, Ph.D., M.D.**

Director of Clinical Research

Department of Anesthesia and Critical Care

Beth Israel Deaconess Medical Center, West Campus

One Deaconess Road

Boston, Massachusetts 02215-9985

## References

1. Bode RH, Lewis KP, Zarich SW, Pierce ET, Roberts M, Kowalchuk GJ, Satwicz PR, Gibbons GW, Hunter JA, Espanola CC, Nesto RW: Cardiac outcomes after peripheral vascular surgery: Comparison of general and regional anesthesia. *ANESTHESIOLOGY* 1996; 84:3-13
2. Lane SE, Lewis SM, Pippin JJ, Kosinski EJ, Campbell D, Nesto RW, Hill T: Predictive value of quantitative dipyridamole-thallium scintigraphy in assessing cardiovascular risk after vascular surgery in diabetes mellitus. *Am J Cardiol* 1989; 64:1275-9
3. Bode RH Jr, Lewis KD, Pierce ET: General versus regional anesthesia for peripheral vascular surgery (reply). *ANESTHESIOLOGY* 1996; 85:225

(Accepted for publication February 3, 1997.)

Anesthesiology  
1997; 86:1011-2  
© 1997 American Society of Anesthesiologists, Inc.  
Lippincott-Raven Publishers

## Use of the LMA for Management of Difficult Airway Due to Extensive Facial and Neck Contracture

*To the Editor:*—The laryngeal mask airway (LMA) provides an alternative technique for managing difficult airway scenarios.<sup>1,2</sup> We would like to report a case of compromised airway resulting from an extensive severe postburn contracture and its subsequent management.

During a medical humanitarian mission to the West Bank of Palestine, a 32-year-old woman, ASA physical status 2, presented with severe extensive neck contracture that affected the neck, the chin, and the lower lip. The contracture was a result of an untreated partial and full-thickness thermal burn because of the ignition of clothing during a house fire. Surgical reconstruction had been scheduled 1 year previously, but the operation was cancelled because of failure of conventional orotracheal intubation. Because of psychological dis-

turbances and apparent limited intelligence, attempts to establish satisfactory rapport with the patient was unsuccessful. Consequently, we did not believe that an awake blind nasotracheal intubation was an option.<sup>2</sup> Also, the retrograde technique (translaryngeal-guided intubation) was not attempted because of anatomic deformity resulting from the extensive neck contracture.

After preoxygenation, anesthesia was induced with propofol and fentanyl, and the lungs were ventilated manually with oxygen and halothane by a size 4 face mask without particular difficulty. Laryngoscopy with a Macintosh laryngoscope (blade 3 and 4) was attempted twice, but the larynx could not be seen. Because the facilities for an alternative intubation (*e.g.*, new laryngoscope blades, illuminating intubating stylets, flexible fiberoptic) were not available, a LMA, size



3, was requested. The device was passed easily, and a patent airway was obtained. The patient underwent an uneventful 3-h inhalation anesthetic with spontaneous ventilation. The chin was released from the chest, and the defect, which included all the anterior and lateral neck, was covered with thick partial thickness skin grafts. The LMA was left in place until the patient regained full consciousness, and the recovery was uneventful.

**Vasilios Dimitriou, M.D., D.E.A.A.**  
**Gregory S. Voyagis, M.D.**  
**Antigone Malefaki, M.D.**  
 Department of Anesthesiology  
**Demosthenis Tsoutsos, M.D.**  
 Department of Plastics  
 G. Gennimatas General Hospital

154 Mesogion Avenue  
 GR-115 27 Athens  
 Greece

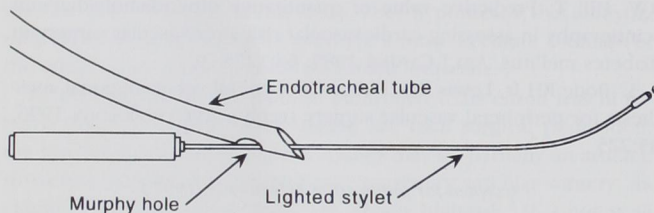
## References

1. Brain AJ: Three cases of difficult intubation overcome by the laryngeal mask airway. *Anaesthesia* 1985; 40:353-5
2. A report by the American Society of Anesthesiologists Task Force on management of the difficult airway: Practice guidelines for management of the difficult airway. *ANESTHESIOLOGY* 1993; 78:597-602

(Accepted for publication February 5, 1997.)

*Anesthesiology*  
 1997; 86:1012  
 © 1997 American Society of Anesthesiologists, Inc.  
 Lippincott-Raven Publishers

## Use of the Lighted Stylet to Aid Direct Laryngoscopy



**Fig. 1.** Distal end of endotracheal tube with the lighted stylet passing through the Murphy hole. In this configuration, the handle of the lighted stylet and endotracheal tube can be easily grasped in one hand for insertion into the trachea.

*To the Editor:*—Recently, several authors have advocated the use of a lighted stylet to facilitate either awake intubation or an unanticipated difficult intubation.<sup>1-3</sup> During direct laryngoscopy, the lighted stylet can improve the view in the hypopharynx, and transillumination can assist in guiding the endotracheal tube into the trachea.

We have had success in patients with unanticipated difficult intubation with a modification of this technique. Based on a previous report using the LTA kit (Abbott Laboratories, North Chicago, IL),<sup>4</sup> we thread a lighted stylet (Tube Stat, Concept, Clearwater, FL) through the Murphy hole of an endotracheal tube (Fig. 1). Using this configuration, the endotracheal tube does not obstruct the view while the end of the lighted stylet is placed in the trachea. Also, traumatic complications may be less likely to occur.<sup>5,6</sup> The lighted stylet threaded through the Murphy hole is more maneuverable, and the light is not attenuated by the surrounding endotracheal tube. Once the tip of the lighted stylet is placed in the trachea, the endotracheal tube can be threaded down over the tip of the stylet into the trachea. With the stylet passing through the Murphy hole, if difficulty is en-

countered because of the alignment of the curved (hockey stick) stylet and the trachea, the endotracheal tube can be gently rotated 180° to improve alignment and ease the passage of the endotracheal tube into the trachea.

**Jerry W. Biehl, C.R.N.A.**  
**Denis L. Bourke, M.D.**

Baltimore Veterans Affairs Medical Center  
 Anesthesiology Service  
 10 North Greene Street  
 Baltimore, Maryland 21201-1566

## References

1. Hung OR, Pytko S, Morris I, Murphy M, Launcelott G, Stevens S, MacKay W, Stewart RD: Clinical trial of a new lightwand device (Trachlight) to intubate the trachea. *ANESTHESIOLOGY* 1995; 83:509-14
2. Hung OR, Pytko S, Morris I, Murphy M, Stewart RD: Lightwand intubation: II—clinical trial of a new lightwand for tracheal intubation in patients with difficult airways. *Can J Anaesth* 1995; 42:826-30
3. Hung OR, Stewart RD: Lightwand intubation: I—a new lightwand device. *Can J Anaesth* 1995; 42:820-5
4. Rosenberg MB, Levesque PR, Bourke D: Use of the LTA® kit as a guide for endotracheal intubation. *Anesth Analg* 1977; 56:287-8
5. Cohn AI: Lighted stylet intubation: Greasing your way to success. *Anesth Analg* 1994; 78:1205-6
6. Szigeti CL, Baeuerle JJ, Mongan PD: Arytenoid dislocation with lighted stylet intubation: Case report and retrospective review. *Anesth Analg* 1994; 78:185-6

(Accepted for publication February 5, 1997.)