

■ CASE REPORTS

Anesthesiology
83:1112-1114, 1995
© 1995 American Society of Anesthesiologists, Inc.
Lippincott-Raven Publishers

Pediatric Caudal Epidural Catheter Sequestration: An Unusual Complication

W. Casey Lenox, M.D.,* Sabine Kost-Byerly, M.D.,† Roy Shipley, A.A., C.B.E.T.,‡ Myron Yaster, M.D.§

THE insertion of plastic catheters into the epidural space for intra- and postoperative pain relief is increasingly used in pediatric anesthetic practice because of the safety, effectiveness, and ease of the technique.^{1,2} Complications, though infrequent, include inadvertent intrathecal or intravenous placement, local anesthetic toxicity, catheter migration, and infection. Catheters have been known to break during removal, and sequestration of a segment of epidural catheter can lead to multiple complications, including infection and nerve injury. Although several textbooks and review articles make recommendations regarding management of catheter fragments retained in the epidural space, there are few reports of these occurrences in adults and children.^{3,4,||}

We report a case of sequestration of an epidural catheter segment in a child.

Case Report

A 23-month-old, 10-kg, otherwise healthy child with midshaft penile hypospadias and ventral chordee underwent elective surgical

repair using a combined general and regional anesthetic technique. After induction of anesthesia *via* mask with halothane (1–4%), nitrous oxide, and oxygen (30%), an intravenous catheter was placed, the patient was paralyzed with pancuronium (0.1 mg/kg), and the trachea was intubated. The patient was rolled to the right lateral decubitus position and the lumbosacral area washed with a 1% iodine solution. Using a loss-of-resistance technique, an 8.89-cm 18-G Crawford needle (Becton-Dickinson, Franklin Lakes, NJ) was inserted through the sacrococcygeal ligament, and a 20-G Teflon radiopaque epidural catheter (Baxter Healthcare, Valencia, CA) was easily inserted and advanced 8 cm past the tip of the needle into the epidural space, and the needle was withdrawn, leaving the catheter in place. At no time was there an attempt to withdraw the catheter through the needle. After a negative aspiration for blood and cerebrospinal fluid, the catheter was injected with 3 ml 0.25% bupivacaine to which 5 µg/ml epinephrine was added (test dose). The site was covered by an occlusive dressing (OpSite, Smith and Nephew Medical LMT, Hull HU3 2BN, United Kingdom), and the edges of the dressing were reinforced with 1-inch Micropore tape (3M Corp, Minnesota). An additional 7 ml of local anesthetic solution was administered after the negative test dose. The length of surgery was 253 min, during which the patient received four supplementary 7-ml doses of 0.25% bupivacaine with epinephrine. The muscle relaxant was antagonized at the end of surgery, the trachea was extubated, and the patient was taken to the postanesthesia care unit.

In the postanesthesia care unit, a continuous epidural infusion of 0.3% lidocaine with 1 µg/ml fentanyl was begun at a rate of 5 ml/h. His postoperative course was uneventful. On the first postoperative day, the patient continued to have excellent analgesia with minimal sedation. Despite physical restraints, he was fairly mobile in bed. The dressing remained intact, and the epidural insertion site appeared to have no signs of infection. His 24-h plasma lidocaine level was 1.3 mg/l (Abbott TDX analyzer). The infusion was continued at the same rate until the following day, when it was decided to discontinue epidural analgesia and convert to enteral analgesics.

When the epidural dressing was removed, the catheter tip was not present. The dressing was wet with clear fluid, and the infusion still running. The proximal portion of the catheter was intact with the most distal end of this part curved slightly at the point of fracture. Judging by the remaining marker lines on the catheter, approximately 8 cm of the catheter were unaccounted for. There was a small spot of erythema approximately 3 mm in diameter at the insertion site, but no catheter fragment could be seen or palpated. Pelvic radiographs (anteroposterior and lateral) confirmed that approximately 8–9 cm of catheter was left *in situ*. A computed tomogram of the insertion site and lower spine was obtained (fig. 1). The proximal portion of the sequestered catheter segment was noted to be subcutaneous with the distal (superior) portion in the epidural space. The patient was taken to the operating room and anesthetized, and after skin incision, had the catheter fragments removed. An additional break in the catheter was noted during this procedure, resulting in

* Assistant Professor, Department of Anesthesiology/Critical Care Medicine, The Johns Hopkins Hospital.

† Instructor, Department of Anesthesiology/Critical Care Medicine, The Johns Hopkins Hospital.

‡ Associate Clinical Engineer, Department of Biomedical Engineering, The Johns Hopkins Hospital.

§ Associate Professor, Departments of Anesthesiology/Critical Care Medicine and Pediatrics, The Johns Hopkins Hospital.

|| Wedel DJ: Neurologic complications of central neural blockage, 44th Annual Refresher Course Lectures and Clinical Update Program. Lecture 253. Park Ridge, American Society of Anesthesiologists, 1993.

Received from the Departments of Anesthesiology/Critical Care Medicine, Biomedical Engineering, and Pediatrics, The Johns Hopkins Hospital, Baltimore, Maryland. Submitted for publication March 15, 1995. Accepted for publication May 27, 1995.

Address reprint requests to Dr. Lenox: Department of Anesthesiology/Critical Care Medicine, Johns Hopkins Hospital, 600 North Wolfe Street, Baltimore, Maryland 21287. Address electronic mail to: clenox@welchlink.welch.jhu.edu.

Key words: Anesthesia: pediatric. Anesthetic techniques: caudal epidural. Complications: epidural catheter sequestration.

CASE REPORTS

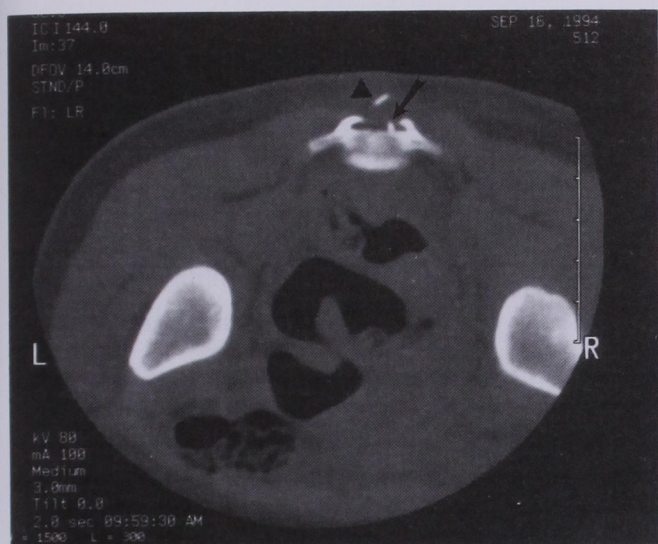

Fig. 1. Computed tomography scan of sacral region. Arrow: catheter in epidural space; arrowhead = subcutaneous catheter fragment.

two separate retained fragments and both were retrieved (fig. 2). Photomicrographs of the catheter showed fragmented ends that were consistent with twisting or crimping before breakage (fig. 3).

The patient was discharged the following day without further sequelae or problems.

Discussion

Although the potential for an epidural catheter to fracture and for the broken catheter segment to be sequestered within the epidural space has long been known, it has rarely been reported. This is only the second report of a sequestered epidural catheter fragment in a pediatric patient and the first to be published in a refereed journal. De Armendi *et al.* described a similar patient in whom a tunneled, pediatric epidural catheter was discovered to be fractured at the time of removal.⁴ When the sequestered segment was surgically retrieved, it appeared to be sheared. This is in contrast to our patient in whom the catheter was neither tunneled nor sheared. Rather, the two segments appeared to be twisted or crimped before fracturing (fig. 3).

Optimal management of a sequestered epidural catheter is unknown. Sequestration of a segment of epidural




Fig. 2. Sequestered epidural catheter fragments removed from patient. (A) Epidural fragment. (B) Subcutaneous fragment.

catheter can lead to multiple complications, including infection, fibrosis, and nerve injury. Fibrosis with spinal canal narrowing resulting in lower extremity weakness and pain has been reported as a complication of a sequestered catheter in an adult patient.⁵ The patient underwent a lumbar laminectomy with removal of the epidural mass, has made an uneventful recovery, and has been asymptomatic to date. Epidural catheter sequestration in a 56-yr-old man was reported nearly three decades ago. That patient had no neurologic abnormalities at a 6-month followup.⁶

Because epidural catheters are manufactured of biologically inert plastic materials, many textbooks recommend leaving the sequestered portion of the catheter in place rather than attempting surgical removal.^{3,4} Although this may be a reasonable management option in some adult patients, it may not be in a child. In a growing 2-yr-old child, the time the catheter is left *in situ* would be much longer than in an adult and would expose the patient to a greater potential risk of infection, fibrosis, fragment migration, erosion through dura,

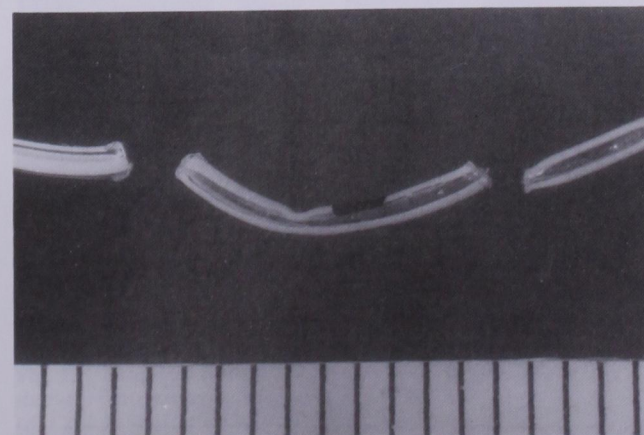


Fig. 3. Photomicrograph of fractured areas in the epidural catheter. Each mark represents 1 mm.

DeArmendi AJ, Ryan JF, Chang HM, Liu LMP, Jaramillo D: Retained caudal catheter in a paediatric patient. *Paediatric Anaesthesia* 2:325-327, 1992.

CASE REPORTS

and irritation of neural tissues. The alternative, removal of the epidural catheter fragment, requires a laminectomy, which in a 2-yr-old may disrupt spinal development and result in scoliosis.

Several studies have reported the safety and effectiveness of caudal anesthesia in pediatric patients.^{7,8} These have been limited primarily to single dose, "through the needle" administration techniques. There are few reports of complications associated with continuous epidural infusions through catheters placed intraoperatively despite the increasing use of this technique in many centers performing pediatric anesthetics.^{9,10} The report by Strafford *et al.* discussed only infectious complications of pediatric epidural catheters and made no comments regarding other complications.¹¹

Diagnostic imaging was crucial in determining the course of our management plan. Computed tomography can delineate the site where the proximal and distal ends of a sequestered catheter lie. If a segment of catheter lies above the epidural canal and below the skin, catheter removal is relatively easy and is the course of action we would recommend. If the sequestered fragment is entirely within the spinal canal, the parents, neurosurgeons, and anesthesiologists will have to weigh the risks and benefits of leaving the catheter fragment *in situ* versus operative intervention.

In conclusion, we recommend obtaining a computed tomography scan and neurosurgical consultation as soon as possible after the recognition of a retained epidural catheter fragment. In our patient, computed to-

mography identified a subcutaneous fragment of the sequestered epidural catheter, which allowed removal by skin incision alone.

References

1. Yaster M, Maxwell LG: Pediatric regional anesthesia. *ANESTHESIOLOGY* 70:324-338, 1989
2. Dalens B: Regional anesthesia in children. *Anesth Analg* 68: 654-672, 1989
3. Cousins MJ, Bromage PR: Epidural neural blockade. *Neural Blockade in Clinical Anesthesia and Management of Pain*. Edited by Cousins MJ, Bridenbaugh PO. Philadelphia, JB Lippincott, 1988, pp 253-360
4. Schechter N, Berde C, Yaster M: Pain in infants, children, and adolescents. Baltimore, Williams and Wilkins, 1993
5. Staats PS, Stinson MS, Lee RR: Lumbar stenosis complicating retained epidural catheter tip. *ANESTHESIOLOGY* 83:1115-1118, 1995
6. Crawley BE: Catheter sequestration: A complication of epidural analgesia. *Anaesthesia* 23:270-272, 1968
7. Dalens B, Hasnaoui A: Caudal anesthesia in pediatric surgery: Success rate and adverse effects in 750 consecutive patients. *Anesth Analg* 68:83-89, 1989
8. McGown RG: Caudal analgesia in children: Five hundred cases for procedures below the diaphragm. *Anaesthesia* 37:806-818, 1982
9. Henderson K, Sethna NF, Berde CB: Continuous caudal anesthesia for inguinal hernia repair in former preterm infants. *J Clin Anesth* 5:129-133, 1993
10. Desparmet J, Meistelman C, Barre J, Saint-Maurice C: Continuous epidural infusion of bupivacaine for postoperative pain relief in children. *ANESTHESIOLOGY* 67:108-110, 1987
11. Strafford MA, Wilder RT, Berde CB: The risk of infection from epidural analgesia in children: A review of 1620 cases. *Anesth Analg* 80:234-238, 1995