

■ CASE REPORTS

Anesthesiology
81:760-762, 1994
© 1994 American Society of Anesthesiologists, Inc.
J. B. Lippincott Company, Philadelphia

Transesophageal Echocardiographic Identification of Persistent Left Superior Vena Cava: Retrograde Administration of Cardioplegia during Cardiac Surgery

William A. Roberts, M.D., Ph.D.,* William H. Risher, M.D.,† Karl Q. Schwarz, M.D.‡

CARDIOPLEGIA, a potassium-rich solution administered to the myocardium during cardiopulmonary bypass, has reduced the morbidity of cardiac surgical procedures by protecting the myocardium from ischemic injury. Cardioplegia solution may be administered in a retrograde fashion *via* the coronary sinus in clinical situations where prolonged periods of cardiac arrest are planned or anterograde administration is impractical. Retrograde administration allows continuous infusion of cardioplegic solutions during the creation of coronary artery bypass grafts or insertion of prosthetic valves.

Persistent left superior vena cava (PLSVC) is a relative contraindication to retrograde administration of cardioplegia. In the presence of PLSVC, the coronary sinus is enlarged and may prevent the coronary sinus catheter balloon from occluding the sinus, resulting in failure to ensure retrograde flow of cardioplegia to the myocardium. Further, with PLSVC, the venous drainage from the left jugular vein and left arm is through the coronary sinus to the right atrium. Under these circumstances, even if an adequate seal was established by the coronary sinus catheter, the cardioplegia delivered would largely be distributed to these veins, rather than to the myocardium.

We report a case of diagnosis of PLSVC by intraoperative transesophageal echocardiography (TEE) before the introduction of a retrograde coronary sinus catheter. This diagnosis modified plans for cardioplegia administration in a patient with severe right and left ostial coronary artery disease and aortic regurgitation requiring aortic valve replacement.

Case Report

The patient, a 67-yr-old man, was found on initial examination to have worsening congestive heart failure of several months' duration. He had a history of stable angina and aortic regurgitation but no previous myocardial infarction. A transthoracic echocardiogram revealed a resting left ventricular ejection fraction of approximately 20%. The left ventricle was hypertrophied, dilated, and globally hypokinetic. Severe aortic insufficiency was also noted. The chest radiograph revealed cardiomegaly, diffuse interstitial markings and peribronchial cuffing. The electrocardiogram revealed left ventricular hypertrophy by voltage.

Coronary angiography demonstrated proximal, ostial lesions of the left main (70–80%) and right (40–50%) coronary arteries. There was no significant gradient across the aortic valve (8 mmHg), nor was there evidence of mitral valve dysfunction. Aortic valve replacement and coronary artery revascularization with vein grafts was scheduled.

A radial artery catheter and large bore peripheral intravenous catheter were inserted and anesthesia was induced intravenously with 50 µg/kg fentanyl, 4 mg midazolam, and 10 mg vecuronium. After induction of anesthesia, a right internal jugular sheath was inserted and a pulmonary artery catheter was placed. A biplane TEE probe (128P0C, Acuson, Mountain View, CA) was then inserted. The previous findings of aortic regurgitation and left ventricular dysfunction were confirmed. There was left atrial dilation, but no thrombi were apparent. The right cardiac chambers appeared normal, with the exception of marked dilation of the coronary sinus (fig. 1). In the absence of significant pulmonary hypertension or right atrial volume overload, enlargement of the coronary sinus suggests a diagnosis of PLSVC. Right atrial and pulmonary artery pressures at the time of the intraoperative TEE were 12 and 35/16 mmHg, respectively.

To confirm the suggestion of PLSVC, a contrast study was performed with 10 ml hand-agitated 5% albumin injected *via* peripheral vein of the left arm. Echo contrast first appeared in the enlarged coronary sinus (fig. 2) and subsequently filled the right atrium. The diagnosis of PLSVC by TEE was confirmed by direct visual inspection of the

* Assistant Professor, Department of Anesthesiology.

† Assistant Professor, Department of Surgery, Division of Cardiac Surgery.

‡ Assistant Professor, Department of Medicine, Division of Cardiology.

Received from the Strong Memorial Hospital, School of Medicine and Dentistry, University of Rochester Medical Center, Rochester, New York. Accepted for publication April 28, 1994.

Address reprint requests to Dr. Roberts: Department of Anesthesiology, Box 604, Strong Memorial Hospital, School of Medicine and Dentistry, University of Rochester Medical Center, 601 Elmwood Avenue, Rochester, New York 14642.

Key words: Cardioplegia, retrograde. Persistent left superior vena cava. Transesophageal echocardiography.

CASE REPORTS

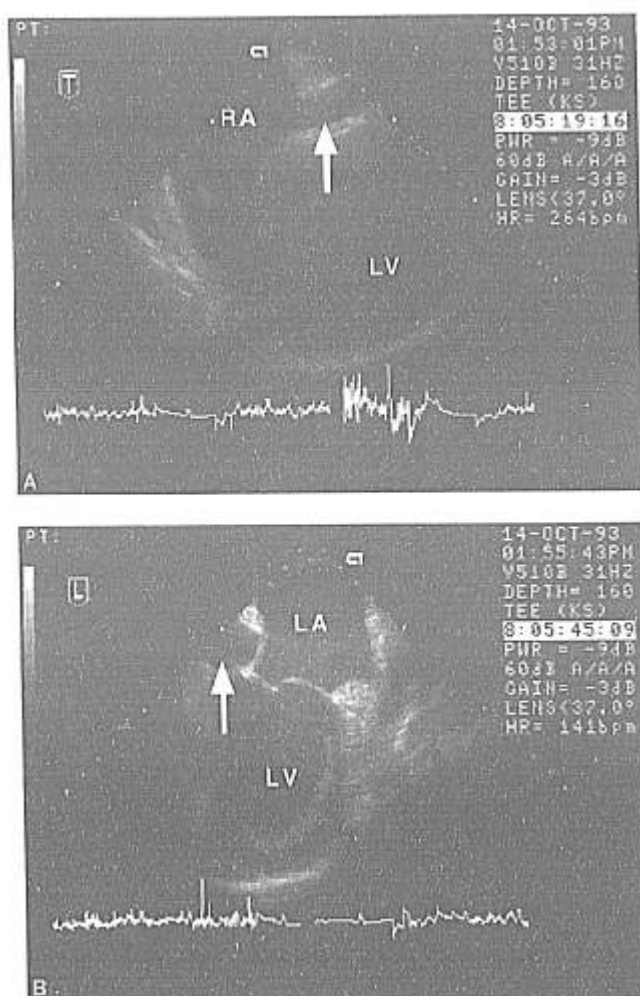


Fig. 1. (A) Long-axis view of the left ventricle (LV). Arrow = coronary sinus; RA = right atrium. (B) Inferiorly angled four-chamber view of the relation between the left atrium (LA), LV, and coronary sinus (arrow).

mediastinum by the surgeon. The innominate vein was absent, and the coronary sinus was dilated.

Retrograde administration of cardioplegia solution had been planned for this patient, but because of the PLSVC, antegrade administration of cardioplegia solution was used. Coronary artery bypass grafts were created, and aortic valve replacement was carried out successfully. Examination by TEE after bypass showed no increase in left ventricular dysfunction, and the prosthetic valve was found to be in good position and functioning well.

Discussion

In this case of PLSVC diagnosed by intraoperative TEE, the PLSVC diagnosis modified initial plans for retro-

grade administration of cardioplegia solution *via* the coronary sinus.

The anatomic features of venous return to the heart and of PLSVC were described in detail by Steinberg *et al.* in their well-illustrated presentation of 11 cases in 1953.¹ The presence of PLSVC, resulting from residual left anterior cardinal vein, occurs in 0.3–0.5% of the general population. PLSVC may complicate the placement of pulmonary artery or central venous catheters. Awareness of this anomaly may reduce confusion about the position of central catheters that appear to have strayed.²

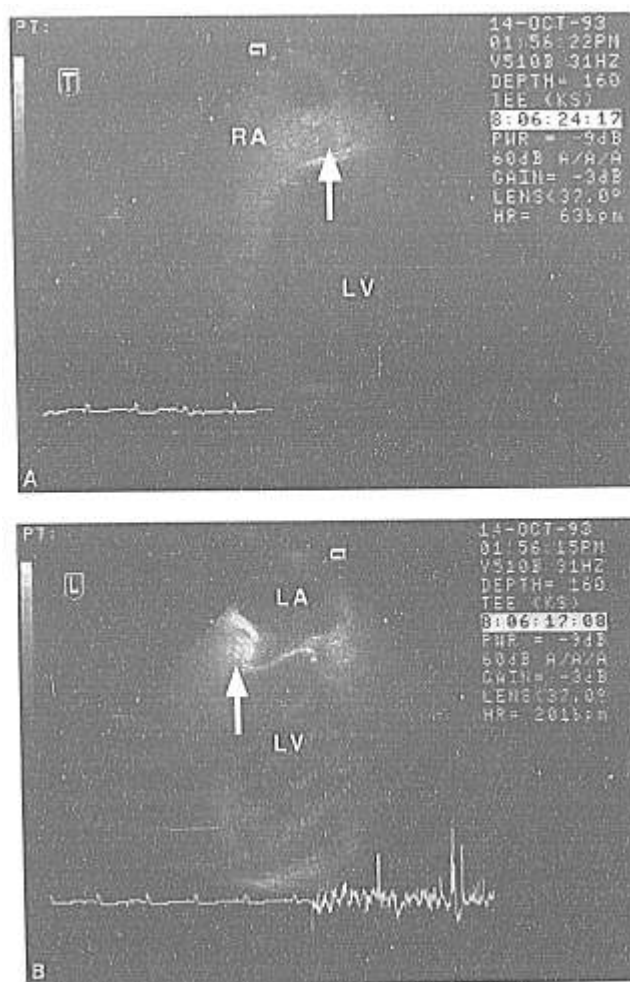


Fig. 2. (A) Image obtained immediately after injection of agitated albumin contrast in a vein of the left arm. Opacification of the coronary sinus (arrow) preceded appearance of contrast in the right atrium. Orientation as in figure 1A. (B) Inferiorly angled four-chamber view. Orientation as in figure 1B. Arrow = contrast opacification of the coronary sinus.

CASE REPORTS

In the operating room, PLSVC may be diagnosed at the surgical field by absence or atresia of the innominate vein and dilation of the coronary sinus. The latter finding is secondary to the large volume of blood returning from the left upper extremity and head, passing through the PLSVC and coronary sinus on route to the right atrium.

The TEE findings of PLSVC include dilation of the coronary sinus in the absence of right atrial dilation or increased right atrial pressure. Coronary sinus diameter in the presence of PLSVC is variable, but may be so great as to result in confusion between the coronary sinus and the left atrium, the pulmonary veins, the descending thoracic aorta or pericardial effusions. The coronary sinus is best visualized in the four-chamber long-axis view of the left ventricle by using the longitudinal plane of a biplane TEE probe. In these views, the coronary sinus is seen posterior to the left atrium on the atrial side of the atrioventricular groove (fig. 1A). It can also be visualized in the five-chamber view or as it traverses the atrioventricular groove in an inferiorly angled transverse four-chamber view (fig. 1B).

PLSVC may be suggested by a large coronary sinus, but the diagnosis can be definitively confirmed by the echo-contrast studies described here. With injection of agitated albumin in a left arm vein, contrast should appear first in the coronary sinus, followed by opacification of the right heart chambers. Injection of echo contrast in a right arm vein should opacify the right heart chambers, but not the dilated coronary sinus.

As has been stated above, we planned initially to use retrograde administration of cardioplegia solution delivered *via* the coronary sinus in this patient for whom aortic valve replacement and coronary artery bypass grafting were scheduled. Retrograde administration of cardioplegia solution is usually reserved for use in patients with complex cardiac disease when a prolonged bypass interval is anticipated. Another indication for retrograde administration of cardioplegia solution is the presence of proximal coronary artery lesions that may prevent successful administration of cardioplegia solution *via* the diseased coronary arteries.

If retrograde perfusion of cardioplegia solution is desired in a patient with PLSVC, two management options are available.^{3,4} A venous cannula can be placed in the PLSVC to drain the left side of the upper circulation. A purse-string banding suture can then be placed around the coronary sinus catheter to ensure retrograde flow of the cardioplegia solution to the myocardium

despite the large coronary sinus diameter. Alternatively, a coronary sinus catheter can be placed and banded to ensure retrograde flow during periods of cardioplegia administration. The PLSVC can be intermittently clamped to prevent distribution of the cardioplegia solution to the left arm and cerebral veins.

If a surgical procedure requiring an open right atrium is planned in a patient with PLSVC, the PLSVC should be cannulated, either directly or *via* the coronary sinus ostium. If the PLSVC is prevented from draining to the right atrium or venous tubing of the bypass circuit during the procedure, cerebral edema may result from cerebral venous hypertension. Under such circumstances, the former of the above management options is recommended, as this will allow for a bloodless operative field throughout the procedure. In all other cases the latter management option is preferable, as this does not require a third venous cannula insertion.

In any cardiac surgical procedure involving retrograde administration of cardioplegia solution, the coronary sinus pressure should be monitored during cardioplegia solution administration. Low coronary sinus pressure may be the only indicator of occult PLSVC, even if the innominate vein appears normal.⁵ Failure to recognize this may result in inadequate cardiac preservation and preventable myocardial injury.

It is important to include identification of the coronary sinus in preoperative and intraoperative TEE studies if retrograde administration of cardioplegia solution is planned. The TEE diagnostic criteria for PLSVC have been summarized and alternative strategies for management of retrograde administration of cardioplegia solution in the presence of PLSVC are discussed.

References

1. Steinberg I, Dublilier W, Lukas DS: Persistence of left superior vena cava. *Dis Chest* 24:479-488, 1953
2. Leibowitz AB, Halpern NA, Myung-Ho L, Iberti TJ: Left-sided superior vena cava: A not-so-unusual vascular anomaly discovered during central venous and pulmonary artery catheterization. *Crit Care Med* 20:1119-1122, 1992
3. Balasundaram S, Al-Halees Z, Duran CG: Persistent left superior vena cava: A simple technique for adequate drainage during cardiopulmonary bypass. *J Cardiovasc Surg* 32:59-61, 1991
4. Shahian DM: Retrograde coronary sinus cardioplegia in the presence of persistent left superior vena cava. *Ann Thorac Surg* 54:1214-1215, 1992
5. Meharwal ZS, Trehan N: Retrograde coronary sinus cardioplegia (letter). *Ann Thorac Surg* 56:1006, 1993