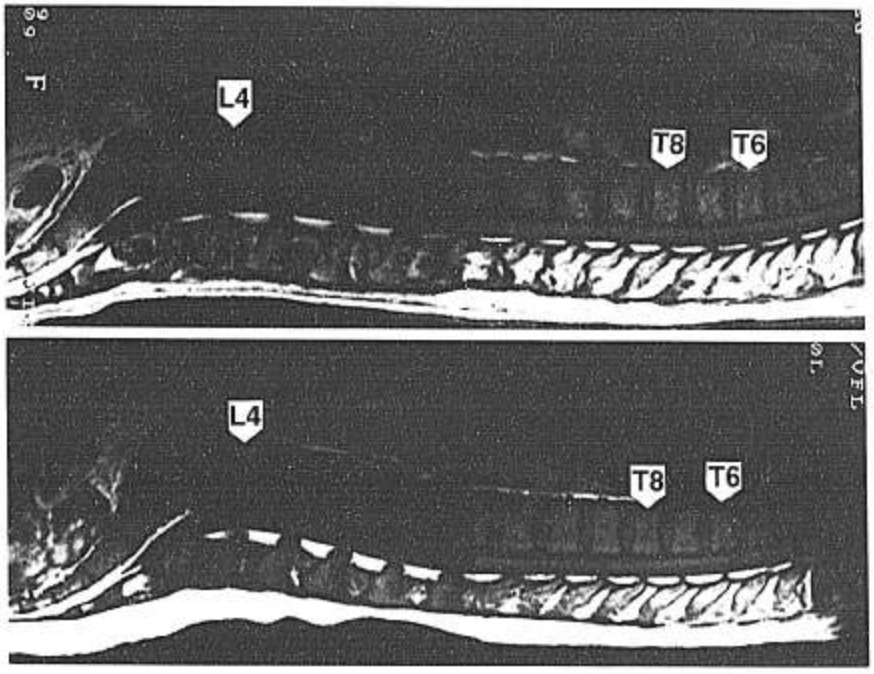

Fig. 1. T1-weighted sagittal midline magnetic resonance images show the spinal column of a 38-yr-old, 170-cm, 67-kg man (*top*) and a 19-yr-old, 153-cm, 54-kg woman (*bottom*). The examinations were performed in the volunteers in the supine position with legs extended. The dural sac lies within the spinal canal and terminates at S2. The level of termination of the spinal cord is seen at L1–L2. In both images, L4 is located at a position higher than L3, whereas T8 is located at a position lower than T6.

Yoshihiro Hirabayashi, M.D.
Lecturer in Anesthesiology

Reiju Shimizu, M.D.
Professor and Chairman of Anesthesiology

Kazuhiko Saitoh, M.D.
Instructor of Anesthesiology

Hirokazu Fukuda, M.D.
Instructor of Anesthesiology

Department of Anesthesiology
Jichi Medical School
Tochigi, 329-04 Japan

References

1. Macintosh RR: Lumbalpunktion and spinalanästhesie. Basel, Benno Schwabe & CO, 1953, p116
2. Dripps RD, Eckenhoff JE, Vandam LD: Introduction to Anesthesia. The Principles of Safe Practice. 7th ed. Philadelphia, WB Saunders, 1988, p231
3. Higgins CB, Hricak H, Helms CA: Magnetic resonance imaging of the body. 2nd ed. New York, Raven Press, 1992, p1058
4. St Amour TE, Hodges SC, Laakman RW, Tamas DE: MRI of the spine. New York, Raven Press, 1994, p6
5. Bisese JH: MRI: A Teaching File Approach. New York, McGraw-Hill, 1988, pp147–148

(Accepted for publication April 16, 1994.)

Anesthesiology
81:267–268, 1994
© 1994 American Society of Anesthesiologists, Inc.
J. B. Lippincott Company, Philadelphia

EMLA Cream in the Treatment of Causalgic Pain

To the Editor:—The management of causalgic pain includes sympathetic blockade, transcutaneous electrical nerve stimulation (TENS),[1] vasodilators,[2] carbamazepine,[3] calcitonin,[4] and intravenous local anaesthetics.[5] Some success also has been reported with topical creams such as prostaglandin E1[6] and 50% dimethylsulpoxide, a free-radical scavenger.[7] EMLA cream (a 1:1 oil and water eutectic mixture of 2.5% lidocaine and 2.5% prilocaine)[8] has been used successfully in the management of herpetic neuralgia.[9,10] We would like to report

Downloaded from http://asa2.silverchair.com/anesthesiology/article-pdf/81/1/267/645292/0000542-199407000-00042.pdf by guest on 19 April 2024

a patient in whom EMLA cream produced marked and sustained alleviation of severe sciatic nerve causalgic pain.

After a parachuting accident, a 24-yr-old man, who sustained multiple lower limb and pelvic fractures, required internal fixation of the right femur. An epidural infusion of bupivacaine and fentanyl was commenced at the time of operation, and excellent analgesia was achieved in the postoperative period. After removal of the catheter on day 7, weakness of the right extensor hallucis longus and absent ankle dorsiflexion was evident. The patient also complained of constant and severe burning pain of the dorsum of the foot, with excruciating pain on light touch. Clinical examination showed hyperesthesia and allodynia in an L5 dermatomal distribution, which was attributed to sciatic nerve injury at the greater sciatic notch due to fracture of the iliac wing. Increasing doses of parenteral opioids and a course of carbamazepine failed to achieve pain control.

Pain clinic review was requested on day 20. Because of suspicion that the first interdigital cleft was spared, a superficial peroneal nerve block was performed. Pain in the dorsum of the foot was controlled and intense interdigital hyperpathia unmasked, confirming the L5 pattern. A second epidural infusion was commenced, supplemented by TENS and 75 mg doxepin. Satisfactory analgesia was achieved, and the infusion was gradually decreased and stopped after 7 days. Causalgic pain initially was much improved and the catheter was removed. Severe nocturnal spasms of hyperesthesia recurred 24 h after catheter removal, and pain, assessed using a visual analog 10-point scale, increased from 4 to 10. Treatment options, including a third epidural, chemical sympathectomy, and intravenous regional anesthesia, were declined by the patient. It was decided to trial EMLA cream to the affected area.

The cream (5 g) was thickly applied for 18 h/day, between 6 PM and midday. Dramatic relief was obtained after the first application with a decrease in pain score from 8 to 4. The patient stopped TENS after 24 h and doxepin after 48 h. After 5 days, he mobilized the limb for the first time and, although altered sensation was evident in the absence of EMLA cream, causalgic pain had ceased and light touch was easily tolerated. He was discharged 6 days after commencing EMLA cream. At the 2-week followup, there was no recurrence of causalgic symptoms, and the patient had ceased to use EMLA cream after 8 days. There were no trophic or residual vascular changes in skin at this time.

The characteristic spontaneous burning pain, allodynia, and hyperpathia of causalgic pain was described by de Takats in 1945[11] and the association with pelvic fracture is well recognized.[12] The modern theory about the pathogenesis of causalgic pain includes both peripheral and central causes. Peripheral causes include spontaneous discharge from neuronal sprouts, with an increase in their sensitivity to adrenergic compounds and increased firing in dorsal root ganglia. Central causes include spontaneous activity of deafferented nerves in the dorsal horn and development of responses to new receptive fields.[13] If untreated, the abnormality becomes self-sustaining and independent of peripheral input.[14] The self-perpetuating cycle of pain can be broken more easily in the early phase by sympathetic blockade achieved by epidural or subarachnoid anesthesia, lumbar sympathectomy, or a guanethidine block. Although not measured, it is unlikely that circulating levels of local anesthetic were responsible for the patient's improvement. Stowe *et al.* reported that plasma concentrations of lidocaine and prilocaine were well below toxic levels when 5–10 g was applied for 24 h in patients with postherpetic neuralgia.[10] Methemoglobinemia was not noted in our patient. It is possible that the EMLA cream may help break the cycle of pain by either local sympathetic inhibition or preferential binding to traumatized tissue.[15] The use of ELMA cream in the management of causalgic pain is worth further investigation.

D. Mecklem, M.B., B.S., F.A.N.Z.C.A.
Staff Anaesthetist

J. Brimacombe, M.B., Ch.B., F.R.C.A.
Senior Lecturer
University of Queensland

Department of Anaesthesia
Cairns Base Hospital
Cairns
Australia 4870

References

1. Stilz RJ, Carron H, Sanders DB: Reflex sympathetic dystrophy in a six year old: Successful treatment by transcutaneous nerve stimulation. Anesth Analg 56:438–443, 1977

2. Prough DS, McLeskey CH, Poehling GP, Koman LA, Weeks DB, Whitworth T, Semble EL: Efficacy of oral nifedipine in the treatment of reflex sympathetic dystrophy. ANESTHESIOLOGY 62:796–799, 1985

3. Reynolds JEF: Anti-epileptics, Martindale: The Extra Pharmacopoea. London, The Pharmaceutical Press, 1993, pp 292–314

4. Jaeger H, Maier C, Wawersik J: Postoperative behandlung von phantomschmerzen und kausalgien mit calcitonin. Anaesthesist 37: 71–76, 1988

5. Schnapp M, Mays KS, North WC: Intravenous chloroprocaine in the treatment of pain. Anesth Analg 60:844, 1981

6. Mashimo T, Tomi K, Pak M, Demizu A, Yoshiya I: Relief of causalgia with prostaglandin E1 ointment. Anesth Analg 72:700–701, 1991

7. Langendijk PN, Zuurmond WW, van Apeldoorn HA, van Loenen AC, de Lange JJ: Goede resultaten van behandeling van acute reflectoir-sympathische dystrofie met een 50% dimethylsulfoxide creme. Ned Tijdschr Geneeskd 137:500–503, 1993

8. Gajraj NM, Pennant JH, Watcha MF: Eutectic mixture of local anesthetics (EMLA) cream. Anesth Analg 78:574–583, 1994

9. Stow PJ, Glynn CJ, Minor B: EMLA cream in the treatment of post-herpetic neuralgia: Efficacy and pharmacokinetic profile. Pain 39:301–305, 1989

10. Stowe PJ, Glynn C, Minor BG: A study to explore the effect of EMLA cream in postherpetic neuralgia. Pain 39:301–305, 1989

11. de Takats G: Causalgia states in peace and war. JAMA 128: 699, 1945

12. Sullivan RJ, Thomas PS, Geel CV: Pain clinic #15: Treatment of sciatic nerve causalgia following pelvic fracture. Orthop Rev 19: 553–558, 1990

13. Girgis FL, Parry CB: Management of causalgia after peripheral nerve injury. Int Disabil Stud 11:15–20, 1989

14. Prithvi Raj P: Prognostic and therapeutic local anesthetic blockade, Neural Blockade in Clinical Anesthesia and Management of Pain. Edited by Cousins MJ, Bridenbaugh PO. Philadelphia, JB Lippincott, 1988, pp 899–934

15. Allen FM, Grossman LW, Lyons LV: Intravenous procaine analgesia. Anesth Analg 25:1, 1945

(Accepted for publication April 17, 1994.)

Downloaded from http://asa2.silverchair.com/anesthesiology/article-pdf/81/1/267/645292/0000542-199407000-00042.pdf by guest on 19 April 2024